



LSTR Antibiotic Paste Versus Zinc Oxide and Eugenol Pulpectomy for the Treatment of Primary Molars with Pulp Necrosis: A Randomized Controlled Trial

Joyce Moura, DDS¹ • Marina Lima, MS, PhD² • Natália Nogueira, DDS³ • Marcus Castro, DDS⁴ • Cacilda Lima, MS, PhD⁵ • Marcoeli Moura, MS, PhD⁶ • Lucia Moura, MS, PhD⁷

Abstract: Purpose: The purpose of this study was to compare the effectiveness of lesion sterilization and tissue repair (LSTR) antibiotic paste comprised of chloramphenicol, tetracycline, and zinc oxide and eugenol (CTZ) versus zinc oxide eugenol (ZOE) pulpectomy in the treatment of primary molars with pulp necrosis. **Methods:** A total of 70 three- to eight-year-old subjects with 88 primary mandibular molars with pulp necrosis were included. The teeth were randomized to the CTZ group or ZOE group. The time taken to perform both techniques was recorded. The parents of the children and the dentist who performed clinical evaluations were blind to the group assignment, although the radiographic evaluator could see the difference in treatments. Clinical and radiographic assessments were performed at three, six, nine, and 12 months. **Results:** At the 12-month evaluation, the clinical success was 86.4 percent for CTZ and 90.9 percent for ZOE ($P=0.50$), the radiographic success was 75.0 percent for CTZ and 72.7 percent for ZOE ($P=0.81$), and the overall success was 70.5 percent for CTZ and 72.7 percent for ZOE ($P=0.81$). The mean time taken to perform was 61.4 (± 20.5 standard deviation) minutes for CTZ and 145.1 (± 53.2) minutes for ZOE ($P<0.001$). **Conclusions:** At 12 months, both techniques presented no significant difference in success rates for nonvital pulp therapy in primary molars with necrosis. The lesion sterilization and tissue repair procedure time using chloramphenicol, tetracycline, zinc oxide, and eugenol was significantly shorter than for a zinc oxide eugenol pulpectomy. (*Pediatr Dent* 2021;43(6):435-42) Received January 22, 2021 | Last Revision August 26, 2021 | Accepted August 30, 2021

KEYWORDS: PULP NECROSIS, RANDOMIZED CONTROLLED CLINICAL TRIALS, ROOT CANAL FILLING MATERIALS

Endodontic treatment in primary molars with pulp necrosis represents one of the challenges faced in the pediatric dentistry clinic.^{1,2} The main difficulties are related to the anatomical complexity of the root canals and the long time needed to carry out the treatment.^{2,3} Moreover, endodontic treatment in children requires their cooperation.^{4,5} The additional difficulty involved in diagnosing root resorption is a limiting condition for determining the actual working length and instrumentation.^{1,6,7}

Pastes used in the endodontic treatment of primary teeth should ideally have antimicrobial properties, be radiopaque and biocompatible, and resorb in a time interval similar to that taken for root resorption to occur.^{8,9} Among the pastes used in the pulp therapy of primary teeth with pulp necrosis, zinc oxide and eugenol (ZOE) paste has been a reference in dentistry since 1930.^{9,10} ZOE paste has characteristics and properties of biocompatibility, radiopacity, and antimicrobial action.¹⁰⁻¹³ Endodontic treatment using ZOE paste has shown satisfactory clinical and radiographic results.^{1,6,7,14} The American Academy of Pediatric Dentistry's (AAPD) clinical practice guideline on the choice of pulpectomy obturation materials indicates that

ZOE is one of the preferred options for treating primary teeth with necrotic pulp.¹⁵ The endodontic technique using ZOE paste requires mechanical chemical preparation before filling root canals.^{1,6,7,15}

Other pastes have been studied, such as those containing antibiotics in their composition, thus dispensing with root canal instrumentation (such as lesion sterilization and tissue repair [LSTR]).¹⁶⁻¹⁸ Among these, CTZ paste, composed of chloramphenicol, tetracycline, zinc oxide, and eugenol, represents an alternative for the treatment of primary molars with necrotic pulps.¹⁹ This paste has antimicrobial action against *Streptococcus aureus*, *Enterococcus faecalis*, *Pseudomonas aeruginosa*, *Bacillus subtilis*, and *Candida albicans*,¹¹ biocompatibility similar to that of calcium hydroxide,²⁰ and relevant clinical and radiographic success rates^{21,22} and does not promote changes in alveolar blood cells.²³ Additionally, the prevalence of enamel defects was lower in premolars whose predecessors with pulp necrosis were treated with CTZ paste than those extracted.²⁴

There is no consensus in the literature on endodontic techniques and filling paste for primary teeth with pulp necrosis.¹⁵ The purpose of this controlled and randomized clinical trial was to compare the effectiveness of lesion sterilization and tissue repair (LSTR) antibiotic paste comprised of chloramphenicol, tetracycline, and zinc oxide and eugenol (CTZ) versus zinc oxide eugenol (ZOE) pulpectomy in the treatment of primary molars with pulp necrosis.

Methods

Ethics. This study was approved by the Research Ethics Committee at Federal University of Piauí and conducted following the principles of the Declaration of Helsinki. The parents/guardians and their children who agreed to participate in the study provided informed consent.

¹Dr. J. Moura, ³Dr. Nogueira, and ⁴Dr. Castro are MSc students, Postgraduate Program in Dentistry; and Drs. ²M. Lima, ⁵C. Lima, ⁶M. Moura, and ⁷L. Moura are professors, Graduate Program in Dentistry and Postgraduate Program in Dentistry; all authors at the Federal University of Piauí, Teresina, Piauí, Brazil.
Correspond with Dr. L. Moura at mouraiso@uol.com.br

HOW TO CITE:

Moura J, Lima M, Nogueira N, et al. LSTR antibiotic paste versus zinc oxide and eugenol pulpectomy for the treatment of primary molars with pulp necrosis: A randomized controlled trial. *Pediatr Dent* 2021; 43(6):435-42.

Study model. The protocol followed the recommendations of the Consort Statement and was registered in the Brazilian Registry of Clinical Trials (no. RBR-8xt8wx) and in the International Clinical Trials Platform at *ClinicalTrials.gov* (NCT03650036). This was a randomized controlled clinical trial in which the clinical evaluator was blinded but the radiographic evaluator would be aware of the different radiographic appearances of the two types of endodontic treatment of primary molars with pulp necrosis using the CTZ and ZOE pastes. The primary outcome was clinical and radiographic success, while the secondary outcome was the procedure time required to perform the two techniques.

Sample. The sample calculation was performed using the OpenEpi 3.01 software (Andrew G. Dean and Kevin M. Sullivan, *www.OpenEpi.com*), in which the following criteria were used: success rates of 63 percent for ZOE¹³ and 93 percent for CTZ paste²¹; the ratio of exposed to unexposed teeth of one to one; test power of 80 percent; and significance level of 95 percent. The sample was defined as 36 teeth per group. To minimize possible losses, an increase of 20 percent was added and a final sample of 88 teeth (44 teeth per group) was obtained.

Inclusion criteria. The participants in the study were three- to eight-year-old boys and girls attending the Children's Dental Clinic at the Federal University of Piauí, Teresina, Piauí, Brazil. Children were included if they had mandibular primary molars diagnosed with pulp necrosis, root resorption equal to or less than one-third (with sufficient dental structure for absolute isolation with rubber dam), and adaptation of a stainless steel crown (SSC).^{25,26}

The clinical diagnosis of pulp necrosis was made based on a history of spontaneous pain and mobility incompatible with chronological age, possibly with the presence of sinus tract or swelling. In the radiographic diagnosis, the presence or absence of a radiolucent area in the furcation region was observed. For diagnosis of pulp necrosis, clinical examination was associated with radiographic examination. The radiographic examination was performed using positioners (Indusbello, Paraná, Brazil) and children's films (Carestream, São Paulo, Brazil) and developed using the conventional manual technique.

Exclusion criteria. The exclusion criteria used were: children with a history of allergic reaction to the components of the tested materials; those who had used antibiotics in the last three months; teeth with pulp canal obliteration or internal or external pathological root resorption visible in periapical radiographs; and coronal destruction that would prevent absolute isolation with a rubber dam and/or restoration with SSC. The inclusion and exclusion criteria were similar to those used by Pramila et al.¹

Randomization. Randomization was performed using Random Allocation 1.0 software (Mahmood Saghaei, Iran) according to the type of paste to be used.²⁷ Two groups were formed: a CTZ group and a ZOE group. Each tooth received a five-digit identification code generated by the program; these codes were placed in opaque, numbered, and sealed envelopes to ensure the randomization was concealed.

The children and their guardians did not know to which group they were allocated. The envelopes were opened in front of the patients by a dental assistant who was not connected with the study. The envelopes were opened before the procedures began to allow the appropriate instruments to be organized for each technique.

Interventions. The procedures were performed by two students in the Postgraduate Program in Dentistry at the Federal

University of Piauí (FUP), Teresina, Piauí, Brazil, who were trained and calibrated by a professor expert in the endodontic treatment of primary teeth. For both groups, the following protocol was adopted: initial clinical exam; radiography; local anesthesia by blocking the mandibular alveolar nerve with one percent lidocaine hydrochloride with a vasoconstrictor (DFL, Rio de Janeiro, Brazil); and absolute isolation with a rubber dam. Decayed dentin was removed using spoon-shaped dentin excavators and low-rotation spherical drills numbers four and six (Microdont, São Paulo) whenever necessary. The pulp chamber roof was removed with a high-speed sterile carbide bur number 330 (KG Sorensen, Cotia, Brazil), followed by irrigating the pulp chamber with two percent chlorhexidine solution (LT Rioquímica, São José do Rio Preto, Brazil) and drying it with cotton balls. After these steps, endodontic treatments were performed per the specific protocols indicated for each group, and both groups were treated in a single session.

CTZ group. In this group, the root canal entrances were located with a number five explorer probe tip (SS White, Rio de Janeiro), irrigation of the coronal chamber with two percent chlorhexidine solution (LT Rioquímica), and drying with sterile cotton balls. The components of the CTZ paste were micronized at the FUP Pharmacy School to reduce the size of the powder particles, guarantee the homogeneity of the mixture, and improve the properties of the paste.^{28,29} Then, the components of the CTZ paste powder were packed into 250 mg

Table 1. INITIAL CLINICAL AND RADIOGRAPHIC CONDITIONS IN THE GROUPS*

Clinical and radiographic conditions	CTZ	ZOE	Total	P-value†
	N (%)	N (%)	N (%)	
<i>Tooth</i>				
First molars	16 (36.4)	23 (52.3)	39 (44.3)	0.13
Second molars	28 (63.6)	21 (47.7)	49 (55.7)	
<i>Tooth mobility</i>				
Present	6 (13.6)	12 (27.3)	18 (20.5)	0.11
Absent	38 (86.4)	33 (72.7)	70 (79.5)	
<i>Sinus tract or swelling</i>				
Present	28 (63.6)	30 (68.2)	58 (65.9)	0.65
Absent	16 (36.4)	14 (31.8)	30 (34.1)	
<i>Root resorption</i>				
Absent	13 (29.5)	8 (18.1)	21 (23.9)	0.20
<1/3	22 (50.0)	20 (45.5)	42 (47.7)	
1/3	9 (20.5)	16 (36.4)	25 (28.4)	
<i>Radiolucent area in the root furcation region</i>				
Present	36 (81.8)	38 (86.4)	74 (84.1)	0.56
Absent	8 (18.2)	6 (13.6)	14 (15.9)	
<i>Involvement of the bone crypt of the permanent successor</i>				
Present	7 (15.9)	8 (18.2)	15 (17.0)	0.78
Absent	37 (84.1)	36 (81.8)	73 (83.0)	
Total	44 (100.0)	44 (100.0)	88 (100.0)	

* Abbreviations used in this table: CTZ=chloramphenicol, tetracycline, and zinc oxide and eugenol; ZOE=zinc oxide eugenol.

† Pearson's chi-square test.

capsules that contained 62.5 mg of chloramphenicol, 62.5 mg of tetracycline, and 125 mg of zinc oxide.²⁰

At the time of the procedure, the contents of the capsule containing the powder of the CTZ paste were dispensed onto a glass plate and manipulated with 0.1 mL of eugenol (Biodynamics, Ipirorã, Brazil) using a flexible metal spatula (SS White).

The CTZ paste was placed on the pulp chamber floor using a number five exploratory probe (SS White). Cotton balls were used to pressure the CTZ paste and removed after use. Next, a thin layer of gutta-percha (Dentsply, Rio de Janeiro) was placed on the CTZ paste using an amalgam condenser to physically isolate the paste from the glass ionomer restoration.

ZOE paste group. For the ZOE pulpectomy group, chemical-mechanical root canal debridement and disinfection were performed using a two percent chlorhexidine solution (LT Rioquímica) and K-files (sizes 15 to 25; Dentsply). The limit of manual instrumentation was one mm short of the radiographic apex.^{1,6}

The zinc oxide of the ZOE paste was packed into 250 mg capsules at FUP Pharmacy School, mixed with 0.1 mL of eugenol (Biodynamics) on a sterile glass plate, and manipulated

with a flexible metal spatula (SS White). The paste was inserted manually with K-files (sizes 15 to 25; Dentsply), respecting the limit of one mm short of the radiographic apex.^{1,6} The ZOE paste was physically protected with a thin layer of gutta-percha using a method similar to that described in the CTZ paste technique.

Restorations of both groups. The teeth of both groups were restored after the pulp therapy using high-viscosity glass ionomer cement (Gold Label 9R, GC, Tokyo, Japan). After the removal of the rubber dam, SSCs were cemented (Iso-Form, 3M ESPE, Minneapolis, Minn., USA) with glass ionomer cement (Ketac Cem Easy Mix, 3M ESPE). All procedures were done according to the manufacturer's specifications. Whenever necessary to adapt the SSC, proximal surfaces of the primary molars were reduced using a no. 69 L bur (Teezkavan Co., Tehran, Iran).²⁶ The time taken to perform the two techniques was recorded (Vollo, São Paulo, Brazil) and counted starting after absolute isolation with a rubber dam and ending after restoration of the tooth with GIC but before placement of the SSC.

Clinical evaluation. Patients were evaluated clinically and radiographically every three months for 12 months.¹³ Clinical evaluations were performed by a professor of pediatric dentistry experienced in clinical studies who did not participate in the study and did not know to which group the teeth belonged. The intraexaminer calibration was performed with 10 teeth of children who did not participate in the study, with an interval of two weeks between evaluations. The agreement was 100 percent (kappa equals 1.0). Clinical success was considered in the absence of sinus tract/swelling and/or exfoliation before six months.^{1,15}

Radiographic evaluation. Radiographic evaluations were performed by a professor of dental radiology who did not participate in the study. The periapical radiographs were placed in a Negatoscope (Ultra Slim Led Tomographic Bivolt Biotron Negatoscope, Santa Rita do Sapucaí, Brazil), fixed with transparent tape, and evaluated by the radiologist without including patient identifications. The intra-examiner calibration was performed with 10 radiographs and repeated after two weeks (kappa equals 0.9). The radiographic criteria for success included absence, decrease or disappearance of the initial radiolucent area, and no new radiolucency.¹⁵ Overall success was defined as only those teeth that showed both clinical and radiographic success simultaneously.

Statistical analysis. The data were tabulated and analyzed using SPSS 22.0 software for Windows, IBM Corp., Armonk, N.Y., USA). Descriptive analysis of the data was performed. To compare the CTZ and ZOE groups concerning clinical and radiographic parameters at different time intervals of assessment, Pearson's chi-square and Fisher's exact tests were performed. The Kolmogorov-Smirnov normality test was used to analyze the distribution of time taken to perform endodontic treatment and showed a non-normal distribution of data

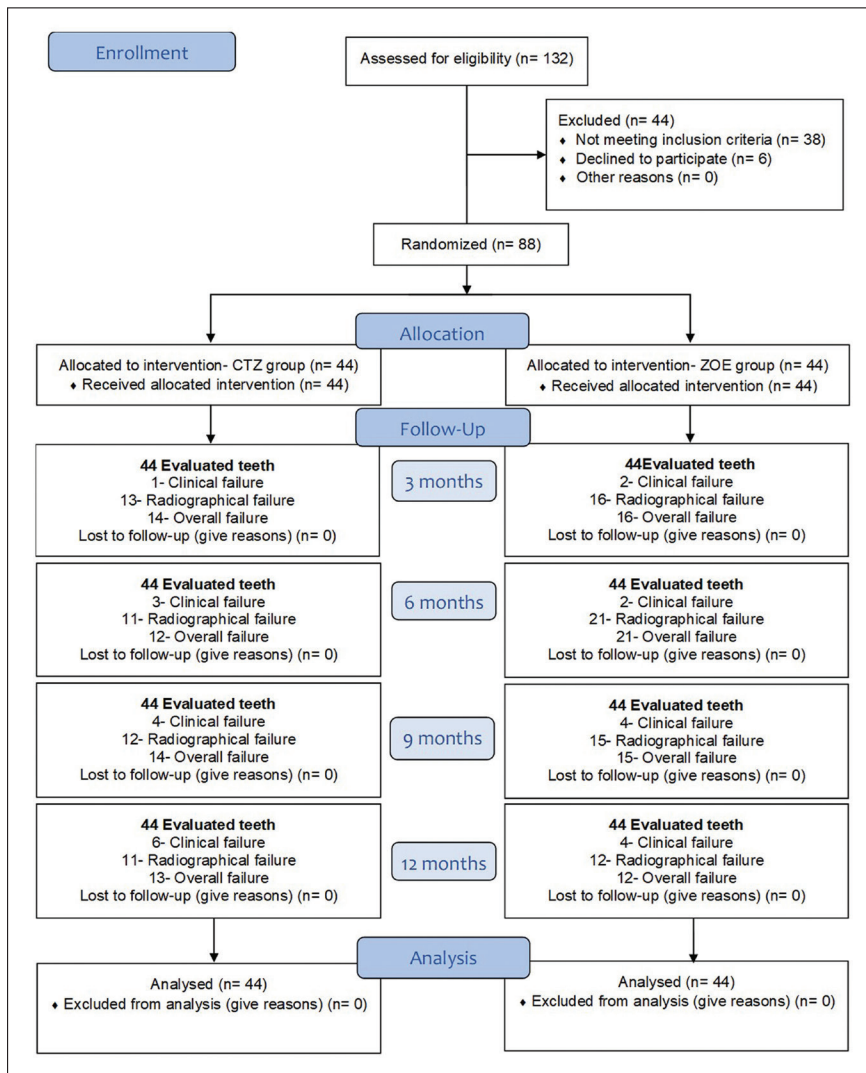


Figure 1. Flowchart.

($P < 0.05$). The Mann-Whitney U test was performed to assess the differences between groups concerning the time taken to perform the procedure. The level of significance was five percent ($P < 0.05$).

Results

Seventy children, with a mean age of 5.5 (± 1.2 standard deviation) years, participated in the study, including 35 males and 35 females. There was no difference between the groups concerning the initial clinical and radiographical conditions ($P > 0.05$; Table 1). A flowchart of this study is shown in Figure 1.

Clinical and radiographic evaluations and the overall success between groups at three-, six-, nine-, and 12-month time intervals are described in Table 2, (Figure 2). The CTZ group had significantly fewer radiolucent lesions that increased and/or stabilized at six months ($P = 0.03$) compared to ZOE,

but there was no significant difference at nine months ($P = 0.49$) and at 12 months ($P = 0.81$). Furthermore, at the six-month evaluation, the CTZ group (75.0 percent) presented a higher radiographic success rate than the ZOE group (52.3 percent; $P = 0.03$), but for the overall success there were no difference at the $P < 0.05$ level. At nine months, there was no difference in the radiographic success ($P = 0.49$) and the overall success ($P = 0.82$; Table 2).

At 12 months, the clinical success rate was 86.4 percent and 90.9 percent for the CTZ group and ZOE group, respectively ($P = 0.50$). The radiographic success rate of the CTZ paste was 75.0 percent versus 72.7 percent for ZOE ($P = 0.81$). The overall success rate of the CTZ paste was 70.5 percent compared to 72.7 percent for ZOE ($P = 0.81$; Table 2).

At the 12 month-evaluation, internal resorption was observed in three cases in the CTZ group and external inflammatory resorption was observed in one case in the CTZ group.

Table 2. CLINICAL AND RADIOGRAPHIC EVALUATION BETWEEN THE TWO GROUPS AT 3, 6, 9, AND 12 MONTHS*

Time	3 months			6 months			9 months			12 months		
	CTZ N=44	ZOE N=44	P-value	CTZ N=44	ZOE N=44	P-value	CTZ N=44	ZOE N=44	P-value	CTZ N=44	ZOE N=44	P-value
	N (%)	N (%)		N (%)	N (%)		N (%)	N (%)		N (%)	N (%)	
Clinical parameters												
<i>Fistula/abscess</i>												
Present	1 (2.3)	2 (4.5)	1.00**	2 (4.5)	2 (4.5)	1.00**	3 (6.8)	4 (9.1)	1.00**	5 (11.4)	4 (9.1)	1.00**
Absent	43 (97.7)	42 (95.5)		42 (95.5)	42 (95.5)		41 (93.2)	40 (90.9)		39 (88.6)	40 (90.9)	
<i>Exfoliation before 6 months</i>												
Yes	0 (0.0)	0 (0.0)		1 (2.3)	0 (0.0)	1.00**	1 (2.3)	0 (0.0)	1.00**	1 (2.3)	0 (0.0)	1.00**
No	44 (100.0)	44 (100.0)		43 (97.7)	44 (100.0)		43 (97.7)	44 (100.0)		43 (97.7)	44 (100.0)	
<i>Clinical success</i>												
Yes	43 (97.7)	42 (95.5)	1.00**	41 (93.2)	42 (95.5)	1.00**	40 (90.9)	40 (90.9)	1.00**	38 (86.4)	40 (90.9)	0.50†
No	1 (2.3)	2 (4.5)		3 (6.8)	2 (4.5)		4 (9.1)	4 (9.1)		6 (13.6)	4 (9.1)	
Radiographic parameters												
<i>Radiolucent lesion</i>												
Present	31 (70.5)	34 (77.3)	0.47†	23 (52.3)	29 (65.9)	0.20†	17 (38.6)	21 (47.7)	0.39†	14 (31.8)	19 (43.2)	0.27†
Absent	13 (29.5)	10 (22.7)		21 (47.7)	15 (34.1)		27 (61.4)	23 (52.3)		30 (68.2)	25 (56.8)	
<i>Radiolucent area</i>												
Decreased	18 (40.9)	18 (40.9)	0.50†	12 (27.3)	8 (18.2)	0.03†	5 (11.4)	6 (13.6)	0.49†	3 (6.8)	7 (15.9)	0.81†
Increased	3 (6.8)	3 (6.8)		4 (9.1)	1 (2.3)		6 (13.6)	0 (0.0)		3 (6.8)	2 (4.5)	
Stabilized	10 (22.7)	13 (29.5)		7 (15.9)	20 (45.5)		6 (13.6)	15 (34.1)		8 (18.2)	10 (22.7)	
Disappeared	5 (11.4)	4 (9.1)		13 (29.5)	9 (20.5)		19 (43.2)	17 (38.6)		22 (50.0)	19 (43.2)	
Absent	8 (18.2)	6 (13.6)		8 (18.2)	6 (13.6)		8 (18.2)	6 (13.6)		8 (18.2)	6 (13.6)	
<i>Radiographic success</i>												
Yes	31 (70.5)	28 (63.6)	0.50†	33 (75.0)	23 (52.3)	0.03†	32 (72.7)	29 (65.9)	0.49†	33 (75.0)	32 (72.7)	0.81†
No	13 (29.5)	16 (36.4)		11 (25.0)	21 (47.7)		12 (27.3)	15 (34.1)		11 (25.0)	12 (27.3)	
Overall success												
Yes	30 (68.2)	28 (63.6)	0.65†	32 (72.7)	23 (52.3)	0.05†	30 (68.2)	29 (65.9)	0.82†	31 (70.5)	32 (72.7)	0.81†
No	14 (31.8)	16 (36.4)		12 (27.3)	21 (47.7)		14 (31.8)	15 (34.1)		13 (29.5)	12 (27.3)	

* Abbreviations used in this table: CTZ=chloramphenicol, tetracycline, and zinc oxide and eugenol; ZOE=zinc oxide eugenol.

** Fisher's exact test. † Pearson chi-square test. **Bolded values** are statistically significant.

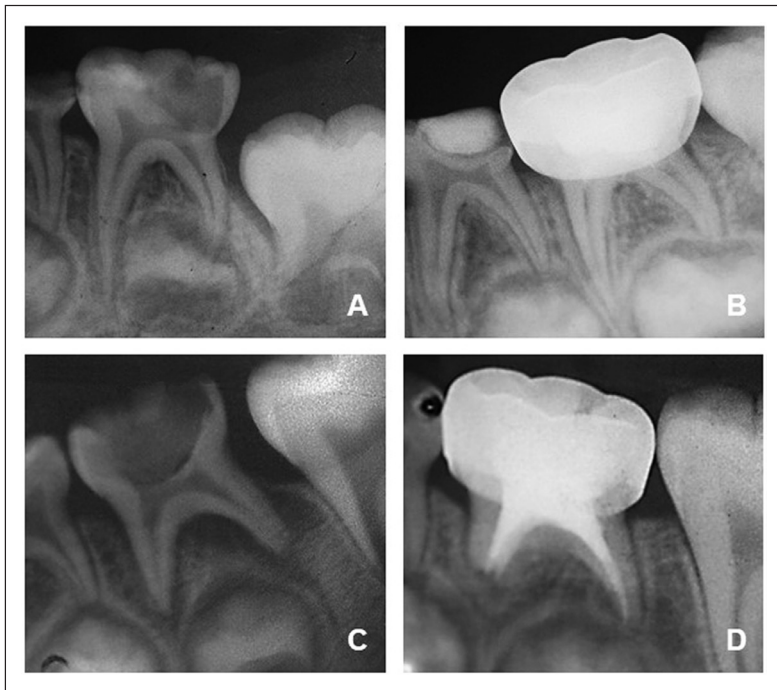


Figure 2. CTZ and ZOE folder: initial conditions and 12 months controls. CTZ paste: (A) initial condition (B) radiographic evaluation 12 months. ZOE Paste: (C) Initial condition; (D) Radiographic evaluation 12 months.

In the ZOE group, a furcation lesion developed into a cyst in one tooth. During the pulpectomies in the ZOE group, 15 of 44 teeth had extrusion of the ZOE paste and none showed resorption of the paste at 12 months. There was no difference in clinical success ($P=0.60$), radiographic success ($P=0.72$), or overall success ($P=0.72$) compared to the rates of those teeth without extrusion in the ZOE group.

The mean time taken to perform the CTZ technique was 61.4 (± 20.5) minutes (median time equals 60.0 minutes; inter-quartile range equals 23.0); for the ZOE technique, the mean time was 145 (± 53.2) minutes (median time equals 146.5 minutes; interquartile range equals 70.0; $P < 0.001$).

Discussion

After 12 months of evaluation, the CTZ paste showed no significant difference in clinical, radiographic, or overall success versus the ZOE paste for the treatment of primary molars with necrotic pulps. In this study, the option of using ZOE paste as a standard for comparison with CTZ paste was taken because the former is one of the pastes most widely used in pediatric dentistry, in addition to being one of the pastes indicated by the AAPD.¹⁵

LSTR for nonvital pulp therapy is proposed for the treatment of irreversibly inflamed or necrotic primary teeth and consists of nonmechanical instrumentation of the root canals and the use of antibiotic pastes.^{15,30-32} The purpose of the antibiotics is to reduce the bacterial load in the pulp via a simpler technique than pulpectomy.³¹⁻³³ Some studies, including two systematic reviews, have concluded that the success rates for LSTR and pulpectomy are similar.^{17,31,34} Another study has concluded that, if the roots are intact, pulpectomy is preferred, but if the roots are resorbed LSTR is preferred.³⁴

According to the AAPD, LSTR should be chosen over pulpectomy in teeth with root resorption in order to retain teeth for up to 12 months, which would otherwise have to be extracted.¹⁵ Distinct protocols have been proposed for the LSTR technique. Considering the potential adverse effects of tetracycline in children, when doing LSTR, the AAPD recommends that clinicians should choose an alternate paste without tetracycline¹⁵; however, this affirmation lacks scientific evidence. This randomized controlled trial used LSTR therapy with CTZ paste. The diversity of antibiotics, proportions, and vehicles may interfere in the clinical and radiographic outcomes of LSTR.³²

In the absence of endodontic infection, the body's defenses act in the process of repairing the sequelae caused by pulp necrosis.^{33,35} To provide effective antimicrobial action, the CTZ paste must be placed at the root canal entrances and on the pulp chamber floor of primary molars, where periodontal pulp communications are present.^{16,36-38} It is important to note that endodontic infections are localized, the amount of CTZ paste used is small²¹, and no reports were found in the literature on the systemic diffusion of drugs used in the pulp therapy of primary molars.

In the present study, extrusion of ZOE paste to the periapical region was observed in approximately one-third of the cases; however, the paste extrusion did not interfere with the success of the treatment. The extrusion of ZOE paste to periapical regions can be caused by the presence of areas of root resorption not visible in diagnostic periapical radiographs.^{34,37} The use of an apical locator can assist in the accurate detection of areas of apical resorption, as has been shown in some studies^{15,39,40}; however, the authors did not use them in the present study because they are not included in protocols adopted in most clinical studies.^{1,6,16} At 12 months, the extruded ZOE paste had not been reabsorbed. Similar results have been reported in other studies.^{1,6} The delay or absence of resorption of ZOE paste occurs because the zinc particles are resistant to the process of phagocytosis.³⁷

At the 12-month evaluation, in one case in the ZOE group, the lesion in the furcation region developed into a root cyst. A similar condition was reported in another study in which the same paste was used.⁴¹ Internal resorption was observed in three cases in the CTZ group; this rare condition can be attributed to the body's response to chronic inflammatory conditions.^{33,42} A case of external inflammatory resorption was observed in the CTZ group, a pathological process in which the immune system induces the occurrence of resorption of the external surface of the tooth under the stimulus of infections, trauma, and orthodontic forces.⁴³ The occurrence of inflammatory root resorption can be attributed to the acceleration of the root resorption stage caused by the pulp therapy⁴⁴ or errors in diagnosis or execution of techniques.⁴⁵

Restorative failure can influence the performance of endodontic treatments,⁴⁶ especially in proximal occlusion lesions.⁴⁷ To minimize this bias in the present study, the restorative option used was an SSC, as it exhibits satisfactory marginal adaptation, requires a shorter operating time, and offers better cost-effectiveness.^{48,49} The steel crowns were cemented with glass ionomer cement because of its fluoride-releasing properties, adequate marginal sealing, and adhesion to both the steel crown and the tooth.^{50,51}

In this study, the mean clinical time spent on treatment in the CTZ group was twice as short as that spent in the ZOE group. A shorter clinical session is considered a differential in the quality of dental care for children.³³ However, the authors suggest that further studies should be conducted using rotary files and/or validated instruments capable of accurately assessing children's acceptance based on the time taken to perform the dental treatment.

The use of CTZ paste has the limitation of causing tooth discoloration in the primary molar due to the presence of tetracycline, but the technique is indicated only for posterior teeth, which do not participate in the smile. Studies have shown that alternate 3Mix pastes without tetracycline should be chosen over the traditional pastes with tetracycline.^{15,34} The presence of tetracycline in CTZ paste has provoked discussions, so further studies should be carried out, excluding tetracycline or replacing it with another antibiotic.

As a differential, the present clinical trial applied micronization of the powder components of CTZ paste to provide homogeneity between the two antibiotics (chloramphenicol and tetracycline) and zinc oxide and to optimize the pharmacological properties of the paste.^{28,29} A systematic review had indicated that LSTR should be used for situations in which the tooth will remain in the dental arch for less than 12 months, due to root resorption,³⁴ and in cases in which there is the presence of external root resorption and pulpectomy cannot be performed.³⁴

Studies relative to the simplification of endodontic techniques in pediatric dentistry should be encouraged, especially to reduce the time taken to perform the surgical steps. Most studies have recommended instrumentation of root canals without considering the child's ability to collaborate, despite researchers having recognized and reported that the anatomical peculiarities inherent in primary teeth made the technique more complex.^{1,6,7} Therefore, this study's authors believe it is important to contribute to science by presenting satisfactory results produced with a faster technique, without losing methodological/scientific rigor, while considering and preserving both the children's physical and emotional health.

For endodontic treatment alternatives to be accepted by the academic/scientific community, prejudices and dogmas that imprison and limit the thinking of many researchers must be overcome. Therefore, simplified techniques for the pulp therapy of primary teeth must be disseminated so that dentists are capable of performing them and preventing early loss of primary teeth that may cause malocclusions and have a negative impact on children's oral health-related quality of life.

Conclusions

Based on this study's results, the following conclusions can be made:

1. The LSTR procedure with CTZ paste needs less chair time than that for the ZOE pulpectomy.
2. Considering that at 12 months, there was no difference between two nonvital pulp treatments, LSTR technique with CTZ paste can be a treatment option for primary molars with pulp necrosis.

References

1. Pramila R, Muthu MS, Deepa G, Farzan JM, Rodrigues SJL. Pulpectomies in primary mandibular molars: A comparison of outcomes using three root filling materials. *Int Endod J* 2016;49(5):413-21.
2. Ozcan G, Sekerci AE, Cantekin K, Aydinbelge M, Dogan S. Evaluation of root canal morphology of human primary molars by using CBCT and comprehensive review of the literature. *Acta Odontol Scand* 2016;74(4):250-8.
3. Ariffin SM, Dalzell O, Hardiman R, Manton DJ, Parashos P, Rajan S. Root canal morphology of primary maxillary second molars: A micro-computed tomography analysis. *Eur Arch Paediatr Dent* 2020;21(4):519-25.
4. Jamali Z, Najafpour E, Aminabadi NA's, et al. Does the length of dental procedure influence children's behavior during and after treatment? A systematic review and critical appraisal. *J Dent Res Dent Clin Dent Prospects* 2018; 12(1):68-76.
5. Sivakumar P, Gurunathan D. Behavior of children toward various dental procedures. *Int J Clin Pediatr Dent* 2019; 12(5):379-84.
6. Chen X, Liu X, Zhong J. Clinical and radiographic evaluation of pulpectomy in primary teeth: A 18-months clinical randomized controlled trial. *Head Face Med* 2017; 13(1):12.
7. Smail-Faugeron V, Glenny AM, Courson F, Durieux P, Muller-Bolla M, FronChabouis H. Pulp treatment for extensive decay in primary teeth. *Cochrane Database Syst Rev* 2018;5(5):CD003220.
8. Rajasekharan S, Martens LC, Vandenbulcke J, Jacquet W, Bottenberg P, Cauwels RG. Efficacy of three different pulpotomy agents in primary molars: A randomized control trial. *Int Endod J* 2017;50(3):215-28.
9. Najjar RS, Alamoudi NM, El-Housseiny AA, Al Tuwirqi AA, Sabbagh HJ. A comparison of calcium hydroxide/iodoform paste and zinc oxide eugenol as root filling materials for pulpectomy in primary teeth: A systematic review and meta-analysis. *Clin Exp Dent Res* 2019;5(3): 294-310.
10. Navit S, Jaiswal N, Khan SA, et al. Antimicrobial efficacy of contemporary obturating materials used in primary teeth—An in-vitro study. *J Clin Diagn Res* 2016;10(9): ZC09-ZC12.
11. Amorim LDFG, Toledo OA, Estrela CRDA, Decurcio DDA, Estrela C. Antimicrobial analysis of different root canal filling pastes used in pediatric dentistry by two experimental methods. *Braz Dent J* 2006;17(4):317-22.
12. Pilownic KJ, Carvalho CN, Romano AR et al. Antibiofilm activity of five different endodontic filling materials used in primary teeth using confocal laser scanning microscopy. *Pediatr Dent* 2017;39(2):145-9.
13. Goel H, Mathur S, Sachdev V. Clinical and radiographic evaluation of four different zinc-oxide integrated root canal obturating materials used in primary teeth. *Pediatr Dent J* 2018;28(2):73-86.
14. Barcelos R, Santos MPA, Primo LG, Luiz RR, Maia LC. ZOE paste pulpectomies outcome in primary teeth: A systematic review. *J Clin Pediatr Dent* 2011;35(3):241-8.
15. Coll JA, Dhar V, Vargas K, Chen CY, Crystal YO. Use of non-vital pulp therapies in primary teeth. *Pediatr Dent* 2020;42(5):357-49.

16. Nakornchai S, Banditsing P, Visetratana N. Clinical evaluation of 3Mix and Vitapex as treatment options for pulpally involved primary molars *Int J Paediatr Dent* 2010;20(3):214-21.
17. Doneria D, Thakur S, Singhal P, Chauhan D. Comparative evaluation of clinical and radiological success of zinc oxide-ozonated oil, modified 3Mix-MP antibiotic paste, and Vitapex as treatment options in primary molars requiring pulpectomy: An *in vivo* study. *J Indian Soc Pedod Prev Dent* 2017;35(4):346-52.
18. Zacharczuk GA, Toscano MA, López GE, Ortolani AM. Evaluation of 3Mix-MP and pulpectomias in non-vital primary molars. *Acta Odontol Latinoam* 2019;32(1):22-8.
19. Cappiello J. Tratamentos pulpares em incisivos primários. [Pulp treatment in primary incisors]. *Rev Asoc Odontol Argent* 1967;52(4):139-45.
20. Lima CC, Conde Júnior AM, Rizzo MS, et al. Biocompatibility of root filling pastes used in primary teeth. *Int Endod J* 2015;48(5):405-16.
21. Moura LFAD, Lima MDM, Lima CCB, Machado JAAG, Moura MS, Carvalho PVC. Endodontic treatment of primary molars with antibiotic paste: A report of 38 cases. *J Clin Pediatr Dent* 2016;40(3):175-7.
22. Ferreira LJ, Jiménez AS, Medrano CLE, García TI, Álvarez AM. Clinical and radiographic evaluation of formocresol and chloramphenicol, tetracycline and zinc oxide-eugenol antibiotic paste in primary teeth pulpotomies: 24-month follow up. *J Clin Pediatr Dent* 2019;43(1):16-21.
23. Moura LFAD, Lima MDM, Lima CCB, et al. Cellular profile of primary molars with pulp necrosis after treatment with antibiotic paste. *Int J Exp Pathol* 2018;99(5):264-8.
24. Sousa HCS, Lima MDM, Lima CCB, Moura MS, Bandeira AVL, Deus Moura LFA. Prevalence of enamel defects in premolars whose predecessors were treated with extractions or antibiotic paste. *Prev Dent Saúde Oral* 2020;18(1):793-8.
25. Seraj B, Shahrabi M, Motahari P, et al. Microleakage of stainless steel crowns placed on intact and extensively destroyed primary first molars: An *in vitro* study. *Pediatr Dent* 2011;33(7):525-8.
26. Ebrahimi M, Sarraf SA, Afshari E. Success and behavior during atraumatic restorative treatment, the Hall technique, and the stainless steel crown technique for primary molar teeth. *Pediatr Dent* 2020;42(3):187-92.
27. Saghaei M. Random allocation software for parallel group randomized trials. *BMC Med Res Methodol* 2004;4:1-6.
28. Joshi J. A review on micronization techniques. *J Pharm Sci Technol* 2011;3(7):651-81.
29. Olusanmi D, Jayawickrama D, Bu D, et al. A control strategy for bioavailability enhancement by size reduction: Effect of micronization conditions on the bulk, surface, and blending characteristics of an active pharmaceutical ingredient. *P Technology* 2014;258:222-33.
30. Takushige T, Cruz EV, Asgor Moral A, et al. Endodontic treatment of primary teeth using a combination of antibacterial drugs. *Int Endod J* 2004;37(2):132-8.
31. Agarwal SR, Bendgude VD, Kakodkar P. Evaluation of success rate of lesion sterilization and tissue repair compared to Vitapex in pulpally involved primary teeth: A systematic review. *J Conserv Dent* 2019;22(6):510-15.
32. Duarte ML, Pires PM, Ferreira DM, et al. Is there evidence for the use of lesion sterilization and tissue repair therapy in the endodontic treatment of primary teeth? A systematic review and meta-analyses. *Clin Oral Investig* 2020;24(9):2959-72.
33. Sain S, Reshmi J, Anandaraj S, George S, Issac JS, John SA. Lesion sterilization and tissue repair-current concepts and practices. *Int J Clin Pediatr Dent* 2018;11(5):446-50.
34. Coll JA, Vargas K, Marghalani AA, et al. A systematic review and meta-analysis of nonvital pulp therapy for primary teeth. *Pediatr Dent* 2020;42(4):256-272.
35. Shahad ALS, Abdullah AM, Takushige T, Cruz EV, Asgor MA, Hoshino E. Endodontic treatment of primary teeth using a combination of antibacterial drugs. *Int J Endod* 2004;37(2):132-8.
36. Kumar VD. A scanning electron microscope study of prevalence of accessory canals on the pulpal floor of deciduous molars. *J Indian Soc Pedod Prev Dent* 2009;27(2):85-9.
37. Lugliè PF, Grabesu V, Spano G, Lumbau A. Accessory foramina in the furcation area of primary molars: A SEM investigation. *Eur J Paediatr Dent* 2012;13(4):329-32.
38. Sharma U, Gulati A, Gill N. An investigation of accessory canals in primary molars: An analytical study. *Int J Paediatr Dent* 2016;26:149-56.
39. Bhat KV, Shetty P, Anandakrishna L. A comparative evaluation of accuracy of new-generation electronic apex locator with conventional radiography to determine working length in primary teeth: An *in vivo* study. *Int J Clin Pediatr Dent* 2017;10:34-6.
40. de Alencar NA, Oriano MD, Bolan M, Cardoso M. Is there any difference in length measurement methods for pulpectomies in primary teeth? A double-blind, controlled clinical trial. *Int J Clin Pediatr Dent* 2019;29:712-9.
41. Sandhyarani B, Noorani H, Shivaprakash PK, Dayanand AH. Fate of pulpectomized deciduous teeth: Bilateral odontogenic cyst? *Contemp Clin Dent* 2016;7:243-5.
42. Trairatvorakul C, Detsomboonrat P. Success rates of a mixture of ciprofloxacin, metronidazole, and minocycline antibiotics used in the non-instrumentation endodontic treatment of mandibular primary molars with carious pulpal involvement. *Int J Paediatr Dent* 2012;22(3):217-27.
43. Ahangari Z, Nasser M, Mahdian M, Fedorowicz Z, Marchesan MA. Interventions for the management of external root resorption. *Cochrane Database Syst Rev* 2015;1:CD008003.
44. Nero-Vieira G. Resorption is the inflammatory process: Approach to the pathogenicity of periodontal tooth and resorption. *RCOE* 2005;10(5-6):545-56.
45. Vieira-Andrade RG, Drumond CL, Alves LP, Marques LS, Ramos-Jorge ML. Inflammatory root resorption in primary molars: Prevalence and associated factors. *Braz Oral Res* 2012;26(4):335-40.
46. Gillen BM, Looney SW, Gu LS, et al. Impact of the quality of coronal restoration versus the quality of root canal fillings on success of root canal treatment: A systematic review and meta-analysis. *J Endod* 2011;37(7):895-902.
47. Brustolin JP, Mariath AA, Ardenghi TM, Casagrande L. Survival and factors associated with failure of pulpectomies performed in primary teeth by dental students. *Braz Dent J* 2017;28(1):121-8.

48. Chisini LA, Collares K, Cademartori MG, et al. Restorations in primary teeth: A systematic review on survival and reasons for failures. *Int J Paediatr Dent* 2018;28(2): 123-39.
49. Taran PK, Kaya MS. A comparison of periodontal health in primary molars restored with prefabricated stainless steel and zirconia crowns. *Pediatr Dent* 2018;40(5): 334-39.
50. Memarpour M, Mesbahi M, Rezvani G, Rahimi M. Microleakage of adhesive and nonadhesive luting cements for stainless steel crowns. *Pediatr Dent* 2011;33(7):501-4.
51. Parisay I, Khazaei Y. Evaluation of retentive strength of four luting cements with stainless steel crowns in primary molars: An in vitro study. *J Dent Res* 2018;15(3):201-7.

OPEN ACCESS DISCLAIMER AND RIGHTS:

The American Academy of Pediatric Dentistry (AAPD) publishes and maintains select Open Access articles from the journal Pediatric Dentistry. These articles are available on the AAPD's website at: <https://www.aapd.org/publications/journals/open-access/>. They are intended for the personal, educational use of the reader. Requests for any additional use, distribution, and/or reproduction in any medium of any Open Access article should be submitted directly to the AAPD, who may within its sole discretion determine whether to permit a licensed use. In such case, the original work must be properly cited along with the following statement:

"This article is Copyright © 2021 of the American Academy of Pediatric Dentistry and reproduced with their permission. The statements and opinions contained in this article are solely those of the individual authors and do not necessarily represent the views of the American Academy of Pediatric Dentistry. The American Academy of Pediatric Dentistry does not endorse any specific organization, product, or services referenced in the article."