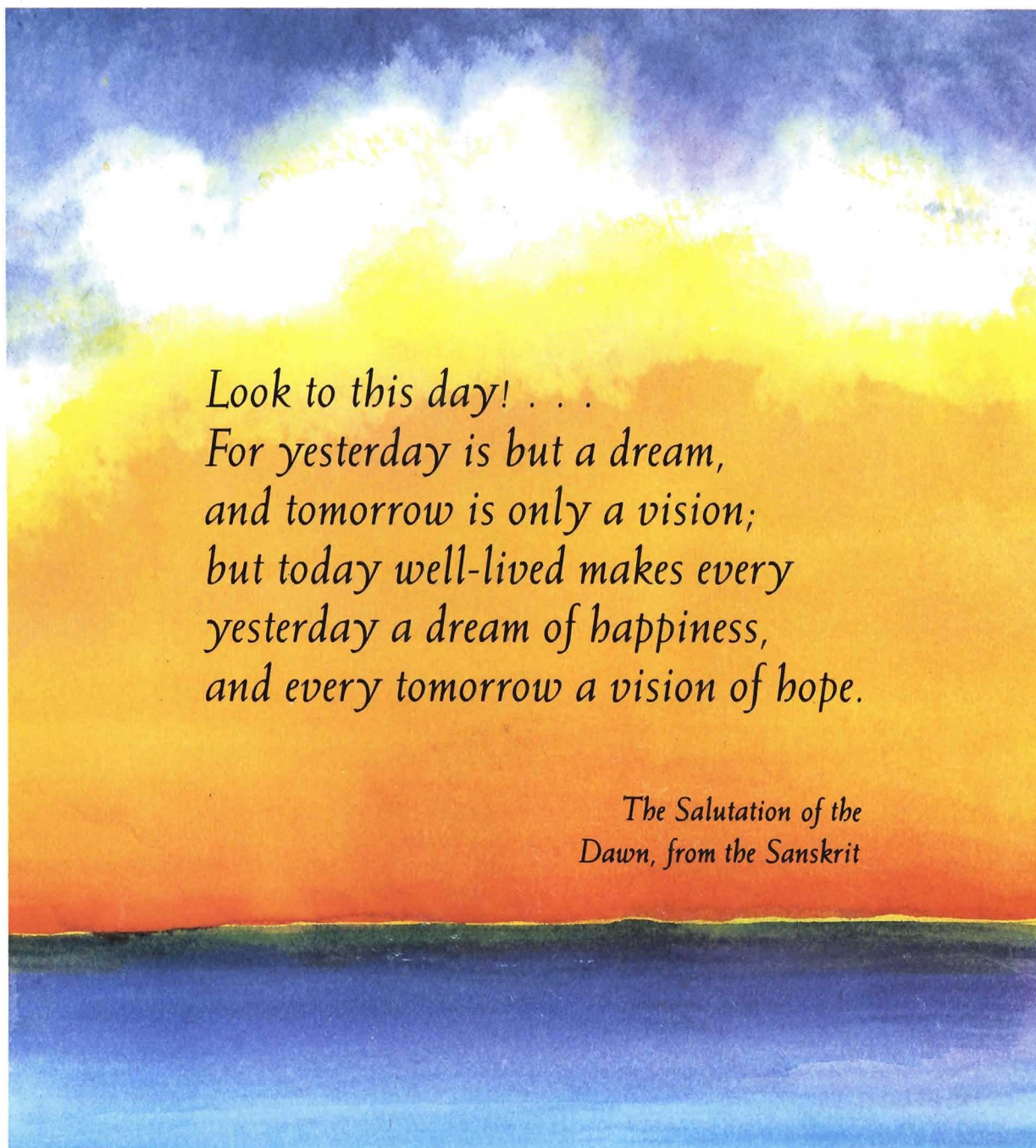


# ASDC

AMERICAN SOCIETY OF DENTISTRY FOR CHILDREN

NOVEMBER-DECEMBER 1987

## JOURNAL OF DENTISTRY FOR CHILDREN



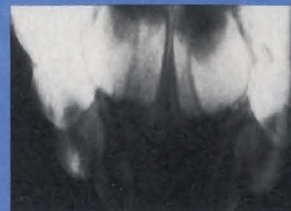*Look to this day! . . .  
For yesterday is but a dream,  
and tomorrow is only a vision;  
but today well-lived makes every  
yesterday a dream of happiness,  
and every tomorrow a vision of hope.*

*The Salutation of the  
Dawn, from the Sanskrit*

**OFTEN DO THE SPIRITS  
OF GREAT EVENTS STRIDE ON BEFORE THE EVENTS,  
AND IN TO-DAY ALREADY WALKS TO-MORROW.**

*—Samuel Taylor Coleridge*





## JOURNAL OF DENTISTRY FOR CHILDREN

Volume 54 Number 6 November-December 1987


Copyright 1987 by the American Society of Dentistry for Children—ASDC JOURNAL OF DENTISTRY FOR CHILDREN. USPS #279-480. Issued bimonthly—in January-February, March-April, May-June, July-August, September-October, and November-December—at 211 E. Chicago Avenue, Suite 1430, Chicago, IL, (312) 943-1244. Second class postage paid at Chicago, IL and additional mailing office. Subscription prices: within U.S.A., individuals \$60.00 per volume, institution \$80, single copies, \$15.00; Foreign (including Canada and Mexico) individuals \$70.00 per volume, institution \$90, single copies \$20.00. Thirty dollars and fifty cents (\$30.50) of the full membership dues are allocated to the Journal. Member—American Association of Dental Editors.

All copy and manuscripts for the journal should be sent directly to the Editorial Office, 730 Blaney Drive, Dyer, Indiana 46311, (219) 865-1184.

Prospective authors should consult "Information for Authors," which appears in the January and July issues. Reprints of this document may be obtained from the Editorial Office.

### POSTMASTER

Change of address, subscriptions, advertising and other business correspondence should be sent to Executive Secretary, 211 E. Chicago Ave., Suite 1430, Chicago, Illinois 60611.



It is very difficult, if not impossible, to predict with any degree of certainty what the future will bring. The way to secure the future is to do the best we can today.

Art and design by Sharlene Nowak-Stellmach.

- |                               |                                  |
|-------------------------------|----------------------------------|
| <b>394 Abstracts</b>          | <b>463 Index</b>                 |
| <b>388 Busy reader</b>        | <b>391 Index to advertisers</b>  |
| <b>390 Classified ads</b>     | <b>396 News</b>                  |
| <b>400 Editorial</b>          | <b>458 Table of Organization</b> |
| <b>397 Fellowship program</b> |                                  |

### CLINIC

#### 401 Traumatically injured primary incisors: a clinical and histological study

Theodore P. Croll, DDS; Elizeu A. Pascon, DDS, MSD; Kaare Langeland, DDS, PhD

*This study observed pulpal and periapical changes due to traumatic injuries to primary incisors, and to correlate those observations with clinical and radiographic findings.*

#### 423 A histological comparison of direct pulp capping agents in primary canines

Clara Turner, DMD; Frank J. Courts, DDS, PhD; Harold R. Stanley, DDS, MS

*This histological study evaluated and compared the results of applying three commercial calcium hydroxide preparations and a standard calcium hydroxide-saline paste to the dental pulp. Reactions of major interest were pulpal inflammation and formation of a dentinal bridge.*

#### 429 Biochemical study of whole saliva from children with chronic renal failure

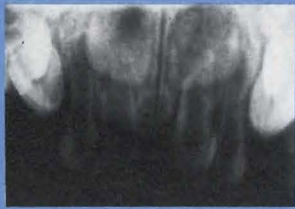Frédéric Obry, Dr Chir Dent; Alain B. Belcourt, Dr Sc; Robert M. Frank, Dr Chir Dent, Dr Med, Dr Sc Odont

*Children suffering from chronic renal failure show two interesting oral conditions. They have a high incidence of dental anomalies and a very low rate of caries activity.*

#### 433 The unpredictability of primary molar resorption following ectopic eruption of permanent molars

Sergio J. Weinberger, DDS, Cert pedo; Gerald Z. Wright, DDS, MSD, FRCD[c]

*This paper presents case histories showing the unpredictability of the resorptive process, which may occur to the roots of second primary molars and may continue until the teeth are prematurely lost.*

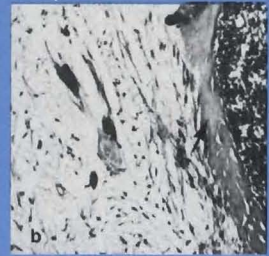


401

423



423



## BEHAVIOR

### 437 Comparison of chloral hydrate-hydroxyzine with and without meperidine for management of the difficult pediatric patient

John E. Nathan, DDS, MDS; M. Stewart West, PhD

*The need exists for controlled research to establish dosage guidelines for chloral hydrate combinations, particularly for management of the refractory child. Sedation was more successful when meperidine was added.*

## PRENATAL FLUORIDE

### 445 Optimum dosage for prenatal fluoride supplementation (PNF): Part IX

Frances B. Glenn, DDS; William Darby Glenn III, MD

*Because of the maternal loss of fluoride, the problem in pregnancy is to deliver sufficient fluoride to the fetal teeth.*

## SEALANTS

### 451 The use of dental sealants in the Washington State Medical Assistance Program: a one-year report

Robert C. Faine, DDS, MPH

*Every dental claim that included a sealant procedure was reviewed for a one-year period.*

## NUTRITION

### 454 Dietary cholesterol recommendations for children

Alvin M. Mauer, MD

*The rationale for recommending modifications of children's diets is the prevention of adult atherosclerosis.*

#### OFFICERS

Elliott J. Gordon . . . . . President  
Prem S. Sharma . . . . . President-elect  
Weldon W. Crompton . . . . . Vice-President  
Roland W. Hansen . . . . . Secretary-Treasurer  
George W. Teuscher . . . . . Executive Officer

#### EDITORIAL STAFF

George W. Teuscher . . . . . Editor-in-Chief  
Donald W. Kohn . . . . . Associate Editor  
Jane W. Teuscher . . . . . Assistant Editor  
730 Blaney Drive  
Dyer, Indiana 46311

#### EDITORIAL AND PUBLICATIONS COMMISSION

Thomas K. Barber  
Donald F. Bowers  
Irving W. Eichenbaum  
Donald W. Kohn  
Ralph E. McDonald  
John E. Nathan  
Jimmy R. Pinkham  
Prem S. Sharma  
Robert Spedding  
Paul P. Taylor

#### EXECUTIVE COUNCIL

Peter J. Fos  
Alfred C. Griffin  
Frank L. Herbert  
Robert B. James  
Donald W. Kohn  
Ralph E. Lassa  
William H. Lieberman  
James F. Rundle

#### EDITOR EMERITUS

Alfred E. Seyler

# For the busy reader

## **Traumatically injured primary incisors: a clinical and histological study—page 401**

In this study, 138 traumatized primary incisors were evaluated clinically and radiographically, with the following data recorded: exact or approximate time-interval of traumatic episode(s) and extraction, mobility, color change, sensitivity to percussion/palpation, swelling, sinus tract, caries, crown/root fracture, periodontal/periapical lesions, external/internal root resorption, mineralization, and obturation.

Requests for reprints should be directed to Dr. Theodore P. Croll, East Street and N. Main Street, Doylestown, PA 18901.

## **A histological comparison of direct pulp capping agents in primary canines—page 423.**

This study indicates that direct pulp capping of exposures in primary teeth is a viable procedure. Data indicated the calcium hydroxide-saline paste induced more inflammation and produced a greater zone of mummification than the three commercial preparations studied. The newer commercial agents produce minimal inflammation, satisfactory dentinal bridging, and preservation of most of the vital pulp tissue.

Requests for reprints should be directed to Dr. Clara Turner, JHMHC Box J-426, Gainesville, FL 32610.

## **Biochemical study of whole saliva from children with chronic renal failure—page 429.**

The saliva of the ten children with CRF in this study had a very altered composition compared to the normal control group. From the standpoint of cariology, these observations suggest that the massive amounts of urea in the saliva of the experimental group may lead to the release of free acids by plaque being inhibited upon saturation with ammonia.

Requests for reprints should be directed to Dr. R. M. Frank, Centre de Recherches Odontologiques, Unité Inserm U 157, Faculté de Chirurgie Dentaire, 4 Rue Kirschleger, 67085 Strasbourg, France.

## **The unpredictability of primary molar resorption following ectopic eruption of permanent molars—page 433.**

The authors recommend that in cases similar to the two reported here, dentists examine the radiographs carefully and follow each case closely. Parents should be advised to contact the dentist when their child loses a molar, as molar losses may be premature and can lead to orthodontic problems.

Requests for reprints should be directed to Dr. Sergio J. Weinberger, Division of Pediatric Dentistry, Faculty of Dentistry, Dental Sciences Bldg., The University of Western Ontario, London, Ontario, Canada N6A 5C1.

## **Comparison of chloral hydrate-hydroxyzine with and without meperidine for management of the difficult pediatric patient—page 437**

This study assessed the effectiveness of CH-H combination using the standard and higher doses in overcoming refractory behavior. The impact of adding low doses of oral meperidine was also assessed. Additionally, as nitrous oxide provides analgesia and offers the capacity for titration, data to compare the adjunctive benefit of nitrous oxide versus oral meperidine were considered useful.

Requests for reprints should be directed to Dr. John E. Nathan, 800 Enterprise Drive, Suite 101, Oak Brook, IL 60521.

## **Optimum dosage for prenatal fluoride supplementation (PNF): Part IX—page 445.**

As dental caries resistance improves with increasing amounts of the essential trace mineral fluoride, the definition of optimum fluoride supplementation is the most fluoride that can be ingested on a daily basis without causing fluorosis. The authors estimate the optimal daily fluoride supplement in pregnancy to be 4 mg/day. In fluoridated areas, a supplemental 2 mg tablet seems appropriate.

Requests for reprints should be directed to Dr. Frances B. Glenn, 7741 S.W. 62nd Avenue, South Miami, FL 33143.

**The use of dental sealants in the Washington State Medical Assistance Program: a one-year report—page 451.**

A one-year utilization-and-cost review was conducted of a Medical Assistance sealant program in Washington State. A total of 6,191 children received sealants, representing 17.3 percent of children in the state, aged six to fourteen, who made at least one visit to a dentist. An average of 3.16 teeth were sealed per child. There were 593 dentists who placed sealants during the study period.

Requests for reprints should be directed to Dr. Robert C. Faine, 7015 S.E. 32nd Street, Mercer Island, WA 98040.

**Dietary cholesterol recommendations for children—page 454**

Seven recommendations are provided to physicians and health professionals who work with children, concerning dietary cholesterol. These include: infant formulas, a varied diet for infants, early recognition of obesity and hypertension, counseling on maintenance of ideal body weight, pertinent family history for patients, screening for serum cholesterol measurements in high-risk individuals, and moderation in diet and in following dietary trends.

Reprints are not available.

# Traumatically injured primary incisors: a clinical and histological study

## Clinic

**Theodore P. Croll, DDS**  
**Elizeu A. Pascon, DDS, MSD**  
**Kaare Langeland, DDS, PhD**

**E**pidemiological studies in Denmark, Israel, Great Britain, the United States, and the Dominican Republic, reveal that up to a third of children younger than seven years of age sustain injury to the primary incisors.<sup>1-6</sup> It is estimated that between 300 and 400 children each year were treated at Children's Hospital of Philadelphia for traumatic injuries to primary incisors from 1976 to 1981.<sup>7</sup> Injuries include crown fracture, root fracture, tooth avulsion, and dental displacement of all types within the alveolus. All such injuries occur in any combination and may also be accompanied by various soft tissue injuries and trauma to other head and neck structures.

In the early 1900's, Turner described hypoplastic developmental defects of permanent incisors, resulting from injuries to the primary predecessors.<sup>8-10</sup> Since that time, numerous reports on dental trauma have considered etiology, histopathosis, and clinical manifestations of such abnormalities.<sup>11-47</sup>

---

Dr. Croll is in the private practice of pediatric dentistry, in Doylestown, PA; Clinical Assistant Professor, Department of Pediatric Dentistry, University of Pennsylvania School of Dental Medicine; Research Associate, Temple University School of Dentistry.

Dr. Pascon is Assistant Professor, Department of Endodontics, University of Connecticut School of Dental Medicine.

Dr. Langeland is Professor and Chairman, Department of Endodontics, University of Connecticut School of Dental Medicine.

This study was supported in part by USPHS Grant #5 R01DE-04096.

The most extensive studies of traumatic dental injuries have been performed and reported by Andreasen and his co-workers.<sup>1,28,29,32,35,37,39,44</sup> Their descriptions of abnormalities of permanent teeth resulting from injuries to the primary predecessors include: "white or yellow-brown discoloration of enamel; white or yellow-brown discoloration of enamel and horizontal enamel hypoplasia; crown dilaceration; odontoma-like malformation; root duplication; vestibular root angulation; lateral root angulation or dilaceration; partial or complete arrest of root formation; sequestration of entire tooth germ; and ectopic, premature, or delayed eruption or impaction".<sup>28,29,44</sup> Such dental pathological alterations have been reported to have a prevalence of 17 percent to 74 percent in children with history of injury to primary incisors.<sup>24,29,32,33,40,44</sup>

Using Vervet monkeys, Andreasen found that the immediate histological effect of injury by impact to the immature permanent tooth consists of "contusion and displacement of the reduced enamel epithelium and slight displacement of the hard dental tissue in relation to the cervical loop".<sup>35</sup> When injured primary teeth are left in position, further alterations occur, including changes in the reduced enamel epithelium, with formation of stratified squamous epithelium and concomitant changes in dentinal and enamel matrices.<sup>35</sup>

Extent of malformation of a permanent incisor, caused at the time of traumatic impact, varies greatly, depending on the developmental status of the permanent tooth, force of impact, and direction of the traumatic forces on the primary incisor(s).<sup>13,15,19,24,25-27,29,32,33,35,41,44,46,47</sup>

Even though it has been shown that a permanent tooth in the early stages of development is more at risk of developmental aberration from trauma than a more mature tooth, a developing permanent incisor that appears radiographically to have a fully formed crown can still suffer developmental alterations.<sup>19,24,27,29,33,44,46,47</sup> The intrusion of primary incisors by trauma against such permanent crowns can cause various types of enamel surface lesions and also result in radicular abnormalities.<sup>13,15,17,25-29,35</sup> It is suspected that the reduced enamel epithelium may be involved in late enamel maturation, and damage to those cells can cause superficial, clinically detectable defects to the form and color of enamel.<sup>29,33,35,44,46,47</sup>

Malformation of permanent teeth associated with pulp disintegration or endodontic treatment of primary teeth can occur.<sup>11,18,20-23,30,31,34,36,39,43</sup> As is generally true in tissue morbidity, cell injury in the dental pulp results in inflammatory changes of associated periradicular tissues, leading to osteitis, osteolysis, and potential damage to adjacent developing permanent teeth.<sup>48</sup> Such inflammatory changes may be severe

enough not only to disturb amelogenesis, but have been reported to abort the development of a permanent tooth.<sup>11,12,18,20-23,27-30,34,36,39,43,44</sup> Ectopic, premature, and delayed eruption have also been attributed to den-toalveolar inflammation, associated with degenerating pulp tissue of primary teeth; altered resorption patterns of primary teeth under such conditions have been observed.<sup>15,18,20,23-30,44</sup>

Color changes are known to occur from the deposition of blood pigment in dentinal tubules and from optical alterations associated with pulp space, soft tissue, and dentinal changes.<sup>25,26,38,40,45</sup> Dark grey discoloration, which occurs soon after injury and persists, is thought to portend rapid pulp disintegration with poor chances of healing; and brown-yellow changes are reported to result from chronic low-grade pulpal inflammation with radiographic evidence of pulp space calcification.<sup>17,25,26,38,40</sup> The latter phenomenon reportedly does not often jeopardize a developing succedaneous tooth.<sup>25,26,38,40</sup>

Dentists must rely on clinical and radiographic diagnostic findings to assess the pulpal status of an injured primary tooth, as a basis for appropriate treatment. Because histopathological changes can be only surmised from clinical observation, a means of correlating clinical and radiographic findings with the histological condition of the pulp would be desirable. The purpose of this study was to observe pulpal and periapical changes due to traumatic injuries to primary incisors, and to correlate those observations with the clinical and radiographic findings.

## MATERIAL AND METHODS

The material consisted of 138 primary incisors that had been exposed to trauma and extracted at various time-intervals after the injuries. The teeth were from children treated in a private pediatric dental practice and were extracted by the principal investigator.

All clinical data were recorded, including tooth-mobility; grey-black or yellow-brown discoloration; sensitivity to percussion; sensitivity to palpation; gingival swelling; presence of draining sinus tract, caries, and crown fracture.

Radiographic observations were recorded, including increased periodontal ligament space (PDL), periapical radiolucency, external/internal root resorption, pulp space calcification, and presence of endodontic filling material. Radiographic technique was standardized by using the "Elcan" Precision Radiographic Alignment Instrument.\*

Following extraction by forceps, the teeth were im-

\* Masal Orthodontics Inc., Bristol, PA.

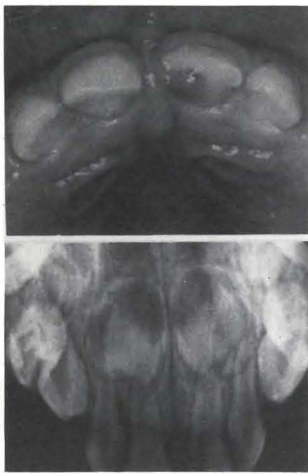

Figure 1. Clinical observations: S.H., eighteen-month-old girl struck tooth F on sidewalk. Tooth was mobile, sensitive to percussion and palpation, with Class III Ellis fracture. Clinical photo shows vertical crown fracture, and radiograph shows root fracture. The tooth was extracted two days after trauma.

mersed in 10 percent neutral buffered formalin, and sent to the histology laboratory. After fixation, the teeth were rinsed in tap water, demineralized in 22 percent formic acid/sodium citrate and processed for embedding in paraffin.

Semiserical sections were cut parallel to the long axis of the tooth at the 5  $\mu$ m setting of the microtome. Every third slide was stained with hematoxylin-eosin for general cellular recognition, and selected slides were stained in Masson trichrome for collagen, and Brown and Brenn for bacteria.

## OBSERVATIONS

The posttrauma interval in our 138 cases varied from two days to sixty-one months. In eighteen cases, despite clinical evidence of previous injury, the parents were unable to provide details of any trauma. Typical cases are demonstrated in chronological order, starting with the shortest interval. Variations in the extent of the injury, as related to the patient's age, are demonstrated within this sequence.

Two days earlier, a 1.5-year-old girl struck the maxillary left central incisor (F) in a fall. The blow resulted in a Class III Ellis fracture, radiographically confirmed as coronal and radicular. The tooth was sensitive to percussion and palpation and mobile (Figure 1). There was a dense concentration of neutrophilic leukocytes in the pulpal horn extending through the coronal third of the pulp. No inflammatory cells were present in the radicular pulp and none in the foraminal area (Figures 2,3).

Figure 3. Same case as shown in Figures 1 and 2: a, Radicular part, white area between predentin and pulp tissue, a shrinkage artifact (hematoxylin eosin, orig. mag. x 20); b, From central pulp tissue, nerve (n) and capillary (c) in non-inflamed tissue (hematoxylin eosin, orig. mag. x 1250); c, From central part, functioning capillaries with erythrocytes scattered or in rouleau in noninflamed tissue (hematoxylin eosin, orig. mag. x 1250); d, From apical part, vessel with one lymphocyte (ly) in uninflamed pulp tissue (hematoxylin eosin, orig. mag. x 1250). Despite necrosis at fracture site and adjacent severe acute inflammation there is vital, noninflamed tissue in the apical part of the canal.

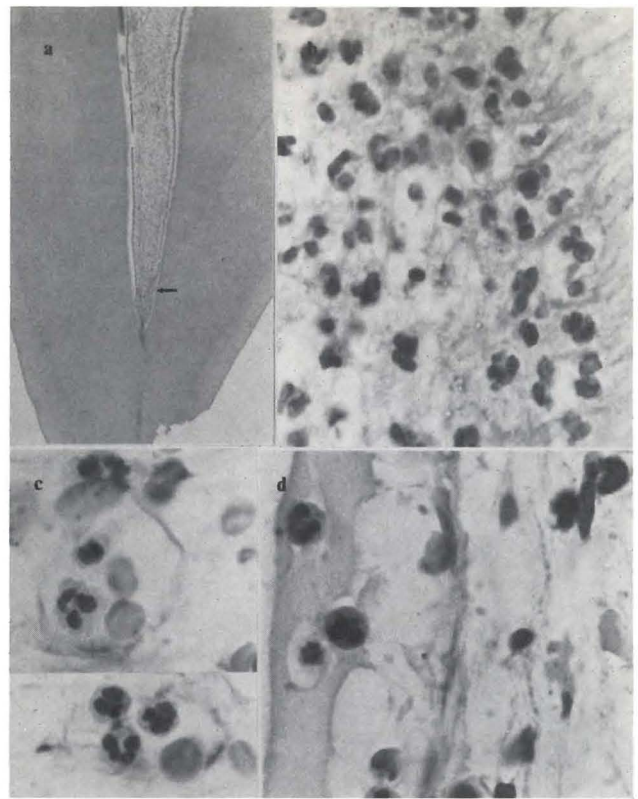
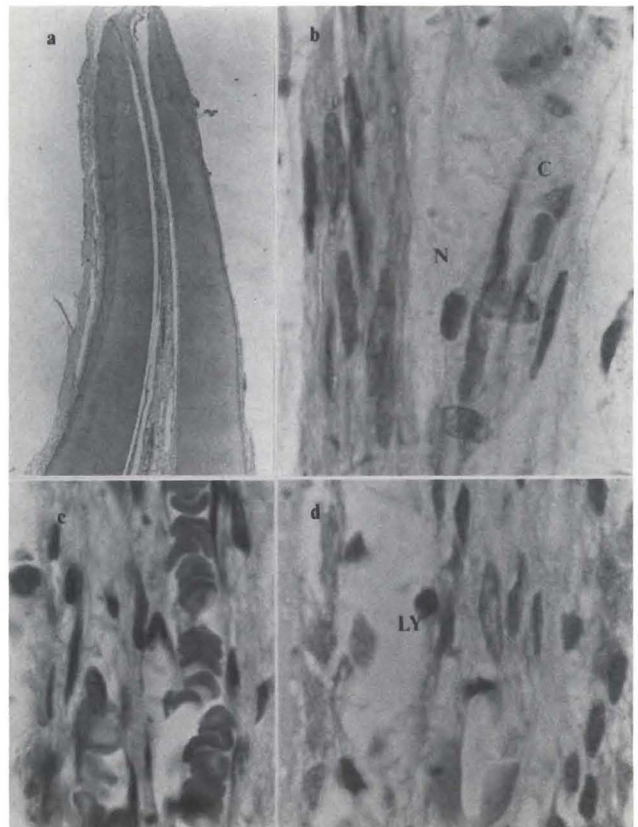
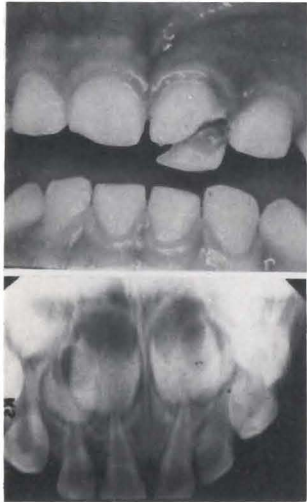


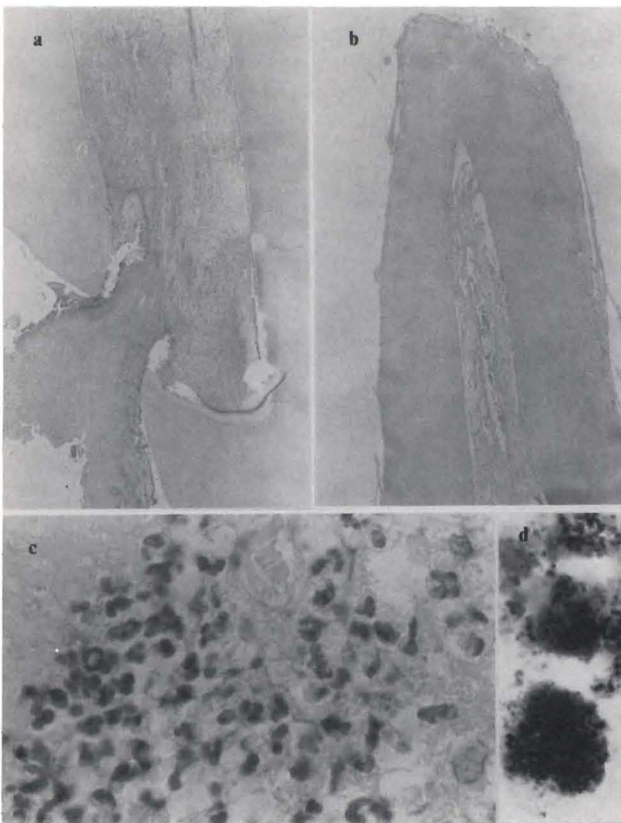
Figure 2. Coronal part of tooth F in Figure 1: a, Coronal pulp away from exposure with vital tissue (hematoxylin eosin, orig. mag. x 20); b, From pulp horn at arrow in a; no remaining odontoblast, only neutrophilic leukocytes along predentin and adjacent layer of Weil (hematoxylin eosin, orig. mag. x 1250); c, From central part of pulp horn, neutrophilic leukocytes in cross cut vessels (hematoxylin eosin, orig. mag. x 1250); d, From central part of pulp, neutrophilic leukocytes in and outside afferent vessel.







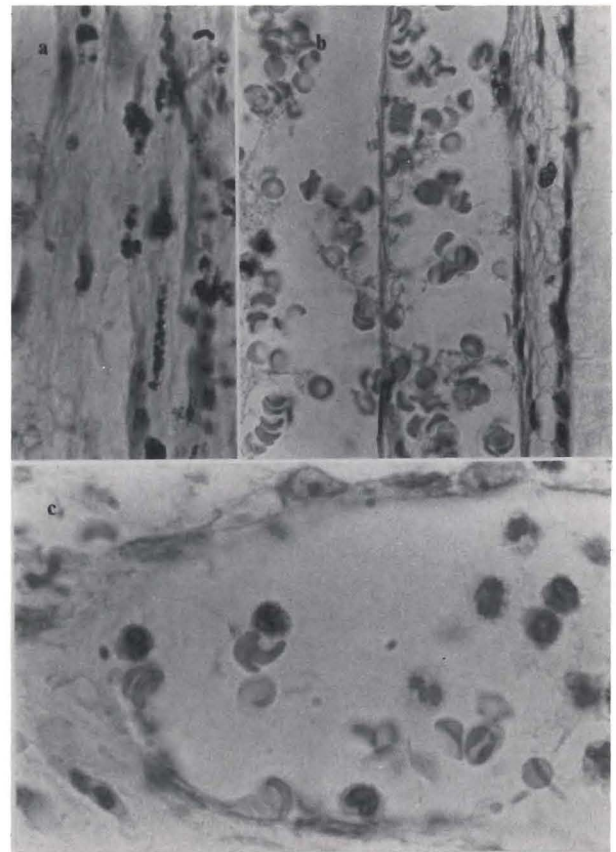
*Figure 4. Clinical observations: P.M., two-year, seven-month-old boy fell and struck tooth F, four days earlier. Patient in pain, tooth F was mobile, sensitive to percussion and palpation, with extensive Class III Ellis fracture. Clinical photograph and radiograph show crown fracture. The tooth was extracted four days after trauma.*



*Figure 5. Clinical history of case shown in Figure 4: a, Coronal part including fracture (hematoxylin eosin, orig. mag. x 20); b, Apical part not including foramen (hematoxylin eosin, orig. mag. x 20); c, Odontoblast layer destroyed by neutrophilic leukocytes (hematoxylin eosin, orig. mag. x 1000); d, Bacteria on pulp surface (Brown & Brenn, orig. mag. x 1250).*

Four days before treatment, a two-year, seven-month-old boy suffered a blow in which tooth F sustained a Class III Ellis midcoronal fracture (Figure 4).<sup>26</sup> There were bacteria on the wound surface and in the adjacent tissue. A dense concentration of neutrophilic leukocytes existed throughout the coronal pulp, extended into the root pulp, but tapered off with increasing distance from the fracture site. Circulatory disturbances were also present (Figures 5-7). In the root pulp, there were inflammatory cells scattered free in the tissue, and many of them in the afferent vessels. In the apical part, however, there were noninflamed tissue and noninvolved vessels (Figure 7).

Two cases were used to demonstrate variations in reactions, seven days after injury. The maxillary right central incisor (E) of a three-year-old boy sustained a Class II Ellis coronal fracture, and tooth E of a 4.5-year-old boy was traumatically displaced lingually without



*Figure 6. (Cont. of case shown in Figures 4, 5) a, Centrally in pulp, blood disintegration products (Brown & Brenn, orig. mag. x 1250); b, Blood disintegration in pulp vessels (hematoxylin eosin, orig. mag. x 700); c, Pulp vessel with neutrophilic leukocytes and monocytes (hematoxylin eosin, orig. mag. x 1250).*

exarticulation.<sup>26</sup> In the case with the Class II Ellis coronal fracture (Figure 8), liquefaction necrosis in the most coronal area and coagulation necrosis in the remaining coronal pulp chamber occurred.<sup>26</sup> In the root pulp, the tissue retained some fibrous structure, although areas of necrobiotic and necrotic tissue were present (Figure 9). In the periapical tissue, there was a dense concentration of neutrophilic leukocytes (Figure 10).

In the tooth E that had been displaced within its socket, an oblique root fracture was present. The most coronal extent of the fracture involved the periodontal pocket (Figure 11) where bacterial plaque and a dense concentration of neutrophilic leukocytes were observed.

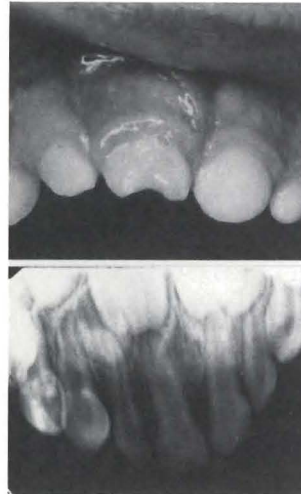

Figure 8. Clinical observations: R.P., three-year-old boy struck tooth E on a metal chair, a week earlier. Tooth E was mobile, grey-black, sensitive to percussion and palpation. Class II Ellis fracture and swollen labial gingiva as shown in the clinical photograph. Radicular fracture and periapical radiolucency seen on radiograph. The tooth was extracted seven days after injury.

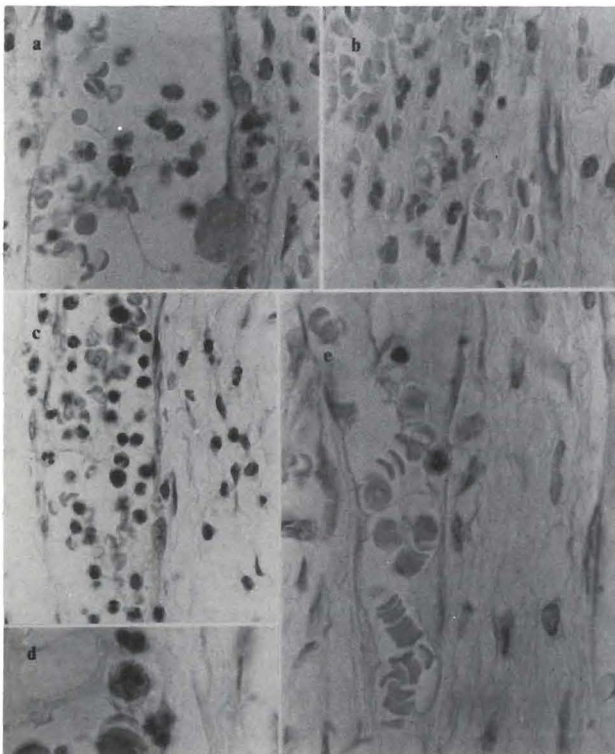


Figure 7. (Cont. of case in Figures 4-6). a, Vessel in root pulp with neutrophilic leukocytes and monocytes (hematoxylin eosin, orig. mag. x 700); b, Deeper in pulp, scattered neutrophilic leukocytes and extravasated erythrocytes (hematoxylin eosin, orig. mag. x 800); c, Afferent vessel in root pulp with neutrophilic leukocytes, monocytes and lymphocytes scattered outside vessel (hematoxylin eosin, orig. mag. x 700); d, Neutrophilic leukocytes and mast cell in vessel (hematoxylin eosin, orig. mag. x 1250); e, In apical third, vessel with healthy erythrocytes, one extravasated neutrophilic leukocyte and one lymphocyte in otherwise noninflamed root pulp (hematoxylin eosin, orig. mag. x 850).

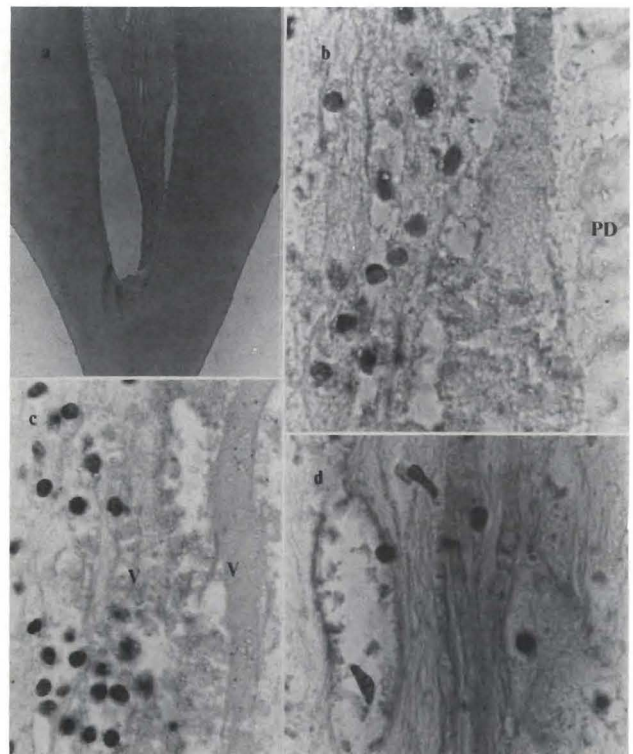


Figure 9. Coronal part of tooth E in Figure 8: a, coronal pulp away from exposure with necrotic and vital pulp tissue (hematoxylin eosin, orig. mag. x 20); b, From area of most coronal odontoblast layer, no remaining odontoblasts, lymphocytes in layer of Weil (pd - predentin, Brown & Brenn, orig. mag. x 1200); c, Destroyed odontoblast layer with lymphocytes in necrotic tissue with retained structure of vessels (v) (hematoxylin eosin, orig. mag. x 100); d, Farther apically in coronal part, no pulpal cells, only few inflammatory cells, but overall pulp structure better retained than in c, (hematoxylin eosin, orig. mag. x 1000).

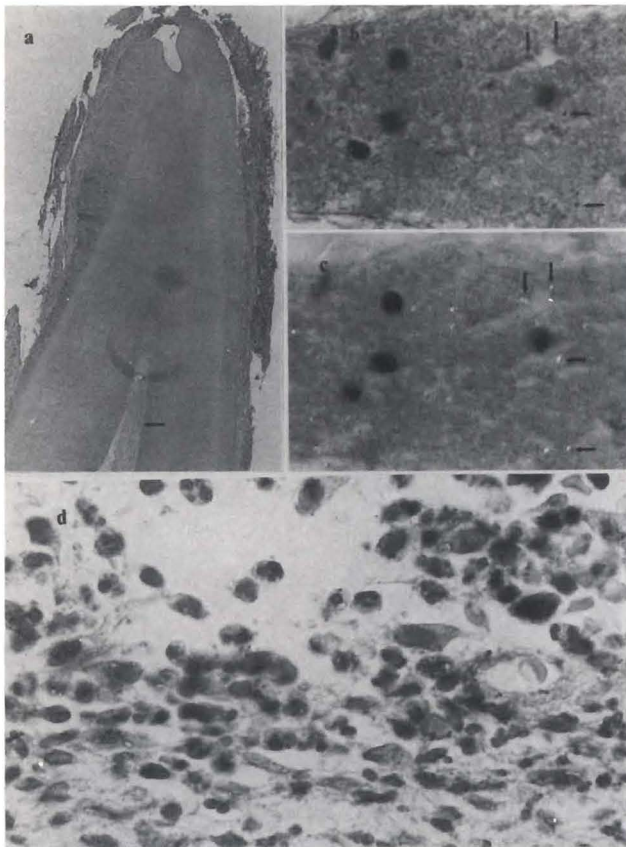


Figure 10. Apical part of tooth E in Figures 5 and 6. a, Apical root with structured pulp tissue in visible part of canal; empty foramina, and periapical tissue (hematoxylin eosin, orig. mag. x 20); b, From root canal, disintegrating pulp tissue with lymphocytes (ly), and blood disintegration products appearing as small black particles (arrows) in transmittent, diffuse light (hematoxylin eosin, orig. mag. x 1000); c, Exactly same area as in b. Particles appearing black in b, are birefringent (arrows) in transmittent polarized light (hematoxylin eosin, orig. mag. x 1000); d, From periapical lesion, large numbers of neutrophilic leukocytes (hematoxylin eosin, orig. mag. x 1000).

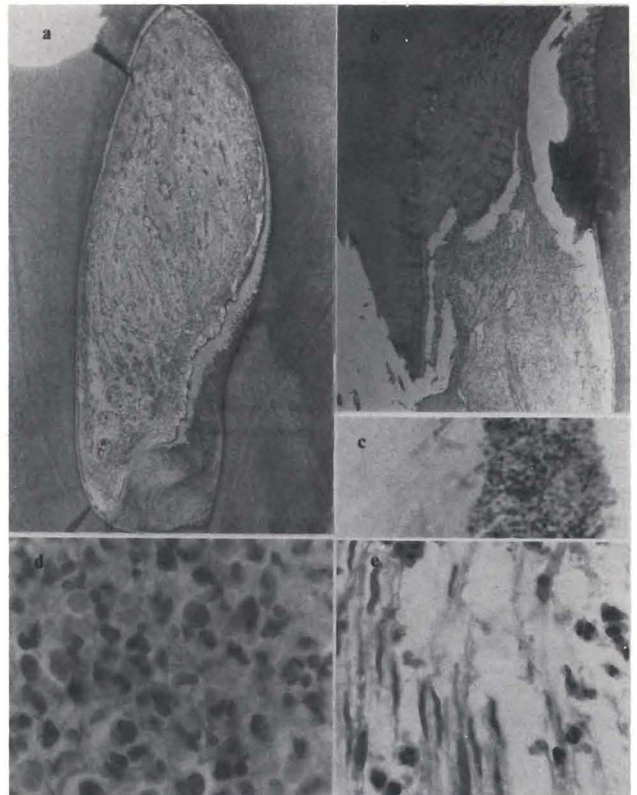


Figure 12. Coronal and apical parts of tooth E in Figure 11. a, Coronal part thick layer of irritation dentin. Well-structured pulp tissue with foci of inflammatory cells (hematoxylin eosin, orig. mag. x 20); b, Root part from fracture area. Irritation dentin on root canal wall, dense concentration of inflammatory cells in part of root pulp (hematoxylin eosin, orig. mag. x 20); c, From fracture area, bacterial plaque (Brown and Brenn, orig. mag. x 1250); d, Adjacent to fracture area, dense concentration of neutrophilic leukocytes (hematoxylin eosin, orig. mag. x 1000); e, Farther apically, structured pulp tissue with nerves and neutrophilic leukocytes. (hematoxylin eosin orig. mag. x 630).

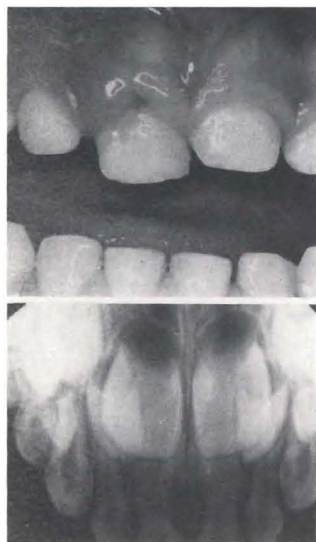


Figure 11. Clinical observations: J.W., 4.5-year-old girl struck tooth E on sidewalk. Tooth E was lingually displaced, mobile, normal color, sensitive to percussion and palpation, with swollen labial gingiva (Clinical photo). Oblique mid-root fracture seen in radiograph. The tooth was extracted seven days after trauma.

The pulp tissue in the coronal portion was well maintained. Circulatory disturbances were present in the root pulp, but the apical pulp tissue was not inflamed (Figures 12,13).

Two cases were used to demonstrate similar pulp reaction to substantially different traumata at the four-teen-day observation period. In one case involving tooth F of a sixteen-month-old boy, traumatic intrusion and coronal fracture occurred. The tooth was grey-black, and sensitive to percussion and palpation (Figures 14,15). In the other case, tooth F of a four-year, two-month-old girl, there were no remarkable clinical findings, except a periapical radiolucency (Figure 16). In the former case (Figure 14), there was coronal necrobiosis, but the structure of the pulp tissue was retained. In the apical part, there were vessels with disintegrating blood; bacteria; and inflammatory cells, including neutrophilic leukocytes in necrobiotic tissue (Figure 15).

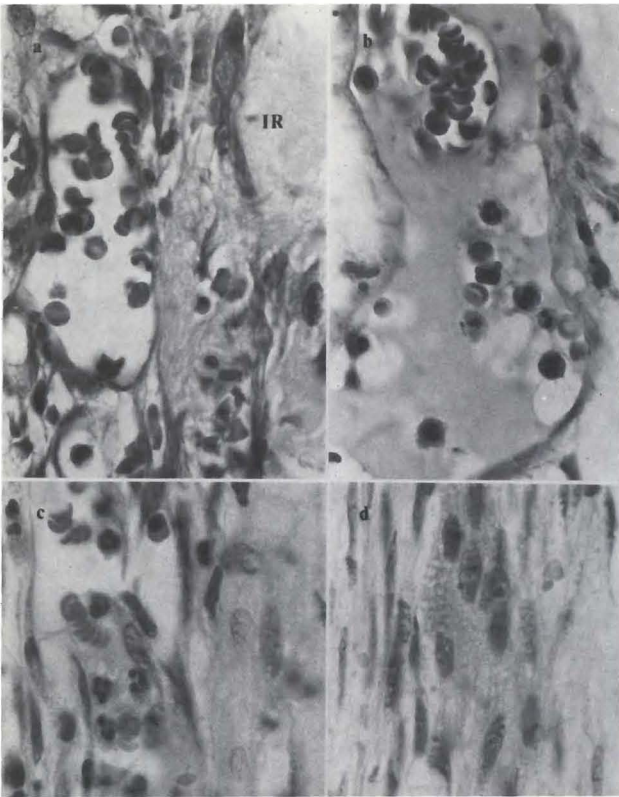


Figure 13. Same case as in Figures 11 and 12. a, Coronal part, irritation dentin (ir) with adjacent inflamed pulp (hematoxylin eosin orig. mag. x 8000); b, Coronal part, vessel with partly agglutinated blood, erythrocytes separate or in rouleau, and neutrophilic leukocytes (hematoxylin eosin orig. mag. x 1000); c, Apical root pulp with neutrophilic leukocytes in vessels. Less inflamed than coronally (hematoxylin eosin, orig. mag. x 1000); d, Apical root pulp; no inflammation (hematoxylin eosin, orig. mag. x 800).

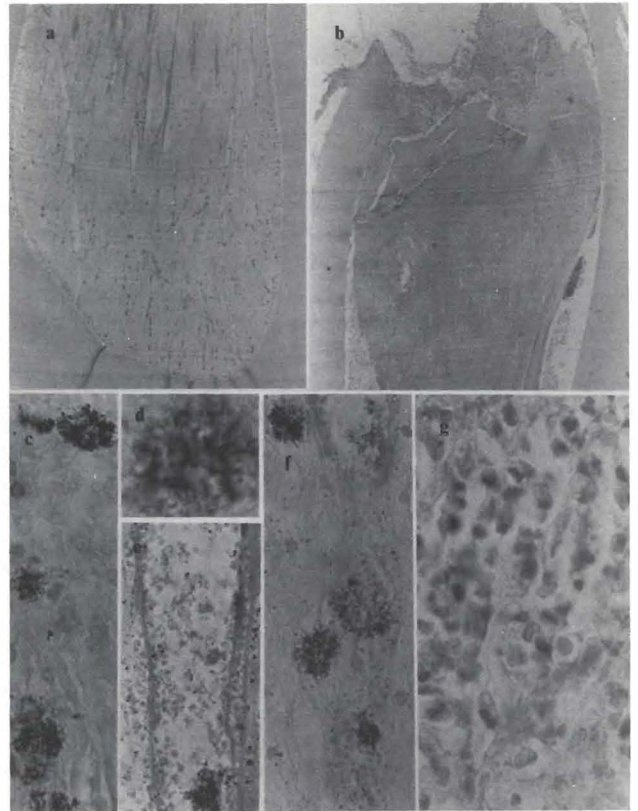


Figure 15. Coronal and apical parts of tooth F in Figure 14. a, Coronal part; necrobiosis, structured pulp tissue (hematoxylin eosin, orig. mag. x 20); b, Apical part with fragments of hard tissue in foraminal pulp (hematoxylin eosin, orig. mag. x 20); c, From pulp horn, disintegrated odontoblast layer with bacteria (hematoxylin eosin, orig. mag. x 800); d, Centrally in pulp, bacteria (Brown and Brenn), orig. mag. x 1250); e, Remaining structure of vessel with disintegrating blood and bacteria (hematoxylin eosin, orig. mag. x 800); f, Farther apically, vessel with disintegrating blood and bacteria (Brown and Brenn, orig. mag. x 500); g, Apical fragment, disintegrating inflammatory cells in necrobiotic pulp tissue (hematoxylin eosin, orig. mag. x 800).

Figure 14. Clinical observations: M.B., one-year, four-month-old boy intruded tooth F on unknown object. Tooth F was mobile, grey-black, sensitive to percussion and palpation. Class II Ellis fracture, gingival swelling, tooth intrusion, increased PDL space, and periapical radiolucency were present. The tooth was extracted fourteen days after trauma.

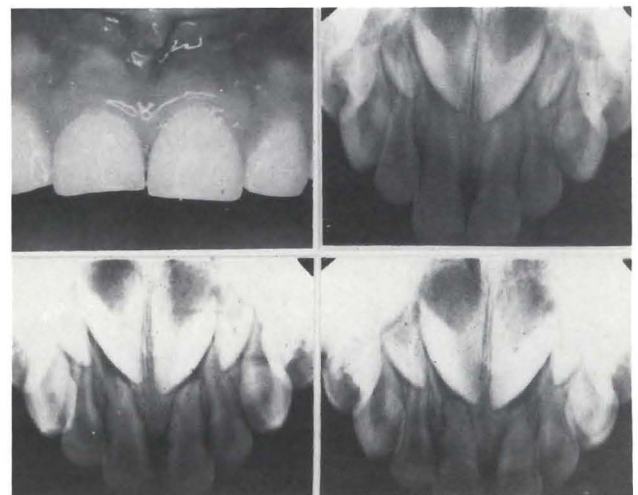
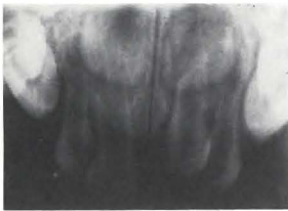

Figure 16. Clinical observations: M.L., four-year, two-month-old girl struck tooth F on swing. Tooth F was mobile, normal color, sensitive to percussion and palpation, with normal soft tissues as seen in the clinical photograph, increased PDL space, periapical radiolucency, and external root resorption were present. The tooth was extracted fourteen days after injury.

Figure 17. Coronal and apical tissue of tooth in Figure 16. a, Pulp horn with poorly staining tissue (hematoxylin eosin, orig. mag. x 70); b, From pulp horn, destroyed odontoblast layer and necrobiotic adjacent pulp tissue (hematoxylin eosin, orig. mag. x 1250); c, From foraminal area, necrobiotic, although still structured, pulp tissue with inflammatory cells having pyknotic nuclei (hematoxylin eosin, orig. mag. x 1250); d, From periapical area, reversal line indicating previous resorption, severe acute periapical inflammation (hematoxylin eosin, orig. mag. x 220).

In the other fourteen-day case (Figure 16), the coronal part of the pulp was necrotic and also had maintained its structure. In the apical part, inflammatory cells were present. In the periapical tissue, there was a dense concentration of inflammatory cells, particularly neutrophilic leukocytes (Figure 17). Bacteria were also present in the necrotic pulp tissue.

The case that had an eighteen-day observation period demonstrates the cumulative effect of two reported traumatic blows to one tooth. The two-year-old boy fell and struck tooth F on a cement walk. One week later he fell again, striking the same tooth, fracturing the crown (Figure 18). In the fracture area, pulpal necrosis and bacteria were observed. In the remaining part of the coronal pulp, there was structured, but necrotic/necrobiotic, pulp tissue. In the apical part of the root canal, there was a dense concentration of neutrophilic leukocytes and no structured pulp tissue. Similar conditions existed in the lateral canals in this area (Figures 19,20). The reactions demonstrated in these patients were typ-

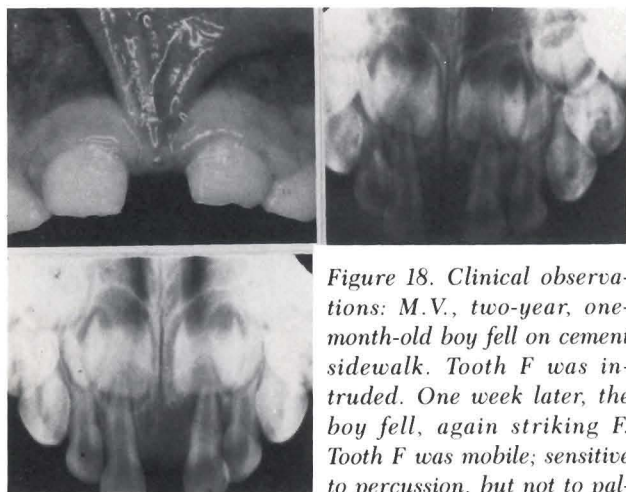
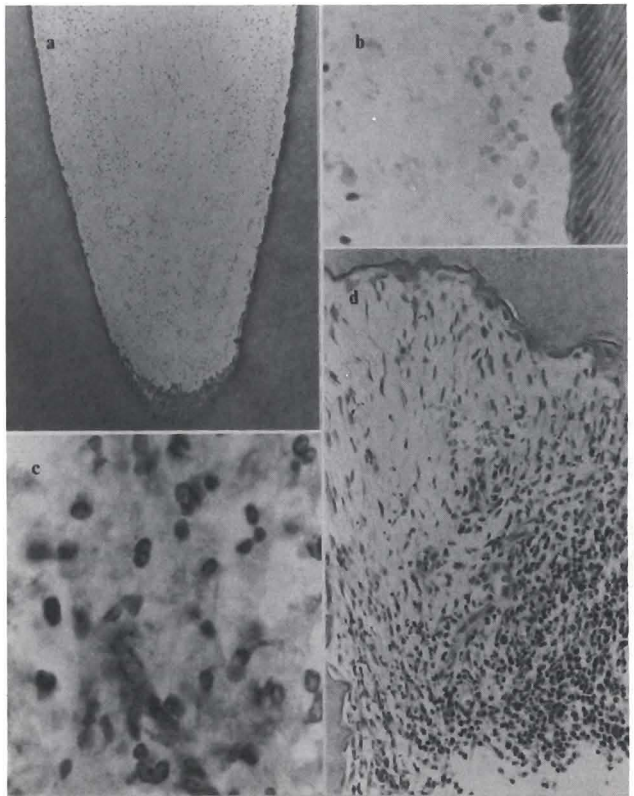


Figure 18. Clinical observations: M.V., two-year, one-month-old boy fell on cement sidewalk. Tooth F was intruded. One week later, the boy fell, again striking F. Tooth F was mobile; sensitive to percussion, but not to palpation; unchanged color; coronal fracture; and gingival swelling as seen in the clinical photograph. Increased PDL space and periapical radiolucency were also observed. The tooth was extracted eighteen days after original injuries.

ical of those occurring in the short to intermediate periods of this study.

Although there are no stages in biological reactions, we selected a four-month observation-period for the next demonstration. A thirty-two-month-old girl suffered a blow to her mandibular right central incisor (P). At the time of extraction the tooth was yellow-brown, mobile, and the swollen labial gingiva displayed a draining sinus tract. The radiograph showed a periapical radiolucency and external root resorption. The patient had no pain during this period, explaining why she was not presented for dental examination (Figure 21). The coronal and apical parts of the root canal had necrotic, necrobiotic, and some remaining vital pulp tissue. It should be especially noted that under these extreme pathological conditions, fragments of vital tissue remain (Figure 22).

The ten-month posttrauma case demonstrates a cumulative effect of trauma left untreated for four months; then treated with calcium hydroxide and retained *in situ* for another six months. There were no external soft tissue changes. The radiograph showed root resorption and pulp-space calcifications (Figure 23). In the histologic examination, pathological calcifications were confirmed along with necrotic tissue with bacteria (Figure 24). In the hard tissue formation (often er-

ected by trauma), the pulp space was filled with a dense, eosinophilic, amorphous material. This material was composed of calcium hydroxide and pulp tissue. The pulp space was filled with a dense, eosinophilic, amorphous material. This material was composed of calcium hydroxide and pulp tissue. The pulp space was filled with a dense, eosinophilic, amorphous material. This material was composed of calcium hydroxide and pulp tissue.

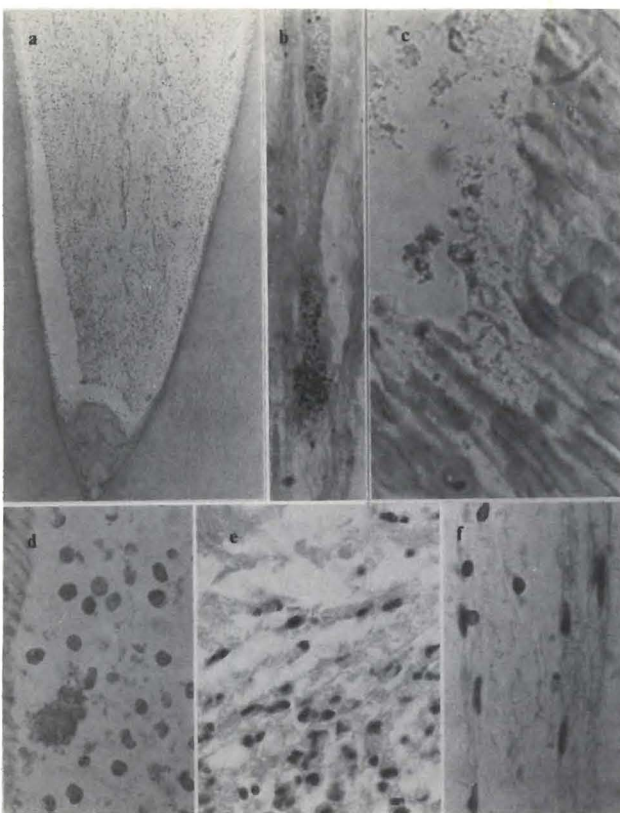


Figure 19. Coronal tissue of tooth F in Figure 18. a, Pulp horn with structured, necrobiotic pulp tissue (hematoxylin eosin, orig. mag. x 60); b, Coronal dentin with bacteria in crack (Brown and Brenn), orig. mag. x 1250); c, From pulp horn, bacteria in necrotic tissue (Brown and Brenn, orig. mag. 1250); d, Farther apically in coronal fragment, necrobiotic odontoblasts/layer with bacteria (hematoxylin eosin, orig. mag. x 500); e, Centrally in pulp, transition zone necrobiotic/inflamed area; inflammatory cells with pyknotic nuclei (hematoxylin eosin, orig. mag. x 700); f, Deeper in canal, partially retained pulp structure vessel with endothelial cells that have pyknotic nuclei (hematoxylin eosin, orig. mag. x 700).

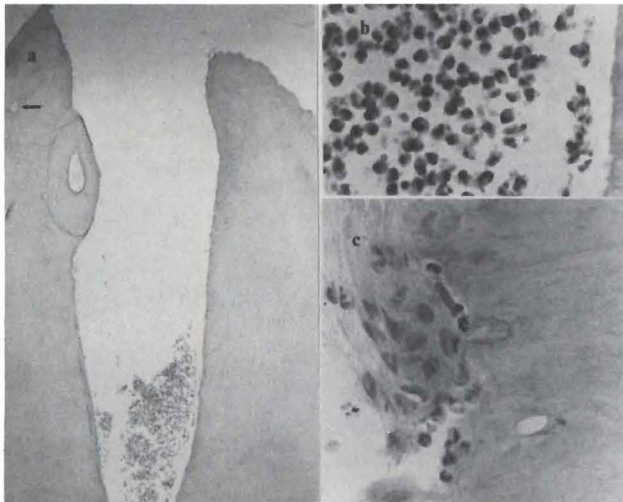
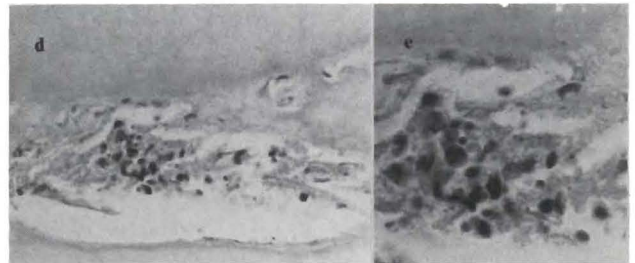


Figure 20. Foramen of tooth F in Figures 18 and 19. a, Root end with abscess (hematoxylin eosin, orig. mag. x 50); b, From



abscess in a; disintegrating neutrophilic leukocytes and chronic inflammatory cells (hematoxylin eosin, orig. mag. x 500); c, Resorption lacunae from apical part of canal, with neutrophilic leukocytes and osteoclasts (hematoxylin eosin, orig. mag. x 500); d, Lateral canal (arrow in a) with necrobiotic and inflamed tissue (hematoxylin eosin, orig. mag. x 500); e, From cell concentration in d, disintegrating neutrophilic leukocytes and chronic inflammatory cells (hematoxylin eosin, orig. mag. x 1000).

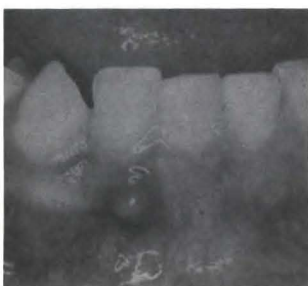
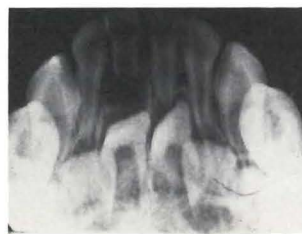
Figure 21. Findings: K.S., three-year-old girl, struck tooth P at thirty-three months. Tooth P was mobile, yellow-brown with no sensitivity to percussion or palpation. Labial gingival swelling (clinical photograph) with draining sinus tract are



shown. Increased PDL space, periapical radiolucency, external root resorption, and internal root resorption are seen in radiograph. The tooth was extracted four months after injury.

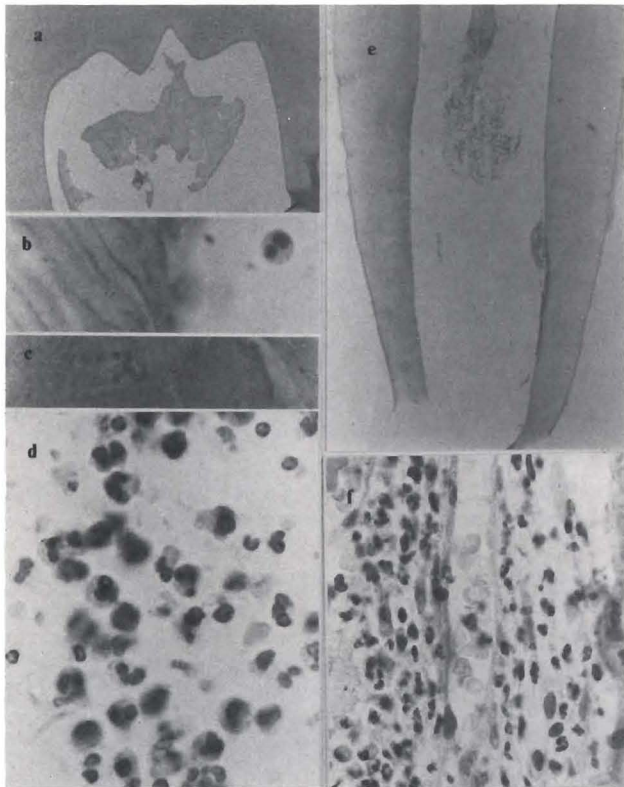


Figure 22. Coronal and apical sections of tooth F in Figure 21. a, Pulp horn with necrotic tissue (hematoxylin eosin, orig. mag. x 50); b, From pulp horn in a, dentin without predentin adjacent to pulp horn exposed to liquefaction necrosis. One neutrophilic leukocyte with pyknotic nucleus (hematoxylin eosin, orig. mag. x 1250); c, From unstructured tissue centrally in a necrotic tissue (hematoxylin eosin, orig. mag. x 1250); d, Farther apically, neutrophilic leukocytes and chronically inflamed cells of abscess (hematoxylin eosin, orig. mag. x 1250); e, Section from apical part with remaining pulp tissue (hematoxylin eosin, orig. mag. x 50); f, Remaining organized pulp tissue in apical root canal, vessel with functioning erythrocytes and neutrophilic leukocytes; and adjacent inflamed pulp tissue (hematoxylin eosin, orig. mag. x 650).

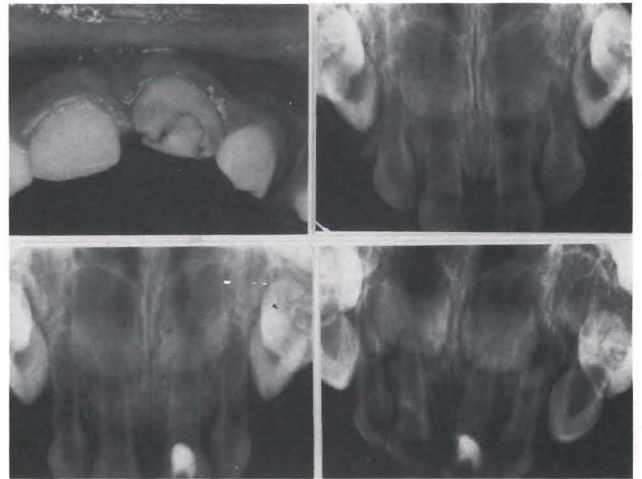


Figure 23. L.D., 1.5-year-old boy struck tooth F on coffee table at eight months of age. At ten months, F was treated with calcium hydroxide pulpotomy, zinc oxide and eugenol pulp canal restoration, and a bonded composite resin (clinical photograph). Tooth F was mobile, yellow-brown; percussion and palpation sensitivity were not recorded. There were no soft tissue changes. External root resorption, pulp space calcification, and endodontic filling material were seen on the radiograph. The tooth was extracted ten months after injury, eight months after endodontic treatment.

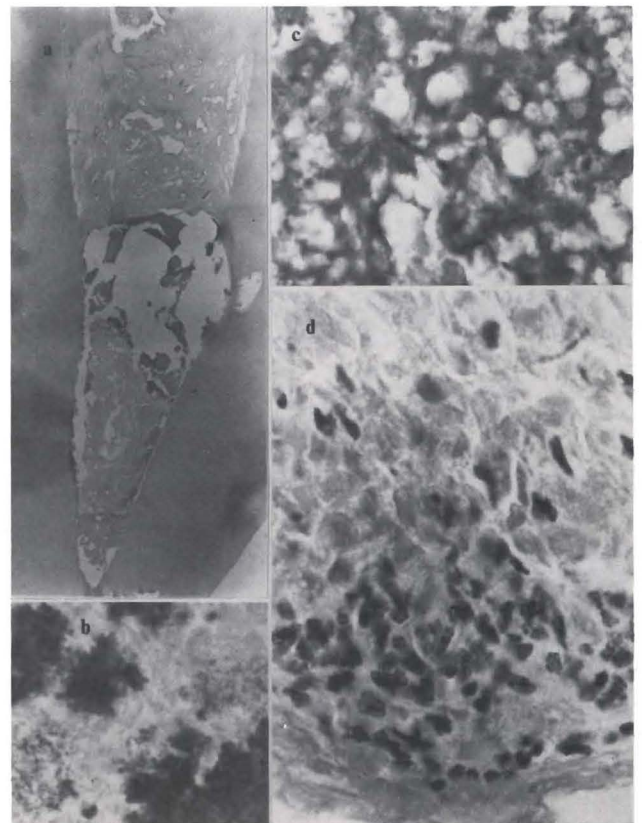


Figure 24. Coronal part of tooth F in Figure 23. a, Pulp horn with material, necrotic and necrobiotic tissue and a "bridge" (hematoxylin eosin, orig. mag. x 20); b, Pulp horn with necrotic tissue and bacteria (Brown and Brenn, orig. mag. x 1250); c, Pulp horn with necrotic tissue (hematoxylin eosin, orig. mag. x 1250); d, Next to bridge, coronal aspect, necrobiotic tissue with disintegrating neutrophilic leukocytes (hematoxylin eosin, orig. mag. x 1250).

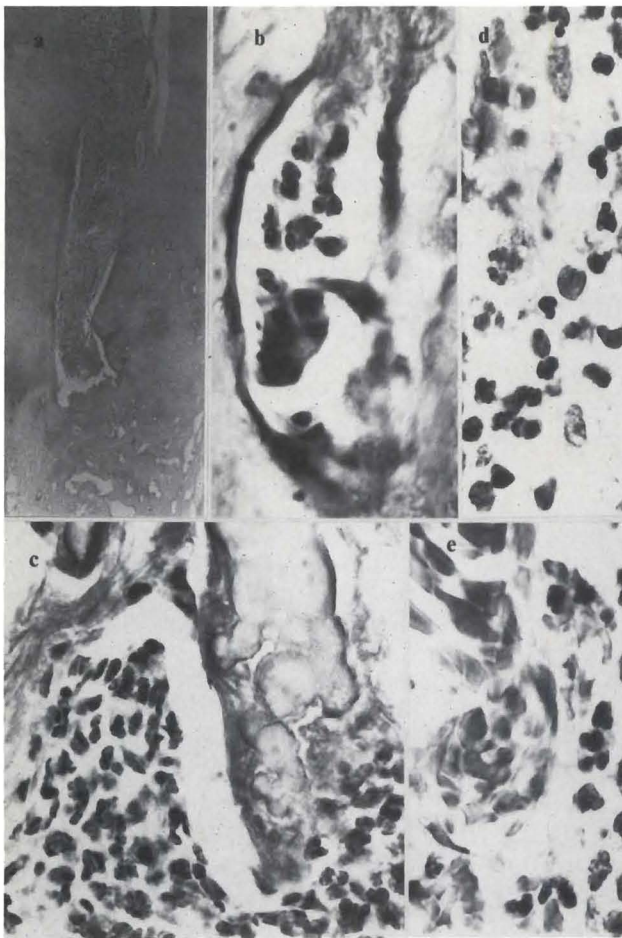


Figure 25. Same case as in Figure 23 and 24. a, Apical part of "bridge" (hematoxylin eosin, orig. mag. x 20); b, Inclusion in "bridge". Vessel with neutrophilic leukocytes (hematoxylin eosin, orig. mag. x 900); c, Apical side adjacent to "bridge"; calcification and severely inflamed pulp tissue (hematoxylin eosin, orig. mag. x 1000); d, Pulp tissue adjacent to c, severely inflamed with few remaining pulp fibroblasts (hematoxylin eosin, orig. mag. x 1000); e, Farther apically, functioning vessels with neutrophilic leukocytes (hematoxylin eosin, orig. mag. x 1000).

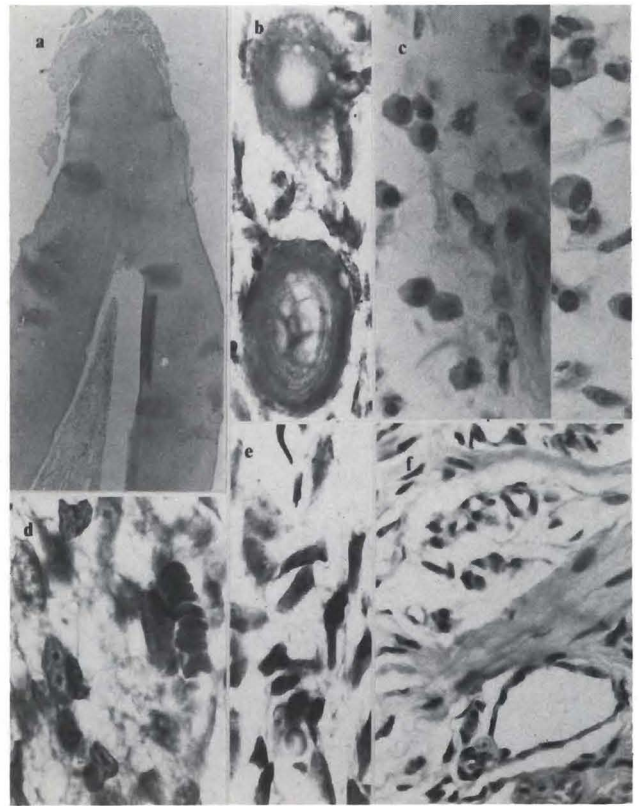

Figure 26. Same case as in Figure 23-25. a, Apical section with pulp tissue and periapical lesion (hematoxylin eosin, orig. mag. x 20); b, Apical pulp tissue with free calcifications (hematoxylin eosin, orig. mag. x 900); c, Apical tissue with primarily chronic inflamed cells (hematoxylin eosin, orig. mag. x 1000); d, Farther apically in canal, structured pulp tissue with functioning capillary (hematoxylin eosin, orig. mag. x 1000); e, Apical pulp tissue, fairly noninflamed with functioning vessel (hematoxylin eosin, orig. mag. x 900); f, Periapical lesion with mostly chronic inflammatory cells.

roneously termed "dentin bridge") there was inclusion of inflamed pulp tissue (Figure 25). In the apical part, there were free calcifications in the central pulp tissue and apposition on the canal walls. Undisturbed circulation and structured pulp tissue were present in the apical area. In the periapical lesion, primarily chronic inflammatory cells were present (Figure 26).

An example of variations in reactions, twelve months posttrauma in teeth E and F, following apparently equally traumatic injury to both, is presented. Both teeth were mobile, discolored, not sensitive to palpation, and free of soft tissue pathosis. Radiographically, both teeth had increased periodontal ligament space, periapical radiolucency, and external root resorption (Figure 27). Tooth E showed primarily well-structured,

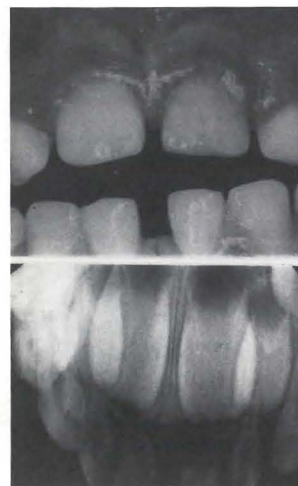


Figure 27. Findings: J.D., 4.5-year-old girl struck teeth E and F on concrete driveway at 3.5 years. Both teeth were mobile, and not sensitive to percussion or palpation, with no soft tissue changes (clinical photograph). tooth E was yellow-brown, and tooth F was of grey-black discoloration. Both teeth showed increased PDL space, periapical radiolucency, and external root resorption. The teeth were extracted twelve months after injury.



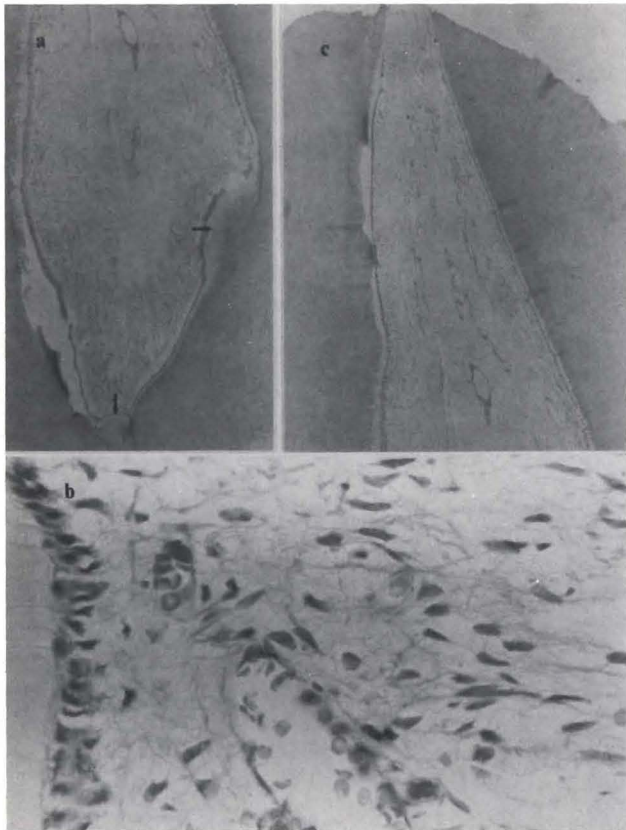


Figure 28. Coronal and apical section of tooth E in Figure 27. a, Coronal section. Irritation dentin (arrows), and histologic artifact (a) (hematoxylin eosin, orig. mag. x 20); b, From pulp horn. Healthy odontoblasts layer and the adjacent pulp with circulation (hematoxylin eosin, orig. mag. x 500); c, Apical section. Healthy pulp tissue (hematoxylin eosin, orig. mag. x 20).

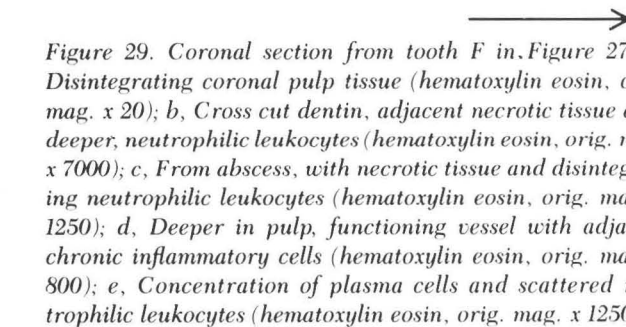


Figure 29. Coronal section from tooth F in Figure 27. a, Disintegrating coronal pulp tissue (hematoxylin eosin, orig. mag. x 20); b, Cross cut dentin, adjacent necrotic tissue and, deeper, neutrophilic leukocytes (hematoxylin eosin, orig. mag. x 7000); c, From abscess, with necrotic tissue and disintegrating neutrophilic leukocytes (hematoxylin eosin, orig. mag. x 1250); d, Deeper in pulp, functioning vessel with adjacent chronic inflammatory cells (hematoxylin eosin, orig. mag. x 800); e, Concentration of plasma cells and scattered neutrophilic leukocytes (hematoxylin eosin, orig. mag. x 1250).

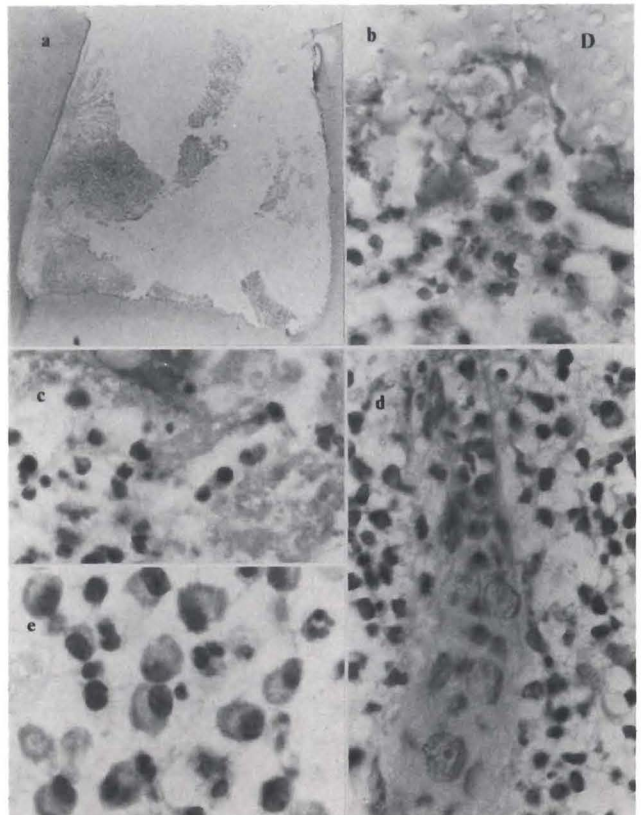
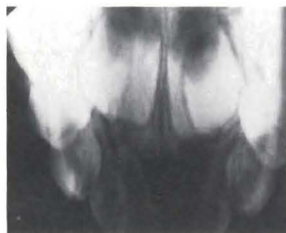


Figure 30. Findings: N.D., two-year, ten-month-old girl traumatized tooth E at fifteen months. Tooth E was mobile, grey-black; there was no sensitivity to percussion or palpation; gingival swelling and draining labial sinus tract were present (clinical photograph). Increased PDL space, radiolucency, and external root resorption were observed in radiograph. The tooth was extracted eighteen months after trauma.



noninflamed pulp tissue, with only a minor accumulation of chronic inflammatory cells apically (Figure 28); whereas tooth F showed necrotic pulp tissue all the way to the area of root resorption (Figure 29).

Eighteen months following dental trauma in a two-month-old girl, tooth E was grey-black, showed mobility, swelling, and a labial sinus tract. There was periapical radiolucency, an indication of root resorption and deformation (Figure 30). In the coronal area, there was mostly disintegrating pulp tissue, with some structured tissue remaining. In the apical area, a periapical lesion, evidence of external root resorption, and apposition appeared (Figure 31).

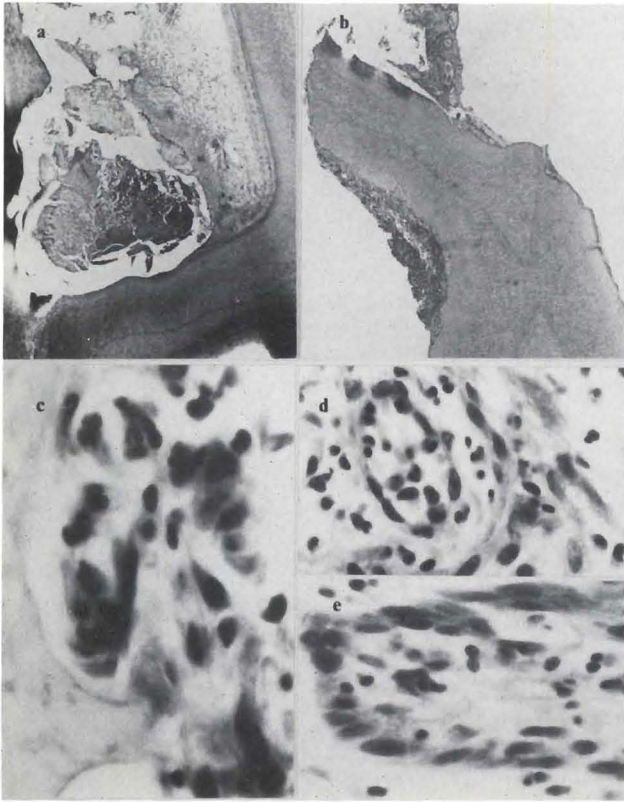


Figure 31. Sections from coronal and apical part of tooth E in Figure 30. a, Coronal pulp horn with disintegrating pulp tissue (hematoxylin eosin, orig. mag. x 20); b, Root tip with attached periapical lesion (hematoxylin eosin, orig. mag. x 20); c, From apical area of external resorption, osteoclast artificially removed from contact with lacunae wall and mixed inflammation (hematoxylin eosin, orig. mag. x 600); d, From area of periapical lesion, acute and chronic inflammatory cells (hematoxylin eosin, orig. mag. x 600); e, From other area of periapical lesion, epithelial and inflammatory cells (hematoxylin eosin, orig. mag. x 1000).

The following cases demonstrate long-term injury in our study. The first of these patients had two traumatic injuries to teeth E and F within thirty-six months: the last one, two weeks before extraction. Both teeth were yellow-brown. Tooth E was mobile, and sensitive to percussion and palpation. Tooth F was neither mobile nor sensitive. Both teeth showed, radiographically, the presence of pulp space calcifications (Figure 32). In tooth F, necrotic pulp tissue was present with bacteria in the coronal part; necrotic, but still structured pulp tissue in the apical part; and bacteria as far apically as the necrosis (Figures 33,34).

The pulp tissue in tooth F confirmed the radiographic

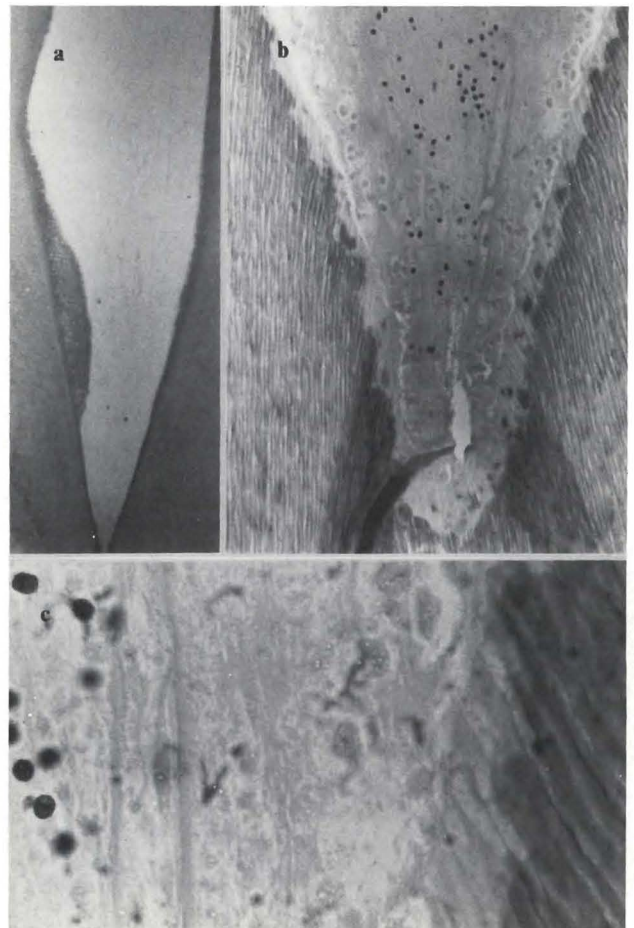


Figure 33. Section from coronal part of tooth E in Figure 32. a, Coronal pulp with disintegrating tissue and irritation dentin (hematoxylin eosin, orig. mag. x 20); b, Pulp horn with disintegrated odontoblast layer, cells with pyknotic nuclei, but some remaining structure (hematoxylin eosin, orig. mag. x 240); c, From pulp horn in b. Disintegrated odontoblast layer, remaining structure of vessel, pyknotic cell nuclei (hematoxylin eosin, orig. mag. x 900).

Figure 32. Findings: J.B., four-year, ten-month-old boy struck teeth E and F at one year and again at three years of age. Both teeth were yellow-brown, with Class II Ellis fractures (clinical photograph). Tooth E was mobile, sensitive to percussion and palpation. Tooth F was not mobile, and had no sensitivity to percussion or palpation. Radiographically, E showed crown fracture, periapical radiolucency, increased PDL space; and E and F both showed pulp-space calcification. The teeth were extracted three years after the first trauma, two weeks after the subsequent injury.

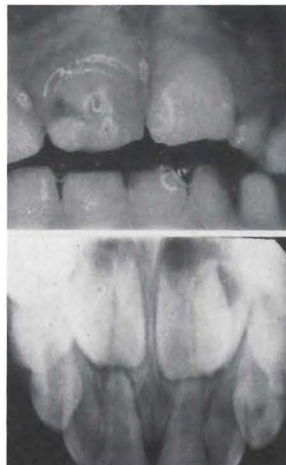
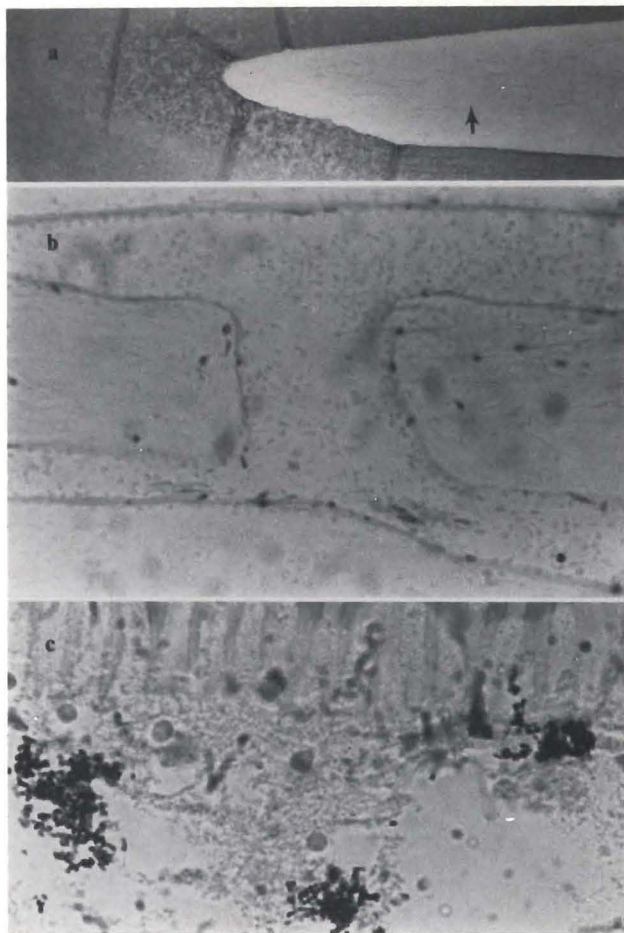


Figure 34. Sections from apical part of tooth E in Figures 32 and 33. a, Apical part of canal with remaining structured pulp tissue (hematoxylin eosin, orig. mag. x 20); b, From pulp tissue in a (arrow). Interconnecting vessels with disintegrated blood cells (hematoxylin eosin, orig. mag. x 340); c, From dentin wall in a. Bacteria in odontoblast layer and in adjacent dentinal tubules of predentin (Brown and Brenn, orig. mag. x 1250).



observation of pulpal calcifications, which proved to be bone rather than dentin. In the coronal part, there was chronic inflammation in the remaining soft tissue; whereas in the apical part a noninflamed pulp remained (Figures 35,36).

Figure 35. Section from coronal part of tooth F in Figure 32. a, Coronal pulp, hard tissue, with pulp tissue inclusions (hematoxylin eosin, orig. mag. x 20); b, From calcified pulp horn. Irritation dentin, vital pulp tissue with inflammatory cells, and vessel with agglutinated blood (hematoxylin eosin, orig. mag. x 600); c, From remaining pulp horn, reversal line, irritation dentin, and disintegrating pulp tissue (hematoxylin eosin, orig. mag. x 700); d, Centrally in pulp, moderate chronic inflammation. (hematoxylin eosin, orig. mag. x 800).

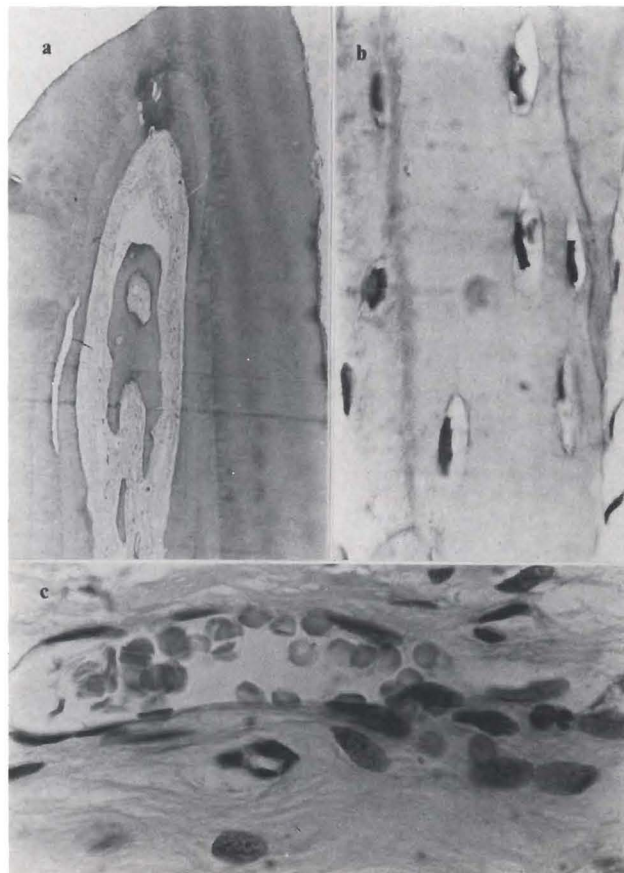
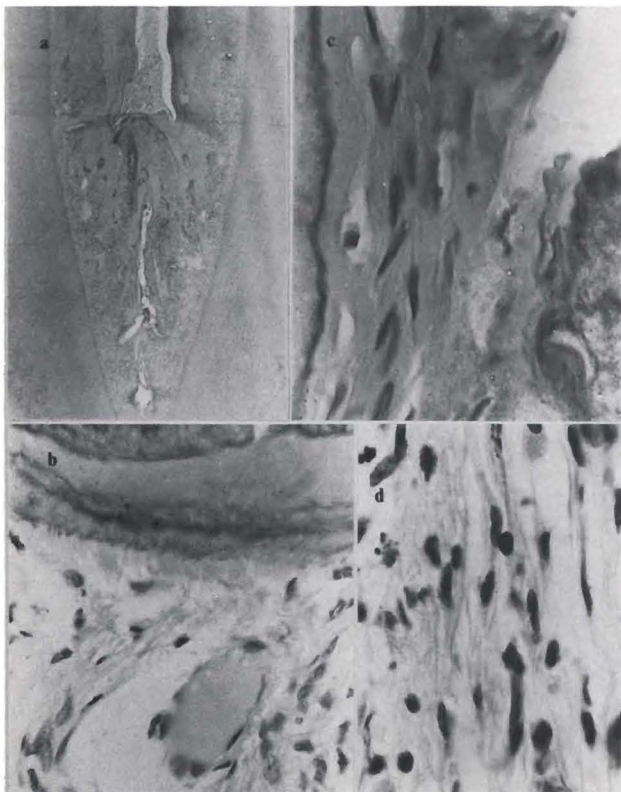


Figure 36. Section from apical part of tooth F in Figure 32. a, Root pulp with extensive central calcification (hematoxylin eosin, orig. mag. x 20); b, From central calcification, hard tissue with cells (hematoxylin eosin, orig. mag. x 900); c, From apical pulp, functioning vessel in noninflamed tissue (hematoxylin eosin, orig. mag. x 800).

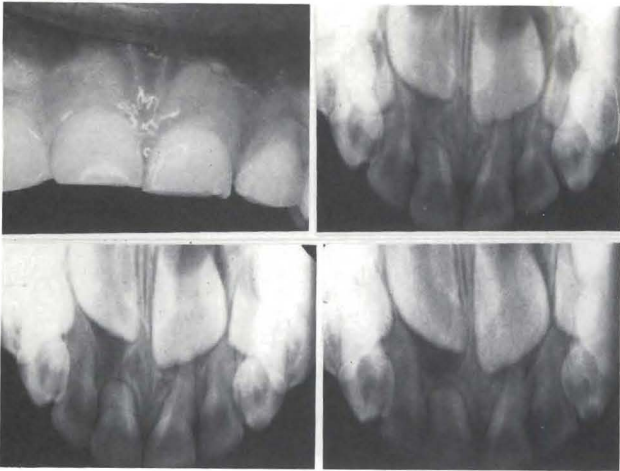

Figure 37. Findings: 5.5-year-old girl struck tooth E at about two years of age. Tooth E was mobile, not sensitive to percussion or palpation; had normal color, and normal associated soft tissues (clinical photograph). Increased PDL space, periapical radiolucency, and external root resorption were seen on the radiograph. The tooth E was extracted approximately forty-two months after trauma.

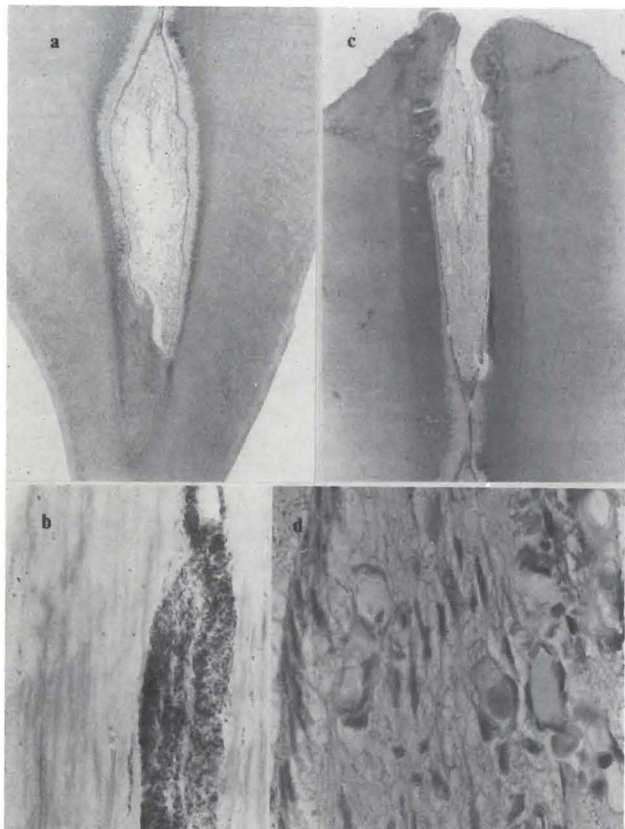

Figure 38. Sections of coronal and apical part of tooth E in Figure 37. a, Coronal pulp with irritation dentin and structured pulp tissue; b, Crack in coronal dentin with bacteria (Brown and Brenn, orig. mag. x 500); c, Section from apical part of root with structured pulp (hematoxylin eosin, orig. mag. x 20); d, From tissue in c, remaining odontoblast layer, and some vessels with agglutinated blood (hematoxylin eosin, orig. mag. x 600).

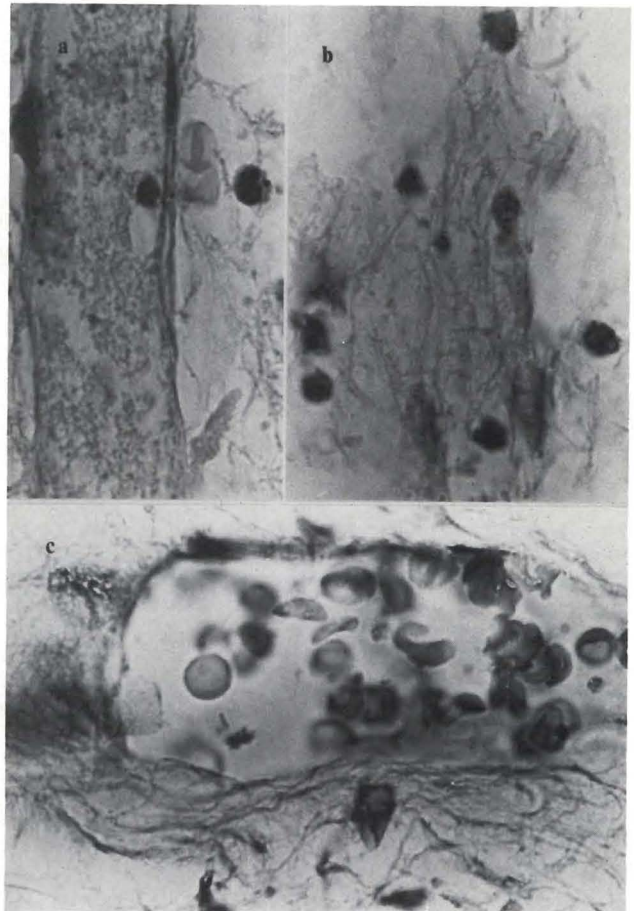


Figure 39. Sections from coronal pulp in Figure 38A. a, Vessel with disintegrated blood (hematoxylin eosin, orig. mag. x 1250); b, Disintegrating pulp tissue with scattered chronic inflammatory cells (hematoxylin eosin, orig. mag. x 1250); c, Functioning vessel in healthy pulp tissue (hematoxylin eosin, orig. mag. x 1250).

A five-year-old girl was evaluated forty-two months after dental trauma. Tooth E was struck when she was two years old. The tooth was mobile, but not sensitive to percussion or palpation. There was no apparent soft tissue damage. Radiographically, there were increased periodontal ligament space, a periapical radiolucency and external root resorption (Figure 37). There were cracks in the dentin with bacteria, irritation dentin in the pulp horn, and remaining structured pulp tissue with agglutination of blood, in vessels (Figures 38,39).

Forty-four months previously, a five-year, eight-month-old girl was struck on tooth F. The tooth became grey and then gradually lightened. Tooth F was hit several times later, but the subsequent traumatic injuries were not thought to require treatment. At the time of extraction, the tooth was mobile, grey-black, had

Figure 40. Findings: J.L., five-year, eight-month old girl struck tooth F at two years of age. Tooth became grey quickly, then lightened. Several additional traumatic incidents followed over the next few years, none requiring treatment. Tooth F was mobile, grey-black, with draining sinus tract, swollen labial gingiva, and Class II Ellis coronal fracture (clinical photograph). Periapical radiolucency, external root resorption, and pulp space calcification were seen in the radiograph. The tooth F was removed approximately forty-four months after injury.

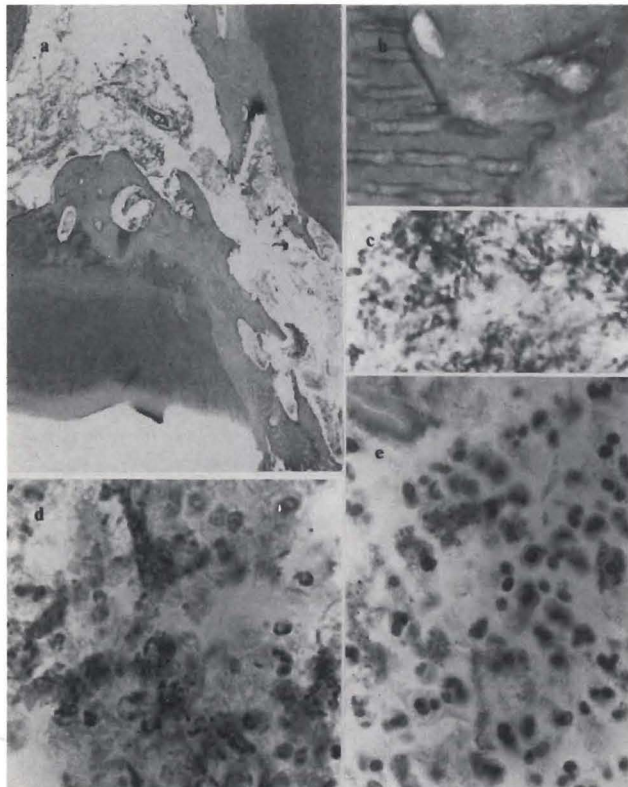
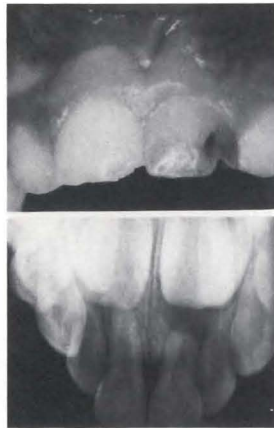

Figure 41. Sections of coronal part of tooth F in Figure 40. a, Perforation of distal pulp horn with earlier resorption, present apposition and disintegrating pulp tissue. (hematoxylin eosin, orig. mag. x 20); b, From transition area, dentin/hard tissue demonstrating irregular hard tissue apposition directly on primary dentin. (hematoxylin eosin, orig. mag. x 900); c, From coronal perforation, dense clustering of bacteria in coronal part (Brown and Brenn, orig. mag. x 900); d, From area adjacent to c, transition between neutrophilic leukocytes and bacteria (Brown and Brenn, orig. mag. x 1250); e, Area adjacent to d, dense concentration of pyknotic neutrophilic leukocytes with bacteria (hematoxylin eosin, orig. mag. x 900).

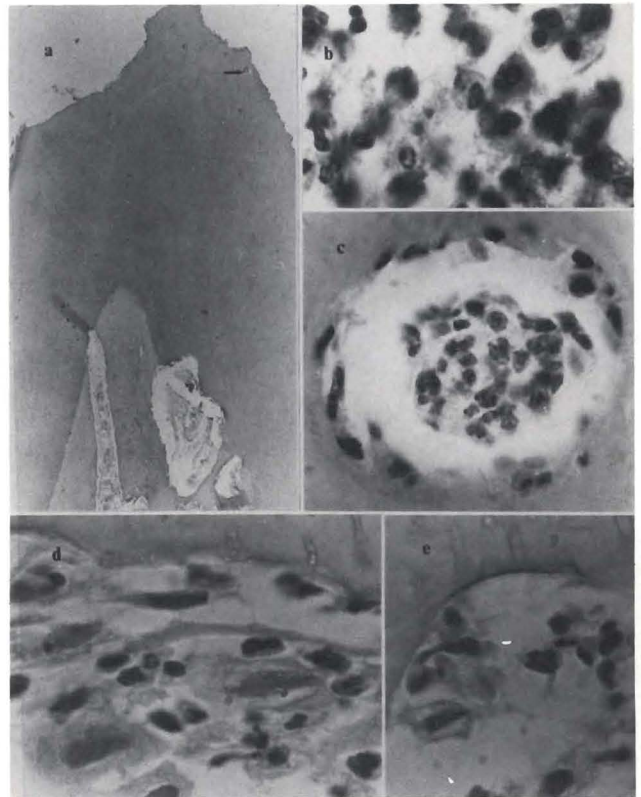


Figure 42. Root section of tooth in Figure 41. a, External root resorption, with internal hard tissue apposition in canal (hematoxylin eosin, orig. mag. x 20); b, Necrobiotic neutrophilic leukocytes and chronic inflammatory cells in apical third root canal (hematoxylin eosin, orig. mag. x 1250); c, From arrow in a, neutrophilic leukocytes in lateral canal (hematoxylin eosin, orig. mag. x 1250); d, Periapical tissue, mast cells, neutrophilic leukocytes, lymphocytes, and macrophages (hematoxylin eosin, orig. mag. x 1250); e, Earlier resorption, presently no apposition (hematoxylin eosin, orig. mag. x 1250).

gingival swelling, a draining labial sinus tract, and a Class II Ellis fracture (Figure 40).<sup>26</sup> There was a coronal pulp space exposure with bacterial invasion and disintegrated pulp tissue; numerous neutrophilic leukocytes; and in the apical direction, lymphocytes, plasma cells and macrophages (Figure 41). In the apical pulp tissue, there were no circulatory disturbances. In the apical part of the canal there was considerable apposition of hard tissue, and resorption. There was severe inflammation, which also extended into lateral canals (Figure 42).

A six-year, two-month-old boy suffered several traumatic incidents over a sixty-one-month period. He first injured teeth E and F, at the age of thirteen months. None of the teeth caused the patient pain or other symptoms during the sixty-one months. At presentation, both teeth were mobile, yellow, not sensitive to percussion or palpation and there were no soft tissue changes in the region. Both teeth showed increased

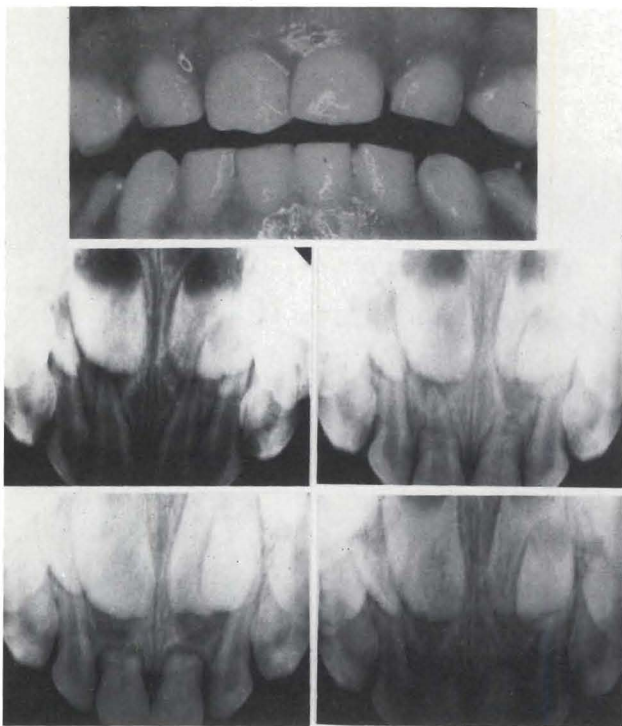


Figure 43. Findings: T.K., six-year, two-month-old boy struck teeth E and F; first at thirteen months. Subsequent episodes of minor trauma occurred over next five years. Teeth E and F were mobile, yellowed, not sensitive to percussion or palpation, with no soft tissue changes (clinical photograph). Radiographically, both teeth showed increased PDL space, pulp space calcification, apical external root resorption, and periapical radiolucencies. The teeth were extracted five years, one month, after initial trauma.

periodontal ligament space, pulp-space calcifications, periapical radiolucencies, and apical root resorption (Figure 43). Both teeth demonstrated similar hard tissue appositions in the root canals, with remaining pulp tissue in poor condition. Partial necrosis of and bacteria in the remaining pulp tissue, and vital pulp tissue in the apical part with resorption and apposition were observed (Figures 44-46).

## DISCUSSION

Our data indicate great variability in combinations of clinical conditions, leading to equally great variability in radiographical and histological findings, following traumatic injuries to primary incisors. Because clinicians can only observe the clinical signs and symptoms and the radiographical changes, the actual status of the pulp is left to conjecture.

Early in this century, it was shown that there was no correlation between clinical signs and symptoms and an accurate histological diagnosis.<sup>49</sup> Although that study was flawed by many artifacts in the histological evaluation, the general results were sound and confirmed in

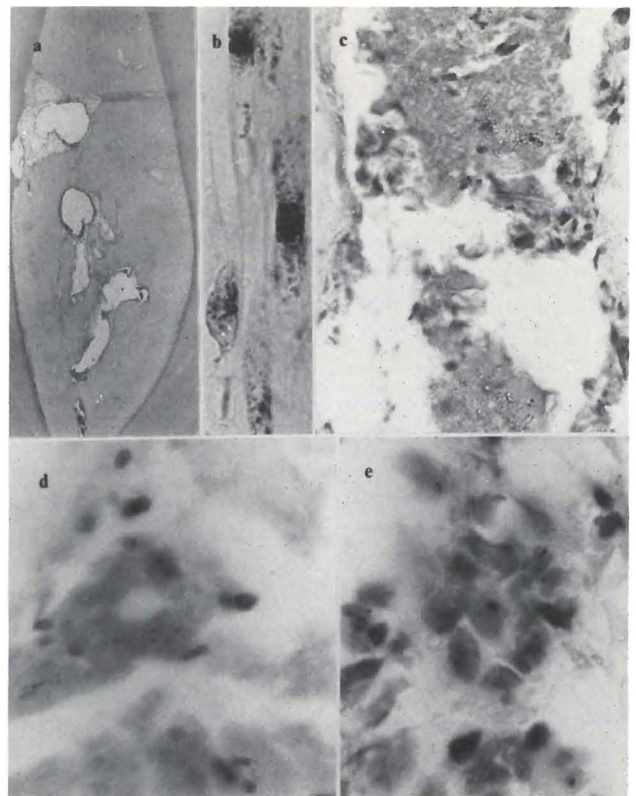


Figure 44. Section from remaining coronal part of tooth E in Figure 43. a, Extensive hard tissue formation with pulp tissue inclusions (hematoxylin eosin, orig. mag. x 20); b, Crack in coronal dentin, with bacterial (Brown and Brenn, orig. mag. x 1250); c, Coronal remaining disintegrating pulp tissue (hematoxylin eosin, orig. mag. x 800); d, Central pulp tissue, necrotic (hematoxylin eosin, orig. mag. x 1250); e, Inflammatory cells in disintegrating pulp tissue (hematoxylin eosin, orig. mag. x 1250).

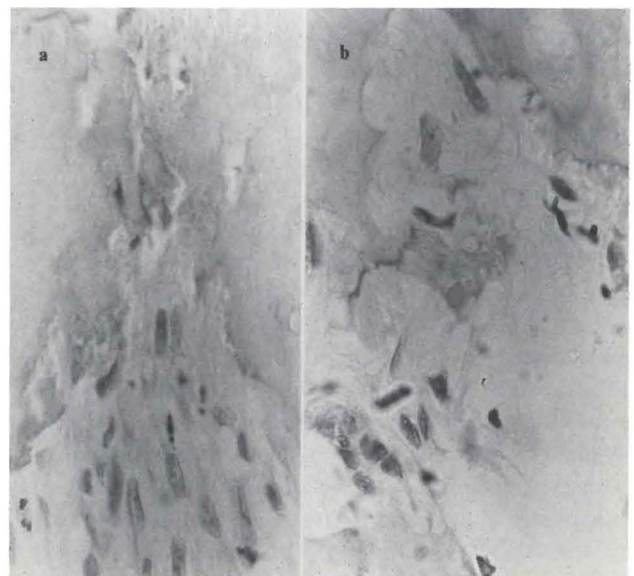


Figure 45. Section from apical part of tooth E in Figures 43 and 44. a, Resorption/apposition, vital apical pulp with few neutrophilic leukocytes (hematoxylin eosin, orig. mag. x 550); b, Resorption/apposition to reversal lines in apical ramification (hematoxylin eosin, orig. mag. x 700).

later studies, utilizing improved histological methodology and strict criteria.<sup>50,51</sup>

Also in our study, there was no correlation between the clinical signs and symptoms and the histopathological findings; thus, even patterns among our findings could not be determined.

Because parental histories of dental injuries are sometimes scanty, unreliable, or totally lacking, little is known about the exact nature of the trauma: for example, force of the trauma, direction of the blow, and sensitivity of the tooth. We classified our cases, therefore, in accordance with the elapsed time between injury and extraction. Histopathological changes occurred in the pulp of all injured primary teeth.

In general, the cellular response to dental trauma is directed by the same response mechanisms found in other connective tissues. According to Robbins *et al.*, "Cell injury is one of the most common cell responses in disease affecting virtually every cell type in almost all pathologic conditions."<sup>48</sup> This general rule was confirmed in our study, where there was necrosis, acute and chronic inflammation, and resorption and apposition in almost all cases. Calcifications, often considered by the dental profession as beneficial and protective, are in fact part of the pathological condition, in that they represent deposition of calcium salts in dead and dying tissue.<sup>52</sup>

Regarding color changes of traumatized primary teeth, our observations do not confirm the statement that grey/black discoloration is the result of rapid pulp disintegration and yellow/brown discoloration the result of chronic low grade pulpal inflammation.<sup>17,25,26,38,40,45</sup> Out of 110 discolored teeth, fifty-one were grey/black and fifty-nine, yellow/brown. Of the grey/black teeth, there was necrosis in thirty-three and resorption/apposition in eighteen; whereas in the yellow/brown, there was necrosis in seventeen and resorption/apposition in forty-two. Thus, although the overriding histological feature in the grey/black teeth was necrosis, and in the yellow/brown teeth was resorption/apposition, in each case there could be resorption/apposition in the grey/black and necrosis in the yellow/brown. To illustrate the point, the tooth in Figure 21 was yellow/brown and the pulp was totally necrotic in the total absence of calcifications (Figure 22); whereas the tooth in Figure 40 was grey/black and the pulp showed extensive calcifications involving the apical third of the root canal (Figures 41,42). Parts of the pulp were necrotic.

On the other hand, of two teeth with normal color, one had no calcifications and a necrotic pulp (Figures 18-20); whereas the other had calcifications and a vital pulp (Figures 37-39). Thus, color changes give the clinician

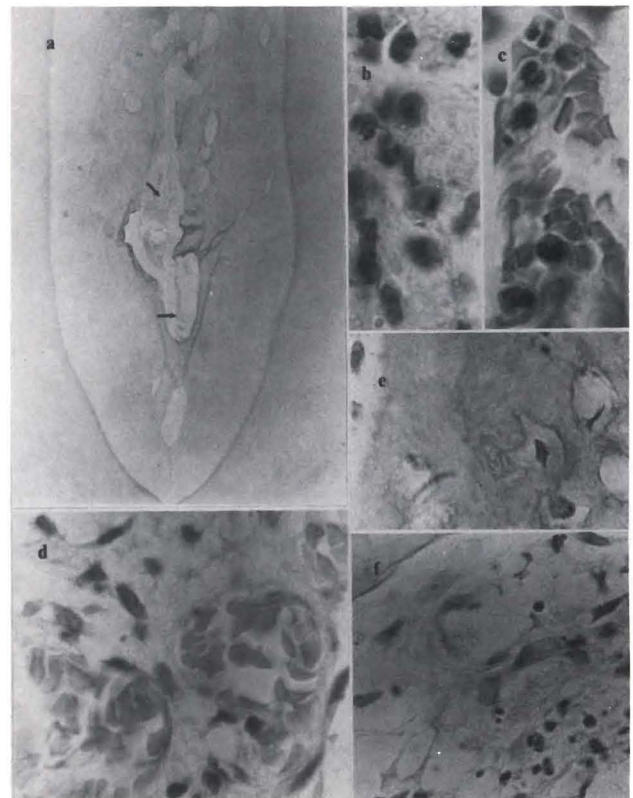


Figure 46. Section from remaining coronal part of tooth F in Figure 43. a, Extensive hard tissue formation with pulp tissue inclusions (hematoxylin eosin, orig. mag. x 20); b, Tissue at point of horizontal arrow a, necrotic with neutrophilic leukocytes (hematoxylin eosin, orig. mag. x 1250); c, From oblique arrow in a, functioning afferent vessel with neutrophilic leukocytes (hematoxylin eosin, orig. mag. x 1250); d, Farther apically, vital pulp tissue with functioning vessels and scattered inflammatory cells (hematoxylin eosin, orig. mag. x 1000); e, Hard tissue with cell inclusion in apical root canal (hematoxylin eosin, orig. mag. x 700); f, In apical root canal, vital pulp tissue with scattered inflammatory cells.

strong indications of pulpal changes, even though not of the specific change; but lack of color changes do not necessarily indicate a healthy pulp. On the contrary, the pulpal changes may be as severe (Figures 16,17) as those occurring in teeth with color changes.

Although the time-interval since the trauma is important for the extent of pulpal damage, great variables also occurred in this area. At seven days, there was extensive necrosis in one case (Figures 8-9); whereas there was a well-structured pulp tissue with only foci of inflammation in another (Figures 11-13). Thus, the time-interval is not a decisive factor in determination of the extent of

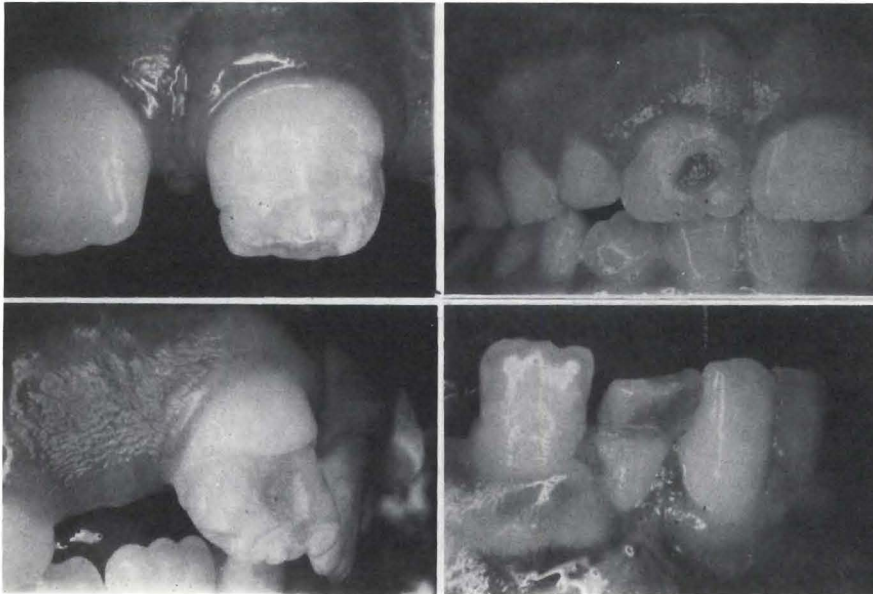


Figure 47. Permanent teeth damage due to trauma of corresponding primary tooth, which were retained after the trauma.

destruction of the pulp. Also at fourteen days, where histological examination revealed total necrosis of the entire coronal pulp and a periapical lesion in two teeth (Figures 14-17), the traumata were distinctly different. This emphasizes that force and direction of the trauma are as important as the time-factor.

On the other hand, apparently equal traumata in the same region may cause vastly different responses. This is illustrated in two pairs of central incisors in each of two patients (Figures 27-29 and 32-36). In both cases, there was extensive necrosis in one tooth, whereas there was vital pulp with a severe inflammatory response and resorption/apposition in the other.

The cumulative effect of two traumata do not give any clue as to the destructive effect of each trauma. The pulp response in teeth exposed to two traumata cannot be distinguished from the response in teeth exposed to one trauma, at the same time-interval (Figures 18-20 and 23-26).

Radiographic changes such as external root resorption, internal root resorption, pulp space calcifications, periodontal ligament space-thickening, and periapical radiolucencies suggest ongoing pulpal disintegration and associated inflammation. It is important to note that all of the above diagnostic factors may occur with or without complaints from the patient. Oftentimes the chief complaint comes from a parent who is concerned about the child's compromised cosmetic appearance from a discolored tooth. Absence of dental pain or other symptomatology, however, does not rule out pathosis of dental and periodontal structures.

Following the resolution of the pain associated with the trauma per se, in our study, pain was not a factor for clinical intervention. Clinical examinations showed palpation/percussion sensitivity in thirty-eight cases. These observations confirm our previous investigations, which showed a lack of correlation between pulpal destruction and pain.<sup>50,51</sup>

At the time of the initial trauma to primary incisors, following any obvious emergency treatment of face, neck or jaw lacerations, the dentist has to decide the appropriate treatment of the primary tooth.

To aid in immediate diagnosis, the dentist relies on observations of tooth and alveolar mobility, dental fractures, dental displacement, periodontal conditions, and radiographical interpretation of hard-tissue damage. To aid in long-term diagnosis, the data include tooth-color changes, mobility of the teeth, odontalgia, results of pulp-sensitivity testing, soft tissue changes, and radiographic evidence of pathological alterations of the primary incisor or morphological changes of a developing tooth.

Injuries to developing permanent teeth from initial traumatic displacement of primary incisors are not preventable. The dentist aims all management efforts, therefore, at preventing or minimizing subsequent inflammatory histopathological insult to the immature, adjacent developing permanent teeth.

Once a total analysis of the injuries is made and neurological impairment and injuries requiring referral have received proper attention, the treatment options are to reposition and stabilize displaced teeth, intervene endodontically, or extract the injured tooth (teeth).

With the exception of extraction, any treatment carries with it some risk to the permanent incisor. If a primary incisor pulp is not irreversibly damaged, tissue healing will occur and the permanent tooth bud will not be at risk. If pulp disintegration does occur, associated periapical osteitis may in time jeopardize the adjacent permanent teeth. Careful periodic diagnostic monitoring is essential, if no clinical intervention is planned. Such careful observations, however, still do not ensure undisturbed odontogenesis of underlying permanent teeth.

Abnormalities of permanent anterior teeth following injuries to their primary predecessors (Figure 47) have



been reported to occur in from 17 percent to 74 percent of the cases.<sup>24,29,32,33,40,44</sup> The prudent dentist realizes, therefore, the importance of eliminating or at least minimizing the risk of injury to the permanent teeth.

Andreasen documented and illustrated a case in which a 1.5-year-old child suffered an intruded maxillary primary central incisor.<sup>53</sup> After the injury, the intruded incisor was not treated, but left alone to re-erupt. Although clinical and radiographic evidence of pulpal pathosis could be seen one year later (for example, yellow discoloration, pulp space calcification, increased periodontal ligament space) the injured primary incisor was still left in place. The succedaneous central incisor consequently ceased development, and was removed. Although one can argue that the initial traumatic impact may have caused cessation of development of the permanent tooth, effects of the chronically inflamed intramedullary environment around the permanent tooth bud must be seriously considered. Our material, including cases of intrusion (Figures 14,15 and 18-20), emphasizes this point. The accumulation of neutrophilic leukocytes in the area of the permanent tooth bud provides the mechanism of dissolving the enamel epithelium (Figures 17,19,20,28). According to Robbins and Cotran the half-life of neutrophilic leukocytes is seven hours, and when they disintegrate, enzymes are released which are capable of dissolving tissue.<sup>54</sup> Had the severely intruded primary incisor been removed soon after injury, any influence of subsequent inflammatory changes would have been eliminated.

While all known endodontic medicaments are irritating to associated tissues, one must refrain from using highly toxic medicaments such as formocresol, paraformaldehyde, tricresol, camphorated monochlorophenol, or other phenol combinations or derivatives.<sup>55</sup> It is also shown that any medicament which is introduced in the pulp may sensitize the individual.<sup>56</sup> This is specifically confirmed for formocresol and glutaraldehyde.<sup>57-59</sup>

The only irrigation solution to be used is 1 percent sodium hypochlorite.<sup>60</sup> The objective of canal instrumentation, short of areas of resorption, must be as in permanent teeth to remove all disintegrating pulp tissue.<sup>61</sup> In case of partial necrosis, calcium hydroxide (pure chemical) should be used as described in Safavi *et al.*<sup>62</sup> Following the elimination of bacteria, a thick mix of zinc oxide and eugenol should be used for obturation.

A less favorable prognosis for primary teeth requiring endodontic treatment could be attributed to anatomic differences, particularly to more extensive ramifications of the root canal in primary teeth, which make it more difficult to achieve adequate instrumentation. Finally,

the fact that primary teeth will be resorbed makes the choice of a material for obturation of the root canal, more of a problem. Furthermore, the relatively short time that primary teeth remain *in situ* allows for successful endodontic therapy of most primary teeth during the time when their retention would be advantageous for space maintenance and aesthetics. The concern for the permanent tooth, however, must be of paramount importance. As long as therapy does not involve the use of toxic medicaments, and instrumentation and obturation are limited to the canal, no additional trauma will accrue to the succedaneous tooth.

The cosmetic integrity of a succedaneous tooth must be considered at risk, whenever the tooth is subjected to the impact from a traumatized or infected primary tooth. Although the risk of minor areas of enamel discoloration or hypoplasia may be worth taking in premolars, the prominent cosmetic role of permanent incisors and the restorative implications of such defects in anterior teeth merit extraordinary concern.<sup>34,43,63</sup>

Special concern must be noted for children who are at risk, because of medical complications: for example, subacute bacterial endocarditis attributable to cardiac abnormalities.<sup>64</sup> There is no rationale for retaining a primary incisor with progressive pulpal disintegration, in such patients. As occurred in our cases, because the pulp tissue of many injured primary incisors contains bacteria (Figures 4-7,14,15,32-36), one must assume that such bacteria may serve as a nidus for potential circulatory inoculation. Children with intraventricular shunts for treatment of hydrocephalus, and those with medical conditions that compromise normal healing processes or immunological competence are further examples of patients who merit special concern.<sup>65</sup>

Finally, taking all considerations together, an attempt should be made for retention of the traumatized tooth with appropriate treatment. Based upon examination of the histologic data in our study, extraction was the treatment of choice.

## CONCLUSIONS

- Trauma to primary teeth causes pulpal damage of various degrees, depending on the force of the trauma.
- Color changes of the crown may or may not occur; but none of these conditions will indicate a specific stage of pulpal degeneration.
- Depending on force and direction of the blow and the development of the adjacent tooth bud, damage to the latter will often occur.

- It is possible under these circumstances to perform endodontic treatment of the primary tooth, provided no toxic medicaments are used, and provided the obturation material is placed short of the foramen.
- Since it is difficult to establish the state of periapical inflammatory destruction, which would further damage the tooth bud, when in doubt, the primary tooth should be extracted.
- No correlation between clinical/radiographical observations and the histopathological changes in the pulp and periapical tissue can be established.

#### REFERENCES

1. I. Andreassen, J.O., and Ravn, J.J.: Epidemiology of traumatic dental injuries to primary and permanent teeth in a Danish population sample. *Int J Oral Surg*, 1:235-239, 1972.
2. Zadik, D.: A survey of traumatized primary anterior teeth in Jerusalem preschool children. *Community Dent Oral Epidemiol*, 4:149-151, July, 1976.
3. Gelbier, S.: Injured anterior teeth in children. A preliminary discussion. *Brit Dent J*, 123:331-335, October, 1967.
4. Grundy, J.R.: The incidence of fractured incisors. *Brit Dent J*, 106:312-314, May, 1959.
5. Ferguson, F.S., and Ripa, L.W.: Prevalence and type of traumatic injuries to the anterior teeth of preschool children. *J Pedodontics*, 4:3-8, Fall, 1979.
6. Sanchez, J.R.: Traumatismos de los dientes anteriores en niños pre-escolares. *Acta Odontol Pediatr*, 2:17-23, June, 1981.
7. Personal Communication. Dr. L. Nelson, Dr. R. Harshaw, October, 1982.
8. Turner, J.G.: Effects of abscesses arising from temporary teeth. *Brit J Dent Science*, 49:562-564, 1906.
9. Turner, J.G.: Injury to the teeth of succession by abscess of the temporary teeth. *Brit Dent J*, 30:1233-1237, December, 1909.
10. Turner, J.G.: Two cases of hypoplasia of enamel. *Proc Odon Soc Roy Soc Med*, 5:73-74, February, 1912.
11. Morningstar, C.H.: Effect of injection of the deciduous molar on the permanent tooth germ. *J Am Dent Assoc*, 24:786-791, May, 1937.
12. Bauer, W.H.: Effect of periapical processes of deciduous teeth on the buds of permanent teeth, a pathological clinical study. *Am J Orthodont*, 32:232-241, April, 1946.
13. Borgman, M.: Das akute trauma im milchgebiss. *Deutsche Zahnärztliche Zeitschrift*, 14:325-331, February, 1959.
14. Schreiber, C.K.: The effect of trauma on the anterior deciduous teeth. *Brit Dent J*, 106:340-343, May, 1959.
15. Castaldi, C.R.; Florence, D.E.; Van Alstine, R.S. *et al*: Traumatic injury to unerupted incisors following a blow to the primary teeth. *J Canad Dent Assoc*, 25:752-762, December, 1959.
16. Rodda, J.C.: Gross maldevelopment of a permanent tooth caused by trauma to its deciduous predecessor. *N Z Dent J*, 56:24-25, January, 1960.
17. Bennett, D.T.: Traumatized anterior teeth. *Brit Dent J*, 116:52-55, January, 1964.
18. Ando, S.; Sanka, Y.; Nakashima, T. *et al*: Studies on the consecutive survey of succedaneous and permanent dentition in Japanese children. Part 3. Effects of periapical osteitis in the deciduous predecessors on the surface malformation of their permanent successors. *J Nihon U Sch Dent*, 8:61-81, June, 1966.
19. Hawes, R.R.: Traumatized primary teeth. *D Clin N Am*, 391-404, July, 1966.
20. McCormick, J. and Filostrat, J.J.: Injury to the teeth of succession by abscess of the temporary teeth. *J Dent Child*, 34:501-504, November, 1967.
21. Kaplan, N.L.; Zach, L.; and Goldsmith, E.D.: Effects of pulpal exposure in the primary dentition on the succedaneous teeth. *J Dent Child*, 34:237-242, July, 1967.
22. Binns, W.H. and Escobar, A.: Defects in permanent teeth following pulp exposure of primary teeth. *J Dent Child*, 34:4-14, January, 1967.
23. Matsumiya, S.: Experimental pathological study on the effect of treatment of infected root canals in the deciduous tooth on growth of the permanent tooth germ. *Int Dent J*, 18:546-559, September, 1968.
24. Ravn, J.J.: Sequelae of acute mechanical traumata in the primary dentition. A clinical study. *J Dent Child*, 35:281-289, July, 1968.
25. MacGregor, S.A.: Management of injuries to deciduous incisors. *J Canad Dent Assoc*, 35:26-34, January, 1969.
26. Ellis, R.G., and Davey, K.W.: *Treatment of injuries of children*. 5th ed. Chicago: Year Book Medical Publishers, 1970, pp 27-55.
27. Selliseth, N.E.: The significance of traumatized primary incisors on the development and eruption of permanent teeth. *Eur Orthod Soc Rep Congr*, 443-459, 1970.
28. Andreassen, J.O.; Sundstrom, B.; and Ravn, J.J.: The effect of traumatic injuries to primary teeth on their permanent successors. I. A clinical and histologic study of 117 injured permanent teeth. *Scand J Dent Res*, 79:219-283, 1971.
29. Andreassen, J.O. and Ravn, J.J.: The effect of injuries to primary teeth on their permanent successors. II. A clinical and radiographic follow-up study of 213 teeth. *Scand J Dent Res*, 79:284-294, 1971.
30. Valderhaug, J.: Periapical inflammation in primary teeth and its effect on the permanent successors. *Int J Oral Surg*, 3:171-182, 1972.
31. Winter, G.B., and Kramer, I.R.H.: Changes in periodontal membrane bone, and permanent tooth following experimental pulpal injury in deciduous molar teeth of monkeys (*Macaca Iruis*). *Arch Oral Biol*, 17:1771-1779, December, 1972.
32. Andreassen, J.O., and Ravn, J.J.: Enamel changes in permanent teeth after trauma to their primary predecessors. *Scand J Dent Res*, 81:203-209, 1973.
33. Ravn, J.J.: Developmental disturbances in permanent teeth after exarticulation of their primary predecessors. *Scand J Dent Res*, 83:131-134, 1975.
34. Brook, A.H., and Winter, G.B.: Developmental arrest of permanent tooth germs following pulpal infection of deciduous teeth. *Brit Dent J*, 139:9-11, July, 1975.
35. Andreassen, J.O.: The influence of traumatic intrusion of primary teeth on their permanent successors. A radiographic and histologic study in monkeys. *Int J Oral Surg*, 5:207-219, 1976.
36. Pruhs, R.J.; Olen, G.A.; and Sharma, P.S.: Relationship between formocresol pulpotomies on primary teeth and enamel defects on their permanent successors. *J Am Dent Assoc*, 94:698-700, April, 1977.
37. Thylstrup, A. and Andreassen, J.O.: The influence of traumatic intrusion of primary teeth on their permanent successors in monkeys. A macroscopic, polarized light, and scanning electron microscopic study. *J Oral Pathol*, 6:296-306, September, 1977.
38. Schroder, V.; Wennberg, E.; Granath, L. *et al*: Traumatized primary incisors—follow-up program based on frequency of periapical osteitis related to tooth color. *Swed Dent J*, 1:95-98, 1977.
39. Andreassen, J.O. and Riis, I.: Influence of pulp necrosis and periapical inflammation of primary teeth on their permanent successors. Combined macroscopic and histologic study in monkeys. *Int J Oral Surg*, 7:178-187, 1978.
40. Jacobsen, I. and Sagnes, G.: Traumatized primary anterior teeth. Prognosis related to calcific reactions in the pulp cavity. *Acta Odontol Scand*, 36:199-204, 1978.

41. Smith, R.J. and Rapp, R.: A cephalometric study of the developmental relationship between primary and permanent maxillary central incisor teeth. *J Dent Child*, 47:36-41, January-February, 1980.
42. Zadik, D.: Traumatized teeth: Two-year results. *J Pedodontics*, 4:116-123, Winter, 1980.
43. Messer, L.B.; Cline, J.T.; and Korf, N.W.: Long-term effects of primary molar pulpotomies on succedaneous bicuspid. *J Dent Res*, 59:116-123, February, 1980.
44. Andreasen, J.O.: *Traumatic injuries of the teeth*. 2nd ed. Philadelphia: Saunders, 1981; pp 273-383.
45. Soxman, J.A.; Nazif, M.M.; and Bouquot, J.: Pulpal pathology in relation to discoloration of primary anterior teeth. *J Dent Child*, 51:282-284, July-August, 1984.
46. Brin, I.; Ben-Bassat, Y.; Fuks, A. *et al*: Trauma to the primary incisors and its effect on the permanent successors. *Pediatric Dentistry*, 6:78-82, June, 1984.
47. Ben-Bassat, Y.; Brin, I.; Fuks, A. *et al*: Effect of trauma to the primary incisors on permanent successors in different developmental stages. *Pediatric Dentistry*, 7:37-40, March, 1985.
48. Robbins, S.L.; Cotran, R.S.; and Kumar V.K.: Cellular injury and adaptation. In: *Pathologic basis of disease*. Philadelphia: W.B. Saunders, 1984, pp 2, 3.
49. Greth, H.: *Diagnostik der pulpaerkrankungen*. Berlin: Hermann Meusser Verlag, 1933.
50. Langeland, K.: Histologic evaluation of pulp reactions to operative procedures. *Oral Surg*, 12:1235-1248, 1357-1371, November, 1959.
51. Langeland, K.; Anderson, D.M.; Cotton, W.R. *et al*: Microbiological aspects of dentin caries and their pulpal sequelae. Proceedings: International Symposium on Amalgam and Tooth-Coloured Restorative Materials. University of Nijmegen, OP Dent, Nijmegen, The Netherlands, pp 173-202, 1976.
52. Robbins, S.L.; Cotran, R.S.; and Kumar, V.K.: *Pathologic Basis of Disease*. Philadelphia: W.B. Saunders, 1984; p 35.
53. Andreasen, J.O.: *Traumatic injuries of the teeth*. 2nd ed. Philadelphia: W.B. Saunders, 1981, pp:310-311.
54. Robbins, S.L. and Cotran, R.S.: *Pathologic basis of disease*. Philadelphia: W.B. Saunders, 1979; p 76.
55. Spangberg, L.; Engstrom, B.; and Langeland, K.: Biologic effects of dental materials. Toxicity and antimicrobial effect of endodontic antiseptics *in vitro*. *Oral Surg*, 36:856-871, December, 1973.
56. Barnes, G.W. and Langeland, K.: Antibody formation in primates following introduction of antigens into the root canal. *J Dent Res*, 45:1111-1114, July-August, 1966.
57. Myers, D.R.; Shoaf, H.K.; Dirksen, T.R. *et al*: Distribution of 14C-Formaldehyde after pulpotomy with formocresol. *J Am Dent Assoc*, 96:805-813, May, 1978.
58. Myers, D.R.; Pashley, D.; Whitford, D. *et al*: Acute toxicity of systemically administered formocresol. *J Dent Res Abst*, #803, 58A:293, January, 1979.
59. Myers, D.R.; Pashley, D.; Burham, D. *et al*: Distribution of 14C-Glutaraldehyde absorbed from pulpotomy sites. *J Dent Res, Abst #152*, Vol. 65 (special issue), February, 1986.
60. Langeland, K.: The histologic basis in endodontic treatment. *D Clin N Am*, 491-520, November, 1967.
61. Langeland, K.; Liao, K.; and Pascon, E.A.: Work savings devices in endodontics. Efficacy of sonic and ultrasonic instruments. *J Endod*, 11:499-510, November, 1985.
62. Safavi, K.; Dowden, W.E.; Introcaso, J.H. *et al*: A comparison of antimicrobial effects of calcium hydroxide and iodine-potassium iodide. *J Endod*, 11:454-456, October, 1985.
63. Simon, M.; Mullem, P.J.; and Lamers, A.C.: Periapical tissue reaction in monkeys to endodontic treatment using formocresol as a disinfectant. *J Endod*, 5:239-241, August, 1979.
64. American Heart Association: Prevention of bacterial endocarditis. *J Am Dent Assoc*, 95:600-605, September, 1977.
65. Croll, T.P.; Greiner, D.; and Schut, L.: Antibiotic prophylaxis for the hydrocephalic dental patient with a shunt. *Pediatric Dent*, 1:81-86, June, 1979.

---

## NEUTROPHILS IN HUMAN DISEASES

Human neutrophilic polymorphonuclear leukocytes (neutrophils) provide an effective host defense against bacterial and fungal infection, but they are also important in the pathogenesis of tissue damage in certain noninfectious diseases.

Mild to moderate abnormalities of neutrophil function have been reported in many acquired and congenital diseases. In most of these disorders, the biochemical or morphologic basis of the defects is unknown and the relevance of the neutrophil defect to the manifestations of the disease is unclear. In contrast, persons with marked neutropenia or severe defects in neutrophil function may have aphthous ulcers of the mucous membranes, severe gingivitis, periodontal disease and recurrent bouts of pneumonia and other types of life-threatening bacterial and fungal infections, although infection-free periods may occur.

Malech, H.L. and Gallin, J.C.: Immunology: Neutrophils in human diseases. *N Engl J Med*, 317:687-694, September 10, 1987.

---

# A histological comparison of direct pulp capping agents in primary canines

Clara Turner, DMD  
Frank J. Courts, DDS, PhD  
Harold R. Stanley, DDS, MS

**D**irect pulp capping is designed to stimulate the formation of reparative dentin in teeth where the pulp is exposed.<sup>1-7</sup> Histological studies have shown that a number of calcium hydroxide preparations will stimulate the formation of a calcified bridge in the area of a pulp exposure.<sup>1-4,6,7</sup> Ideally, the placement of an appropriate medicament in direct contact with the exposed pulp tissue will promote deposition of a mineralized dentinal bridge and maintain pulp vitality.

Most studies have evaluated or compared the effectiveness of various agents in direct pulp capping procedures by using human permanent teeth or animal models.<sup>2-6,8-10</sup> Pulpotomy procedures in both primary and permanent teeth have also been used to study the response of the pulp to calcium hydroxide preparations. Currently, calcium hydroxide is recommended for pulpotomy procedures in young permanent teeth, but is not recommended as a medicament for pulpomies in primary teeth.<sup>11,12</sup> The frequency of chronic pulpal inflammation, necrosis and internal resorption leading to premature loss of the primary tooth led to this recommendation.<sup>13-17</sup> The failure rate reported for the calcium hydroxide pulpomies in primary teeth is responsible for not using calcium hydroxide for other pulp capping

procedures in primary teeth. The validity of primary teeth as a model for studying direct pulp capping, however, has been previously demonstrated.<sup>1,7</sup>

For many years the most commonly used direct pulp capping agent was *Dycal*\*. Recently, new calcium hydroxide preparations were introduced. *Life* (Sybron-Kerr) and *Nu-Cap* (Coe Laboratories, Inc.) are two of the more recent commercially available calcium hydroxide pulp-capping agents. The purpose of this histological study was to evaluate and to compare the results of applying three commercial calcium hydroxide preparations and a standard calcium hydroxide-saline paste to the dental pulp. The reactions of major interest were pulpal inflammation and formation of a dentinal bridge.

## METHODS AND MATERIALS

The pulpal response to direct pulp capping with *Dycal* and *Life* was reported in a previous study.<sup>7</sup> Those data were compared to the responses of *Nu-Cap* and calcium hydroxide-saline paste in this study. Identical methodologies were used in both studies. Thirty-four patients, ranging in age from six years to ten years, five months, were used in the study. The patient sample consisted of twelve males and twenty-two females. All patients were in good general health. From these patients, ninety-two primary canines (maxillary and man-

\*Advanced, Chemical-cured, L.D. Caulk.

Dr. Turner is Assistant Professor and Dr. Courts is Associate Professor and Chairman, Department of Pediatric Dentistry; Dr. Stanley is Professor Emeritus, Department of Oral Diagnostic Sciences, College of Dentistry, University of Florida, Gainesville, Florida.

dibular) were chosen as specimens for studying the pulpal response to direct pulp capping. *Nu-Cap*, *Dycal*, *Life* and calcium hydroxide-saline paste (calcium hydroxide and sterile saline) were used as the pulp-capping agents. Bilateral teeth were selected in each patient. All teeth were anesthetized by block or infiltration using 2 percent Lidocaine with 1:100,000 epinephrine. One of the four agents was placed directly over the pulp in each of the specimens. All teeth were intended for extraction, due to excessive crowding in the permanent incisor region. Fixed bilateral space maintainers were used where indicated. Teeth with restorations, caries, or more than a third of the root resorbed were excluded from the study. A written informed consent was obtained from the parent or legal guardian of each patient.

All teeth were isolated by a rubber dam, and a class V cavity preparation was made on the facial surface of the tooth. The floor of each preparation was prepared approximately 1.5 mm in depth. Following the cavity preparation, a mechanical pulp exposure was made with a sterile number four round bur in the central portion of the preparation. An attempt was made to limit the exposure size to 0.5 to 1.0 mm in diameter. Bleeding from the pulp exposure, if present, was controlled by dry, sterile cotton pellets. Then the exposure site and floor of the preparation were covered with one of the calcium hydroxide preparations. Zinc-oxide eugenol (IRM L.D. Caulk) was used to fill and seal the cavity.

Teeth to be evaluated for an immediate response were extracted seven days after treatment and those to be evaluated for long-term pulpal response were extracted at sixty-three days. Twenty-eight teeth were extracted at seven days and sixty-four were extracted at sixty-three days. Extraction of the teeth was done after using local anesthetic procedures as previously described. The teeth were coded at the time of extraction by the clinician and placed in 10 percent formalin for at least seventy-two hours. In teeth with limited root resorption, the apical third of the root was removed to facilitate the passage of the fixative into the pulp. The teeth were then decalcified in 5 percent formic acid for approximately twenty-one days. After embedding in paraffin and sectioning serially, sections were alternately stained with hematoxylin and eosin. The sections were evaluated for degree of pulpal inflammation and prevalence and integrity of dentinal bridge formation. The degree of pulpal inflammation was graded on a 0-4 scale:

- 0 - no inflammation
- 1 - mild inflammation infiltrate
- 2 - moderate inflammation infiltrate
- 3 - heavy inflammation infiltrate
- 4 - abscess

Table 1 □ Inflammation at seven days.

Inflammation score	Life	Dycal	Nu-Cap	CaOH <sub>2</sub>
0	1	1	1	0
1	0	1	5	1
2	1	2	1	5
3	0	0	2	3
4	1	0	1	1
Number (n)	3	4	10	10
Mean	2.00	1.25	1.7	2.4
Std. dev.	2.00	0.96	1.25	0.84
S.E.M.	1.16	0.48	0.40	0.27

Group distribution significantly different ( $p < 0.05$ ) as determined by Kruskal-Wallis analysis.

The quality of dentinal bridge formation was based on a 0-3 scale with the following significance:

- 0 - no matrix
- 1 - compression of collagen with fibrous matrix
- 2 - thin or incomplete matrix
- 3 - a complete dentin bridge with few or no cellular inclusions

All histological evaluations were completed by the same examiner, under blind conditions. A Kruskal-Wallis test was used to determine the significant differences in inflammatory response and bridge formation between the four groups.

## RESULTS

### Short-term study (seven days)

Following the direct pulp capping procedure, twenty-eight teeth were extracted at seven days. The inflammatory response of the various medicaments at seven days is summarized in Table 1. The Kruskal-Wallis statistical analysis indicated significant differences between the groups ( $p < 0.05$ ). The calcium hydroxide-saline paste produced the highest degree of inflammation with a mean inflammatory score of 2.40. The mean inflammatory scores for the other groups ranged from 1.25 to 2.00. When exposures produced tears in the pulp and impaction of dentinal chips, the degree of inflammation increased for all medicaments. A wide zone of mummification was seen with the calcium hydroxide-saline paste, while the commercial products showed little to no zones of mummification (Figures 1-3).

### Long-term study (sixty-three days)

Sixty-four primary canines were evaluated for long-term inflammatory response to direct pulp capping. The inflammatory responses to the various medicaments at sixty-three days are summarized in Table 2. The

Table 2 □ Inflammation at sixty-three days.

Inflammation score	Life	Dycal	Nu-Cap	CaOH <sub>2</sub>
0	12	8	8	5
1	4	7	4	5
2	1	2	1	2
3	0	1	1	1
4	1	0	0	1
Number (n)	18	18	14	14
Mean	0.56	0.78	0.64	1.14
Std. dev.	1.04	0.88	0.93	1.23
S.E.M.	0.25	0.21	0.25	0.33

Group distribution significantly different ( $p < 0.05$ ) as determined by Kruskal-Wallis analysis.

Table 3 □ Bridge formation at sixty-three days.

Bridge score	Life	Dycal	Nu-Cap	CaOH <sub>2</sub>
0	0	0	0	0
1	4	3	0	0
2	10	9	7	2
3	4	6	7	12
Number (n)	18	18	14	14
Mean	2.0	2.17	2.5	2.86
Std. dev.	0.69	0.71	0.52	0.36
S.E.M.	0.16	0.17	0.14	0.10

Group distribution significantly different ( $p < 0.05$ ) as determined by Kruskal-Wallis analysis.

Kruskal-Wallis statistical analysis indicated significant differences between groups ( $p < 0.05$ ). The calcium hydroxide-saline paste produced the highest degree of inflammation, with a mean inflammatory score of 1.14. Specific instances of high inflammation scores in all

groups were usually associated with impacted dentinal chips or inclusion of medicament deep pulpal tissues.

The dentinal bridge formations for the various medicaments are summarized in Table 3. The Kruskal-Wallis analysis indicated significant differences between

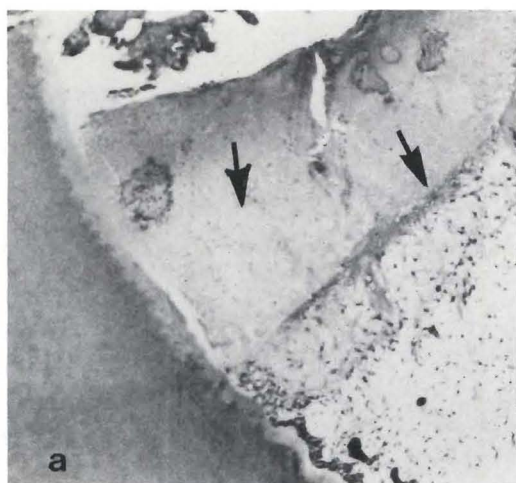


Figure 1a. Calcium hydroxide-saline paste, seven days. Note the thickness of the mummified layer. A line of demarcation is apparent. The exposure site — upper left corner. X80.

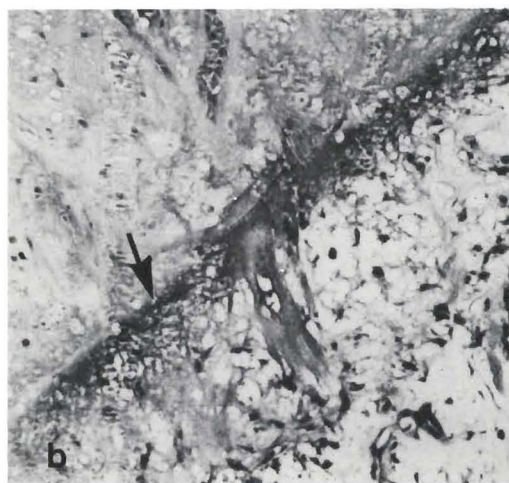


Figure 1b. Higher power of Figure 1a. Note the line of demarcation, which will eventually regenerate a new odontoblastic layer. X200.

Figure 2. Nu-Cap, seven days. A few inflammatory cells are present. No evidence of a mummified layer. X300.

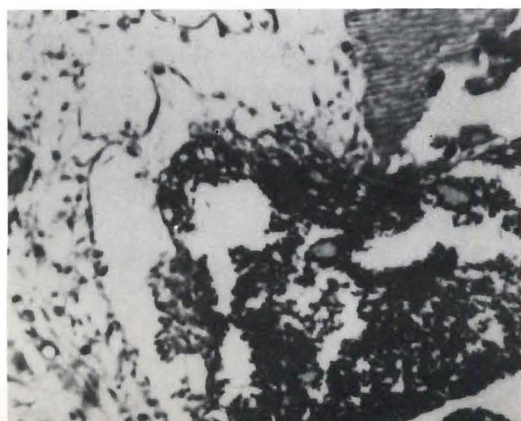


Figure 3. Nu-Cap, seven days. A more extreme inflammatory response, but no evidence of a mummified layer. X200.



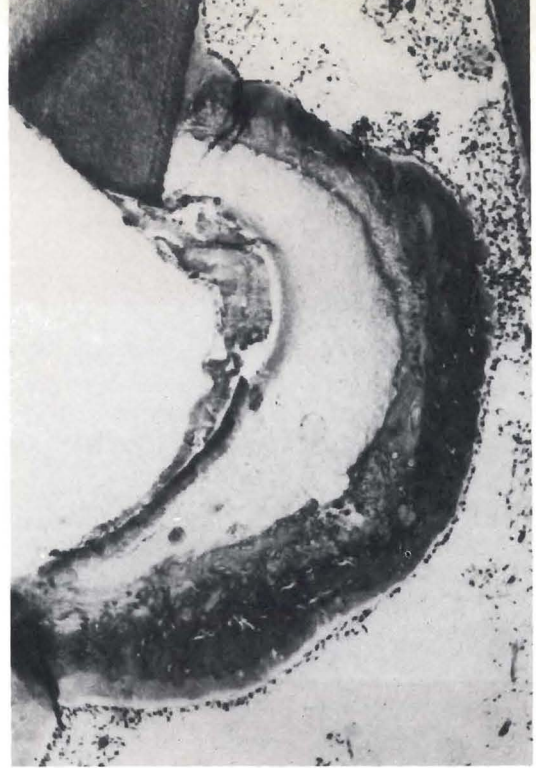groups ( $p < 0.05$ ). The calcium hydroxide-saline paste produced the thickest bridge with a mean score of 2.86. *Nu-Cap*, *Dycal*, and *Life* effected thinner bridges and little to no zone of mummification, when compared to those produced by the calcium hydroxide-saline paste (Figures 4-9). Bridge formations in the teeth treated with *Nu-Cap*, *Dycal* and *Life* were closely associated with the exposure sites, while with the calcium hydroxide-saline paste bridging occurred deeper within the pulp at the apical or lingual margin of the zone of mummification.

## DISCUSSION

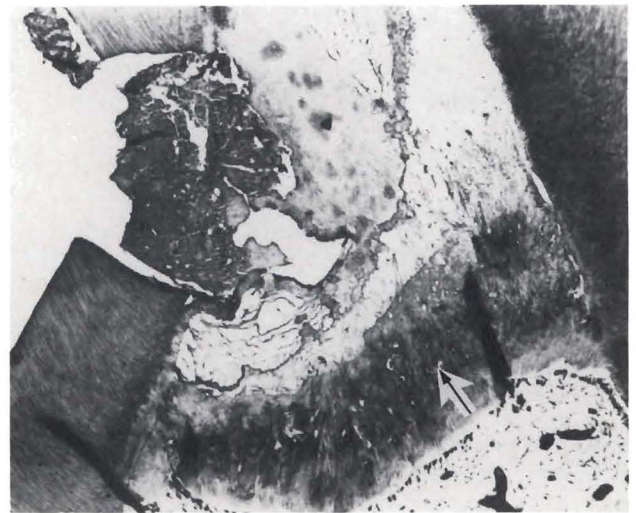The pulpal responses seen in this study were similar to those reported for permanent teeth.<sup>2</sup> The noninflamed pulp responded to all medicaments that contained calcium hydroxide, by the deposition of reparative dentin. The high incidence of internal resorption reported in previous studies was not seen in any of the histological specimens examined in this study; but one must consider that this was a relatively short-term study.<sup>13,14,16,17</sup> These results indicate that calcium hydroxide may be placed in direct contact with the primary pulp, if the pulp is not inflamed. Examples of such clinical use would include the direct capping of mechanical exposures; and in pulpotomies, when the remaining pulp tissue is not inflamed.

The seven-day histological examinations showed that the calcium hydroxide-saline paste causes a greater inflammatory response within the pulp, and also resulted in a wide zone of mummification. This finding may be associated with the greater alkalinity of the calcium hydroxide-saline paste. In teeth evaluated after sixty-three days, the trend toward increased inflammation with the calcium hydroxide-saline paste was again noted. Specific instances of high inflammatory scores were associated with deep maceration of the pulp during the initial preparation and the inclusion of dentinal chips and medicament. The maceration of the pulp and the inclusion of dentinal chips were relatively common, when standard clinical exposures were made.

While all medicaments stimulated dentinal bridges, there were important differences in quality and position. The calcium hydroxide-saline paste consistently formed thick bridges, but they occurred deep within the pulp at the junction of the mummified zone and the normal pulp tissue. All the commercial agents generally demonstrated thinner dentinal bridges and bridge positions more closely associated with exposure sites. This type of response may be more favorable, since it results



*Figure 4. Calcium hydroxide-saline paste, sixty-three days. Because of the thick mummified zone, the dentinal bridge almost reaches the lingual wall. This situation could eventually lead to loss of an adequate blood supply to the more incisally positioned tissue. X80.*



*Figure 5. Calcium hydroxide-saline paste, sixty-three days. The effects of the paste and the degree of pulpal destruction has led to the formation of a horizontal bridge, much removed from the point of exposure. X200.*

in a pulp of near original size. The reduced zone of mummification with these agents is the most probable cause of this bridge location. Excessive and deep bridge formation may result in areas of necrotic pulpal tissue, secondary to vascular constriction (Figure 4).

Because newer commercial calcium hydroxide medicaments have reduced alkalinity, incidences of local chemical cautery (mummification), pulpal necrosis and

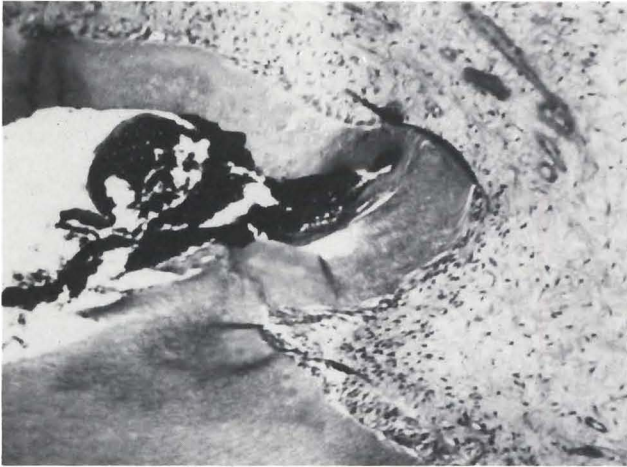


Figure 6. *Life*, sixty-three days. Dentinal bridge formation. Note impaction of medicament. X100.

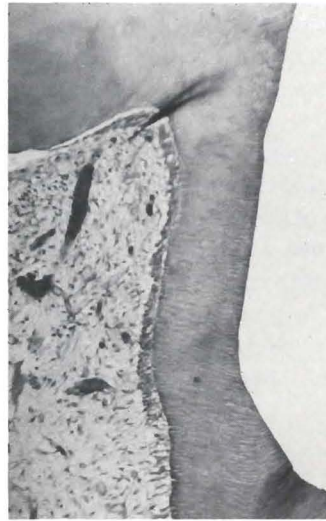

Figure 7. *Dycal*, sixty-three days. Dentinal bridge formation. X100.

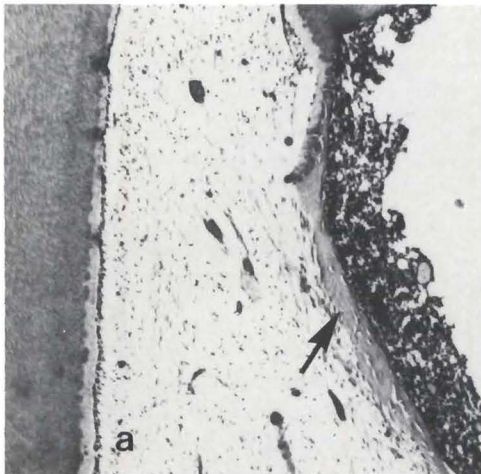


Figure 8a. *Nu-Cap*, sixty-three days. A thin dentinal bridge, located at the interphase of the capping medicament and the vital pulp tissue. X80.

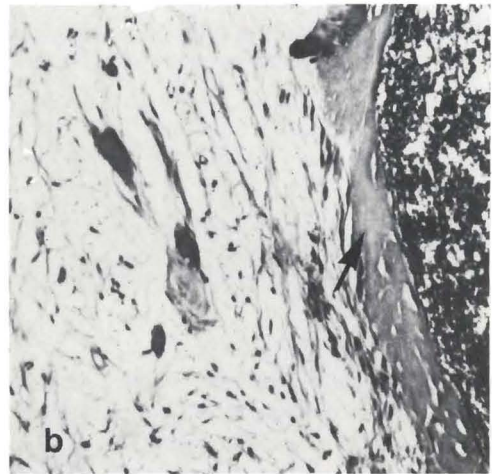


Figure 8b. A higher power of Figure 8a, revealing the dentinal bridge and a completely restored pulp. No inflammatory cells, X200.

inflammation are reduced. These characteristics may render them more effective in pulp therapy involving primary teeth. Since these teeth are highly susceptible to pulpal necrosis and internal resorption, a calcium hydroxide agent that is able to stimulate bridge formation with minimal inflammation and mummification should result in greater clinical success.

Certain types of clinical problems may be seen more frequently with the newer medicaments. The commercial agents demonstrated good bridge formation when the medicament was placed on the exposure site without deep impaction of dental chips. If the dental chips

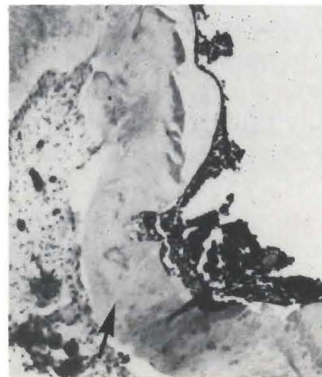


Figure 9. *Nu-Cap*, sixty-three days. A thicker dentinal bridge located at the interphase of the pulp capping medicament and the vital pulp tissue. X80.



were beneath the surface, however, they prevented good bridge formation. Inflammatory cells then accumulated around and between the chips and the medication, leading to pulp necrosis or continued pulpal inflammation. This phenomenon was not observed with the calcium hydroxide paste, since the broad zone of mummification usually included the area of maceration and chip impaction. Because of the decreased thickness of mummification in the commercial medicaments, the impaction of dentinal chips or maceration of the pulp may lead to an inflammatory response beyond the zone of mummification. This may result in continued inflammation that would lead to less favorable bridge formation.

#### REFERENCES

1. Phaneuf, R.A.; Frankel, S.N.; and Ruben, M.P.: A comparative histological evaluation of three calcium hydroxide preparations on the human primary dental pulp. *J Dent Child*, 35:61-76, January, 1968.
2. Stanley, H.R. and Lundy, T.: Dycal therapy for pulp exposures. *Oral Surg*, 34:818-827, November, 1972.
3. Pereira, J.C.; Bramante, C.M.; Berbert, A. *et al*: Effect of calcium hydroxide in powder or in paste form on pulp-capping procedures: histopathologic and radiographic analysis in dog's pulp. *Oral Surg*, 50:176-186, August, 1980.
4. Tronstad, L.: Reaction of the exposed pulp to dycal treatment. *Oral Surg*, 34:945-953, December, 1974.
5. Tronstad, L. and Mjor, I.A.: Capping of the inflamed pulp. *Oral Surg*, 34:477-485, September, 1972.
6. Weiss, M.B. and Bjorvatn, K.: Pulp capping in deciduous and newly erupted permanent teeth of monkeys. *Oral Surg*, 29:769-775, May, 1970.
7. Jerrell, R.G.; Courts, F.J.; and Stanley, H.R.: A comparison of two calcium hydroxide agents in direct pulp capping of primary teeth. *J Dent Child*, 51:34-38, January-February, 1984.
8. Isermann, G.T. and Kaminski, E.J.: Pulpal response to minimal exposure in the presence of bacteria and dycal. *J Endodont*, 5:322-327, November, 1979.
9. Brannstrom, M.; Nyborg, H.; and Stromberg, T.: Experiments with pulp capping. *Oral Surg*, 48:347-352, October, 1979.
10. McWalter, G.M.; El-Kafrawy, A.H.; and Mitchell, D.F.: Long-term study of pulp capping in monkeys with three agents. *JADA*, 93:105-110, July, 1976.
11. McDonald, R.E. and Avery, D.R.: *Dentistry for the child and adolescent*. St. Louis: C.V. Mosby Co., 1983, pp 218-219.
12. Kopel, H.M.: *Pediatric endodontics*. In *Endodontics*: Ingle, J.I. and Traintor, J.F. Ed 3. Philadelphia: Lea and Febiger, 1985, p 797.
13. Via, W.F.: Evaluation of deciduous molars treated by pulpotomy and calcium hydroxide. *JADA*, 50:34-43, January, 1955.
14. Doyle, W.A.; McDonald, R.E.; and Mitchell, D.F.: Formocresol versus calcium hydroxide in pulpotomy. *J Dent Child*, 29:86-97, 2nd Quarter 1962.
15. Spedding, R.H.; Mitchell, D.F.; and McDonald, R.E.: Formocresol and calcium hydroxide therapy. *J Dent Res*, September-October, 1965.
16. Magnusson, B.: Therapeutic pulpotomy in primary molars-clinical and histological follow-up. Calcium hydroxide paste as wound dressing. *Odontol Revy*, 21:415-431, 4th Quarter, 1970.
17. Schroder, U.: A 2-year follow-up of primary molars, pulpotomized with a gentle technique and capped with calcium hydroxide. *Scand J Dent Res*, 86:273-278, July, 1978.

This work was supported by grants from the Sybron-Kerr Corporation and Coe Laboratories, Inc.

---

#### DRINKING DURING PREGNANCY

Results of this study showed that light and moderate drinkers (those who drank two or fewer drinks per day) did not have an increased rate of malformations compared with nondrinkers. For those drinking less than one drink per day, these findings provide considerable reassurance in terms of overall risk; as little as a 12% increase in malformations had a 80% chance of being detected if it had been present. For those drinking one to two drinks per day, a 50% increase would likely have been identified if it were present.

The confidence limits may also provide some insight into the question of increased risk. With repeated estimates of two-sided 95% confidence limits, the true risk is expected to be below the upper limit 97.5 of 100 times. Therefore, the upper limits of the adjusted risk . . . are of interest. Increases in total malformations of more than 4% in the women averaging less than one drink per day and 29% in those averaging one to two drinks per day are unlikely.

Mills, J.L. and Graubard, B.I.:  
Is moderate drinking during pregnancy associated with an increased risk for malformations? *Pediatrics*, 80:309-314, September, 1987.

---

# Biochemical study of whole saliva from children with chronic renal failure

Frédéric Obry, Dr Chir Dent  
Alain B. Belcourt, Dr Sci  
Robert M. Frank, Dr Chir Dent,  
Dr Med, Dr Sci Odont

Children suffering from chronic renal failure (CRF) exhibit two oral conditions of interest. They have a high incidence of dental anomalies and their caries activity is very low.<sup>1-7</sup>

Moreover, Obry *et al* noted a DMFT Index of 0 in ten out of eighteen of such children, despite their high sugar intake, as well as their very poor oral hygiene and the subsequent accumulation of dental plaque.<sup>2</sup> The authors correlated these observations with the high pH values of the whole saliva from these subjects.

The aim of the present investigation was to establish the biochemical composition of unstimulated whole saliva, in the same group of CRF children.

## MATERIAL AND METHODS

### Experimental group

The experimental group consisted of ten CRF children, four girls and six boys, ages seven to sixteen years. These children were all dialyzed three times weekly at the Hautepierre Central Regional Hospital, Strasbourg. Their mean DMFT was 3.

A control group to consist of eight children, three girls and five boys, ages five to fourteen years, with an infant girl eight months old, was selected to assure an average

DMFT index of 3, thus matching the average index of the experimental group.

### Collection of saliva

Unstimulated whole saliva was collected from each child after the mouth was rinsed with distilled water. The saliva samples were obtained from CRF children before (T) and after (To) morning dialysis, at an average time-interval of three hours; and from the control group before departure to school. Collection of samples was repeated at several successive dialyses; as well as several days in the week, for the control group. Volumes ranging from 1 to 5 ml were obtained within a range of five to twenty minutes.

Thus collected, the saliva was kept on ice, immediately brought to the laboratory, centrifuged thirty minutes at 10,000g (Beckman, J. 21C), millipore-filtered through 0.45  $\mu$ m membranes and stored in a deep-freezer for further use.<sup>8,9</sup>

### Salivary urea and amino acid analyses

Salivary urea concentration and amino acid composition were determined with an automatic amino acid analyzer (Beckman 119CL), using a single column and a three-buffer system (pHs = 3.37, 4.09 and 6.04), with flow rates of 44 ml/h and 22 ml/h, respectively, for buffers and ninhydrin.<sup>10,12</sup>

The authors are with Centre de Recherches Odontologiques. Unité Inserm U 157. Faculté de Chirurgie Dentaire, 4 Rue Kirschleger 67000 Strasbourg, France.

### Salivary calcium, magnesium and potassium determinations

Salivary measurements of calcium, magnesium, and potassium were performed by atomic absorption spectrophotometry (Beckman 495 and Delhomme IL 157) according to the method described by Ramirez- Munoz and Roth.<sup>13-15</sup>

### Blood analyses

Urea, calcium, magnesium, and potassium concentrations in blood were analyzed, following the same procedures as used for salivary analysis.

### RESULTS

The ten CRF children exhibited very high levels of salivary urea before as well as after dialysis, with mean concentrations of  $513 \pm 210$  mg/100 ml and  $241 \pm 82$  mg/100 ml, respectively (Table 1). Even after dialysis, the urea level remained about 2.5 times higher than the mean urea salivary concentrations of  $110 \pm 48$  mg/100 ml observed in the control group.

Three different quantitative responses to dialysis have been observed among the various free amino acids in unstimulated whole saliva (Table 2). A first group of amino acids consisting of Asp, Thr, Ser, Glu, Pro, Gly, Met, Tyr and His seemed not to be appreciably affected by the treatment, although Gly and His exhibited a slight increase. Four amino acids decreased between T and To, Ala, Cys, Arg and Acy; whereas six increased, namely, Hyp, Val, Leu, Ile, Phe and Lys. Three groups could also be distinguished, when comparing the control group and the concentrations observed at T (Table 2). One group of ten composed of Asp, Thr, Ser, Val, Met, Ile, Leu, Tyr, Phe and Lys was depleted within the saliva of CRF children before dialysis; and another group of five consisting of Acy, Gly, Ala, His and Arg showed a significant increase. Among the variations in concentration of several of the amino acids, when comparing the salivas of the control group and those of the CRF children, before and after dialysis, we noticed that Ala decreased to return almost to the normal level, whereas Val and Lys increased back to normal concentrations. Two amino acids were very consistent, Glu and Pro. Finally the global level of basic amino acids was very high in CRF children's saliva and His remained at a high concentration, even after treatment, and we also observed the slight but permanent increase in Hyp.

Salivary concentrations of calcium and magnesium were significantly lower when compared to those of the

Table 1 □ Urea in unstimulated whole saliva and blood of CRF children expressed as : mg/100ml.

		Mean	S.D.	Range
Saliva	T	513	210	189 - 814
	To	241	82	107 - 362
	Normal	110	48	38 - 176
Blood	T	196	38	103 - 288
	To	53	22	5 - 170
	Normal	20	40	

control group (Table 3). They were three times lower for calcium and ten times lower for magnesium. The potassium levels were increased, proportionately, approximately 25 percent. Within the actual time-frame of the dialysis, i.e. between T and To, no significant variations were observed. As far as blood electrolytes were concerned, the calcium and potassium concentrations, measured before as well as after dialysis, stayed within the normal range.

### DISCUSSION

A very substantial part of the drop in the urea concentration in saliva, between T and To, may find its explanation in the extrarenal purification system. Nevertheless, the values for salivary urea shown in the present study are striking, because they are at least ten times higher than the concentrations found by Suddick *et al* in the saliva of normal subjects, and five times above the levels found in the subjects of the control group.<sup>16</sup> The difference between the results described by Suddick *et al* and those observed in the salivas of our normal subjects might be attributed to the nature of our control group, which was composed of caries-resistant children for whom numerous authors have reported a higher salivary urea content.<sup>16,17</sup>

Urea values observed in saliva were obviously higher than the concentrations recorded in blood within those patients.<sup>1</sup> As in blood, at T as well as at To, urea only increased to levels two to 6.5 times above normal; whereas in saliva the increase was well above these ratios.

It should be pointed out that in the CRF children, T/To ratio for blood urea was higher than the T/To ratio found in saliva. This T/To ratio may be considered as a measure of the efficiency of blood and saliva to purify themselves, which means that the ratios of 2.1 and 3.7 for saliva and blood, respectively, may signify that the function of excretion of the salivary glands was less efficient than dialysis of blood. From an opposing view,

Table 2 □ Amino acid composition of unstimulated whole CRF children's saliva, expressed as residues per thousand.

Amino acids	Normal		C R F			
	Mean values	S.D.	T		T <sub>0</sub>	
			Mean values	S.D.	Mean values	S.D.
Acy	33.66	5.45	61.73	11.48	48.46	8.50
Hyp	18.05	4.97	18.75	4.56	23.32	4.61
Asp	54.62	14.27	32.22	4.53	31.02	4.17
Thr	34.03	6.13	15.50	1.56	16.37	2.57
Ser	78.54	11.02	71.17	12.24	71.91	10.49
Glu	45.29	17.00	45.42	6.93	50.45	9.19
Pro	205.74	38.41	208.37	52.88	206.13	48.26
Gly	150.27	20.63	176.76	35.59	184.82	26.76
Ala	54.62	11.24	71.82	11.96	57.26	8.40
Cys	6.75	1.99	6.49	0.89	5.61	0.81
Val	46.15	10.76	40.11	2.98	46.91	5.15
Met	31.13	12.81	10.04	1.95	9.44	1.10
Ile	20.77	7.67	15.44	1.81	18.65	2.17
Leu	35.31	7.38	23.75	2.93	28.23	4.62
Tyr	46.26	7.54	32.63	4.14	30.90	3.31
Phe	51.28	10.44	28.88	3.73	35.06	3.83
His	30.26	11.66	69.94	8.13	73.67	8.28
Lys	44.17	9.68	32.73	6.80	41.59	9.50
Arg	13.14	6.79	39.25	6.64	20.18	3.25

Table 3 □ Calcium, magnesium and potassium content of saliva and blood of CRF children expressed in mM.

		Normal		C R F	
		Present study	Range <sup>16,23</sup>	T	T <sub>0</sub>
Saliva	Ca <sup>2+</sup>	1.21 ± 0.38	1.5 - 4	0.41 ± 0.08	0.38 ± 0.09
	Mg <sup>2+</sup>	0.34 ± 0.10	0.2 - 0.65	0.04 ± 0.01	0.32 ± 0.03
	K <sup>+</sup>	16.29 ± 2.26	19 - 22	20.75 ± 4.76	17.09 ± 3.58
Blood	Ca <sup>2+</sup>	2.12 ± 2.75		2.50 ± 0.20	2.89 ± 0.25
	K <sup>+</sup>	3.50 ± 5.00		5.28 ± 0.84	3.38 ± 0.35

it can be speculated that an important natural excretion occurred from the salivary glands, partially replacing normal renal function; thus accounting for the high concentrations of urea found in saliva.

Our observations were in agreement with those of de Stopelaar, who noticed high concentrations of urea in the saliva of young CRF patients.<sup>5</sup> Mueller *et al* were able to draw a correlation between blood and salivary urea within a group of CRF children.<sup>6</sup> As our study was performed with unstimulated whole saliva, it is not easy to compare our results with the observations of Dahlberg *et al*, Shannon *et al*, or Mueller *et al*, because they worked with stimulated parotid saliva.<sup>6,18,19</sup> Stimulated secretions may have affected their results.

From the standpoint of cariology, our observations suggest that the massive amounts of urea in saliva may lead to increased neutralizing capacity, as a result of a higher concentration of ammonia, arising from ureal hydrolysis. Thus, release of free acids by plaque would be inhibited once the plaque became saturated with urea. Such hypothesis conforms with the observations reported by Kleinberg, regarding the effects of the formation of urea and ammonia in salivary sediments.<sup>20</sup> In addition, since the salivary urea concentration remains quite high, even after dialysis, it could conceivably sustain this cariostatic effect.

The decrease in the concentration of some of the amino acids may represent a purifying effect; but also finds an explanation in the utilization of these molecules for metabolic purposes or in a detoxicating mechanism.

The observation that some of the amino acids, like Ala, vary and return to the normal concentration after dialysis, may correspond to a utilization by microorganisms in the oral cavity of the amino acids not found in an exogenous supply, when they are depleted; or to the degradation of some salivary protein without utilization of all the amino acids of the microorganisms, resulting in the increase of some of them. Hydroxyproline usually represents the tissular "stress" amino acid; its slight, but regular, increase, as well as the glycine increase, may correspond to a higher collagen turn-over provoked during the dialysis time period. With reference to the study of Dreyfus *et al*, the values obtained for serine in the present investigation were eight times larger, both for the CRF children and the control group.<sup>21</sup> At the present time, we have no explanation for this discrepancy.

Concerning the decreased calcium, the considerable lowering in magnesium as well as the slight increase in potassium, in the saliva of untreated CRF children, no suitable suggestion can be proposed to explain these observations, apart from a cellular response enhancing a leak in electrolytes, which would appear to be returned close to normalcy by dialysis. Our results corroborate the observations of Earlbaum and Quinton.<sup>22</sup> The patterns of ions in the salivas of the CRF children, compared with those in the control group, stand in sharp contrast to the blood electrolyte pattern where the CRF values were within normal ranges. The sodium was not analyzed, because the children were dialyzed against

sodium bicarbonate or acetate solutions, which would be expected to influence the measurements.

In conclusion, the saliva of CRF children in the present study, obviously, had a very disturbed composition. Additional and more detailed biochemical analyses are needed before we can reasonably hope to explain the properties of the saliva of such patients, particularly with respect to the surprisingly marked anticaries capacity of this fluid.

#### REFERENCES

1. Fischbach, M.; Sommermater, J.; Oby, F. *et al*: Anomalies dentaires de l'enfant atteint d'insuffisance rénale chronique. *Médecine et Hygiène*, 42:1259-1261, and *Ibid* 42:1346-1350, 1984.
2. Oby, F.; Belcourt, A.; Frank, R.M. *et al*: Faible activité carieuse et pH salivaire de jeunes dialyses rénaux chroniques. *J Biol Buccale*, 12 (6):181-187, 1984.
3. Chow, M.H. and Peterson, D.S.: Dental management of children with chronic renal failure undergoing hemodialysis therapy. *Oral Surg*, 48:18-34, 1979.
4. Bach, R.; Landeck, E.; Seipelt, H. *et al*: Zahnentwicklung, Kariesfrequenz und Struktur der Alveolarfortsätze bei Kindern mit chronischer Niereninsuffizienz. *Stomat*, 31:408-413, 1981.
5. Stoppelaar, J.D. de: Urea and ammonia in saliva of caries inactive children with renal disease. *J Dental Res*, 61:3-225 (abstract), 1982.
6. Mueller, W.A., Courts, F.J. and Tapley, P.M.: Relationship of salivary urea to caries incidence in CRF patients. *J Dental Res*, 63 (3): Special Issue 1984 (abstract No. 120).
7. Wolff, A.; Sarnat, H.; Stark, H. *et al*: Dental and oral pathology in children with chronic renal failure. *J Dental Res*, 63 (3): 549 (abstract), 1984.
8. Krembel, J.; Frank, R.M.; and Deluzarche, A.: Fractionation of human dental plaques. *Arch Oral Biol*, 14 (5):563-566, 1969.
9. Belcourt, A.; Krembel, J.; and Frank, R.M.: Les acides aminés des lipides de la matrice acellulaire de la plaque dentaire et de la salive filtrée chez l'homme. *J Biol Buccale*, 1 (1): 57-62, 1973.
10. Trelstad, R.L. and Lawley, K.R.: A simple economical buffer system for amino acid analysis. *Anal Biochem*, 70:287-289, 1976.
11. Trelstad, R.L.: Amino acid analysis of collagen. Application Data Beckman DS-526, 1978.
12. Beckman Instruments Inc.: Glycoprotein hydrolysate analysis, 180 minutes single-column. *118/119CL Application Notes* AN 004, 1979.
13. Ramirez-Munoz, J. and Roth, M.E.: Magnesium determination in human blood serum by atomic absorption spectroscopy with Autolam burner. *Flame Notes*, 5:1-5, 1970.
14. Ramirez-Munoz, J. and Roth, M.E.: Magnesium determination in blood serum by atomic absorption spectroscopy with Autolam burner. *Flame Notes*, 5:9-12, 1970.
15. Ramirez-Munoz, J. and Roth, M.E.: Potassium determination in human blood serum by atomic absorption spectroscopy with the autolam burner. *Flame Notes*, 5:16-19, 1970.
16. Suddick, R.P.; Hyder, J.; and Feller, R.P.: Salivary water and electrolytes and oral health. In *"The biological basis of dental caries"*, Menaker, L., ed. Hagerstown: Harper and Row, 1980, pp 132-147.
17. Regolatti, B.: Ammonia and urea in oral pathophysiology. A literature review. *Helv Odont Acta*, 15:139-146, 1971.
18. Dahlberg, W.H.; Sreebny, L.M.; and King, B.: Studies of parotid saliva and blood in hemodialysis patients. *J Appl Physiol*, 23:100-108, 1967.
19. Shannon, I.L.; Feller, R.P.; Eknoyan, G. *et al*: Human parotid saliva in renal failure and during dialysis. *Archs Oral Biol*, 22 (2): 83-86, 1977.
20. Kleinberg, I.: Effect of urea concentration on human plaque pH levels *in situ*. *Archs Oral Biol*, 12 (12):1475-1484, 1967.
21. Dreyfus, P.M.; Levy, H.L.; and Efrow, M.L.: Concerning amino acids in human saliva. *Experientia*, 24:447-448, 1968.
22. Earlbaum, A.M. and Quinton, P.M.: Elevated divalent ion concentration in parotid saliva from chronic renal failure patients. *Nephron*, 28:58-61, 1981.
23. Dawes, C.: The chemistry and physiology of saliva. In *"Textbook of oral biology"*, Shaw, J.H. *et al*, ed. Philadelphia: W.B. Saunders Co., 1978, pp 593-616.

We thank Mr. S. Gillmeth for his technical assistance and the nurses of the Pediatric Ward, Clinic III, Hopital de Haute-pierre, for their kind cooperation.

---

#### CHANGES IN THE DISEASE BURDEN

It is instructive to reflect on the differences in health status between the turn of the century and the present. Life expectancy at birth in the United States has increased from 47.3 to 74.7 years. Mortality among infants has been reduced from 162 to 10.6 per 1,000 live births, among 1- to 4-year-old children from almost 2,000 to 50/100,000, and among 5- to 14-year-old children from 390 to 20/100,000, surely a remarkable change. Life expectancy and infant mortality rates in Canada, worse than those in the United States earlier in the century, are now significantly better.

In 1900, infectious diseases were the leading cause of death. During the past 80 years, there has been a striking reduction in their incidence and lethality, in part because of better nutrition, less crowding, safe water, and nearly universal sanitation. Nonetheless, medical interventions, notably pre- and perinatal care, immunizations, and chemotherapy, were major factors in the dramatic change.

Eisenberg, L.: Preventive pediatrics: the promise and the peril. *Pediatrics*, 80:415-422, September, 1987.

---

# The unpredictability of primary molar resorption following ectopic eruption of permanent molars

Sergio J. Weinberger, DDS, cert. pedo.  
Gerald Z. Wright, DDS, MSD, FRCD (C)

**A**lthough numerous reports document the prevalence, etiology and treatment of ectopically erupting maxillary first permanent molars, little emphasis is given to the necessity of close supervision of second primary molars following corrections. Without close supervision, space loss and its detrimental effects on the dentition may occur. The purpose of this paper is to present case histories demonstrating the unpredictability of the resorptive process which may occur to the roots of second primary molars and may continue until the teeth are prematurely lost.

## LITERATURE REVIEW

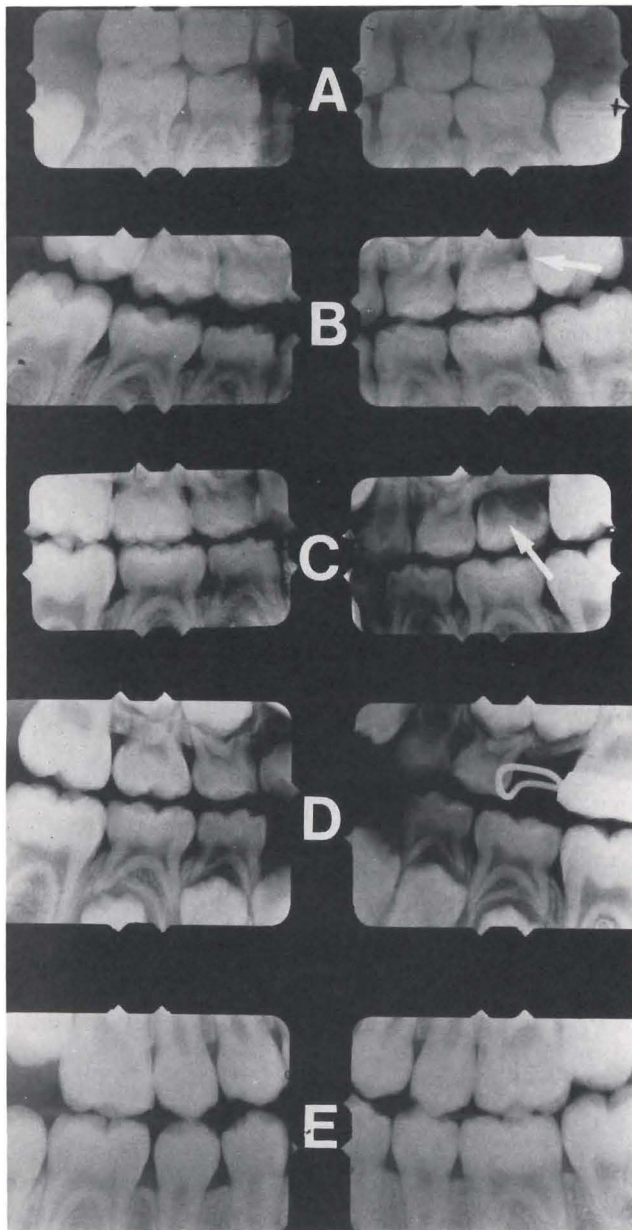
Ectopic eruption of the first permanent molar refers to an abnormal position of this tooth causing premature resorption of the distal surface of the second primary molar.<sup>1-6</sup> In some cases, the permanent molar corrects its path of eruption and erupts into a normal position. This is referred to as a reversible, or "jump" type of ectopic condition, in contrast to an irreversible type, or "hold" type, where the permanent molar is blocked from eruption.<sup>7,8</sup> The irreversible ectopic eruption usually requires some form of treatment to allow the eruption of the first permanent molar into occlusion. Two-thirds of cases, however, correct themselves.<sup>7,8</sup>

The reported incidence of ectopic eruption ranges from 2 percent to 4.3 percent of the population.<sup>2-6</sup> It is more commonly associated with maxillary first permanent molars, and seldom occurs in the mandibular first permanent molar area. There is no sex difference.<sup>7</sup> Carr and Mink, however, have documented a much higher incidence in cleft palate children, ranging as high as 30 percent in Veau Type III clefts.<sup>6</sup>

Many etiologic factors have been suggested for ectopic eruption of first permanent molars. Small arches, the paths of eruption of permanent molars, and early eruption of maxillary first permanent molars are factors that may cause ectopic eruption.<sup>9</sup> Lack of bony growth in the tuberosity region has also been related to this anomaly.<sup>3</sup> Examining lateral cephalograms and dental casts of forty-six children with ectopic eruption, ranging in age from four to twelve years, Pulver noted that a combination of factors contributed to ectopic eruption of the maxillary permanent first molar. These factors included: larger than normal maxillary primary and permanent teeth; shorter than normal length of the maxilla; maxilla is in a posterior relationship to the cranial base; abnormal angulation of eruption of the permanent molar exists; and there is delayed calcification of some affected first permanent molars.<sup>7</sup> Others also have arch-length deficiency related to this condition.<sup>10,11</sup>

Only a few papers have mentioned the long term effects of ectopic eruption on maxillary second primary molars. Kuroi followed the resorption of the second primary molars after reversible ectopic eruptions of

Dr. Weinberger is Assistant Professor, and Dr. Wright is Professor and Chairman, Division of Paediatric Dentistry, Faculty of Dentistry, The University of Western Ontario.



*Figure 1. A series of radiographs of the developing dentition. (A) Bitewing radiograph at 6.5 years of age shows extensive resorption on the right side as compared to the left side. (B) A delayed resorptive process is evident on the left side, while the right second primary molar exfoliated prematurely. In C observe the progressive space loss on the right and continued delayed resorption process on the left side. (D) A slight increase in the resorption process is evident. (E) The late mixed dentition bitewing radiographs taken 3.5 years later show an impacted premolar on the right side and adequate space for the erupting dentition on the left side.*

maxillary first permanent molars.<sup>1</sup> He found that of ninety-two teeth studied, only two teeth were lost prematurely, occurring shortly after the eruption of the permanent molars. Of the ninety remaining teeth, only thirteen (14 percent) showed further resorption during the observation period. All the teeth were normally exfoliated. Kuroi suggested that in cases of reversible ectopic eruption, it is reasonable to expect an arrest of the resorption of the primary molar and to assume that the atypically resorbed second primary molar will need no treatment after the eruption of the maxillary first permanent molar.<sup>1</sup> Starkey reported a case of early loss of the primary tooth occurring after the molar had corrected its position.<sup>12</sup> In his report the patient complained of pain and swelling in the area and there was evidence of cellulitis, necessitating extraction. In the majority of the cases, however, pain is not related to this condition.<sup>8,12</sup>

## CASE REPORTS

### Case 1

A 6.5-year-old, white male, in the early mixed dentition stage, presented for a recall examination in a private dental office. Bitewing radiographs were taken and revealed a moderate resorptive process on the distal surface of the left second primary molar (Figure 1A). On the right side, the resorptive process was severe, involving crown and roots. The patient was dismissed and recalled six months later, when new bitewing radiographs revealed that the resorptive process seemed to be delayed on the left side. The upper right second primary molar had exfoliated prematurely and space loss had occurred (Figure 1B). Only restorative treatment was performed.

The patient was seen again, a year later (Figure 1C). The emphasis appeared to have been on restorative treatment rather than on guiding the developing dentition. Six months later (Figure 1D), the space loss had increased on the right side. On the left side, a slight increase in the resorption process can be noticed. The late mixed dentition result of this case can be observed in Figure 1E. On the left side, the second premolar is erupting prematurely, but adequate space is available. On the right side, however, there appears to be a continuing space loss and the second premolar is impacted between the first premolar and permanent first molar. The patient will require major orthodontic treatment to correct this malocclusion.

**Case 2**

A 5.5-year-old black male presented to a private pediatric dental office for recall examination. Initially, two bitewing radiographs of the primary dentition were made (Figure 2A). No interproximal caries lesions were detected and there was no suspicion that ectopic eruption would occur. Radiographs taken sixteen months later revealed, however, that the upper left first permanent molar was resorbing the distal root of the second primary molar (Figure 2B). Twelve months later, new bitewing radiographs were made (Figure 2C). Severe premature resorption of the root of the upper left second primary molar was evident. The tooth prematurely exfoliated and a small space loss occurred. These bitewing radiographs also showed a resorptive process on the right side. One year later new radiographs were taken (Figure 2D). They show a bandloop space maintainer in place. On the right side, the resorptive process seemed to be arrested. Bitewing radiographs three years later showed all the premolars in occlusion (Figure 2E). In the interim, the child wore a removable appliance to move the maxillary second primary molar distally, recapturing the small space loss.

**DISCUSSION**

These cases demonstrate what appears to be two types of resorption associated with ectopic eruption. In both cases a progressive resorptive process occurred on one side and a stationary resorptive type on the other side. The cases point out the unpredictable courses of resorption.

The cases also emphasize the importance of close follow-up. Even in the same patient, the bilateral resorption rates were variable. Close follow-up resulted in a successful outcome for one patient (Case 2); whereas the other patient (Case 1) was less fortunate, requiring major orthodontic treatment as a sequela of the ectopic eruption. The patient in Case 2 had a favorable outcome resulting from close supervision, although a more aggressive approach could have been adopted. When the third set of bitewing radiographs was taken, the roots were resorbed. Removal of the second primary molar and placement of a space maintainer at that time could possibly have prevented even the minor distal movement required.

According to Kurol, "One could expect an arrest of the resorption of the primary molar in cases of reversible ectopic eruption" and assume that the atypically re-

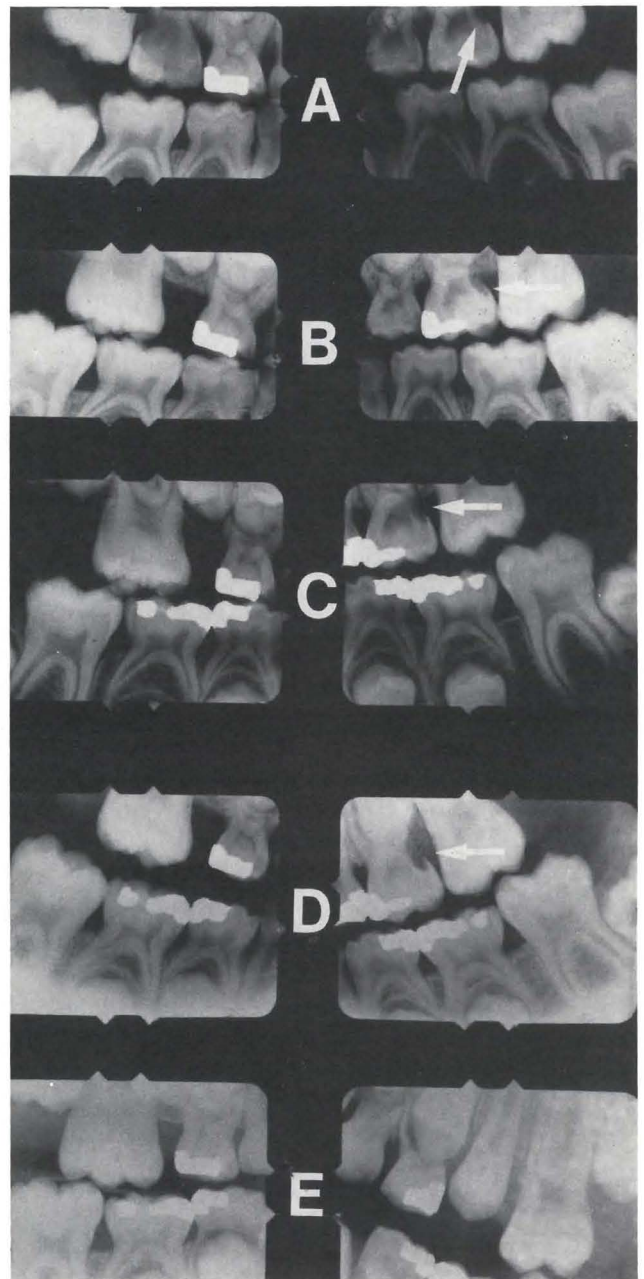


Figure 2. A series of radiographs from primary through to permanent dentitions. (A) Bitewing radiographs of 5.5-year-old show no signs of ectopic eruption on either side. (B) Signs of resorption on distal root of upper left second primary molar were observed, following first molar eruption. (C) One year later, severe resorption of the left primary molar is found and resorption in the primary molar on the right side was first noticed. (D) Space maintainer is in place. Minimal space loss occurred and resorption on the right side appeared arrested. (E) All premolars are in occlusion.



sorbed second primary molar will need no treatment, after the eruption of the maxillary first permanent molar.<sup>1</sup> The cases reported in this paper demonstrate that this does not always occur.

It is recommended that, in situations similar to the cases described, the dentist carefully examine the radiographs and follow each case closely. Another precautionary measure is to advise a parent about the situation. Advise them to call the dentist, if a molar is lost. Most parents are unaware that the molar losses may be premature and they can lead to major orthodontic problems.

#### REFERENCES

1. Kurol, J. and Bjerklín, K.: Resorption of maxillary second primary molars caused by ectopic eruption of the maxillary first permanent molar: a longitudinal and histological study. *J Dent Child*, 49:273-279, July-August, 1982.
2. O'Meara, W.F.: Ectopic eruption pattern in selected permanent teeth. *J Dent Res*, 41:607-616, May-June, 1962.
3. Cheyne, V.D. and Wessels, K.E.: Impaction of permanent first molar with resorption and space loss in region of deciduous second molar. *J Am Dent Assoc*, 35:774-780, December, 1947.
4. Bjerklín, K. and Kurol, J.: Prevalence of ectopic eruption of the maxillary first permanent molar. *Swed Dent J*, 5:29-34, 1981.
5. Kimmel, N.A. *et al*: Ectopic eruption of maxillary first permanent molars in different areas of the United States. *J Dent Child*, 49:294-299, July-August, 1982.
6. Carr, G.E. and Mink, J.R.: Ectopic eruption of the first permanent maxillary molar in cleft lip and cleft palate children. *J Dent Child*, 32:179-188, 3rd Quarter, 1965.
7. Pulver, F.: The etiology and prevalence of ectopic eruption of the maxillary first permanent molar. *J Dent Child*, 35:138-146, March-April, 1968.
8. Young, D.H.: Ectopic eruption of the first permanent molar. *J Dent Child*, 24:153-162, 3rd Quarter, 1957.
9. Chapman, M.H.: First upper permanent molars partially impacted against second deciduous molars. *Int J Oral Surg*, 9:339-345, 1923.
10. Graber, T.M.: *Orthodontics: principles and practice*, 3rd ed. Philadelphia: W.B. Saunders Company, 1972, pp 388-389.
11. Herman, E.: The malposed first permanent molar. *NY Dent J*, 35:343-350, June-July, 1969.
12. Starkey, P.: Infection following ectopic eruption of first permanent molars: case report. *J Dent Child*, 38:327-330, 4th Quarter, 1961.

---

#### TREATMENT OF THUMBSUCKING

Treatment of thumb-sucking needs to be measured against the risk. If the sucking habit is "empty" or devoid of adaptive function, then the risk of ignoring it is probably greater than the risk of treating it. But if the habit is "meaningful" or performs an adaptive function, then treatment may pose the greater risk.

Thumb-sucking in infancy appears meaningful, and in most cases it should be ignored. Sucking in children who are in crisis is an adaptive response and should not be treated. But if the habit remains once the crisis has passed, treatment is indicated.

Thumb-sucking is an inferior form of gratification for an older child's needs. It involves a highly simplistic manipulation of the body. It does not lead to generalized skill development or increased competence. In short, thumb-sucking contributes little if anything to an otherwise normal older child's adaptive behavior, and it presents many risks to the child's health. Therefore, otherwise normal children who have reached the age of 4 and who still suck their thumbs should be treated.

Why begin treatment at age 4?

- The average age at which spontaneous remission of thumb-sucking appears is about 4 years. Waiting until this time may render treatment unnecessary.
- To avoid self-esteem problems resulting from unpleasant feedback from peers and authority figures outside the home, the habit should probably be stopped before the child enters school. If treatment begins at 4 years of age, parents and child have a year to work on the habit.
- The dental problems that occur in chronic thumb-suckers are more difficult to correct if the habit persists beyond the age of 4. By this age, the adaptive value of thumb-sucking is far outweighed by its maladaptive possibilities.
- Four-year-old children have available many alternative responses that can serve a function similar to that of thumb-sucking.
- Four-year-old children are easier to distract and refocus than younger children, so treatment at this age may be easier.

Friman P.C.: Thumbsucking in childhood. *WIC Currents*, Vol. 13, No. 4, 1987.

---

# Comparison of chloral hydrate–hydroxyzine with and without meperidine for management of the difficult pediatric patient

## Behavior

John E. Nathan, DDS, MDS  
M. Stewart West, PhD

**B**y virtue of its wide range of safety, oral chloral hydrate (CH), alone or in combination with hydroxyzine (H), or promethazine is the most frequently used office preoperative medication to manage difficult young patients requiring extensive restorative treatment.<sup>1</sup> Despite its widespread use, frequent unsatisfactory and unpredictable levels of sedation have been reported, when attempting to treat highly disruptive patients, using the manufacturer's recommended 50 mg/kg hypnotic dosage.<sup>2-4</sup> While some authors have suggested higher doses, substantiation of their safety and effectiveness is lacking.

Need exists for controlled research to establish dosage guidelines for chloral hydrate combinations, particularly for management of the refractory child. As an alternative to significantly increasing CH dosage, selecting a parenteral route, or general anesthesia, this retrospective study assessed the efficacy and safety of a CH-H combination using both the standard (manufacturer's) and higher dose (70 mg/kg) of CH with and without oral meperidine.

The study has three specific aims:

- To assess the effectiveness of CH-H combination using the standard and higher doses in overcoming refractory behavior.

Dr. Nathan is Visiting Assistant Professor, Department of Pediatrics, Rush University Medical College, Chicago, IL and is in private practice limited to Pediatric Dentistry, Oak Brook, IL.

Dr. West is Research Associate, Department of Pediatrics, University of Texas Medical Center, Houston.

- To assess the impact of the addition of low doses of oral meperidine on the success of the standard and higher doses of CH.
- To examine the adjunctive effect of nitrous oxide, when medications alone fail to obtund disruptive behavior. It was hypothesized that the addition of meperidine, without increasing risk, would potentiate the depth of sedation sufficiently to permit treatment with less interfering behavior and less need for harsh physical restraint.

While selection of a route of administration which permits titration is considered ideal, the feasibility and practicality of the IV route for the disruptive young child is limited. Given the difficulty associated with vein cannulation on an uncooperative child, the extensive armamentarium required, and particularly an increasing trend toward prohibitive liability costs for in-office par-enteral sedation, the oral route remains viable for management of difficult children, despite its recognized limitations.

## BACKGROUND

On the basis of extensive clinical experience, Trapp and Kopel advocated the use of higher doses of chloral hydrate (70-75 mg/kg, respectively) to circumvent the occurrence of underdosage on difficult children.<sup>3,4</sup> Others report similar observations and have attempted to provide substantive data to assess the efficacy and safety of these higher doses.<sup>5-11</sup>

A few clinicians reported using dosages ranging from 75-100 mg/kg for pediatric dental and medical management.<sup>1,12-15</sup> Although reporting successes with minimal or no adverse reactions, none of these latter medical trials can be considered controlled investigations. Comprehensive reviews of existing studies and problematic issues involving chloral hydrate were reported by Nathan and Moore.<sup>16-18</sup>

Most investigations to date have encountered difficulty in parcelling out specific dose responses attributable to chloral hydrate. Sample sizes have generally been small or have used excessively wide ranges in age and weight; the failure to establish specific criteria for selection of subjects, in terms of the relationship of the criteria to the degree of apprehension and resistance, contributes to the variation of success, using various dosages of chloral hydrate. Studies which have attempted to compare dissimilar regimens, or those which utilized a fixed concentration of nitrous oxide on all subjects have confounded the ability to detect differences attributable to the primary sedative agent(s).

## MATERIALS AND METHODS

### Subjects

One hundred thirty-five patients, ranging in age from eighteen to sixty months (mean: 34), selected on the basis of an inability to perform restorative treatment without rigid physical restraint or potent pharmacologic medication, were treated in 142 visits. The extensiveness of treatment demands were such that patients requiring minimal types of treatment were excluded. Only those requiring a minimum of forty-five minutes of protracted cooperation to complete restorative treatment were included.

Treatment was provided within institutional and private practice settings by eight graduate pedodontic students and two pediatric dentists. All subjects were assessed with respect to their current cardiovascular and respiratory status, before the administration of oral agents. Preoperative NPO instructions for a minimum of six hours were enforced. A sedation log was maintained for each subject with recordings of blood pressure, pulse, and respiratory rates before the administration of drugs, before the commencement of treatment, at five to ten minute intervals during treatment, and until discharge from the dental clinic or private office. A precordial stethoscope was used during the dental treatment phase for continuous monitoring of the rhythm and quality of heart and lung sounds. Close attention was given to the maintenance of a patent airway, to preclude potential soft tissue obstructions related to head, neck, or jaw posture, or oversedation.

### Medications

Subjects received orally, either:

- Chloral hydrate, 50 or 70 mg/kg, plus hydroxyzine, 25 mg, or
- Chloral hydrate, 50 or 70 mg/kg, plus hydroxyzine, 25 mg, plus meperidine, 20-30 mg.

	Availability	Regimen A	Regimen B
CH	500 mg/5cc	50 or 70 mg/kg	50 or 70 mg/kg
Hydroxyzine	25 mg/5cc	25 mg	25 mg
Meperidine*	25 mg/2.5cc	—	1.5 mg/kg*

\*Absorption of meperidine by the oral route approximates 50 percent.

The selection of oral meperidine was not arbitrary. Its addition, even though the drug has a shorter duration of action than CH, was expected to provide an analgesic quality to the combination to overcome arousal, resulting from noxious intraoral manipulation, typically asso-

ciated with injection of a local anesthetic, placement of a rubber dam clamp or mouth prop, or preparation of a cavity.

Hydroxyzine, in a standard dose of 25 mg, was used, because of its anti-emetic qualities, to offset the tendency of chloral hydrate to upset the gastrointestinal tract.

Nitrous oxide-oxygen, in concentrations ranging from 10-50 percent, was used only after oral medications failed to produce adequate sedation, following a sixty-minute latent period; or as sedative effects weakened, when additional working time was needed to complete treatment. Since nitrous oxide provides analgesia and offers the capacity for titration, data to compare the adjunctive benefit of nitrous oxide versus oral meperidine were considered useful.

All restorative treatment was performed, using 2 percent Lidocaine with 1:100,000 epinephrine, using rubber dam wherever feasible. Visits lasted between sixty and ninety minutes (mean: seventy).

### Evaluation of sedation

The primary objective of sedative medication in this trial was to overcome extremely disruptive behavior, and thus permit an acceptable quality of treatment. The sedation was considered "successful" if harsh physical restraint, by a papoose board or auxiliary personnel, was not needed to overcome persistent behavioral interference. The occurrence of infrequent and transient episodes of misbehavior or reflex-type behavior, necessitating only brief intervention, was not construed as an indication of an inadequate level of sedation. Similar distinctions were made with respect to the need for mouth props to maintain oral access under conditions of behavioral resistance vs patient fatigue. While the use of harsh restraints may be considered necessary and appropriate in some emergency medical situations, its appropriateness for lengthy dental procedures is unclear. For the purpose of this retrospective study, this issue was considered beyond the study's scope.

### STATISTICAL METHODS

For the purpose of data analysis, the study population was divided into two groups on the basis of whether nitrous oxide was used. Within each of the nitrous and nonnitrous groups, four subgroups were evaluated on the basis of the amount of chloral hydrate received and whether meperidine was administered. Two outcomes were considered for each patient:

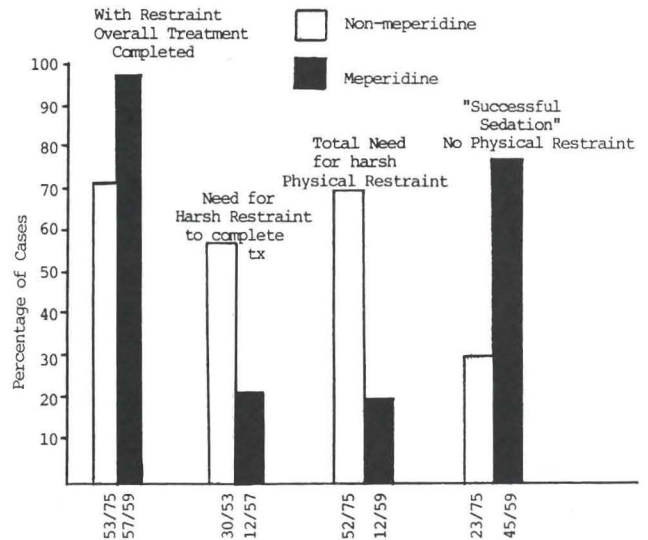


Figure. Overall comparison of chloral hydrate plus hydroxyzine with and without the use of meperidine.

- The absence of the need for harsh restraint to complete treatment and
- Whether treatment was completed (regardless of restraint needed).

The number positive or negative for each of the outcome measures were compared for each of the four drug subgroups within the nitrous and nonnitrous conditions. The four sets of comparisons were made, using the log likelihood ratio test for contingency tables.<sup>19</sup> The statistic calculated has an approximate chi-square distribution with three degrees of freedom. For those comparisons with P-values less than 0.05, selected comparisons of the proportions from the four subgroups, positive for an outcome measure, were made using an extension of Tukey's multiple comparison method for means in an analysis of variance setting.<sup>19</sup>

### RESULTS

Comparisons illustrated in the Figure depict the frequency with which treatment was completed with and without meperidine, and the extent to which harsh physical restraint was necessitated. Overall, regardless of the chloral hydrate dosage, sedation was 45.6 percent more successful (defined by an absence of persistent interfering behavior) when meperidine was added. Similarly, the need for harsh restraint to complete treatment was 35.6 percent less when meperidine was used.

Breakdown of the therapeutic success of the manufac-

Table 1 □ Therapeutic success of manufacturer's and higher doses of CH with and without meperidine and N<sub>2</sub>O.

	Group	Total number	Number of successful sedations (No restraint)	Percent	Total no. completing treatment (Restraint included)	Percent
Without N <sub>2</sub> O	50 mg/kg w/mep	10	6	60.0	10	100.00
	50 mg/kg	12	1	8.33	10	83.33
	70 mg/kg w/mep	9	9	100.00	9	100.00
	70 mg/kg	13	3	23.08	11	84.62
With N <sub>2</sub> O	50 mg/kg w/mep	32	24	75.00	30	93.75
	50 mg/kg	28	7	25.00	19	67.86
	70 mg/kg w/mep	8	6	75.00	8	100.00
	70 mg/kg	22	12	54.55	13	59.09

turer's and higher doses of CH with and without meperidine are found in Table 1. The total number of patients in each of the four subgroups, under conditions with and without nitrous, are shown. In addition, the number positive and associated proportion is given for each of the outcome variables.

Only the results for the nonharsh restraint outcome showed significant differences with a P-value less than 0.05: for subjects not receiving nitrous oxide,  $0.01 < P < 0.05$ , and for the nitrous condition,  $0.25 < P < 0.05$ ; for the treatment-completed outcome (restraint included),  $P > 0.3$  for the nonnitrous and  $0.05 < P < 0.10$  for the nitrous condition.

For the no-need-for-harsh-restraint outcome (successful sedation), five pairwise comparisons of proportions were considered important. The comparisons and the results (S for significant, and NS for nonsignificant) for each group are given in Table 2 (results with a P-value  $< 0.05$  were considered significant).

### Impact of meperidine

In comparison 1, no differences were observed between the 50 mg/kg and the 70 mg/kg doses of CH. While poor success with the manufacturer's dose is not surprising, the negligible improvement with the higher dose was unexpected and falls short of success rates previously reported. The data suggest, if meperidine is not being added, better results may be expected using the higher CH dose supplemented with nitrous oxide. On the other hand, a 55 percent success rate is inadequate from either a clinical or statistical perspective.

The potentiating effects of meperidine added to the 50 mg/kg CH (comparison 2) showed a statistically significant improvement, with or without nitrous oxide. The importance of this finding is further enhanced by the results of comparison 5. The data strongly suggest that the addition of meperidine to the 50 mg/kg dose produces more consistent and effective sedation than selection of the higher dose alone.

Comparison 3 suggests that there were no differences between CH doses with meperidine when nitrous was

needed; when nitrous was not needed, the higher dose with meperidine yielded better results. Although the implication is that the greatest success rate occurs with the latter, caution must be taken in accepting this premise on the basis of the limited samples. The potential benefit of the higher dose – meperidine combination for the extremely refractory patient, unresponsive to trials using the 50 mg/kg dose, warrants, however, further study.

A puzzling inconsistency occurs in comparison 4. In the nonnitrous condition, the effect of meperidine appears substantial, 9/9 vs 3/13. With nitrous oxide, although better with meperidine, the margin between the CH doses, however, was low. One explanation, other than small samples, relates to the criteria under which nitrous was used, i.e. when medications themselves were inadequate. These subjects appeared to manifest the highest levels of anxiety and resistance, and as such, may have been resistant to the dosages. Nine of twenty-two subjects receiving 70 mg/kg CH without meperidine and nitrous oxide were unmanageable, even with considerable restraint applied. Seven of the nine, however, were successfully treated when meperidine was added, while only two required general anesthesia.

### Incidence of adverse reactions

Except for four episodes of vomiting, immediately following initial administrations of oral agents, there were

Table 2 □ Comparison of therapeutic success of the sedative regimens.

Comparison	With N <sub>2</sub> O	Without N <sub>2</sub> O
1. 50 mg/kg CH (no meperidine) vs 70 mg/kg CH (no meperidine)	S	NS
2. 50 mg/kg CH with meperidine vs 50 mg/kg CH (no meperidine)	S	S
3. 50 mg/kg CH with meperidine vs 70 mg/kg CH with meperidine	NS	S
4. 70 mg/kg CH with meperidine vs 70 mg/kg CH (no meperidine)	NS	S
5. 50 mg/kg CH with meperidine vs 70 mg/kg CH (no meperidine)	S	S

S = statistically significant (P4nl.05) NS = nonsignificant

no additional episodes of nausea or vomiting, or detectable loss of protective reflexes. No episodes of respiratory depression or obstructions, or cardiovascular changes were observed.

## DISCUSSION

### Need for a more predictable and effective oral regimen

The findings of this study are consistent with the observations of several clinicians who report frequent failure with the manufacturer's recommended 50 mg/kg dose of CH with hydroxyzine (or promethazine) for refractory young children. In view of the acknowledged limitations encountered with the oral route (e.g. variable absorption due to stomach contents, partial drug inactivation through the hepatic-portal circulation, or "first-pass" metabolism), these findings are not surprising. Factors often underemphasized for their contributions to the variable responses to sedation include the patient's emotional state, basal metabolic rate, and degree of resistance. The availability of drug-response curves that reflect heightened levels of child anxiety would contribute greatly to our ability to select dosages which produce adequate sedation with greater frequency. From the medical trials reported, there appears to be little reluctance to use CH dosages in the range of 80-100 mg/kg, to achieve adequate sedation for procedures that may be less invasive and shorter in duration.

The hypnotic dose of CH should only be expected to induce sleep for an essentially compliant individual; as such, the low success using the manufacturer's recommended dose on highly resistive subjects in this study was not unexpected. Evidence, therefore, appears to exist in support of Trapp's suggested 50-70 mg/kg dosage guideline (when used without meperidine).<sup>3</sup>

In this study, the 75 percent and 91 percent failures of the 50 mg/kg dosage, with and without nitrous oxide, respectively, support the extent to which subjects were difficult to manage. Studies reporting relatively good success with lower doses of chloral hydrate or placebos, suggest that the subjects selected varied widely with respect to levels of anxiety and actual need for sedation. Studies whose primary focus is to establish dose-responses must incorporate a selection criterion that is both valid and specific to the agent(s) used and depth of sedation sought. This retrospective analysis attempted to apply a simplified patient selection criterion, to minimize inclusion of insufficiently resistive subjects. Prospective studies that further define behavioral selection

and subjects at random are needed.

Given the high frequency of failure in the use of the 50 mg/kg dose for very difficult young children, the interpretation of drug responses and the judgment necessary to take corrective action become critical. Often, characteristic of an inadequately sedated child with CH, is a paradoxical state of agitation, which can persist beyond the latent period. On almost all occasions, this is due to an underdose rather than overdose. In many cases, the child can appear well-sedated and somnolent until intra-oral stimulation (e.g. placement of a mouth prop, topical or local anesthesia, rubber dam clamp, or cavity preparation) at which point, awakening and persistent agitation result, frequently exceeding predrug levels of resistance. At this juncture, either more or less drug is needed or a decision is made to abort treatment and reschedule, using alternate dosages, agents, or another modality altogether. Frequently the latter is necessitated by virtue of the impracticality of having an agitated patient ingest additional medication or the time associated with further delay in onset.

In electing to increase the CH dosage, the practitioner faces a dilemma. On one hand, in exceeding the manufacturer's recommendation, the clinician may be subject to criticism, should an adverse reaction or complication result. On the other hand, an insufficient dosage results in inadequate treatment of the patient. It seems logical, however, that documentation of a patient's inadequate response to a recommended dose would serve as justification for selecting a higher dose. Under these circumstances, oversedation resulting from a reasonable upward adjustment in dosage is unlikely. Nevertheless, although remote, this possibility should never be ruled out.

Reluctance to exceed manufacturer's dosage recommendations, however, may be cause to abandon the oral route for a parenteral or unconscious technique. As the use of parenteral techniques within an office setting is becoming cost prohibitive from escalating liability insurance coverage, many practitioners are opting for treatment in a hospital setting rather than considering an IM, IV, or submucosal technique in their offices. For families unable to incur expenses associated with the hospital or general anesthesia, the need for a safe and effective oral sedation regimen is of paramount importance.

This study focused on oral agents with well-established ranges of safety, used in combination, to circumvent the limitations of chloral hydrate-hydroxyzine for unmanageable children. Despite the limitations of oral administration, its ease and relative safety (assuming adequate training and appropriate judgment), warrant

continued study, to develop more predictable regimens and dosage schedules for the refractory child.

### Effect of nitrous oxide

An objective of this study was to examine the benefit of adding nitrous oxide as a potentiating agent, when oral medications alone were inadequate. A logical clinical question is whether its addition is a better alternative to either increasing CH dosage or adding meperidine. Since wide variation in patient response to different concentrations of nitrous oxide occurs, the use of fixed concentrations of inhalant was avoided. In this manner, the opportunity to avoid either excitement (from excessive concentrations) or underdosage (from inadequate concentrations) was maximized. Subgrouping of nitrous and nonnitrous visits was expected, therefore, to circumvent difficulties in assessing specific responses to drug and dose.

As described in the preceding section, nitrous oxide was found beneficial, when meperidine was not used. In view of nitrous oxide's relatively weak potency (MAC - 100 percent),\* this is not surprising. Nevertheless, if by the addition of a titrable agent, such as nitrous oxide, adequate sedation was achieved, the need for another nontitrable oral agent (such as meperidine) would be offset. The data do not appear to suggest, however, that the addition of nitrous is superior to adding meperidine.

### Depth of sedation

Continuous monitoring and assessment of the depth of sedation of the patient receiving hypnotic doses of CH is essential. Although preferable to maintain a conscious state that readily permits oral communication, this objective is often not achievable with nontitrable agents; the onset of somnolence is more the rule than the exception, when using hypnotic doses of CH. Although it might be argued that this level of depressed consciousness does not differ significantly from the unmedicated child patient who falls asleep during treatment, induction of somnolence mandates careful and continuous patient monitoring. This point cannot be overemphasized, and it is imperative that the dental office be properly equipped and that the practitioner and staff be competent in the management of the airway of the se-

dated or unconscious patient. The extent to which the patient is arousable and the appropriateness of his response to physical stimulation or verbal command are determinants of whether classification falls under "conscious" vs "deep sedation."<sup>20,21</sup>

At present, objective data are needed to identify a reasonable upper limit in CH dosage on a mg/kg basis for young, difficult children. One study reported that four of fifteen subjects, when intentionally obstructed, were unable to self-maintain a patent airway with dosages of 60 mg/kg CH with 40 percent nitrous oxide.<sup>10</sup> Under conditions where subjects are not particularly apprehensive or difficult, it is conceivable, if not likely, that this regimen could cause oversedation. The extent to which many of the subjects in this study were manageable by nonpharmacologic means or low doses of CH supports this premise.<sup>10</sup> The 46 percent, 40 percent, and 27 percent success rates reported with a placebo, 20 mg/kg, and 40 mg/kg doses of CH, respectively, strongly suggest a large number of subjects were insufficiently anxious to warrant medication at the outset.

Recently attention has been directed at a need for improved research design and sophistication in studies involving child dental anxiety and management.<sup>22-24</sup> An issue not adequately addressed in the design of pharmacologic studies in children relates to the definition of the criteria used in the selection of subjects who would make it possible to make objective assessments of drug efficacy. If subjects do not manifest sufficient pretreatment resistance to anxiety, greater success is to be expected, when lower medication doses are administered; further conclusions to be drawn with respect to recommendations for a dosage schedule will fall seriously short for the unmanageable child. Following this scenario, warnings related to what might constitute upper limits of dosage will be unwarranted. Alternately, the application of appropriate selection criteria alone does not excuse or preclude negligent or incompetent judgment with respect to use of excessive dosages or drug combinations. Case studies reporting morbidity and mortality records of dentists employing irresponsible doses of narcotics, in addition to their grossly exceeding toxic doses of local anesthetics, have justifiably focused attention on the need for closer regulation of the use of sedation in dental practice. Sensationalization of isolated instances involving inadequately trained and inexperienced practitioners, does affect, however, those who are competent users of sedation. Nevertheless, all possible precautions for the use of conscious and deep sedation, in conformity with accepted guidelines must be taken, to assure patient safety.<sup>20,21</sup>

\*MAC Minimum alveolar concentration. A measure which reflects the relative potency of anesthetic agents as the concentration at which 50 percent of the population is rendered unconscious and unresponsive to noxious stimulation.

## Recovery

An issue not addressed by the present study was the effects of the proposed regimens on duration of action and recovery. The point at which the patient safely can be discharged to the custody of an untrained individual (parent) after having received the proposed regimens warrants further study.

Needed is an oral regimen with greater efficacy than 50 mg/kg CH and which provides adequate working time and minimal recovery time. At present, only parenteral techniques offer opportunity for controlling working time and recovery. Assuming that few practitioners will be able to accept the three-to-five-fold increases in liability coverage associated with the infrequent use of office parenteral sedation, it seems reasonable to expect that the only remaining viable management choices include harsh physical restraint or general anesthetics. Where parents object to restraint or financial considerations preclude hospital management, both dentist and family face a dilemma.

As chloral hydrate dosage is increased it seems logical to expect concomitant increases in recovery time. Even at the 50 mg/kg dose, it is not uncommon for a child, if left unstimulated, to fall asleep for several hours after treatment has been completed. Although CH sedation sufficient for treatment dissipates after approximately 1 to 1.5 hours, its residual sleep-inducing properties represent a distinct disadvantage to this modality. Rather than prolong recovery further by increasing CH dosage, the addition of low doses of oral meperidine was expected to potentiate the chloral hydrate, sufficiently, to overcome resistive behavior; yet be metabolized within a shorter period, to permit more rapid recovery. Based on preliminary observations, subjects receiving 50 mg/kg doses CH appeared more easily arousable and ambulatory sooner than the higher dose subjects. Further study is needed to clarify these observations.

## SUMMARY AND CONCLUSIONS

This study attempted to examine the impact of low doses of meperidine on the effectiveness of two doses of CH for management of highly resistive young pediatric dental patients. The results suggest patient manageability was enhanced by the addition of oral meperidine. As an alternative to a parenteral technique or general anesthetic, the clinician may wish to consider this regimen after having experienced failure of CH either alone, or in combination with an antiemetic, to produce an adequate level of sedation.

The extent to which application of physical restraint is considered necessary or acceptable should be taken into account, when evaluating the need for a regimen of medication. If the purpose of selecting a sedative technique is to accomplish lengthy treatment without harsh restraint, the degree to which restraint is needed no doubt reflects on the adequacy of the sedative regimen. The addition of meperidine was found to reduce significantly the need for persistent harsh physical restraint, to allow treatment of the refractory young child. While the brief application of harsh restraint measures may be warranted and justifiable in emergency medical situations, it seems unwise to make use of harsh restraint for lengthy elective dental procedures. Given the extent to which many adults report negative childhood dental experiences, avoidance of the use of aversive measures seems desirable. Of the cases receiving meperidine, 76.3 percent were treated successfully (no need for persistent restraint), compared to the successful treatment of only 30.7 percent of the patients sedated without meperidine. Although nine of nine visits using the 70 mg/kg dose of CH and meperidine were successful, further study is indicated, to determine the need for the higher dose, when meperidine is added. From a statistical point of view, the results suggest that use of the higher CH dose may not be warranted, when meperidine is included. Until additional controlled studies involving greater sample population and blind conditions are conducted, use of the higher dose with meperidine should likely be limited to cases where inadequate sedation is achieved with the 50 mg/kg dose and meperidine.

Also, further study of the elements of recovery should be undertaken to guide clinicians in the safe and effective use of this sedative combination for the refractory young child.

## REFERENCES

1. Duncan, W.K.; Ashrafi, M.H.; Pruhs, R.J. *et al*: Chloral hydrate and other drugs used in sedating young children: a survey of the American Academy of Pedodontic Diplomates. *Pediatr Dent*, 5:252-256, 1983.
2. Physicians' Desk Reference, 40th Edition. Oradell, N.J.: Medical Economics, pp 1569, 1606, 1754, 1986.
3. Trapp, L.: Pharmacologic management of pain and anxiety, in *Pediatric Dentistry*. Steward, Barber, Troutman, and Wei, eds. St. Louis: C.V. Mosby, pp 810-832, 1982.
4. Kopel, H.M.: An update on anxiety and pain control in dentistry for children. *Alpha Omegan*, 72:25, 1979.
5. Robbins, M.B.: Chloral hydrate and promethazine as premedicants for the apprehensive child. *J Dent Child*, 34:327-331, September, 1967.
6. Tobias, M.; Lipschultz, D.H.; and Album, M.: A study of three pre-operative sedative combinations. *J Dent Child*, 42:453-459, November, 1975.



7. Sheskin, R.B.; Desjardins, P.; Houpt, M. *et al*: Assessing chloral hydrate dosage for young children. *J Dent Res*, (Abstract), 62:198, March, 1983.
8. Houpt, M.; Koenigsberg, S.; Weiss, N. *et al*: A comparison of chloral hydrate with and without promethazine in the premedication of children. *J Dent Res* (Abstract), 63:223, March, 1984.
9. Houpt, M.; Koenigsberg, S.; Weiss, N. *et al*: A comparison of chloral hydrate with and without promethazine in the premedication of children. *Pediatr Dent* (Abstract), 6:176, September, 1984.
10. Moore, P.A.; Mickey, E.; Hargreaves, J. *et al*: Sedation in pediatric dentistry: a practical assessment procedure. *JADA*, 109:564-569, October, 1984.
11. Houpt, M.; Sheskin, R.; Koenigsberg, S. *et al*: Assessing chloral hydrate dosage for young children. *J Dent Child*, 52:364-369, September, 1985.
12. Davis, H.: Sedation of young children for electric response and audiometry. *Audiology*, 12:55, 1973.
13. Houser, O.W.; Baldwin, J.; Gomez, M. *et al*: Evaluation of intracranial disorders in children by computerized tomography. *Neurol*, 25:607-613, 1975.
14. Judisch, G.F.; Andreasen, S.; Bell, E.: Chloral hydrate sedation as a substitute for examination under general anesthesia in pediatric ophthalmology. *Am J Ophthalmol*, 89:560-563, 1980.
15. Thompson, J. *et al*: The choice of sedation for CT in children: a prospective evaluation. *Neurorad*, 143:475-479, 1982.
16. Nathan, J.E.: Management of the refractory young child with chloral hydrate: dosage selection. *J Dent Child*, 55:93-100, March-April, 1987.
17. Nathan, J.E. *et al*: The role of chloral hydrate in pediatric dental sedation. *U.S. Pharmacist* (Hospital edition), 12:52A-52H, December, 1986.
18. Moore, P.A.: Therapeutic assessment of chloral hydrate premedication in pediatric dentistry. *Anesth Progr*, 31:191-196, 1984.
19. Zar, J.H.: *Biostatistical analysis*, 2nd ed. Englewood Cliffs: Prentice Hall, Inc., 1984.
20. American Academy of Pediatric Dentistry and American Academy of Pediatrics: Guidelines for the elective use of conscious sedation, deep sedation, and general anesthesia in pediatric patients. *Pediatr Dent*, 7:334-337, December, 1985.
21. N.I.H.: Consensus development conference statement on anesthesia and sedation in the dental office. *JADA*, 111:90-93, July, 1985.
22. Fields, H.W.: Research methods, issues, and directions in behavioral management of the child dental patient. *Anesth Progr*, 33:23-24, 1986.
23. Moore, P.A.: Pharmacologic research and methodologic needs for child dental patients. *Anesth Progr*, 33:40-43, 1986.
24. Weinstein, P.: Integrating behavioral methodologies into dental pharmacological research. *Anesth Progr*, 33:55-59, 1986.

The procedures, possible discomforts or risks, as well as possible benefits were explained fully to the human subjects (parents or guardians) involved, and their informed consent was obtained prior to the investigation.

Acknowledgement: The authors wish to express their appreciation to Dr. Irwin Seidman and the graduate students in pediatric dentistry from the University of Illinois who assisted in the collection of data for this study.

---

## NEONATAL ANESTHESIA

There is an increasing body of evidence that neonates, including those born preterm, demonstrate physiologic responses to surgical procedures that are similar to those demonstrated by adults and that these responses can be lessened with anesthetic agents. Other studies have suggested that stability of variables such as blood pressure, heart rate, and oxygenation is important in reducing complications such as intraventricular hemorrhage or pulmonary hypertension. There is also increasing evidence that neonatal cortical function is far greater than previously thought and some suggestion that short-term behavior may be affected by prior painful stimuli.

The Committee on Fetus and Newborn, The Committee on Drugs, the Section on Anesthesiology, and the Section on Surgery believe that local or systemic pharmacologic agents now available permit relatively safe administration of anesthesia or analgesia to neonates undergoing surgical procedures and that such administration is indicated according to the usual guidelines for the administration of anesthesia to high-risk, potentially unstable patients. In occasional situations, physiologic instability will be so great that the anesthetic agents must be reduced or discontinued. However, the decision to withhold such medication should be based on the same medical criteria used for older patients. The decision should not be based solely on the infant's age or perceived degree of cortical maturity.

*Pediatrics*, 80:446, September, 1987.

---

# Optimum dosage for prenatal fluoride supplementation (PNF): Part IX

## Prenatal fluoride

**Frances B. Glenn, DDS**  
**William Darby Glenn III, MD**

**I**n 1980, the American Dental Association (ADA)-National Institute of Dental Research (NIDR) symposium concluded that some benefit of caries prevention accrues to the primary teeth when the fetus is supplied with fluoride.<sup>1-3</sup> In 1982, a survey for the ADA found that U.S. dentists, by a ratio of almost 2:1, thought fluoride supplementation should start in pregnancy rather than at birth.<sup>4</sup> As a result of lectures given in Europe by the senior author in 1983, the major brands of fluoride tablets sold on the continent are now labeled for use in pregnancy. Fitzgerald recently found prenatal fluoride effective in reducing caries in an animal model.<sup>5</sup> At the 1986 International Association of Dental Research (IADR) meeting Professor Gedalia, of the Hadassah Dental School in Jerusalem, announced that he recommends prenatal fluoride in his lectures and that his review of the literature of the 1950s and 1960s found that the evidence for the efficacy of prenatal fluoride already existed. As of the first quarter of 1987, NIDR's 585 prenatal-fluoride children in Maine are one to three years old. These developments make it appropriate that we explore the subject of optimum prenatal fluoride dosage. The review of the literature is organized according to six relevant topics.

---

Dr. Frances Glenn is in the private practice of pediatric dentistry and orthodontics in South Miami, Florida. Dr. William D. Glenn, III, is in the practice of otolaryngology in South Miami, Florida.

## **WHY FLUORIDE TABLETS CONTAIN 1 MG OF FLUORIDE**

In 1938-42, Dean surveyed caries and fluorosis in the permanent teeth of children twelve to fourteen years old, in twenty-one Western towns with varying amounts of fluoride (F) in the water. The greatest number of caries-resistant teeth was found in areas of 1.7 to 2.5 parts per million (ppm) F in the water; but, as there was some significant fluorosis in the permanent teeth in those communities, Dean chose Aurora, Illinois, with 1.2 ppm F as his ideal.<sup>6-8</sup> When fluoridation began in 1945 in Newburgh and Grand Rapids, the concentration was reduced to 1 ppm. It was assumed that children three years of age and older drank a liter of water a day, which would provide 1 mg of fluoride. Tablets were then made with 1 mg of fluoride (2.2 mg NaF) for the use of children three years of age and older, in nonfluoridated areas. It is essential that we understand that 1 ppm is a conservative estimate of the limit of concentration of fluoride that should be in water utilized by infants and children from birth. The 1 ppm derivative, 1 mg, is the limitation of daily postnatal dosage for children from age three. What Dean and others found was that utilization of water with between 1.2 to 2.3 ppm F postnatally will result in some undesirable mottling in the permanent teeth of some of the children. One mg may well be the optimum dosage for a 35 lb (16 kg) three-year-old, but it does not necessarily follow that it is the correct amount to give a 135 lb (60 kg) mother-to-be, in order to deliver the optimum dose to the fetal teeth.

## **1 PPM OF FLUORIDE AND PRIMARY TEETH: EARLY STUDIES**

### **The H. Trendley Dean studies**

Dean, in 1938, compared caries and fluorosis in nine-year-olds' primary and permanent teeth in towns with 0.6 to 1.5 ppm F and with 1.7 to 2.5 ppm F.<sup>6</sup> As seen in Table 1, he found almost twice the improvement in primary teeth, when comparing higher fluoride with lower fluoride communities.<sup>7,8</sup> Note that Dean's lower fluoride areas equal and exceed the levels used in fluoridation. The two percent fluorosis in the primary teeth was due to some second primary molar mottling in three of the fifty-four children from Colorado Springs (2.5 ppm). Many persons had already noted the lack of fluorosis in the primary teeth, but this was the first evidence that primary teeth might benefit more from a higher dose of fluoride than would the permanent teeth.

### **The F.A. Bull studies**

Bull, in 1949, reported caries surveys done in Wisconsin communities with different amounts of natural fluoride in the water (Table 2).<sup>9</sup> Bull concluded that 1 ppm F was almost as beneficial for the permanent teeth as was 2 ppm F but that the primary teeth required 2 ppm F.

### **The O. Backer Dirks studies**

Backer Dirks, in 1958, examined the results of fluoridation at 1 ppm F, in Tiel in the Netherlands: he found less benefit for the occlusal surfaces of the primary and first permanent molars and concluded, "Especially for the fissures of first permanent molars and deciduous molars, one would expect a decreased inhibition as these teeth are formed and partly calcified in a period of small fluoride uptake by the fetus and young child (pregnancy and lactation)."<sup>10</sup> Unfortunately, he failed to suggest that the deficiency be corrected by tablet supplementation, as by that time, 1 ppm F was regarded as the inviolate "optimum" on both sides of the Atlantic.

These early observations by Dean, Bull, and Backer Dirks suggested that a larger dose was required by the primary teeth and first permanent molars, and seemed to confirm the concept of a partial placental barrier for fluoride. The studies are valuable as they were performed before the general availability of post-eruptive topical fluorides.

### **Fluoride content of fetal teeth in relation to maternal F exposure**

There are two reports concerning the change in fluoride content of fetal teeth, just on the basis of prenatal exposure. Martin, as part of the Evanston fluoridation study, found that a ten-fold increase in the fluoride concentration in the maternal drinking water was associated with a 5.5-fold increase in the fluoride content of the fetal teeth.<sup>11</sup> Gedalia, in Israel, found that a six- to ten-fold increase in maternal F H<sub>2</sub>O was reflected by a 1.7-fold increase in the fluoride in fetal teeth.<sup>12</sup> These studies found that maternal fluoride, rather than being delivered to the fetus on an exact weight related basis, experienced an additional 50 to 80 percent loss.

### **The apparent "placental barrier" and maternal fluoride loss**

In 1962, Ericsson demonstrated that there was no placental barrier for fluoride in humans and by 1980 this fact

was generally acknowledged by the dental community.<sup>2,13</sup> If there is no barrier, what accounts for the observations that made it seem that there was a partial barrier? Several factors have been identified.

- Maternal dilution. Fluoride is rapidly cleared from the maternal plasma by dilution in up to 40 liters of extra- and intracellular fluid.
- Renal excretion. Twenty percent of maternal blood flow goes to the kidneys, the main organs of fluoride excretion, while only 10 percent goes to the placenta at term. Thus the mother-to-be is excreting fluoride twice as fast as she is allowing it to interface with the fetal circulation.
- Maternal bone uptake. Only slightly less rapid than renal excretion is the incorporation of fluoride into the much larger mass (compared to the fetus) of maternal metabolizing bone. This is termed the maternal fluoride deficit.

Since reviewers have only recently rid themselves of the conception that a placental barrier exists, the above phenomena should be referred to as the maternal loss of fluoride. Although there might have been reason to think there was a placental barrier, in the 1930s, starting with Smith and Smith in 1935, and culminating with Martin in 1948 and Gedalia in 1964, there was no reason to think of it other than a partial barrier.<sup>11,12,14</sup> Those in authority at that time felt that the way to deal with a partial barrier was to withhold the essential nutrient involved. This action was contrary to established principles of nutrition in which evidence for limited passage, as with iron, is regarded as a mandate for supplying more. Possible reasons for this action have been alluded to in previous papers.<sup>15-18</sup> In any case, it seems obvious that pregnancy requires a different dose of fluoride.

#### DETERMINATION OF THE OPTIMUM PRENATAL DOSE OF FLUORIDE

To find the best dose of fluoride we must examine the same factors for the fetal teeth as Dean used for the permanent teeth: caries reduction and fluorosis.

#### Minimum effective dose for caries reduction

The smallest prenatal dose to show efficacy was the presumed 1 mg/day fractionated dose ingested in 1 ppm F H<sub>2</sub>O in the water fluoridation studies. One of these, with less than sixty children per cohort, failed to detect any positive effect.<sup>19</sup> Six others (Arnold and Dean, Blaney and Hill, Tank and Storvick, Soricelli, Horowitz and Heifetz, Lewis) showed a 9 to 35 percent benefit for

Table 1 □ Dean's study of caries and fluorosis in the primary and permanent teeth in lower and higher fluoride communities.

Condition of teeth	Percentage of children	
	0.6-1.5 ppm	1.2-2.5 ppm
Caries-free primary teeth	9	31 (3.4 times as many)
Caries-free permanent teeth	26	49 (1.9 times as many)
Fluorosis	none to questionable	53 (permanent teeth) 2 (primary teeth)

Table 2 □ Bull's report on caries in the permanent and primary teeth in Wisconsin towns with naturally fluoridated water.

ppm F/H <sub>2</sub> O	DMF* 13-year-olds	def** 5 to 6-year-olds
0.05	9.0	4.7
1.0	2.9	2.8
1.2	2.6	2.7
1.5	2.9	2.5
1.8	2.8	1.9
2.0	2.6	1.1
2.3	2.7	1.3

\*decayed, missing, filled permanent teeth  
 \*\*decayed, extracted, filled primary teeth.

the primary teeth.<sup>20-25</sup> In addition, Horowitz found a 23 percent benefit for the first permanent molars at age seven. Often included in these lists, the studies at Lemke *et al.*, and Grainger and Coburn, do not address the effects of prenatal fluoride.<sup>26,27</sup> The report of Katz and Muhler is so seriously flawed that NIDR had serious reservations concerning its validity and Stamm felt it should be disregarded.<sup>1,28,29</sup>

#### Larger effective prenatal dose of fluoride

The next level of dosage is found in the ten prenatal tablet studies.<sup>15-18, 30-38</sup> Most of these utilize 1 mg of F/day with the pulse tablet dose presumably overcoming some of the maternal loss. Pritchard's study involved 1 mg for the last trimester only. Martin and other Australians used 1.5 mg/day for the last two trimesters, while Light and Bibby used 1.5 mg/day dissolved in milk.<sup>33,35,37,39</sup> The higher dose: the author's 1 mg supplement in addition to the presumed 0.7 to 1.0 mg/day derived from fluoridated water for a total dose of 1.7 to 2 mg/day. Although most of the studies involved some exposure to postnatal fluoride also, they all show efficacy from prenatal fluoride with many obtaining virtual elimination of caries in the resultant teeth. Our series, with over 1,000 prenatal fluoride children, some followed up to twenty-three years, maintains a 99 percent reduction in caries with 98 percent of the children never having had a cavity and less than 5 percent needing sealants.

### Larger-dose prenatal studies

Some information might be gained from study of caries statistics from higher fluoride areas, but it is almost impossible to separate prenatal from postnatal effects. It really does not matter how caries-resistant primary teeth are in communities with 6, 10, or 21 ppm of fluoride in their water, as the limitation of prenatal fluoride dosage has been determined by the same criterion used by Dean, the fluorosis index.

### Prenatal fluoride and fluorosis of the primary teeth

We all recognize that fluorosis can be caused by exposure to excessive fluoride during any phase of tooth development, from early secretory to mature preeruptive mineralization. While observations concerning primary tooth fluorosis are of interest, the anterior teeth best reflect prenatal exposure when the child is nursed for at least six months, as it is known that the posterior primary teeth can become fluorotic by exposure to postnatal F from water with 2.5 ppm F and above.<sup>17</sup> Fluorosis of primary teeth is always mildest in the anterior teeth. Dean's index is used: 0 is normal; 0.5 is questionable; 1 is very mild (small dots less than 25 percent of surface); 2 is mild (small dots more than 25 percent of surface); 3 is whole surface; 4 is severe—brown with pits. Fluorosis is always symmetrical; a distinct white spot on one or two central incisors is hypomineralization, however, often due to high fevers in infancy.

McKay, who in 1916 said that fluorosis was never found in the primary teeth, had, by 1932 changed his opinion to, rarely, only in the molars, and only slightly. Smith and Smith in Arizona, in 1935, found moderate fluorosis in the incisors and severe in the molars, in areas with 12 to 18 ppm F in the water.<sup>14</sup> Here was the origin of the opinion that there was a placental barrier to low concentrations of fluoride, but not for amounts of over 10 mg/day. Babeaux and Zipkin reviewed the pre-1966 literature and concluded that it required 4.5 ppm and above to cause fluorosis in posterior primary teeth.<sup>40</sup> Forsman reported on caries and fluorosis in small towns in Sweden with 5.5 and 10 ppm F H<sub>2</sub>O.<sup>41</sup> She found that breast feeding more than six months largely protected the primary teeth from fluorosis. The 10-ppm area did have some severe fluorosis in the molars, but nothing more than grade 0 to 2 for the incisors.

Of the five areas studied, only the primary teeth of the children born in Gadderas, a 10-ppm community, were all caries-free. The 5.5-ppm area is interesting in that

there was grade 3 or 4 fluorosis in the primary canines of molars of 29 percent of the children whose mothers were long-time residents of the area; but nothing more than grade 2 in any of the primary teeth of those whose mothers had lived in lower fluoride areas before becoming pregnant. This suggests that we can expect no significant fluorosis in the primary teeth of a child whose mother lived in a lower fluoride area and ingested 5 mg of fluoride a day while pregnant.

Thylstrup studied fluorosis in Tanzania, in 1978, in primary teeth, in areas of 3.5, 6, and 21 ppm F H<sub>2</sub>O.<sup>42</sup> We must be cautious in translating the results from such areas, which are often calcium deficient. Prodigious water intake, and altitude have also been reported to increase the grade of fluorosis seen, but this study is worth reviewing as it is clearer, unlike many reports, exactly which tooth is being graded. The incisors in the 3.5-ppm-F and the 6-ppm-F areas were grade 1, very mild. The incisors were generally grade 3 in the 21-ppm-F region, but very few showed any signs of pit formation. Thylstrup was surprised by this and by the absence of anything more than very mild flecks in the incisors, in the 6-ppm-F area, and said that fluorosis can be difficult to see in direct sunlight. Our view would be that if you cannot see it, it is not significant. The authors of this paper spent several weeks in the same 3.5-ppm-F area of Arusha, in summer of 1980, and found all the permanent teeth fluorotic with about 80 percent severely so. We could find no mottled anterior primary teeth.

### DISCUSSION

Since dental caries resistance improves with increasing amounts of fluoride, even at levels associated with mild and moderate fluorosis, the definition of optimum fluoride supplementation is the most fluoride that can be ingested on a daily basis without causing fluorosis.<sup>43</sup> For prenatal fluoride, it seems that 5 mg/day or more are required to cause even mild fluorosis objectionable to most people. Since the authors wish to be especially conservative in pregnancy, even when dealing with a substance long recognized to be an essential trace element, we can estimate the optimal daily fluoride supplement in pregnancy to be 4 mg/day.<sup>44,45</sup> In fluoridated areas, we assume 0.5-1 mg from dentifrice and rinses. A supplemental 2 mg tablet (4.4 mg NaF), therefore, seems appropriate. The only exception might be the less than 1 percent of the population who live in areas with over 2 ppm F H<sub>2</sub>O.

Fluoride is unique among the essential trace minerals

in that it is mostly bound in foods and is bioavailable in its ionic form in water and as a sodium fluoride supplement. The fluoride content of the food in rural areas with high fluoride concentrations as presented by Forsman would be expected to be far greater than in any fluoridated community in this country. Only in some Asian areas where children eat large quantities of seafood has some fluorosis been produced, but there is no evidence that this occurs in gestation, because a large part of the fluoride ingested by the mother is excreted normally or assimilated by her. Similarly, there have been cases of delayed fluorosis in later developing teeth in children who moved to a lower fluoride area, after living several years in an endemic fluorosis locality; but there are no reports of that happening with gestation. Again, this is due to the maternal loss mechanism, formally known as the placental barrier.

The authors have achieved remarkable results in a fluoridated area with just 1 mg of prenatal fluoride, but these mothers have benefited from our personal instruction to take it on an empty stomach, not followed by a meal for thirty to sixty minutes, to start by the 10-12th week, not to take the prenatal fluoride with the prenatal vitamin-mineral capsule with its fluoride-binding calcium, etc.<sup>46</sup> As a public health measure, 2 mg prenatal fluoride/day could be used to attempt to immunize 100 percent of children's teeth rather than the author's present 98 percent. Should women in unfluoridated areas take 3 or 4 mg F/day? There would be nothing wrong with it, but it is probably unnecessary. Two mg F should be regarded as the minimum dose for unfluoridated, fluoride-deficient areas, though, because of the maternal deficit. Several years ago a study was published from a New Haven teaching hospital showing that pediatric residents had great difficulty remembering the postnatal fluoride supplementation schedule. As many physicians are confused by 1 mg of F and 2.2 mg of NaF, we should not expect obstetricians to remember 1 mg for fluoridated cities and 1.5 to 2 mg for unfluoridated areas, as we have done in the past. There is such a wide margin of safety for prenatal fluoride in regard to fluorosis that we can use 2 mg/day as a simplified prenatal fluoride dosage in all areas, fluoridated or not. If a small woman with a good family history for caries resistance, living in a fluoridated area, takes just 1 mg/day, it is probably adequate. If a large woman with a severe caries history, living in an unfluoridated area, wishes to take 3 mg/day, it certainly will not cause fluorosis.

Prenatal tablet supplementation is most cost effective: 1-2 cents daily, or less than \$5.00 during pregnancy and should be recommended and available to all, especially the poor.

It should be noted that if the daily fluoride tablet prescribed is only 1 mg in a non-fluoridated area rather than 2 mg, and if the tablet is not being administered daily by the twelfth week on an empty stomach, it may not reproduce the author's results.

## CONCLUSION

Any prenatal fluoride dosage between 1 and 4 mg F/day is better than no prenatal fluoride at all. Because of the maternal loss of fluoride, the problem in pregnancy is to deliver sufficient fluoride to the fetal teeth. Four mg F/day is a conservative maximum sub-fluorosing dose, during pregnancy. In order to simplify matters and allow the same supplement schedule in fluoridated and unfluoridated communities, 2 mg F (4.4 mg NaF) a day can be designated as the universal prenatal fluoride dosage. It should be started by the 10-12th week of the pregnancy, taken on an empty stomach, and not followed by a meal for thirty minutes or by calcium for at least one hour.

## REFERENCES

1. Stamm, J.W.: Perspectives on the use of prenatal fluorides: a reactor's comments. *J Dent Child*, 48:128-133, March-April, 1981.
2. Teuscher, G.W. Editorial. *J Dent Child*, 48:100, March-April, 1981.
3. McDonald, R.E. and Avery, D.R.: *Dentistry for the child and adolescent*. St. Louis: The C.V. Mosby Co., 1983, p 188.
4. Milton, B.; Welsh, V.; Gift, H.C.: Prevention in the dental office: results of a preventive dentistry survey. *JADA*, 108:809-815, May, 1984.
5. Fitzgerald, D.B. and Fitzgerald, R.J.: Caries activity in hamsters prenatally exposed to fluoride. *Caries Res*, 20:71-74, January, 1986.
6. Dean, H.T.: Endemic fluorosis and its relation to dental caries. *Pub Health Rep*, 53:1443-1452, August, 1938.
7. Dean, H.T.; Jay, P.; Arnold, F.A., Jr. *et al*: Domestic water and dental caries. *Pub Health Rep*, 56:761-792, April, 1941.
8. Dean, H.T.; Arnold, A.F., Jr.; Elvove, E.: Domestic water and dental caries. *Pub Health Rep*, 57:1155-1179, August, 1942.
9. Bull, F.A.: Water fluoridation. *Dent Digest*, 55:257-261, June, 1949.
10. Backer Dirks, O.; Houwink, B.; Kwant, G.W.: Some special features of the caries preventive effect of water-fluoridation. *Arch Oral Biol*, Special Supplement, 4:187-192, 1961.
11. Martin, D.J.: The Evanston dental caries study. *J Dent Res*, 27:27-33, February, 1948.
12. Gedalia, I.; Brzezinski, A.; Portuguese, N. *et al*: The fluoride content of teeth and bones of human fetuses. *Arch Oral Biol*, 9:331-340, May-June, 1964.
13. Ericsson, Y. and Malmnas, C.: Placental transfer of fluorine investigated with  $F^{18}$  in man and rabbit. *Acta Obstet Gyne Scan*, 31:144-158, 1962.
14. Smith, M.C. and Smith, H.V.: The occurrence of mottled enamel on the temporary teeth. *JADA*, 22:814-817, May, 1935.
15. Glenn, F.B.: The rationale for the administration of a NaF tablet supplement during pregnancy and postnatally in a private practice setting: Part III. *J Dent Child*, 48:118-122, March-April, 1981.
16. Glenn, F.B.; Glenn, W.D.; Duncan, R.C.: Fluoride tablet supplementation for caries immunity: a study of the offspring produced. *Am J Obstet Gyne*, 143:560-566, July, 1982.

17. Glenn, F.B.; Glenn, W.D.; Duncan, R.C.: Prenatal fluoride supplementation and improved molar morphology: Part V. *J Dent Child*, 51:19-23, January-February, 1984.
18. Glenn, F.B.; Glenn, W.D.; Duncan, R.C.: Prenatal fluoride tablet supplementation and the fluoride content of teeth: Part VII. *J Dent Child*, 51:344-351, September-October, 1984.
19. Carlos, J.P.; Gittleson, A.M.; Haddon, W.: Caries in deciduous teeth in relation to maternal ingestion of fluoride. *Pub Health Rep*, 77:658-660, July, 1962.
20. Arnold, F.A.; Dean, H.T.; Jay, P. *et al*: Effect of fluoridated public water supplies on dental caries prevalence. *Pub Health Rep*, 71:652-658, July, 1956.
21. Blaney, J.R. and Hill, I.N.: Evanston dental caries study XXIV: Prenatal fluorides-value of waterborne fluorides during pregnancy. *JADA*, 69:291-294, September, 1964.
22. Soricelli, D.; Ship, I.; Cohen, A.: Effects of fluoridation on dental caries in Philadelphia school children 1954-1964. *Penn Dent J*, 32:47-51, February, 1964.
23. Horowitz, H.S. and Heifetz, S.B.: Effects of prenatal exposure to fluoridation on dental caries. *Pub Health Rep*, 82:297-304, April, 1967.
24. Lewis, D.W.; Hunt, A.M.; Kawall, K.: Initial dental care time, cost, and treatment requirements under changing exposure to fluoride during tooth development. *J Canad Dent Assoc*, 4:140-144, 1972.
25. Tank, G. and Storvick, C.A.: Caries experience of children one to six years old in two Oregon communities (Corvallis and Albany). *JADA*, 69:749-757, December, 1964.
26. Lemke, C.W.; Doherty, J.M.; Arra, M.C.: Controlled fluoridation: the dental effects of discontinuation in Antigo, Wisconsin. *JADA*, 80:782-786, April, 1970.
27. Grainger, R.M. and Coburn, C.L.: Dental caries of the first molars and the age of children when first consuming naturally fluoridated water. *Canad J Pub Health*, 46:347-354, September, 1955.
28. Katz, S. and Muhler, J.C.: Prenatal and postnatal fluoride and dental caries experience in deciduous teeth. *JADA*, 76:305-311, February, 1968.
29. Horowitz, H.S. and Heifetz, S.B.: V.L. Diefenbach letter to N. Martin. Bethesda, NIDR File A11a, 1968.
30. Dietz, V.: Sodium fluoride tablets in the precision control of dental caries. *J Mo State Dent Assoc*, 33:12-14, December, 1953.
31. Light, A.E.; Smith, F.A.; Gardner, D.E. *et al*: Effect of fluoridated milk on deciduous teeth. *JADA*, 56:249-250, February, 1958.
32. Feltman, R. and Kosel, G.: Prenatal and postnatal ingestion of fluorides - fourteen years of investigation - a final report. *J Dent Med*, 16:190-198, October, 1961.
33. Pritchard, J.L.: The prenatal and postnatal effects of fluoride supplements on West Australian school children, aged 6, 7, and 8. *Aust Dent J*, 14:335-338, October, 1967.
34. Kailis, D.G.; Taylor, S.R.; Davis, B.D. *et al*: Fluoride and caries: observations on the effects of prenatal and postnatal fluoride on some Perth pre-school children. *Med J Aust*, 2:1037-1040, December, 1968.
35. Light, A.E.; Bibby, B.G.; Smith, F.A. *et al*: Fluoride content of teeth from children who drank fluoridated milk. *J Dent Res*, 47:668, July-August, 1968.
36. Hoskova, M.: Fluoride tablets in the prevention of tooth decay. *Cesk Pediatr*, 23:438-441, May, 1968.
37. Martin, N.: Report of the Royal Commissioner on fluoridation of the public water supplies. Royal Report, XII, 265. Hobart, Tasmania: Government Printer, 1968.
38. Schutzmannsky, G.: Fluoride tablet application in pregnant females. *Dtsch Stomatol*, 21:122-129, February, 1971.
39. Martin, N.: Optimum fluoride intake. *Med J Aust*, 1:1118, June, 1973.
40. Babeaux, W.L. and Zipkin, I.: Dental aspects of the prenatal administration of fluoride. *J Oral Ther Pharm*, 3:124-135, September, 1968.
41. Forsman, B.: Dental fluorosis and caries in high-fluoride districts in Sweden. *Community Dent Oral Epidemiol*, 2:132-148, 1974.
42. Thylstrup, A.: Distribution of dental fluorosis in the primary dentition. *Community Dent Oral Epidemiol*, 6:329-337, 1978.
43. Brudevold, F.; Bakhos, Y.; Casenden, R.: Dental fluorosis as related to the concentration of fluoride in teeth and bones. *JADA*, 96:459-463, March, 1978.
44. Food and Nutrition Board, National Research Council, National Academy of Sciences: Recommended dietary allowances. Washington, D.C.: U.S. Government Printing Office, 1968.
45. Food and Drug Administration: RDA regulation 125.1, para (c) 38:20713, No. 148. Washington, D.C.: U.S. Government Printing Office, 1973.
46. LeGeros, R.Z.; Glenn, F.B.; Lee, D.D. *et al*: Some physico-chemical properties of deciduous enamel of children with and without prenatal fluoride supplementation (PNF). *J Dent Res*, 64:465-469, March, 1985.

The study was supported in part by a grant from the Walter G. Ross Foundation, Washington, D.C.

---

## FLUORIDE FOR THE PRIMARY TEETH

Systemic use of fluoride supplements in the form of tablets is often recommended from early life, based on the assumption that an increased caries protection can be achieved by increasing the fluoride content of the enamel of both dentitions [Aasenden and Peebles, 1974]. Most regimes start shortly after birth, but it has also been proposed that fluoride supplements should be provided during pregnancy [Glenn, 1979], although there is no biological rationale behind such a proposal [Thylstrup, 1981]. However, there is a paucity of information about the effect of fluoride tablet medication on (1) fluoride content of the deciduous enamel, and (2) possible fluoride-induced changes in the structure of the dental hard tissues of the primary dentition.

Fejerskov, O. *et al*: Combined effects of systemic and topical fluoride treatments on human deciduous teeth. *Caries Res*, 21:452-459, September-October, 1987.

---

# The use of dental sealants in the Washington State Medical Assistance Program: a one-year report

## Sealants

Robert C. Faine, DDS, MPH

**I**n September 1985, the Washington State Division of Medical Assistance expanded dental services to include dental sealants. Children, ages six to fourteen, enrolled in the Early and Periodic Screening, Diagnosis and Treatment Program (EPSDT) could receive sealants, if participating dentists chose to provide this preventive service. Guidelines that restricted the use of sealants to permanent molars were adopted by the State, for children who met the age criteria.

A survey of private dental practitioners in Washington State in 1985 revealed that 66 percent of respondents were treating medical assistance patients.<sup>1</sup> It was not known how many of these dentists, however, would use sealants on eligible children.

There were certain questions raised when the program was being planned, such as:

- How many children would be served?
- How many teeth would be sealed?
- How many dentists would participate?
- How much money would the sealant program cost?

### PURPOSE OF THIS REPORT

In order to answer many of the questions posed during the planning and implementation phase of the project, a retrospective review of the data covering the utilization and cost of the sealant program for a one-year period was undertaken. The period chosen for the data review and

---

Dr. Faine is Former State Dental Consultant, Department of Social and Health Services, State of Washington.



analysis was from November 1, 1985 to October 31, 1986.

In an effort to inform dentists that the state would pay for sealants placed for eligible children, an announcement was sent out from the Division of Medical Assistance to all dental providers at the initiation of the program. The Washington State Dental Association Newsletter also announced that sealants would become a reimbursable procedure beginning September 15, 1985, for EPSDT children.

## METHODS

A computer program was developed which retrieved information from an extended data base maintained by the Division of Medical Assistance. The following data were recovered: the age and number of children treated; the number of sealants placed by age; the total number of teeth sealed; the number of providers who applied sealants by county of provider; and the total costs of the services delivered to the children.

Every dental claim that included a sealant procedure was reviewed for the one-year period, and the data in this report represent an unduplicated count of patients and providers.

## RESULTS

In the EPSDT category, there were 63,561 children, ages six to fourteen, who were eligible each month to receive dental sealants (1986 Fiscal Year monthly average of eligibles). From November 1, 1985, to October 31, 1986, a total of 35,805 individuals, six to fourteen years of age, made at least one visit to a dentist. Approximately 3000 children in this age-group each month, therefore, received some type of dental care. The services were delivered in private offices, community clinics, and public health dental facilities. The total number of patients receiving sealants in the one-year period was 6,191 or 17.3 percent of all individuals obtaining care.

There were 19,590 teeth sealed in Washington State during the one-year assessment period, for an average of 3.16 teeth sealed per child.

The age-group most frequently receiving sealant application was the seven-year age-category, followed by the eight-year-olds. Those receiving the lowest number of sealants were the individuals in the fourteen-year age-group (Figure).

Some dentists have been reluctant to offer sealants to their patients; but as more scientific studies continue to

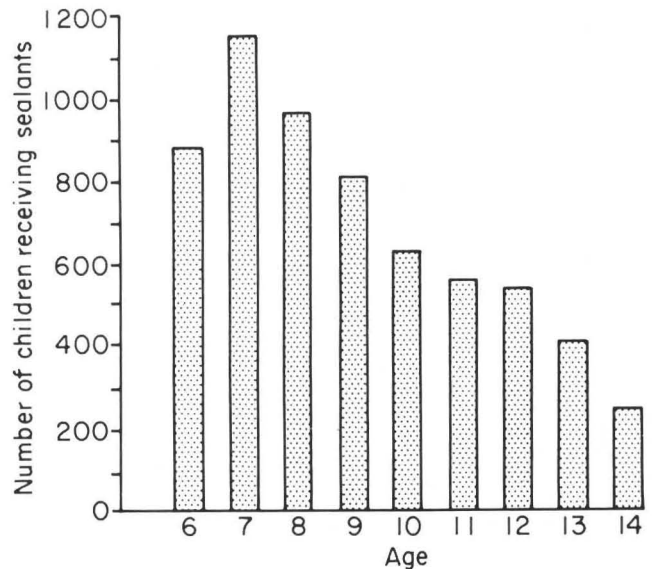


Figure. Number of children, by age, who received sealants, 1985 - 1986.

confirm that sealants are safe and effective, the use of this preventive procedure is expected to increase.<sup>2-4</sup>

For the twelve-month period covered by this study, there was a monthly average of 1,317 dentists who participated in the EPSDT program. The total number of dentists to use sealants was 593 in all counties throughout the state. This figure represents an unduplicated count of dentists who placed sealants from November 1, 1985 to October 31, 1986.

When the sealant program was being developed, one of the most important questions asked by the Division of Medical Assistance Administrators was "how much will the project cost?" This was a critical question, because only limited funds were available for a new program. The staff of the Division of Medical Assistance and the author developed a fiscal prediction model in an attempt to forecast a first-year budget figure for administrators and the Legislature. An annual budget of \$215,000 was estimated for the program based on the number of providers; the number of providers that might place sealants, as determined by national and state utilization figures; the number of children eligible for sealant benefits; past utilization figures for dental services; and the cost of the procedure. The reimbursement rate for each sealant placed was \$9.00. Actual costs for one year of the program were \$172,535. While it was important not to exceed the projected budget figure, it was disappointing that more children did not receive the benefits of sealants.

## DISCUSSION AND SUMMARY

A one-year, utilization-and-cost review was conducted of a Medical Assistance sealant program in Washington State. The period covered by the analysis was November 1, 1985 to October 31, 1986. A total of 6,191 individuals received sealants or 17.3 percent of all children, ages six to fourteen, who made at least one visit to a dentist.

The total number of teeth sealed was 19,590, with an average of 3.16 teeth per child. It is anticipated that the number of children treated will increase during the second year of the sealant project.

An average of 1,317 dentists participated in the dental program each month. There were 593 dentists who placed sealants during the study period. A more concerted effort will be made in the future to encourage dentists to use sealants on Medical Assistance patients.

The total cost of providing sealants to this group of children was \$172,535.

Currently, there are eighteen states involved in a

sealant program for EPSDT children (personal communication with Dr. R. Isman, June, 1987). Limited data are available on sealant utilization and costs for these projects. This information is presented to document the experience of a state that sought to improve the dental health of children by implementing a sealant program. Other states considering the inclusion of sealants in a dental service program may find the data useful for planning purposes.

## REFERENCES

1. Faine, R.C. and Dennen, T.: A survey of private dental practitioners' utilization of dental sealants in Washington State. *J Dent Child*, 53:337-342, September-October, 1986.
2. Gift, H.C. and Frew, R.A.: Sealants: changing patterns. *JADA*, 112:391-392, March, 1986.
3. Horowitz, A.M. and Frazier, P.J.: Issues in the widespread adoption of pit and fissure sealants. *J Pub Health Dent*, 42:312- 323, Fall, 1982.
4. American Association for Dental Research, Committee on Health Promotion: Proceedings of a symposium: pit and fissure sealants: is it time for a new initiative? *J Pub Health Dent*, 42:295-336, Fall, 1982.

---

## FLUORIDE IN CHEWING GUM

The present study was undertaken to collect quantitative data on the fluoride concentration in whole saliva after single and repeated doses of fluoride administered in a chewing gum, a fluoride vehicle which has not been given much attention. When the fluoride gum is used repeatedly during the day, it causes an elevation in the average fluoride concentration in saliva, in some subjects more than 10-fold compared to the basal level. Compared to recommended usage of fluoride dentifrices or rinsing solutions, repeated use of a fluoride-containing chewing gum makes it possible to keep the fluoride concentration in the oral fluids at a higher level during an extended period of time. However, table II also indicates that large differences between individuals will occur. The most likely reason for this is differences in the salivary flow rate. Stimulated saliva dilutes the fluoride concentration to a degree proportional to the individual salivary flow [Dawes, 1983]. This is also indicated by the relationship found between the subject's stimulated salivary flow rate and the mean concentrations of fluoride in the saliva during the entire experimental period.

Oliveby, A. *et al*: Effect of salivary flow rate on salivary fluoride clearance after use of a fluoride-containing chewing gum. *Caries Res*, 21:393-401, September-October, 1987.

---

# Dietary cholesterol recommendations for children

Alvin M. Mauer, MD

**T**he role of diet in the pathogenesis of atherosclerosis has been the subject of considerable study and discussion. In an attempt to resolve some of the controversies and to bring together available information bearing on this topic, a Consensus Development Panel was sponsored by the National Institutes of Health. In its findings published in 1985, the panel concluded that since sufficient evidence of several types linked dietary fat and cholesterol to the risk of atherosclerosis, dietary recommendations could be made which apply to all people over the age of two.<sup>1</sup> These recommendations include limiting fat intake to 30 percent of total calories with 10 percent or less from saturated fat, 10 percent from monounsaturated fat and less than 10 percent from polyunsaturated fat. Total daily cholesterol intake was recommended to be 100 mg/1000 calories and not to exceed 300 mg as a daily total. These proposals have not met with universal acceptance, particularly for application to such specific groups as children.<sup>2,3</sup> In this paper, recently published information bearing on the specifics of these recommendations will be assessed with particular emphasis on their applicability to children and adolescents.

### Adult dietary recommendations

Information from a variety of sources was used by the Consensus Panel in developing recommendations for

---

Dr. Mauer is with the Departments of Medicine and Pediatrics, The University of Tennessee, Memphis, Room H316 Coleman Building, 956 Court Avenue, Memphis, TN 38163.

modification of the typical American diet. A major contribution came from the results of a study in middle-aged, hypercholesterolemic men in which a reduction in the incidence of coronary artery disease was observed when serum cholesterol was lowered by both diet and drug administration.<sup>4,5</sup> The applicability of these results in forming dietary recommendations for all adults continues to be under discussion.<sup>6,7</sup> Specifically, it is suggested that lowering serum cholesterol in people at low risk for coronary artery disease may make a minimal contribution to life expectancy, probably far less than would be achieved by smoking cessation or control of hypertension.<sup>8</sup> Recent studies have also indicated that for the majority of the population, diets exceeding recommended cholesterol limitation of 300 mg do not result in increases in plasma cholesterol values.<sup>9,10</sup> In view of this recent information on the adult dietary recommendations, it is important to consider this application to children over age two and adolescents.

### Children's dietary recommendation

The rationale for recommending modification of children's diets is the prevention of adult atherosclerosis. Kwiterovich recently published an extensive review of the data bearing on the role of children's diets in predisposing to adult atherosclerosis.<sup>11</sup> Generally, three types of studies in humans have yielded data interpreted to support a causative role for children's diets in predisposing to the risk for adult atherosclerosis. In the first type of studies, epidemiological evidence indicates a direct relationship between serum cholesterol values found in the children of various countries and the prevalence of adult coronary artery disease. A second test of this dietary hypothesis, that of prospective clinical trials, is not available for children. However, evidence obtained from trials in middle-aged hypercholesterolemic men mentioned above has been interpreted as supporting the extension of dietary restriction to other populations as well, notably children and women.<sup>4,5</sup> A third approach attempts to establish a linkage between serum lipid patterns in the first two decades of life and the extent of fatty streaks found in arterial vessels of children dying from other causes.<sup>12</sup>

Cautionary commentary is needed in evaluating each of these three approaches in light of making recommendations concerning dietary changes for American children. The epidemiological data tend to isolate the serum cholesterol values and coronary artery disease from other health aspects. These studies are inclined to ignore other consequences of the dietary restrictions

which presumably are associated with the lower levels of serum cholesterol in children. Normal growth and development may be impaired in conditions of dietary restrictions.<sup>13</sup> For example, the relative decreased risk of coronary artery disease in Japanese men is also associated with a pattern of decreased growth and delayed development, which has shown a secular trend since improved diets became available, following the end of the Second World War.<sup>14</sup> Generally, these reports also have not taken into account the prevalence of other risk factors, such as smoking, hypertension and exercise patterns, which may bear a more important relationship.<sup>8</sup>

The large prospective trial of the effect of lowering serum cholesterol values in hypercholesterolemic middle-aged men has been criticized for its applicability to other populations.<sup>15</sup> Its usefulness in assessing dietary change in children as a factor in reducing risk of atherosclerosis in adults seems marginal at best.<sup>2</sup>

The study linking serum lipid patterns and fatty streaks in arterial vessels during the first two decades of life also must be accepted with reservation, because of a lack of a well-defined relationship between these fatty streaks and adult atherosclerosis.<sup>4</sup> In American children, there has been a poor correlation between diet and cardiovascular disease risk factor variables.<sup>16,17</sup> During childhood and adolescence, factors such as obesity and aerobic capacity are more important determinants of the likelihood of cardiovascular risk factors being present than diet.<sup>18,19</sup>

### Implication of dietary restrictions for children

The characteristics of diets meeting the recommendations of the Consensus Panel include limitations of meat, eggs and dairy products with an increase in cereal grains and plant products. For the critical period of growth of children and adolescents, these restrictions mean a reduction in foods that form an important source of high-quality protein. Furthermore, dairy products provide 60 percent of dietary calcium, and meat is an excellent source of available iron.<sup>20</sup> The difficulties in designing diets conforming to the recommendations for American children, based on American food supply and taking into account cultural and ethnic variabilities, are beginning to be appreciated. In assessing results of diet modifications, it must be recognized that in the U.S., the mean serum cholesterol values in children do not increase after age two years and decrease during the second decade with current dietary patterns.<sup>21</sup>

### Current trends in diet and health

During the past several decades, there have been important secular trends in growth and maturation in this country, with improved nutrition being one of the most important influential factors.<sup>22</sup> Analysis of the data from the Second National Health and Nutrition Examination Survey indicates an improvement in the status of iron nutriture among children and adolescents.<sup>23</sup> Currently, moderate or severe anemia, as a consequence of dietary iron deficiency, is rare in the U.S. It remains, however, the predominant, identifiable cause of anemia in children and adolescents. Dietary patterns have also changed with respect to total fat intake in children, ages one to five.<sup>24</sup> Currently, the percent of food energy from fat in children's diets is about 34 percent. In adults, the amount and quality of fat in the diet is an important factor in determining serum cholesterol values.<sup>9,10</sup>

These trends, taken together, would suggest that considerable caution be used before further manipulation of the diets of children and adolescents is recommended. It must be demonstrated that changes are needed and any further restrictions would support adequate growth and development.<sup>2,3</sup>

### RECOMMENDATION

After careful review of currently available information, the Committee on Nutrition of the American Academy of Pediatrics came to seven recommendations with respect to prudence in life-style factors to reduce the risk of atherosclerosis and coronary artery disease in adults.<sup>4</sup> These recommendations are as follows:

- When breast feeding is unsuccessful, inappropriate or stopped early, infant formulas provide the best alternative for meeting nutritional needs during the first six months of life. During the second six months of life, whole cow's milk may be introduced for infants who are consuming one-third of their calories as supplemental foods consisting of a balanced mixture of cereal, vegetables, fruits and other foods. Supplementary foods are recommended beginning at four to six months of age. Dietary fat should probably not be restricted in this age-group.
- After one year of age, infants should receive a varied diet including each of the major food groups. This provides the best assurance of nutritional adequacy; the key is balance from variety.
- Detection of obesity by measuring height and weight and detection of hypertension by measuring blood pressure according to the schedules published by the Academy will permit the early recognition and treatment of obesity and hypertension.
- Counseling on the maintenance of ideal body weight and a regular exercise program and, in teenagers, counseling concerning the dangers of smoking should be a routine part of all health supervision visits.
- Family history for each patient should include information about family members who have had a premature (before sixty years of age) heart attack or stroke, hypertension, obesity, diabetes mellitus and/or hyperlipidemia.
- Screening of children more than two years old who are at risk because of family history should consist of at least two serum cholesterol measurements. High-density lipoprotein cholesterol level should be measured in those who consistently have levels above the 95th percentile for age and sex. If high-density lipoprotein cholesterol is not the cause of the hypercholesterolemia, the child should be treated with an appropriate diet and/or medication.
- Current dietary trends in the U.S. — decreased consumption of saturated fats, cholesterol and salt and an increased intake of polyunsaturated fats — should be followed with moderation. The optimal total fat intake cannot be determined, but 30 percent to 40 percent of calories seems sensible for adequate growth and development. Diets that avoid extremes are safe for children for whom there is not evidence of special vulnerability.

### SUMMARY

These recommendations are provided to physicians and health professionals who work with children. Continued evaluation of dietary trends and the impact of cardiovascular risk factors from the first two decades of life are needed for future recommendations.

### REFERENCES

1. Consensus Development Panel, Lowering blood cholesterol to prevent heart disease, *JAMA* 253:2080-2086, 1985.
2. American Academy of Pediatrics, Prudent life-style for children: dietary fat and cholesterol, *Pediatrics*, 78:521-525, 1986.
3. Taitz, L.S.: Diet of young children and cardiovascular disease. *Brit Med J*, 294:920-921, 1987.
4. Lipid Research Clinics, The lipid research clinics coronary primary prevention trial results: reduction in incidence of coronary heart disease. *JAMA*, 251:351-364, 1984.
5. Lipid Research Clinics, The lipid research clinics coronary primary prevention trial results: the relationship of reduction in incidence of coronary heart disease in cholesterol lowering. *JAMA*, 251:365-374, 1984.

6. Epstein, A.M. and Oster, G.: Cholesterol reduction and health policy: taking clinical science to patient care. *Ann Int Med*, 106:621-623, 1987.
7. Becker, M.H.: The cholesterol saga: whither health promotion? *Ann Int Med*, 106:623-626, 1987.
8. Taylor, W.C.; Pass, T.M.; Shepard, D.S. *et al*: Cholesterol reduction and life expectancy. *Ann Int Med*, 106:605-614, 1987.
9. Edington, J.; Geekie, M.; Carter R. *et al*: Effect of dietary cholesterol on plasma cholesterol concentration in subjects following reduced fat, high fibre diet. *Brit Med J*, 294:333-336, 1987.
10. McNamara, D.J.; Kolb, R.; Parker, T.S. *et al*: Heterogeneity of cholesterol homeostasis in man. *J Clin Invest*, 79:1729-1739, 1987.
11. Kwiterovich, Jr., P.O.: Biochemical, clinical epidemiologic, genetic and pathologic data in the pediatric age group relevant to the cholesterol hypothesis. *Pediatrics*, 78:349-359, 1986.
12. Newman, W.P.; Freedman, D.S., Voors, A.W. *et al*: Relation of serum lipoprotein levels and systolic blood pressure to early atherosclerosis. *N Engl J Med*, 14:138-144, 1986.
13. Pugliese, M.T. *et al*: Parental health beliefs as a cause of non-organic failure to thrive. *Pediatrics*, 80:175-182, 1987.
14. Kondo, S.; Takahashi, E.; Kato, K. *et al*: Secular trends in height and weight of Japanese pupils. *Tohoku J Exp Med*, 126:203-213, 1978.
15. Kronmal, R.A.: Commentary on the published results of the lipid research clinics coronary primary prevention trial. *JAMA*, 253:2091-2093, 1985.
16. Frank, G. C.; Berenson, G.S.; and Webber, L.S.: Dietary studies and the relationship of diet to cardiovascular disease risk factor variables in 10-year-old children – the bogalusa heart study. *Am J Clin Nutr*, 31:328-340, 1978.
17. Weidman, W.H.; Elveback, L.R.; Nelson, R.A. *et al*: Nutrient intake and serum cholesterol level in normal children 6 to 16 years of age. *Pediatrics*, 61:354-359, 1978.
18. Fripp, R.R.; Hodgson, J.L.; Kwiterovich, P.O. *et al*: Aerobic capacity, obesity, and atherosclerotic risk factors in male adolescents. *Pediatrics*, 75:813-818, 1985.
19. Freedman, D.S.; Burke, G.L.; Harsha, D.W. *et al*: Relationship of changes in obesity to serum lipid and lipoprotein changes in childhood and adolescence. *JAMA*, 254:515-520, 1985.
20. National Academy of Sciences, Recommended Dietary Allowances, Ninth Edition, 1978, pp 1-184.
21. Christensen, B.; Glueck, C.; Kwiterovich, P. *et al*: Plasma cholesterol and triglyceride distributions in 13,665 children and adolescents: the prevalence study of the lipid research clinics program. *Pediat Res*, 14:194-202, 1980.
22. Malina, R.M.: Secular changes in size and maturity: causes and effects. In: *Monographs of the Society for Research in Child Development*. Edited by F. D. Horowitz, Vol 43, The University of Chicago Press, 1978, pp 59-120.
23. Dallman, P.R.; Yip, R.; and Johnson, C.: Prevalence and causes of anemia in the United States, 1976 to 1980. *Am J Clin Nutr*, 39:437-445, 1984.
24. U.S. Department of Agriculture, Human Nutrition Information Service, Nationwide Food Consumption Survey, Continuing Survey of Food Intakes by Individuals, NFCS, CSFII Report No. 85-1, 1985, pp 48-49.

Reprinted from Contemporary Nutrition by permission of General Mills Nutrition Department.

---

## CARIOGENICITY OF STARCH AND SUGARS IN CHILDREN

The results of this study showed that dietary sugars were likely to have been more cariogenic than dietary starch. This is indicated by the correlation/partial correlation analyses, and supported by the comparison of groups of subjects with extreme dietary intakes and multiple regression analysis. However, this conclusion should be made with caution since only some of the relationships were statistically significant. From both types of analysis, it appeared that the differences between the possible cariogenicity of starch and sugars occurred almost entirely in fissure surfaces, with little relationship observed in other surfaces. It is possible, though, that the low levels of caries occurring in the non-fissure surfaces might have masked the presence of a relationship (in either direction) since small increments and many zero scores depress the value of correlation coefficients [Appleton *et al*, 1986]. The suggestion in the results that approximal surfaces may be more susceptible to the cariogenic challenge of starch than fissure surfaces should be investigated further.

Rugg-Gunn, A.J. *et al*: Relative cariogenicity of starch and sugars in a 2-year longitudinal study of 405 English school children. *Caries Res*, 21:464-473, September-October, 1987.

---

## ABSTRACTS

**Thesleff, Irma: Does epidermal growth factor control tooth eruption? J Dent Child, 54:321-329, September-October, 1987.**

Several pieces of evidence suggest an important role for epidermal growth factor (EGF) in tooth eruption, which is largely under hormonal control. EGF appears to be a mediator of many effects of hormones. Growth factors (including EGF) are apparently synthesized by many cell types and exert their effects by the paracrine system. This provides the possibility for localized stimulation of growth and other cellular functions. Also, cells associated with erupting teeth bind EGF and are potentially responsive to it. There is increasing evidence that EGF is involved in the process of tooth eruption.

**Epidermal growth factor; Cell receptors; Tooth eruption**

**Nation, Wilfred A.; Matsson, Lars; Peterson, John E.: Developmental enamel defects of the primary dentition in a group of Californian children. J Dent Child, 54:330-334, September-October, 1987.**

This study reports the occurrence of developmental enamel defects in the primary dentition in a group of 300 children, three to six years old. Of the children examined, ninety-nine (33 percent) had such defects; sixty-two (21 percent) showed hypoplasia, and thirty-seven (12 percent) showed opacities only. Black children showed the highest rate (60 percent), followed by whites (38 percent), and Hispanics (18 percent). Sex and socioeconomic status were not important factors.

**Mandibular canine teeth; Hypoplasia; Enamel defects; Opacities**

**Ngan, Peter W.; Wolf, Terry; Kassoy, Gerald: Early diagnosis and prevention of impaction of the maxillary canine. J Dent Child, 54:335-338, September-October, 1987.**

This paper presents the case of a ten-

year-old girl with a maxillary right canine tipped toward the midline and more medially positioned than the left. It was decided in the pedodontic clinic to extract it and observe the eruption of the permanent tooth, which eventually required only minor orthodontic treatment to guide it into a functionally correct dental-arch position.

**Maxillary canine teeth; Impaction; Orthodontics**

**Crim, Gary A. and Shay, Jeffrey S.: Effect of etchant time on microleakage. J Dent Child, 54:339-340, September-October, 1987.**

Although acid conditioning of enamel for one minute is customary, shorter times may be effective; this study examined the effect of reduced etching time on the microleakage of a composite resin with dentin bonding. Three different etch times (15, 30, and 60 seconds) were equally effective in eliminating leakage around enamel margins. The non-etched control group displayed significant leakage. Under the experimental conditions of this study, it appears that it is not necessary to employ extended etching times, which is desirable with young patients. Etching enamel for 15 seconds with an acid gel was as effective in eliminating microleakage as 30- or 60-second etch times.

**Microleakage; Etch times; Enamel**

**Högström, Åsa and Andersson, Lars: Complications related to surgical removal of anterior supernumerary teeth in children. J Dent Child, 54:341-343, September-October, 1987.**

Different opinions exist in the literature concerning the optimal time for surgical removal of anterior supernumerary teeth. Some authors recommend immediate removal, whereas others recommend postponing surgery until the root development of adjacent teeth is completed. Those advocating the latter opinion believe there might be some

potential damage to adjacent teeth and the risk of creating dental anxiety in the young child. The purpose of this investigation was to study the complications related to surgical removal of a mesiodens and to elucidate the psychological effect of this kind of surgery on children at an early age. The study consisted of 40 patients, 23 with uncompleted and 17 with completed root development. The results showed that early surgical removal neither impaired the prognosis for the adjacent teeth nor increased the risk for creating dental anxiety, compared with postponing surgery until root development of incisors is completed.

**Surgical complications; Oral surgery; Dental anxiety; Supernumerary teeth, anterior**

**Waldman, H. Barry: Another perspective on children's dental needs and demands for services during the 1980s. J Dent Child, 54:344-348, September-October, 1987.**

A review is provided of parent reports on children's dental service needs, use of services, and reports of children's restricted days, bed days, and lost school days associated with dental conditions. Continuing parental awareness of the need for more services is noted.

**Pediatric dentistry; Epidemiology**

**Nelson, Linda P. and Album, Manual M.: AIDS: children with HIV infection and their families. J Dent Child, 54:353-358, September-October, 1987.**

This review is based on the participation of two pediatric dentists who were invited to the Surgeon General's workshop conference on AIDS. Through mid-April 1987, there were 600 cases of pediatric AIDS (that fit the CDC definition) in the United States; 60 percent of these children have died. Diagnosis of HIV infection in children creates a state of crisis in the family.

**AIDS; HIV infection; Pathogens; Health education**

**Croll, Theodore P.; Pascon, Elizeu, A.; Langeland, Kaare: Traumatized injured primary incisors: a clinical and histological study. J Dent Child, 54:401-422, November-December, 1987.**

World-wide epidemiological studies state that from 8 percent to 30 percent of children up to 7 years of age sustain injury to primary incisors, including crown fracture, root fracture, tooth avulsion, and dental displacement, which result in malformation of permanent incisors depending upon their state of development. In this study, traumatized primary incisors were evaluated clinically and radiographically, with the following data recorded: exact or approximate time-interval of traumatic episode(s) and extraction, mobility, color change, sensitivity to percussion/palpation, swelling, sinus tract, caries, crown/root fracture, periodontal/periapical lesions, external/internal root resorption, mineralization, and obturation. Based upon the local damage and developmental age, 138 teeth were extracted, fixed in 10 percent formalin, and processed for histological evaluation according to routine methodology. Histologic findings were: the presence of varying extent of necrosis, bacteria in the area of necrosis—not in all cases—neutrophilic leukocytes, chronic inflammatory cells, pulpal calcifications, resorption/apposition, and circulatory changes. The blood pigment distinguished hemorrhage due to extraction from pathologic circulatory changes. All the described reactions varied in intensity and extent with the time interval and the assumed force of the original trauma. Physical trauma to primary teeth caused pulpal damage, which could involve periapical tissue, depending on the extent of the initial damage.

**Tooth, primary: Wounds and injuries, follow-up study**

**Turner, Clara; Courts, Frank J.; Stanley, Harold B.: A histological comparison of direct pulp capping agents in primary canines. J Dent**

**Child, 54:423-428, November-December, 1987.**

The purpose of this study was to evaluate the pulpal response to four calcium hydroxide preparations in primary teeth. Data indicated the calcium hydroxide-saline paste induced more inflammation and produced a greater zone of mummification than the three commercial preparations studied. Unintentional deep impaction of the medication or dentinal chips increased inflammation for all categories. All medicaments produced a superficial necrosis (mummification) of the pulp. The greatest degree of mummification was seen with the calcium hydroxide-saline paste. The calcium hydroxide-saline paste produced a thick dentinal bridge, located deeper in the pulp when compared with the commercial agents. Commercial agents produced narrower but sufficiently high-quality dentinal bridges. This study indicates that direct pulp capping of exposures in primary teeth is a viable procedure. The newer commercial agents may be preferred, as they produce minimal inflammation, satisfactory dentinal bridging, and preservation of most of the vital pulp tissue.

**Direct pulp capping; Primary teeth; Mummification; Dentinal bridging**

**Obry, F.; Belcourt, A.B.; Frank, R.M.: Biochemical study of whole saliva from children with chronic renal failure. J Dent Child, 54:429-432, November-December, 1987.**

The biochemical composition of unstimulated whole saliva was studied on ten children suffering from chronic renal failure and who, at the same time, displayed a very low caries activity. Various salivary components were studied before (T) and after (To) dialysis and were compared with similar elements of a control group, as well as with blood values. A mean salivary urea concentration of  $513 \pm 210$  mg/100 ml was found prior to dialysis, whereas after treatment this value dropped to  $241 \pm 82$  mg/100 ml, about twice as much as in the control group,  $110 \pm 48$  mg/100 ml.

The mean urea concentrations in blood at T and To were respectively  $196 \pm 38$  mg/100 ml and  $53 \pm 22$  mg/100 ml. The various free amino acids in the whole saliva of these patients showed different changes in their concentrations as a result of dialysis, with the basic amino acids being considerably increased. Blood electrolytes remained close to the normal range, although calcium was depleted and magnesium lowered by a factor of 10 when compared before and after dialysis, as well as versus the control group.

**Renal failure, chronic; Whole saliva, unstimulated; Urea; Amino acids; Electrolytes**

**Weinberger, Sergio J. and Wright, Gerald Z.: The unpredictability of primary molar resorption following ectopic eruption of permanent molars. J Dent Child, 54:433-436, November-December, 1987.**

Two case reports are given, demonstrating what appears to be two types of resorption associated with ectopic eruption. In both cases a progressive resorptive process occurred on one side and a stationary type on the other. Close follow-up is important; it resulted in a successful outcome for the patient in case 2 here, whereas the first patient required major orthodontic treatment because of the ectopic eruption.

**Ectopic eruption; Molars primary; Resorption; Orthodontic treatment**

**Nathan, John E. and West, M. Stewart: Comparison of chloral hydrate-hydroxyzine with and without meperidine for management of the difficult pediatric patient. J Dent Child, 54:437-444, November-December, 1987.**

This study examined the effectiveness of chloral hydrate-hydroxyzine with and without meperidine in the treatment of 135 unmanageable children with extensive caries, comprising 142 visits. Comparisons were made between subjects receiving either a 50- or 70 mg/kg dose of chloral hydrate in combination with 25



mg hydroxyzine, with or without 20-30 mg oral meperidine, in this study using multiple operators. The adjunctive effect of nitrous oxide (used only when oral medications were inadequate) was also studied.

Subjects receiving the meperidine combination were successfully treated (without need for persistent or harsh physical restraint) in 76 percent of the cases, compared to 31 percent when meperidine was not added. No episodes of respiratory or cardiac depression or detectable loss of protective reflexes occurred during any of the visits. The addition of low doses of oral meperidine to a chloral hydrate/hydroxyzine combination appears beneficial and safe, effectively overcoming severely disruptive child responses and providing adequate working time for treatment. It minimizes the need for harsh physical restraint. When meperidine is included, use of the higher dose of chloral hydrate appears unwarranted.

**Chloral hydrate; Meperidine; Sedation, oral; Behavior, difficult**

**Glenn, Frances, B. and Glenn, William, D. III: Optimum dosage for prenatal fluoride supplementation (PNF): Part IX. J Dent Child, 54:445-450, November-December, 1987.**

There exists such a wide margin of safety for prenatal fluoride in regard to fluorosis that 2 mg/day can be used as a simplified prenatal fluoride dosage in all areas, regardless of whether they are fluoridated. Any prenatal fluoride dosage between 1 and 4 mg/day is better than no prenatal fluoride at all.

**Fluoride, prenatal; Fluorosis**

**Faine, Robert C.: The use of dental sealants in the Washington State Medical Assistance Program: a one-year report. J Dent Child, 54:451-453, November-December, 1987.**

The total cost of providing sealants to a group of 6,191 children (17.3 percent of those eligible) by an average of 1,317 dentists participating in the program

from November 1985 through October 1986 was \$172,535. There were 593 dentists who placed sealants during the one-year program, with an average of 3.16 teeth sealed per child. It is antici-

pated that more children will be treated during the second year of the sealant project.

**Sealants; Epidemiology; Delivery of dental services**

## News

### NEW EDUCATIONAL MATERIALS

Following the recommendations of the ASDC Education Committee, several new patient-education items have been produced, during recent months. A brochure titled, *Child behavior and the dentist: a parent's guide*, is now available. The concept expressed is a positive approach to preparing children for visits to the dentist. The parents' roles are described and the need for cooperative efforts is emphasized. The brochures are sold in packets of 100 at a cost to members of \$15.00 per packet.

A second new brochure, in production, is on interceptive orthodontics. The illustrations depict actual cases and will be in a four-color format. The text describes in simple and concise language the advantages of interceptive orthodontics, from time-saving, patient-comfort, and cost-of-treatment points of view. (Ready in mid-November)

A third brochure, *Preventive resin restorations*, will also be in four-color format. This describes a restorative technique, which, its supporters claim, will grow rapidly in popularity. (Ready in late November)

A fourth brochure, *Development of children's teeth*, tells the story of the development, eruption, and shedding of the primary teeth; and states the normal eruption times of the permanent teeth. A useful brochure, designed to save your time and provide parents with the answers to their questions on tooth

development. (Ready in late November)

A fifth brochure is a Spanish version of the very popular *Infant Nursing*. This will sell for the same price as the English version: \$15.00 for a packet of 100 to members.

Three slide/tape programs, *Child abuse alert*, *Nursing caries syndrome*, and *Your baby is on the way*, have been completely revised, and are available in video as well as the slide/tape format. The script has been tightened and the illustrations animated. A single professional voice presents the text. The slide/tape format is sold for \$75 and the video version for \$59.95.

The video history of dental care for children is completed and was shown for the first time at the 1987 Annual Meeting in Tucson. Plans for distribution will be announced in the next Newsletter and in the catalog.

The new catalog of educational materials is in preparation and a copy will be mailed to all members, when it is completed.

### ADA NAMES EDITOR

The Board of Trustees of the American Dental Association has appointed Dr. William F. Wathen of Fort Worth, Texas, as ADA Editor. As such he will serve as an officer of the Association and head of the Editorial Division of the ADA, which is responsible for publication of the Journal of the American Dental As-