

Orofacial dog bites: Review and case report

Bryan J. Williams, D.D.S., M.S.D., M.Ed.

Abstract

Estimates of the national yearly frequency of dog bites vary between 500,000 to one million. Children comprise the largest segment of these victims. Since many of these bites involve the facial region, the pediatric dentist must be aware of the magnitude and the management of the problem. Principles of care involve a careful history, thorough wound examination, and meticulous wound management and closure. Since bite wounds carry a risk of tetanus organism colonization and bacterial infection from canine oral fluids, both tetanus prophylaxis and prophylactic antibiotics are usually indicated.

Introduction

Each year, large numbers of children are bitten by dogs. Pediatric dentists may be involved in the management of these patients in private offices or hospital emergency rooms. Since dog bites present many unusual features, anyone who may be involved in the management of these bites should understand the epidemiology, sequelae and principles of treatment. This paper reviews these aspects and illustrates principles of care with a case report.

Epidemiology

Animal bites present a nationwide public health problem. Berzon¹ showed a peak of eight animal bites per 1,000 population in 1972 which declined to 5.8 bites per 1,000 in 1976. Most of the bites were from dogs. Beck et al² reported an animal attack rate of 448.4 per 100,000 people in 1973 for the city of St. Louis. In this survey, one in 50 emergency room visits was due to a dog bite injury. Douglas³ stated that 1 percent of all visitors to a Toronto hospital emergency room for the year 1971 attended with bite wounds, mostly inflicted by dogs.

Estimates of the national yearly frequency of dog bites vary between 500,000 to one million. Since many bites are unreported, the actual frequency may be much higher.^{4,5} Children comprise the largest segment of these victims. Schultz⁴ reported that 92 percent of the patients with bite wounds treated in his plastic surgery clinic were between one and seven years of age. Robinson⁶ reported that 41.2 percent of the bite victims treated in an English hospital emergency room were less than 14 years old. Other authors^{7,8,9} report that 40 percent to 50 percent of bite wounds occur from birth to the early teenage years.

Reports from plastic surgical practices relate an incidence of facial bites ranging from 28 percent to 65 percent.^{5,9} Other surveys^{3,7} show a slightly lower proportion of bites localized on the face. Many of these bites are of great importance since reported deaths from dog bites⁴ frequently involve head and facial bites on children. A case of a child who suffered a mandibular fracture as the result of a dog bite has been reported.¹⁰

Certain breeds of dogs appear to be involved in a disproportionate number of biting incidents. German Shepards⁹ and Saint Bernards⁴ are frequently involved, a fact which should be noted in recommending a child's pet.

Sequelae

Dog bites in children involve both short and long term sequelae. The patient experiences pain and emotional trauma initially. Significant medical costs are incurred in the treatment of these patients.⁸ The child may be afflicted with both temporary and long term disability and disfigurement. Biting incidents may have significant long term psychological effects on a child.

Principles of Management of Bite Injuries

Initially, it is critical to secure a careful history

Accepted: February 5, 1980.

from a patient suffering a dog bite. The dog should be identified and the time of bite, the location and the circumstances of the attack should be elicited. Each community usually has a protocol to follow in reporting animal bites which should be available from the local hospital emergency room. If a stray dog bites a child, the local health authorities should be contacted immediately.

Regional public health authorities have a protocol to follow in cases of bites by stray animals. If the dog can be found, it is placed in quarantine and observed for signs of rabies. Incidents where the dog cannot be found are reviewed by the authorities, and a decision on the need for rabies vaccine injections is made on a case by case basis. This judgement varies in different areas of the country according to the prevalence of rabies. Since 14 to 21 subcutaneous doses of vaccine are necessary, the decision is not taken lightly. However because rabies is invariably fatal, any patient with a reasonable chance of exposure is vaccinated.

The nature of the injury should be assessed by careful examination. Children who are very young or very distraught may require some means of sedation in order for the clinician to perform a thorough examination and secure cooperation for the meticulous wound care needed. The wound should be flushed with copious quantities of normal saline and inspected for foreign bodies. A wound involving gross facial involvement or evulsion of tissue should be managed by someone familiar with these injuries. Pediatric dentists should be proficient in closure of most minor intraoral, through and through, and extraoral lacerations. Following debridement and assessment of the injury, any osseous fractures, dental luxations or evulsions should be reduced and stabilized. Lacerations should be closed in layers using the "inside out" principle. Starting with the intraoral mucosal laceration, trim any jagged edges and reoppose using interrupted sutures. In children, 3-0 or 4-0 black silk may cause less exploration with the tongue than a synthetic suture material which has rigid suture ends. In a child with limited cooperation, synthetic sutures may be preferred since suture removal is unnecessary. Restoration of the intraoral tissues to their proper anatomic relationships prevents future difficulty with food entrapment in abnormal pouchings.

The operator should change gloves and the extraoral portions of the wound should be reirrigated. Severely torn wound margins should be carefully trimmed and the skin edges slightly undermined. The muscle layers should be closed with synthetic resorbable suture. The primary esthetic concern in closure of the skin surface of a through and through laceration is the reapposition of the vermillion border. The

skin edges should be everted as the surface is closed with 6-0 interrupted black silk or nylon suture. Currently, some debate exists over closure or non-closure of any puncture wounds, but judgement is made on a case by case basis.

The predominant organism present in canine oral fluids is *Pasteurella multocida*.¹¹ Since this organism is quite virulent, all wounds large enough to require closure require prophylactic penicillin.^{12,13,14,15} Any wound may be contaminated and potentially infected by tetanus organisms. If the child has had a previous tetanus immunization, tetanus toxoid alone usually will be adequate. If the child has had no previous immunizations or the history is unknown, both tetanus immune globulin and tetanus toxoid should be given. The child's physician should be consulted for recommendation on tetanus prophylaxis.

The patient should be seen three days following the initial visit for wound inspection and removal of alternating facial sutures. At one week, the remaining sutures should be removed. Subsequent frequency of visits will be determined by the need for oral rehabilitative procedures.

Case Report

A six-year-old caucasian male was brought to the emergency room by his foster mother, one hour after having been bitten by a Labrador retriever. The child's health history was non-contributory. Vital signs were normal and stable and the child was cooperative for examination.

Extraoral examination revealed a shallow puncture wound in the midline directly under the chin. (Figure 1) A deeper puncture wound was found along the left inferior mandibular border in the area of the mental foramen. A deep puncture wound communicated into the oral cavity below the right corner of the mouth. Superior to this wound, the vermillion portion of the lip was torn loose and the wound communicated intraorally. Facial fracture evaluation proved negative. Neurological evaluation indicated no damage to sensory or motor nerves.

Intraoral examination revealed a mandibular dentoalveolar fracture with displacement of the mandibular primary central incisors and evulsion of the primary lateral incisors. (Figure 2) A vertical laceration extended down the facial bony alveolar surface over the left central incisor and a laceration ran across the top of the alveolar ridge into the right mucobuccal fold and communicated extraorally. An occlusal radiograph revealed the displacement of the primary central incisors, evulsion of the primary lateral incisors and the presence of normal permanent mandibular incisors. (Figure 3) The patient was given bilateral intraoral

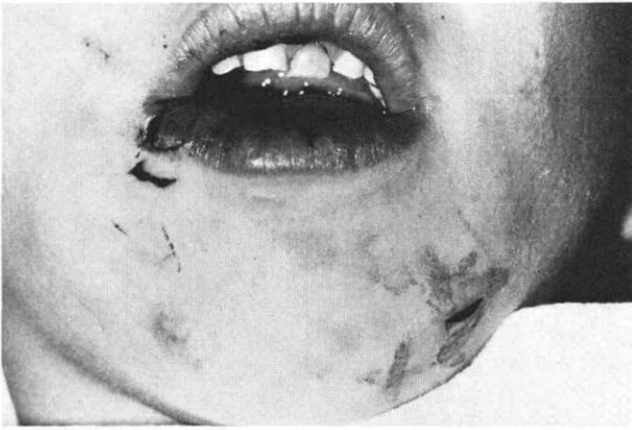


Figure 1

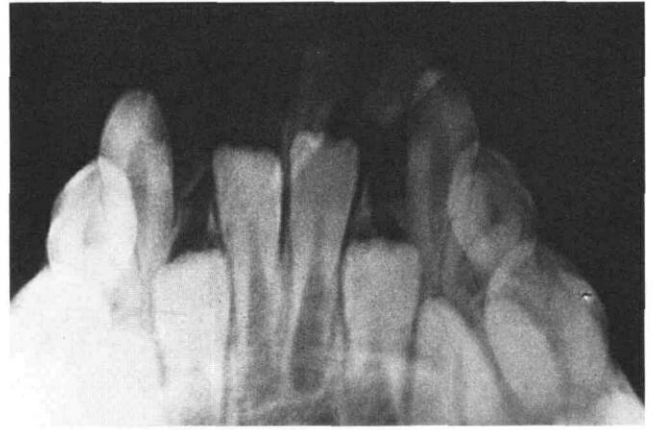

Figure 3

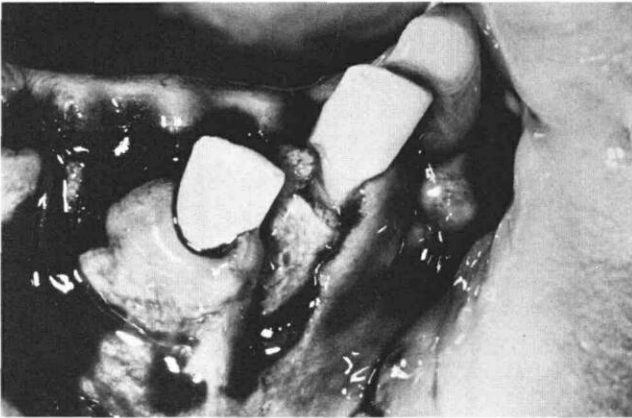


Figure 2

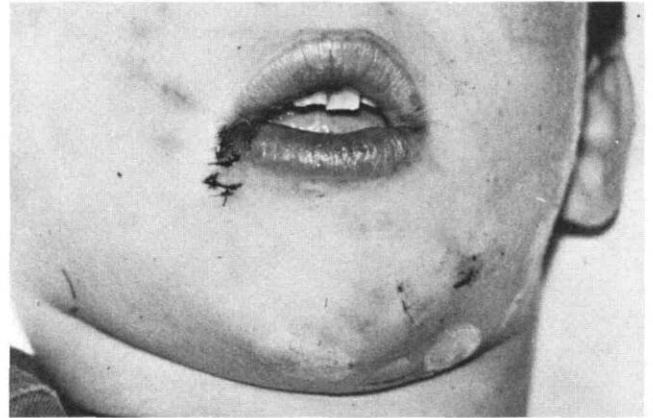

Figure 4

mental blocks and the lacerations were explored thoroughly and irrigated liberally with normal saline. The mandibular primary central incisors were moved to their original positions with digital pressure. Since the alveolar fractures were attached by the periosteum at the base, the teeth were firm in this position. The primary teeth were retained for ten days in order to allow the healing of the alveolus. The intraoral laceration was closed using 3-0 black silk sutures. Gloves were changed and the patient was draped for extraoral closure. The wound edges were undermined slightly and the wound was reirrigated; 4-0 Dexon suture was used to reappose the orbicularis oris muscle. The laceration at the right corner of the mouth was closed using 6-0 black silk sutures taking care to evert the wound edges. (Figure 4)

Since the immunization history of the patient was unknown, he was given both tetanus immune globulin and tetanus toxoid. The patient started a regimen of oral phenoxymethyl penicillin 250 mg. stat and 125 mg. q. 6. h. for one week. Local health authorities were contacted and the dog was observed for signs of rabies. No action was taken against the animal

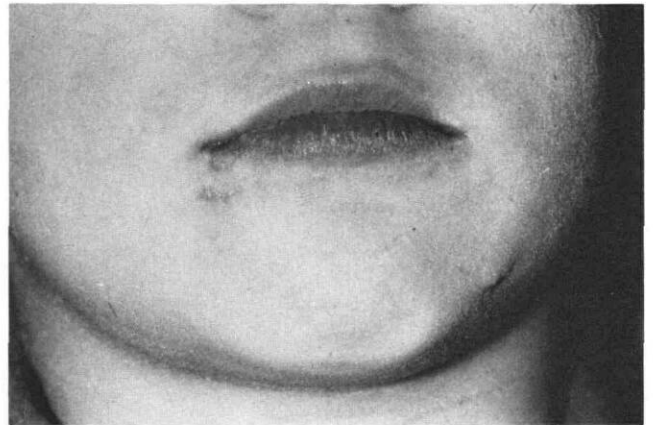


Figure 5

since the attack was largely provoked and rabies did not develop. The patient was seen three days after the initial visit. All areas were healing well and alternate facial sutures were removed. After one week the remaining facial sutures and the intraoral sutures were removed. The primary incisors were extracted with no loss of alveolar bone. The areas of facial laceration

showed a slight residual scarring at two weeks. (Figure 5) Subsequent visits demonstrated continuing improvement in these areas. The child, in spite of the traumatic incident, had remained extremely cooperative and showed no long term emotional effects.

Acknowledgments

The author would like to thank M. Anderson, D.D.S., and E. Marcuse, M.D., for recommendations during the treatment of this case, and assistance in preparation of this manuscript.

References

1. Berzon, D. R.: "The Animal Bite Epidemic in Baltimore, Maryland: Review and Update," *Am J Public Health*, 68 (6):593-5, 1978.
2. Beck, A. M., Loring, H., and Lockwood, R.: "The Ecology of Dog Bite Injury in St. Louis, Missouri," *Public Health Rep*, 90(3):262-7, 1975.
3. Douglas, L. C.: "Bite Wounds," *Am Fam Physician*, 11 (4):93-9, 1975.
4. Winkler, W. G.: "Human Deaths Induced by Dog Bites, United States, 1974-75," *Public Health Rep*, 92(5):425-9, 1977.
5. Schultz, R. C., and McMaster, W. C.: "The Treatment of Dog Bite Injuries, Especially of the Face," *Plast Reconstr Surg*, 49(5):494-500, 1972.
6. Robinson, D. A.: "Dog Bites and Rabies: An Assessment of Risk," *Br Med J*, 1(6017):1066-7, 1976.
7. Moore, R. M., Renoldson, B. Z., Moulthrop, J. I., and Parker, R. L.: "Surveillance of Animal-Bite Cases in the United States, 1971-1972," *Arch Envor Health* 32(6):267-70, 1977.
8. Berzon, D. R., and De Hoff, J. B.: "Medical Costs and Other Aspects of Dog Bites in Baltimore," *Public Health Rep*, 89(4):377-381, 1974.
9. Graham, W. P., Calabretta, A. M., and Miller, S. H.: "Dog Bites," *Am Fam Physician*, 15(1): 132-7, 1977.
10. Rapuano, R., and Stratigos, G. T.: "Mandibular Fracture Resulting from Dog Bite," *J Oral Surg*, 34(4): 359-61, 1976.
11. Bailie, W. E., Stonie, E. C., and Schmitt, A. M.: "Aerobic Bacterial Flora of Oral and Nasal Fluids of Canines," *J Clin Microbiol*, 7(2):223-31, 1978.
12. Francis, D. P., Holmes, M. A., and Brandon, G.: "Pasteurella Multocida Infections After Domestic Animal Bites and Scratches," *JAMA*, 233(1):42-45, 1975.
13. Torphy, D. E., and Ray, C. G.: "Pasteurella Multocida in Dog and Cat Bite Infections," *Pediatrics*, 43(2):295-297, 1969.
14. Herrell, W. E.: "Pasteurella Multocida Infections," *Clin Medicine*, 76(9):11-12, 1969.
15. Callahan, M. L.: "Treatment of Common Dog Bites: Infection Risk Factors," *JACEP*, 7(3):83-87, 1978.

BRYAN J. WILLIAMS is an Assistant Professor in the Departments of Pediatric Dentistry and Orthodontics, School of Dentistry, University of Detroit, 2985 East Jefferson Avenue, Detroit, MI 48207.

Requests for reprints may be sent to Bryan J. Williams at the above address.