

Aspiration of gauze pressure-pack following a dental extraction: a case report

Alejandra Villasenor, DDS, MS

Dr. Villasenor is assistant professor, Pediatric Dentistry Department, Baylor College of Dentistry Texas A&M University System and assistant director, Dental Service, Texas Scottish Rite Hospital for Children, Dallas, Texas.

Postoperative instructions after surgical or restorative procedures are a routine practice in all areas of dentistry. Postextraction instructions include information about length of the local anesthetic, diet, pain control, oral care, and bleeding control. Pressure gauze packs have proven to be effective in most cases for hemostasis control. In pediatric dental practices, where young children and children with special needs are seen, these standard postoperative instructions require careful evaluation in direct relation to the patient's age, neurologic development and, parental involvement in the child's total care. Failure to identify these special circumstances can lead to emergency situations that could easily be prevented.

There are several reports in current literature about bronchial aspiration of metal restorations,¹ ingestion of foreign bodies during dental treatment,² obstruction of endotracheal tubes with teeth,³ and related issues such as prevention and symptom recognition for proper patient management should they occur.⁴⁻⁶ However, no reports were found either detailing aspiration incidents after the patient has been discharged from the dental office setting, or outlining the treatment and prevention of this medical emergency.

Case report

The patient was a 10-year-old male well known to Texas Scottish Rite Hospital for Children, Dallas, TX, since the age of 14 months, and to the Dental Service since age seven. The patient's past medical history was extensive and included microcephaly, resolved ventriculoseptal defect, sagittal synostosis, cortical blindness, static encephalopathy, complex partial seizures, hypertonic quadriplegia, failure to thrive, asthma, and global developmental delay. This child had received his nutrition primarily by gastric tube and mobilization has been via wheel chair. His current medications include Tegretol and Artane. No known allergies were reported.

The past dental history was remarkable for one admission to the operating room for full-mouth dental rehabilitation, lingual frenectomy, and a free gingival graft to the facial aspect of all the mandibular permanent incisors at the age of eight years, eight months. Due to the patient's history of gastric tube feeding and resulting severe calculus accumulation, his frequent recall visits included full-mouth scaling, prophylaxis, and fluoride application.

During the most recent recall visit, upon the completion of full-mouth scaling and rubber-cup polishing, it was deemed

necessary to extract the upper right primary lateral incisor which exhibited significant mobility due to normal exfoliation. Due to the complex neurologic deficits of this youngster, extraction of the mobile tooth was indicated in an effort to prevent dislodgement into the airway and subsequent ingestion or bronchoaspiration after discharge. No local anesthetic was required and the extraction was accomplished without complications. Hemostasis was obtained with gauze and pressure, and the appointment was concluded with the application of topical fluoride. The postoperative instructions included routine pain management and wound care. A packet containing four 2 x 2-in gauze was dispensed to the child's mother. The indication for gauze use was only for pressure hemostasis, if significant bleeding should occur. Minimal bleeding was observed at the completion of the appointment, and the patient was discharged without a pressure pack in the mouth.

Following the discharge from the dental clinic, the patient was transported to another area of the hospital by his mother accompanied by a younger ambulatory sibling. During the transport to this area, the mother of this child placed a 2 x 2 gauze in the patient's mouth while she was in the pharmacy refilling a prescription. During the time that the child was left unattended with gauze in the oral cavity, aspiration of the dressing occurred. An emergency code was called when the child was found with alarming signs of asphyxia of unknown etiology. Once the emergency team arrived upon the scene, the child was removed from the wheel chair and placed on the floor where rapid cardiopulmonary assessment was initiated. It was then discovered that a gauze, fully saturated with saliva, had been aspirated and was promptly retrieved. Normal respiratory function was re-established and, following full recovery from this event, the patient was discharged to home without any complications. Close follow-up indicated no pulmonary sequelae in the post-treatment period.

Discussion

The indications for the use of hemostatic pressure packs in young children must be carefully evaluated when the following factors are present:

1. A child with special needs with poor oromotor tone due to neurologic involvement
2. Limited understanding of postoperative instructions relative to the patient's developmental delays or mental retardation by the parent

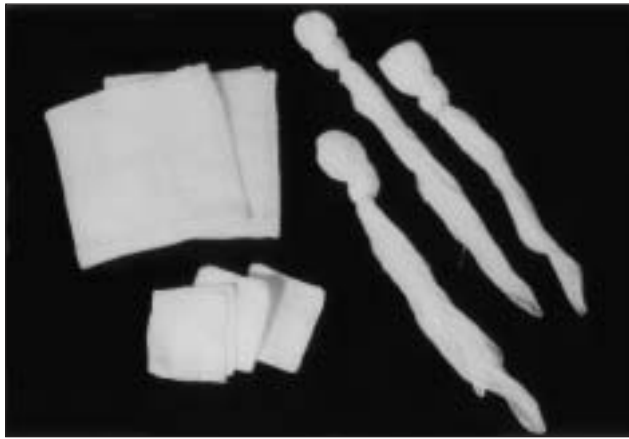


Fig 1. Modified gauze pad.

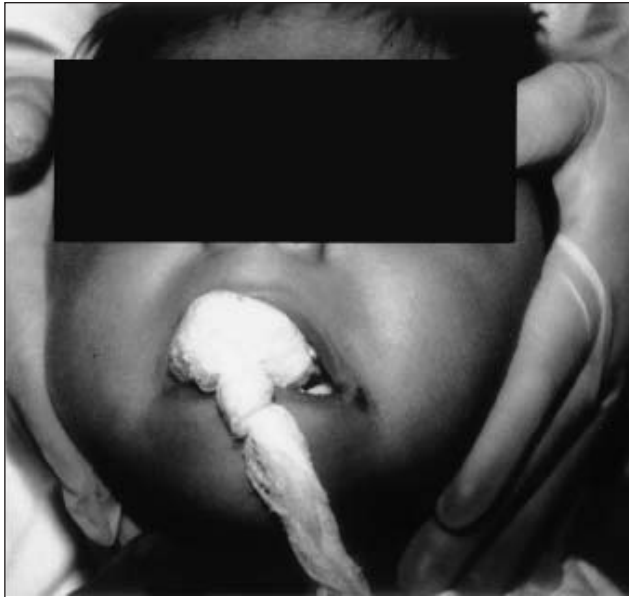

Fig 2. Modified gauze pad in use.

3. Inadequate supervision
4. Excessive salivation.

In the ideal situation, waiting until total hemostasis has been achieved prior to the patient's discharge is recommended. If a pressure pack is required in the immediate postoperative period, a modified gauze pack is a safe option (Fig 1). This large-size gauze pack can be made with one 4 x 4 and one 2 x 2 sterile gauzes tied in a knot. This "ghost" shaped pack can be inserted in the oral cavity, allowing the patient to bite and apply pressure to the wound. Easy access to the pack is visualized if removal is required, which is achieved by pulling the long end of the pack located extraorally (Fig 2). This over-sized pack will prevent accidental aspiration in young children, and especially in children who have neurological handicaps.

Postoperative instructions following a dental extraction must be carefully designed according to the needs of each patient and parent. This revised approach to the traditional pressure pack for hemostasis will prevent life-threatening complications when caring for the special pediatric dental patient.

References

1. Seals ML, Andre JM, Kellar PN: Pulmonary aspiration of a metal casting: report of a case. *J Am Dent Assoc* 117:587-88, 1988.
2. Wandera A, Conry JP: Aspiration and ingestion of a foreign body during dental examination by a patient with spastic quadriplegia: case report. *Pediatr Dent* 15:362-63, 1993.
3. Kenney JN, Laskin DM: Nasotracheal tube obstruction for a central incisor. Report of a case. *Oral Surg Oral Med Oral Pathol* 67:266-67, 1989.
4. Wilwerding TM: Preventing aspiration or ingestion of single fixed restorations. *J Prosthet Dent* 63:489, 1990.
5. Wandera A, Conry JP: Tips to prevent aspiration. *Pediatr Dent* 15:362-63, 1994.
6. Hodges ED, Durham TM, Stanley RT: Management of aspirating and swallowing incidents: a review of the literature and report of a case. *ASDC J Dent Child* 59:413-19, 1992.