

## Treatment of infantile bilateral nasal valve stenosis using an endotracheal tube stent

John H. Unkel, DDS   Joe A. Graves, MD   Lauren D. Holinger, MD  
Robert O. Cooley, DDS, MS   Rodney P. Lusk, MD

### Introduction

The nasal valve is an anterior triangular area of the nose delineated by the inferior margin of the nasal lateral cartilage, septum, and floor of the piriform aperture. On inspiration, the dilator muscles of the nose elevate the cartilage and permit widening of the anterior airway.<sup>1</sup> Cartilaginous nasal valve stenosis impairs valve dilatation and is a form of nasal obstruction. Since infants are obligate nasal breathers,<sup>2,3</sup> bilateral nasal obstruction in the neonate is a potentially life-threatening condition.<sup>3</sup> Prompt diagnosis and management of the airway is essential to avoid serious complications.

Diagnosing nasal obstruction in adults consists of a history of respiratory difficulties, which may be followed up with rhinometry.<sup>4,5</sup> In children, a history of cyanotic spells relieved by crying,<sup>6</sup> sternal retractions, or feeding difficulties, is common with nasal obstructive disorders. Passing a nasopharyngeal catheter may help locate obstructions and provide a temporary airway.<sup>7</sup> Surgical correction is a more permanent approach to nasal airway management.<sup>1</sup> We describe an interesting and uncommon case of infantile bilateral nasal valve stenosis and one treatment method. The differential diagnosis and pathophysiology are discussed.

### Case report

CR is a 2 1/2-month-old Latin male who presented to the emergency room with a history of congenital progressive nasal obstruction. The intensity of his symptoms had progressed to the point that he was having difficulty with bottle feedings and sleep. The mother also described cyanotic episodes lasting several seconds. His birth history was unremarkable and he was an otherwise healthy, full-term infant.

Physical examination revealed near total occlusion of the nasal vestibule due to stenosis of the nasal valve apparatus. The lower lateral cartilages were very prominent and thick, producing a collapsed nasal valve bilaterally (Fig 1). There were mild sternal retractions and occasional tracheal tugging at the sternal notch. There was no evidence of acute respiratory distress. The oral airway was adequate. Stenting of the nasal valve with a nasal speculum relieved the obstruction. Red rubber catheters passed easily through both nares into the

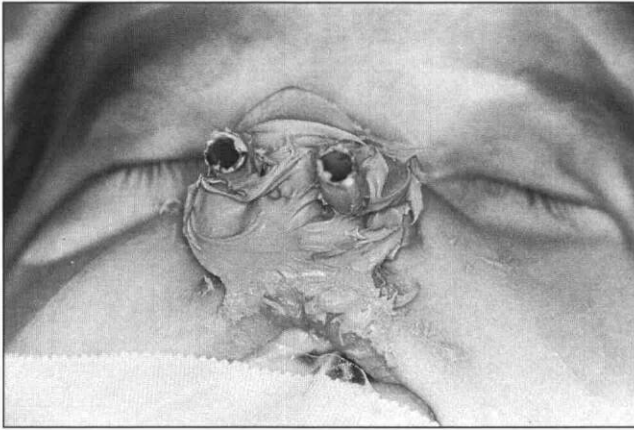
nasopharynx. Auscultation of the chest revealed normal breath sounds. Chest radiographs were within normal limits. Otherwise, his physical examination was unremarkable.

The patient was taken to the operating room and placed under general anesthesia for nasopharyngoscopy, direct laryngoscopy, and bronchoscopy. Other than occlusion of the nasal vestibules, no structural abnormalities were noted. Dental and otolaryngology services fashioned a stent fabricated from a 3.5 polyvinylchloride endotracheal tube and polyvinylsiloxane impression material to maintain his nasal airway. The endotracheal tube was cut to appropriate lengths and placed in each naris extending minimally posterior to the bony piriform aperture. The tubes were wired together externally and a polyvinylsiloxane adhesive was applied to the tubes and wire. Light body impression material was injected around the tubes (Fig 2). The tubes were then inserted into the nose. Heavy body polyvinylsiloxane was molded over the soft tissue of the nasal tip and tubes. Excess material was trimmed. The device (Fig 3) was easily removed and reinserted several times. The patient was awakened and extubated. With his mouth closed, he was able to breathe easily and comfortably through the endotracheal tube stents.

The patient was able to bottle feed normally with the stents in place. His parents were instructed carefully on care of the appliance prior to discharge. An apnea

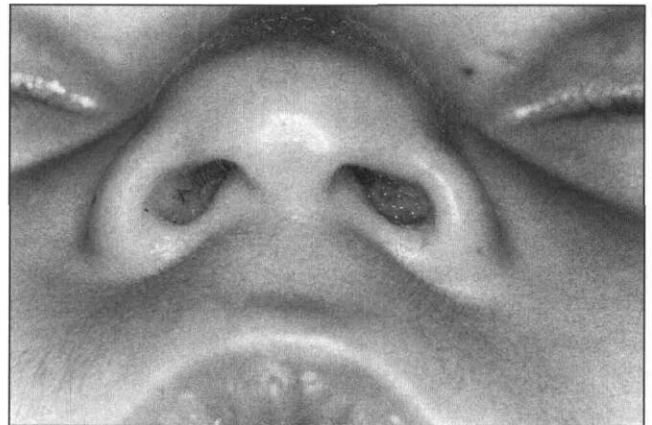

Fig 1. Bilateral cartilaginous nasal valve stenosis.

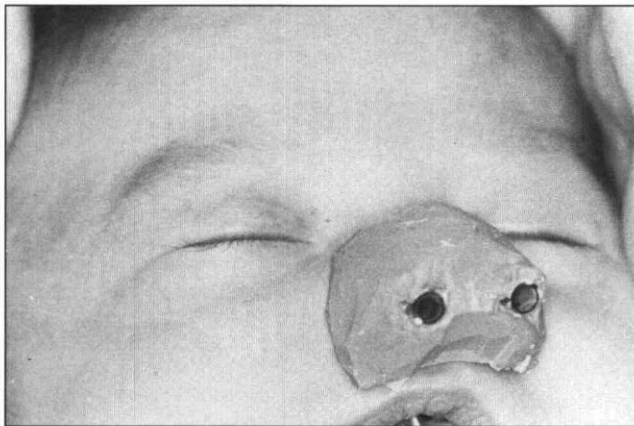

**Fig 2.** Light body polyvinylsiloxane surrounding endotracheal tubes.

monitor was placed in the home as well as a portable suction machine to keep the stents clear of secretions. The stents were maintained until the child was about 5-1/2 months old and no longer an obligate nasal breather. At that time the mother observed that, independent of the stents, the child could feed without respiratory distress. There were no complications and the patient has done well since his discharge.

## Discussion

A differential diagnosis of nasal obstruction includes upper respiratory infections,<sup>9</sup> congenital nasal and midface deformities or masses,<sup>2,8,9</sup> a small bony piriform aperture, bilateral choanal atresia,<sup>9</sup> neonatal rhinitis,<sup>3</sup> and cartilaginous nasal valve stenosis. Endoscopic evaluation under general anesthesia is an extension of the physical exam and is indicated in the presence of significant upper airway obstruction of uncertain etiology. In this child, the only observed abnormality was his bilateral cartilaginous nasal valve stenosis. This was relatively easily corrected as described.



**Fig 3.** Endotracheal tube stent.

An alternative approach might involve placing a nasopharyngeal airway tube. Since the posterior nasal airway and nasopharynx were normal, this seemed excessive and more invasive in this case. Also, prophylactic antibiotics may have been needed to prevent infection. Due to the possibility of postoperative nasal deformities or growth disturbances, we prefer to avoid surgical resection of cartilage to open the neonatal nasal vestibule. Placing an orogastric tube will sometimes provide both an airway and a feeding route. However, these are usually uncomfortable and are not ideal for long-term management. Topical decongestants<sup>10</sup> and steroid preparations<sup>11</sup> would likely not be effective as this is a cartilaginous soft tissue abnormality as opposed to a mucosal inflammatory disorder.

Neonatal bilateral cartilaginous nasal valve stenosis is seen infrequently but can be serious if not recognized and treated appropriately. This treatment is a conservative yet effective management option.

Dr. Unkel is assistant professor, department of pediatric dentistry, West Virginia University School of Dentistry and pediatric dentist, Ruby Memorial Hospital, Morgantown, West Virginia. Dr Graves is assistant clinical professor, department of otolaryngology, University of Tennessee and pediatric otolaryngologist, East Tennessee Children's Hospital, Knoxville, Tennessee. Dr. Holinger is professor, department of otolaryngology, Northwestern University, and director, pediatric otolaryngology, Children's Memorial Hospital, Chicago, Illinois. Dr. Cooley is professor, division of pediatric dentistry, Northwestern University and director, pediatric dentistry, Children's Memorial Hospital, Chicago, Illinois. Dr. Lusk is associate professor, department of otolaryngology, Washington University and director, pediatric otolaryngology, St. Louis Children's Hospital, St. Louis, Missouri.

1. Hurst W: Internal nasal implant to correct nasal valve obstruction. *Laryngol & Otol* 92:47-50, 1978.
2. Mazzara CA, et al: Neonatal respiratory distress: sequela of bilateral nasolacrimal duct obstruction. *Int J Pediatr Otorhinolaryngol* 25:209-16, 1993.
3. Tolley NS, et al: The management of neonatal rhinitis. *Int J Pediatr Otorhinolaryngol* 24(3):253-60, 1992.
4. Guilette BJ, et al: Use of nasal valve stent with anterior rhinomanometry to quantitate nasal valve obstruction. *Ann Otol, Rhinol Laryngol* 99:175-78, 1990.
5. Jones A: The nasal valve: a physiological and clinical study. *J Laryngol, Otol* 102:1089-94, 1988.
6. Cieberman A: Congenital nasal stenosis in newborn infants. *J Pediatr* 120:124-27, 1992.
7. Knecht-Junk K: Congenital nasal stenosis in neonates. *J Laryngol, Otol* 102:500-2, 1988.
8. Berkowitz B, et al: Nasal obstruction of the newborn revisited: clinical and subclinical manifestations of congenital nasolacrimal duct obstruction presenting as a nasal mass. *Otolaryngol - Head & Neck Surg* 103:468-71, 1990.
9. Bluestone CD, Stoole SE: *Pediatric Otolaryngology*, 1983, pp. 705-16.
10. Bende M, Loth, S: Vascular effects of topical oxymetazoline of human nasal mucosa. *J Laryngol Otol* 100:285-88, 1986.
11. Orgel HA, et al: Clinical rhinomanometric and cytologic evaluation of seasonal allergic rhinitis treated with beclomethasone dipropionate as aqueous nasal spray or pressurized aerosol. *J Allerg Clin Immunol* 77:858-64, 1986.