



Treatment of the avulsed tooth

Martin Trope, DMD, J.B

Dr. Trope is a Freedland professor and chair, Department of Endodontics, School of Dentistry, University of North Carolina at Chapel Hill, Chapel Hill, North Carolina.

This short article is an attempt to give the practitioner a practical guide in the sequencing and appropriate treatment for the avulsed tooth. The sequencing of the article should coincide with the sequencing of treatment. The treatment guidelines should be accepted by most experts as appropriate according to information that is currently available.

Treatment outside the dental office

1. Replant immediately after *gentle* washing if practical.
2. If not practical, store the tooth in the best (and quick est) storage medium available. Avoid dry time.
3. Storage media in order of preference are milk, saline, and saliva (buccal vestibule). Water is the least desirable storage medium.



Fig 1. Avulsed tooth placed in a solution of Hank's Balanced Salt Solution while preliminary information is obtained from the patient.

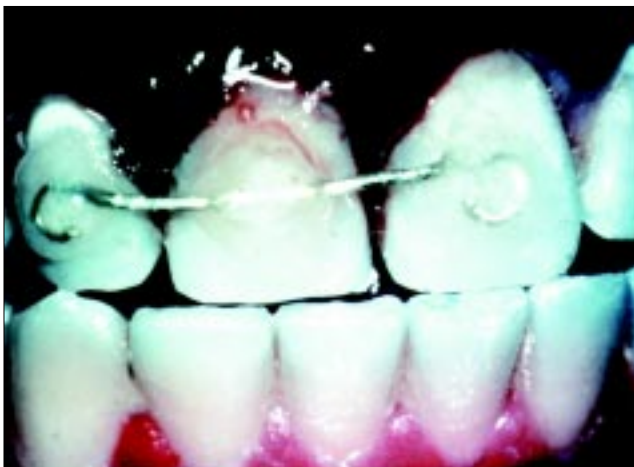


Fig 2a. Functional splint for permanent dentition.

Treatment inside the dental office

A. Emergency visit:

1. Place the tooth in Hank's Balanced Salt Solution (HBSS) (Fig 1) while a history is taken and an exam is conducted. Look for a more serious injury.
2. Prepare the socket for gentle repositioning of the tooth.

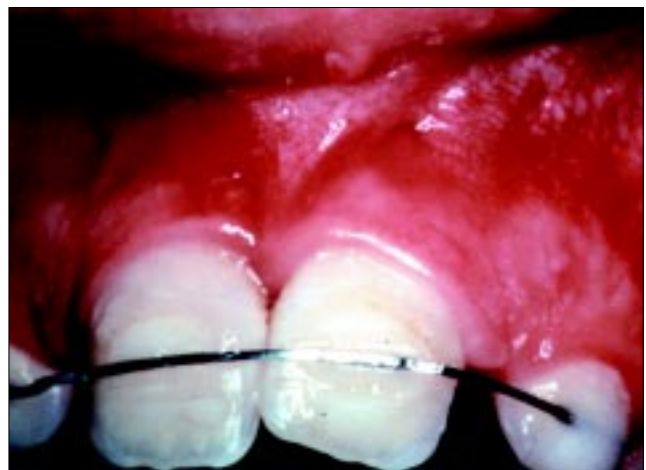

Fig 2b. Functional splint for mixed dentition.

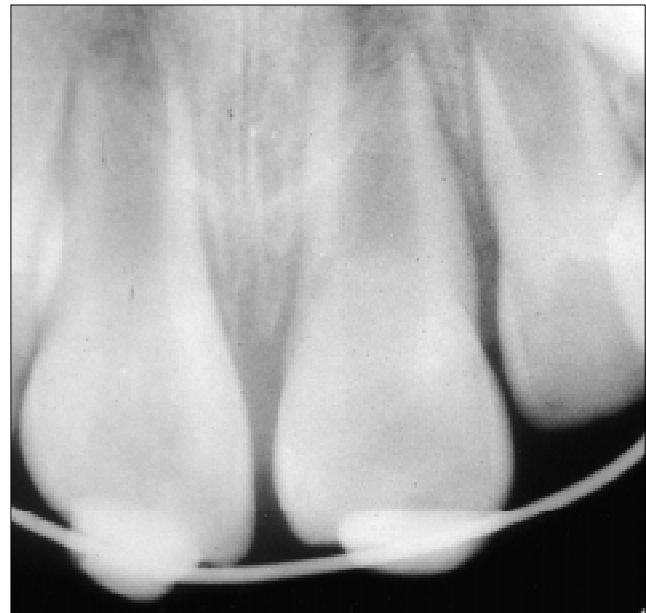

Fig 3a. Maxillary central incisors with open apices replanted and splinted soon after the accident.

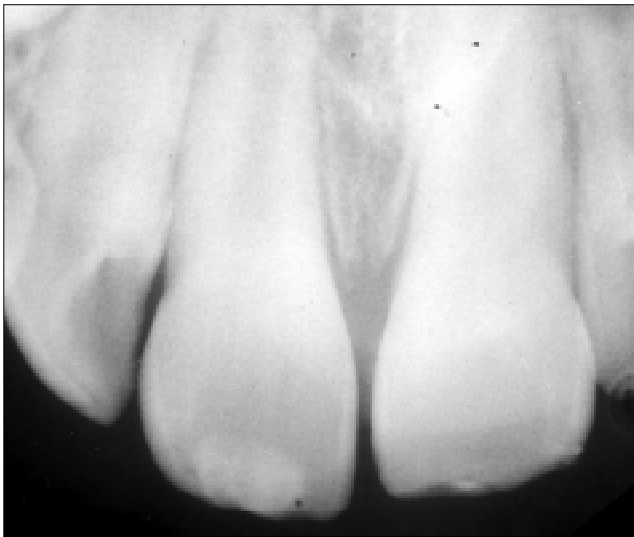


Fig 3b. Maxillary central incisors with open apices one-year recall showing successful revascularization with continued root formation.



Fig 4. Creamy mix of calcium hydroxide that is spun into the canal with a lentulo-spiral instrument. This form of placement is common for short-term use (up to 8 weeks).

3. Prepare the root.

- a. Mature tooth (closed apex)
 - Extraoral dry time <60 minutes: replant as soon as is practical.
 - Extraoral dry time >60 minutes: soak in citric acid or curette the root, soak in fluoride for 5-10 minutes, and replant.
- b. Immature tooth (open apex)
 - Extraoral dry time <60 minutes: soak in doxycycline (approx. 1mg/20ml saline) for 5 minutes and replant.
 - Extraoral time >60 minutes: same as with closed apex.

4. Apply a functional splint for 7-10 days (Fig 2). If alveolar fracture is present, rigid splint for 4-6 weeks. Suture soft-tissue lacerations, particularly in the cervical area of the avulsed tooth.

5. Administer adjunctive therapy for 7-10 days.

- a. Systemic antibiotics—tetracycline if possible.
- b. NSAIDS if possible.
- c. Chlorhexidine rinses and oral hygiene instruction.
- d. Tetanus booster consultation.




Fig 5a. Stiff mix of calcium hydroxide that is carried to the canal orifice in an amalgam carrier.

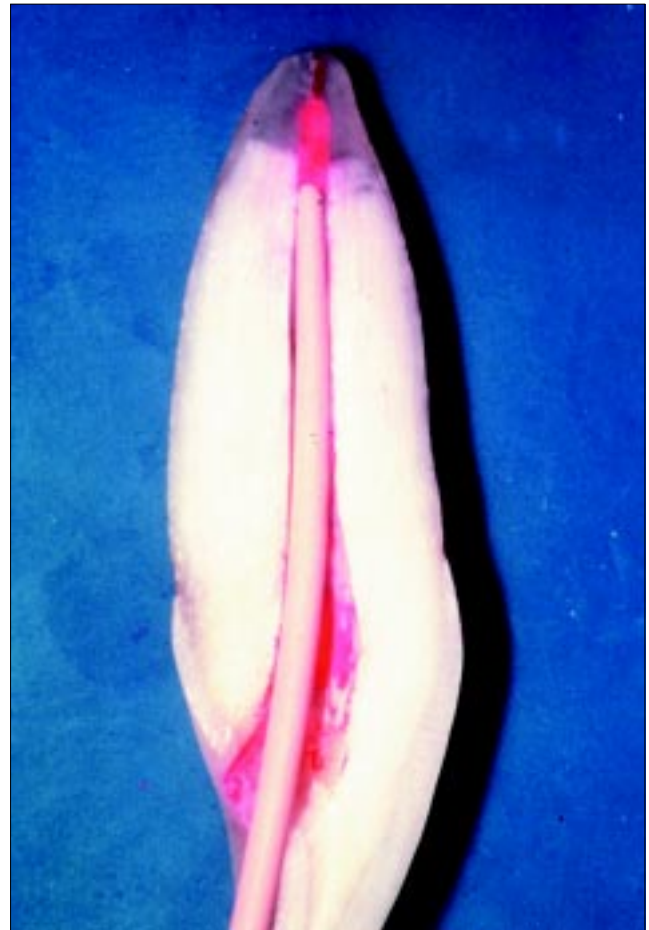

Fig 5b. The stiff mix of calcium hydroxide is condensed in apical segments until the canal is filled. Pluggers or a large gutta perch cone can be used for this purpose.

B. Second visit after 7 to 10 days:

1. Provide endodontic treatment

- a. Tooth with open apex tooth and extraoral dry time <60 minutes: No endodontic treatment initially. Monitor every 3-4 weeks for signs of revascularization (Fig 3) or pathosis. If pathosis noted, disinfect the pulp space and start apexification procedure.

- b. Tooth with open apex and extraoral dry time >60 minutes: Initiate apexification procedure.
 - c. Tooth with closed apex: Endodontics should be initiated after 7 to 10 days. Careful chemomechanical instrumentation under strict asepsis.
2. Splint is removed.
- C. Obturation visit:
- 1. Teeth with closed apices:
 - a. If endodontics was initiated 7 to 10 days after the avulsion, obturation can take place after short-term treatment with a creamy mix of calcium hydroxide (Fig 4).
 - b. If endodontics was initiated more than 14 days after the avulsion or if signs of inflammatory resorption are present, treat for the long term with a stiff mix of calcium hydroxide (Fig 5) until an intact lamina dura can be traced.
 - 2. Teeth with open apices:
 - a. Follow apexification procedure, and obturate when an intact lamina dura can be traced and an apical stop has developed.
- D. Restorations:
- 1. Temporary restorations: Should be 4 mm deep. Use reinforced zinc-oxide eugenol, acid etch composite resin, and glass ionomer cement.
 - 2. Permanent restorations: Should be placed as soon after obturation as practical. Use acid etch resin and dentin bonding agents.
- E. Follow-up:
- 1. 3, 6, and 12 months, every year for 5 years.

References

1. Trope M: Clinical management of the avulsed tooth. *Dental Clinics of North America* 39:93-112, 1995.
2. Trope M: Current concepts in the replantation of avulsed teeth. *Alpha Omegan* 90:56-63, 1997.

ABSTRACTS OF THE SCIENTIFIC LITERATURE



EXTERNAL APICAL ROOT RESORPTION OF POSTERIOR TEETH

The purpose of this study was to determine if there is a significant difference in external apical root resorption (EARR) between asthmatic and non asthmatic patients who underwent fixed appliance orthodontic treatment. 44 asthmatic patients and 97 control patients with no known medical problems were studied. An orthopantomogram was obtained prior to treatment and again within one month of debanding. External apical root resorption was measured on premolars, mesiobuccal and distobuccal roots of the upper first molars and mesial and distal roots of lower first molars. Only teeth with complete root formation were studied. The authors conclude. 1. "The combined tooth analysis showed that asthmatic patients had statistically significantly more root resorption than non asthmatics ($P=.0194$)."

2. "Because the tooth-by-tooth analysis found a similar number of sites at greater risk of EARR in both medicated and non medicated asthmatics, this study suggested that medication was not an indicator of an increased susceptibility to posterior EARR."

3. "The increased incidence of EARR in asthmatics was confined to an increase in root blunting (grade 1). Therefore, asthmatics have only a minimal risk of posterior EARR that may not adversely affect the function or longevity of posterior teeth."

Comments: Root resorption is such a difficult outcome to predict, it is interesting to see data which show even a minor correlation between a preexisting medical condition and orthodontic treatment. Even though the root resorption seen in this study does not have great clinical significance, it may serve as a biologic insight that could stimulate other studies in the area of root resorption. JEP

Address correspondence to: Anne L. Symons, BDS PhD, 200 Turbot Street, Brisbane, Queensland, 4000, Australia.

External apical root resorption of posterior teeth in asthmatics after orthodontic treatment. McNab S, Battistutta D, Taverne A, Symons AL. *Am. J. Ortho. Dentofacial Ortho.* 116-5:545-51, 1999.

19 references



DENTAL HEALTH HABITS CHANGES OVER 2 YEARS

This study reported the dental health habits change over two years of children from Finland 3 to 5 years old. A survey and an examination during the two years evaluated over 700 children. Children, age 3, who had dental caries, continued to exhibit more caries two years later. Preventive dental care decreased caries in only about one-third of the study population. Plaque is an indicator of caries risk and therefore should be a key element in health education.

Comments: Caries was not found in over 50 % of this age group. LHS

Address correspondence to: Dr. Rautava, Dept of Public Health, Univ. of Turku, Lemminkaisenkatu 1, 20520 Turku, Finland.

Changes in Dental Health and Dental Health Habits from 3 to 5 Years of Age. Mattila, M., Paunio, P., Rautava, P., Ojaniatva, A., and Sillanpaa, M. *J Public Health Dent* 58: 270-74, 1998.