

Supernumerary primary first molar and first premolar: clinical report

Michael J. Trenouth, BSc, MDS, FDS, D Orth
Raman Bedi, BDS, FDS

Abstract

A case is presented of a nine-year-old male having a supernumerary maxillary right first primary molar together with a supernumerary maxillary right first premolar. The implications of early diagnosis and orthodontic management are discussed.

The occurrence of supernumerary teeth in both the primary and permanent dentitions in the same patient seems to be rare. A review of the literature (including a computer search) revealed 28 cases reported in 10 publications.¹⁻¹⁰

In the 28 cases there were 35 supernumerary primary teeth with permanent successors: 32 were in the maxillary incisor and canine regions, 3 in the mandibular incisor region. Most of the permanent supernumerary teeth occurred at the same site as their primary predecessors, although in 3 cases they were found at the site of the adjacent teeth (the position of the other 7 was not reported). The side of occurrence was reported in 27 cases, 16 being on the left and 11 on the right.

In the primary dentition, 32 teeth were of normal morphology and more correctly would be termed supplemental teeth, 1 was geminated, and 2 were conical. In the permanent dentition, 25 were supplemental, 1 geminated, 8 conical, and 1 showed insufficient calcification to establish crown morphology. The sex of the patient was reported in 21 cases; 14 were male and 7 female, a 2:1 male-to-female ratio.

As far as can be ascertained, no fully developed supernumerary primary molars have been reported occurring either singly or in conjunction with a successional supernumerary premolar. However Oöe¹¹ reported a case of a tooth germ between the first and second primary molars of a five-month-old fetus, but at this stage it appeared only as a thickening of the dental lamina. Leche¹² reported a tooth germ in the cap stage in a three-month infant, located between the upper primary canine and first primary molar, but it is not known whether this tooth

would have developed into a primary canine or first molar.

Grahnen and Granath⁵ examined 1,173 records of Swedish children aged three to five years and found 3 cases of supernumerary primary teeth (0.3%). Out of another group of 46 patients referred specifically because they had an abnormal number of teeth, 20 had supernumerary primary teeth and 6 of these had supernumerary permanent teeth in the corresponding region (30%). In 1961 Grahnen and Lindahl reported that the prevalence of supernumerary teeth in the permanent dentition in the Swedish population was 2-3%.¹³ The occurrence in both dentitions is, therefore, greater than would be expected by chance alone. Jarvinen and Lehtinen¹⁰ examined 1,141 children who were three to four years old and found 5 supernumerary primary teeth (0.4%), one of which developed a similar anomaly in the permanent dentition (20%). Again, the occurrence is six times greater than would be expected by chance.

An association between supernumerary teeth in the primary and permanent dentitions is to be expected since primary enamel organs normally produce a successional dental lamina for the permanent teeth. Berkovitz and Thompson¹⁴ performed a histological investigation of supernumerary primary and permanent incisors in the albino ferret and believe they arose by dichotomy of primary first incisor tooth germs. Permanent supernumerary teeth appeared to develop from the successional dental lamina associated with the corresponding primary supernumerary incisor, but frequently were lost from the functional dentition by fusion with the developing first permanent incisor enamel organ.

Clinical Report

A nine-year-old Caucasian male was referred to a child dental health department by his general practitioner because the boy had refused dental treatment.

Clinical examination showed the following teeth to be erupted:

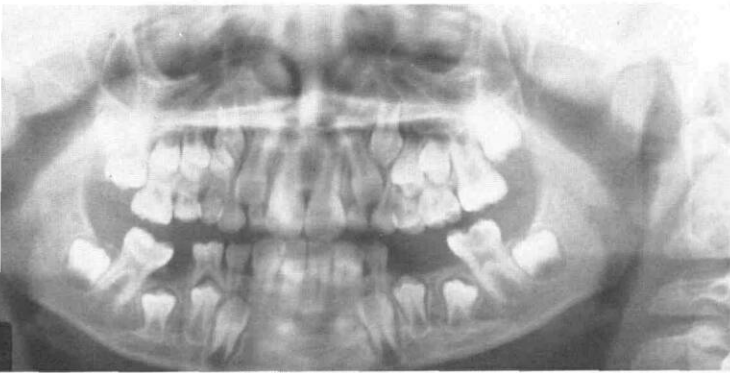


Figure 1. A panoramic radiograph showing maxillary right first supernumerary primary molar and supernumerary permanent premolar.

S
 EDDCB1/1BCDE6
 6 DC21/12C 6

A panoramic radiograph (Figure 1) showed the following teeth to be unerupted:

S
 7654432/2345 7
 7 5 43 / 345 7

Third molars were absent or had not yet developed. The upper left first permanent molar together with both mandibular first permanent molars were grossly carious. The maxillary right first permanent molar was unerupted and impacted against the second primary molar.

Clinically, the maxillary right supernumerary primary first molar was diminutive in form with distal caries, but still clearly showed the morphology of a primary molar with buccal and lingual cusps (Figure 2). Only one root was present mesially, splayed with a distal curvature typical of a primary molar (Figure 3). The supernumerary first premolar was of normal morphology and clearly present (Figure 4), but appeared slightly smaller and showed less root development than the other premolars.

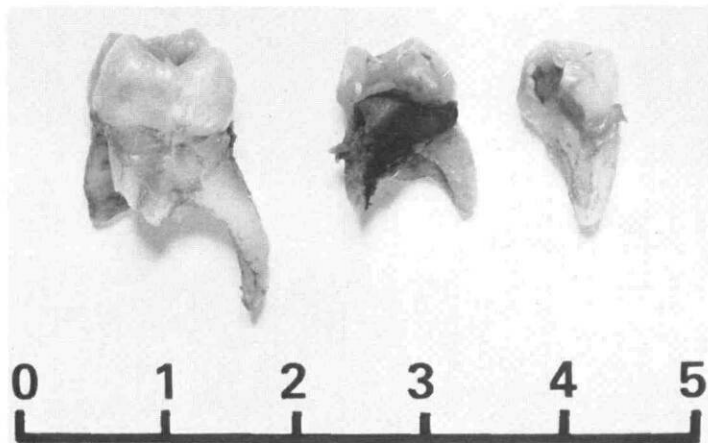


Figure 3. Lateral view of extracted maxillary right first and second primary molars and supernumerary first molar (from left to right).



Figure 2. Occlusal view of extracted maxillary right primary second, first and supernumerary first molars (from left to right).

Treatment

The following teeth were removed under general anesthesia:

S
 EDD/E6
 6 / 6

The first permanent molars were removed because of extensive caries and to relieve crowding. The primary molars were removed because of caries and to accelerate eruption of the first permanent molar and premolars in the maxillary right quadrant.

The patient is under review to improve oral hygiene and diet, and to relieve potential crowding in the maxillary right quadrant.

Discussion

The presence of a primary supernumerary tooth should not be ignored; a full radiographic examination should be done since there is an increased chance of a permanent supernumerary tooth. Early diagnosis permits an interceptive orthodontic approach, which in this case allowed early correction of arch crowding.

Most primary supernumerary teeth are erupted and asymptomatic when diagnosed; hence, it is likely that many are exfoliated without being discovered. More attention now is being given to prevention and restoration

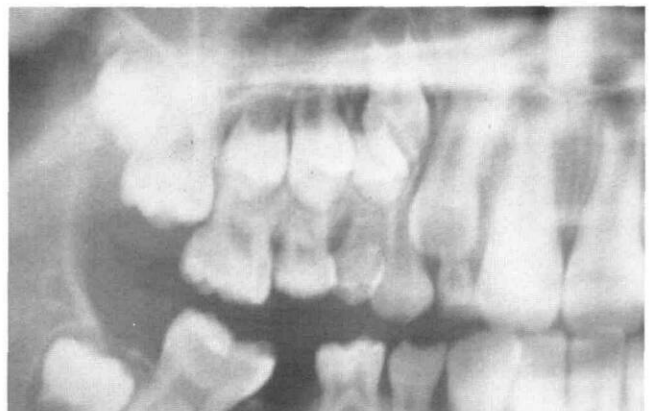

Figure 4. Radiograph showing maxillary right first supernumerary primary molar and supernumerary premolars.

in the primary dentition and, as a consequence, a greater proportion of patients with primary dentitions is being examined by members of the dental profession. Thus, the chance of supernumerary teeth being detected will increase.

We would like to thank Professor P. J. Holloway of the Department of Child Dental Health for allowing us to publish the case, and for reading the manuscript; and the Department of Medical Illustration, Manchester Royal Infirmary for preparing the photographs.

Dr. Trenouth is a lecturer, Dental Anatomy and Orthodontics and Dr. Bedi is a lecturer in Child Dental Health, University Dental Hospital of Manchester, Bridgeford St., Manchester M15 6FH. Reprint requests should be sent to Dr. Trenouth.

1. Barritt, A.T. A successional supernumerary. *Br Dent J* 72:117, 1942.
2. Munro, D. Supernumerary teeth of the permanent and deciduous dentitions: two cases. *Br Dent J* 93:321-22, 1952.
3. Townend, B.R. Two cases of duplication of deciduous laterals followed by duplication of permanent laterals. *Br Dent J* 95:47-48, 1953.
4. Brown, E.N. A case of bilateral supplemental maxillary deciduous lateral incisors. *Br Dent J* 96:81-82, 1954.
5. Grahnen, H., Granath, L.E. Numerical variations in primary dentition and their correlation with the permanent dentition. *Odont Revy* 12:348-57, 1961.
6. Robertson, N.R.E. Supplemental incisors in the deciduous and permanent dentitions. *Dent Pract (Bristol)* 13:150-51, 1962.
7. Duffy, J.H. Supernumerary deciduous and permanent mandibular incisors. *Oral Surg* 16:1201, 1963.
8. Taylor, G.S. Characteristics of supernumerary teeth in the primary and permanent dentition. *Dent Pract (Bristol)* 22:203-8, 1972.
9. Sykaras, S.N. Mesiodens in primary and permanent dentitions. *Oral Surg* 39:870-74, 1975.
10. Jarvinen, S., Lehtinen, L. Supernumerary and congenitally missing primary teeth in Finnish children. *Acta Odontol Scand* 39:83-86, 1981.
11. Oöe, T. Three instances of supernumerary tooth germs observed with serial sections of human foetal jaws. *Z Anat Entwicklungsgesch* 135:202-9, 1971.
12. Leche, W. Zur entwicklungsgeschichte des zahnsystems der saugetierte. *Ontogenie Bibliotheca Zoologica*. Stuttgart: Nagele 1895.
13. Grahnen, H., Lindahl, B. Supernumerary teeth in the permanent dentition. A frequency study. *Odont Revy* 12:290-94, 1961.
14. Berkovitz, B.K.B., Thompson, P. Observations on the aetiology of supernumerary upper incisors in the albino ferret (*Mustela putorius*). *Arch Oral Biol* 18:457-63, 1973.

Quotable Quote

If holistic health advocates were content with encouraging sensible preventive medicine or with criticizing the economic organization of American medicine, we might be enthusiastic, but they are not. If the movement were without influence on American life, we would be indifferent, but it is not. Holistic medicine is a pablum of common sense and nonsense offered by cranks and quacks and failed pedants who share an attachment to magic and an animosity toward reason. Too many people seem willing to swallow the rhetoric — even too many medical doctors — and the results will not be benign.

At times, physicians may find themselves in sympathy with the holistic movement, because some fragment of the rhetoric rings true, because of certain practices and attitudes they encounter in their daily work with colleagues and patients, or because of dissatisfaction with the economic and social organization of medicine. One hopes they will speak bluntly, but it does no good to join forces with cranks and quacks, magicians and madmen.

From: Glymour, C. and Stalker D. Engineers, Cranks, Physicians, Magicians. *The New England Journal of Medicine*, Vol. 308, No. 16, April 21, 1983.