

# Neurofibroma of the mandible in an adolescent with von Recklinghausen's disease

John B. Thornton, DMD, MA Claudia E. Tomaselli, DMD  
Brad Rodu, DDS Curtis J. Creath, DMD, MS

## Introduction

Neurofibromatosis, as identified by von Recklinghausen, is an autosomal dominant, neurocutaneous syndrome, characterized by multiple neurofibromas, cafe-au-lait spots, and iris Lisch nodules.<sup>1, 2</sup> This disorder has also been referred to as the "Elephant Man" disease, and was the subject of a play and movie depicting the life of Joseph Merrick, who suffered severely from neurofibromatosis.<sup>2</sup> Other features which can be associated with von Recklinghausen's neurofibromatosis are macrocephaly, short stature, seizures, hypertension, deafness, constipation, kyphoscoliosis, developmental and learning disorders, cosmetic disfigurement, and neurofibrosarcomas, among others.<sup>3</sup> This genetic disorder was noted as early as 1793, but credited to Frederick von Recklinghausen who, in 1882, described two cases of his own and several others from the literature.<sup>4</sup> Neurofibromatosis occurs in one of every 3,000 live births in the United States, with more than 80,000 cases reported in 1981.<sup>5</sup> There are no ethnic or racial predilections for the disease.<sup>2</sup> Neurofibromatosis is a progressive disease which becomes more apparent and severe with time.<sup>3</sup> When puberty is reached, neurofibromas often may become visible for the first time, and any which already are present will increase in size.<sup>3</sup>

Several varieties of neurofibromatosis other than von Recklinghausen's disease have been identified. Recent research indicates that there are at least eight types, with von Recklinghausen (NF-I) being the classical and most common type. NF-I comprises 85-95% of all cases.<sup>5</sup> The genetic transmission of NF-I shows an autosomal dominant pattern of inheritance, but most cases occur as a result of a new mutation.<sup>6</sup> It has one of the highest spontaneous mutation rates for human genetic diseases.<sup>7</sup> New mutations are responsible for 50% or more of all NF-I cases.<sup>6</sup>

The purpose of this article is to present a case of NF-I in a 15-year-old patient with an unusually massive, inoperable, plexiform neurofibroma of the mandible. This lesion also was accompanied by severe hypoplasia of the mandible in the area of the lesion. These findings are discussed in relation to a review of manifestations of NF-I which follows.

## Clinical Findings of NF-I: An Overview

Although there are numerous clinical findings which may be associated with NF-I, this review is directed

toward identifying and describing the classical features of NF-I which are cafe-au-lait spots, neurofibromas, and iris Lisch nodules.

Cafe-au-lait spots (CLS) are seen in nearly all cases of NF-I.<sup>2</sup> CLS are obvious at birth in most cases, but tend to increase in number and definition by the first year of age.<sup>3</sup> The typical CLS range in size from 10 to 30 mm in diameter but can be larger or smaller than this range. They are ovoid in shape, generally of a pale yellow-brown color, and have sharp, well-defined borders that are usually smooth.<sup>3, 8</sup> CLS in NF-I are seen anywhere on the body except for the scalp and eyebrows, palms and soles.<sup>2, 3</sup> The presence of six or more CLS, each 15 mm in diameter is considered diagnostic of NF-I.<sup>2, 3</sup> Some authors, however, emphasize caution in using this criterion alone because of the extreme clinical heterogeneity of NF-I, and because some alternative disorders may display CLS (i.e., Russell-Silver syndrome and tuberous sclerosis).<sup>2, 9</sup> Other pigmentary features of NF-I include freckling typically seen in the axillary region, but also appearing in the inguinal folds and inframammary region.<sup>3</sup> Freckling is a cluster or clusters of small hyperpigmented macules of 1 to 3 mm, and similar to CLS in color.<sup>2</sup>

The neurofibroma is a benign tumor originating from nerve tissue composed primarily of Schwann cells, fibroblasts, and perineural cells.<sup>10</sup> Three types of neurofibromas have been identified from a clinical perspective: cutaneous, subcutaneous, and plexiform.<sup>2</sup> Discrete cutaneous neurofibromas occur within the dermis and epidermis. They move with the skin and are sessile, but become pedunculated at a later stage. They are reddish to bluish, soft, and usually not painful. In the later stages of NF-I, these cutaneous neurofibromas may cover all areas of the body, including the hands and soles of the feet.<sup>2</sup> Subcutaneous neurofibromas occurring below the dermis have an ovoid spherical shape and may become tender. The cutaneous or subcutaneous neurofibromas can progress from the size of a pea to that of a grapefruit or larger.<sup>3</sup> The plexiform neurofibroma is made up of numerous, branching, fingerlike projections. This tumor can occur superficially or into the deeper tissues. Due to the extensive network of the tumor, complete surgical removal is at times impossible without extensive removal of normal tissue.<sup>2, 11</sup>

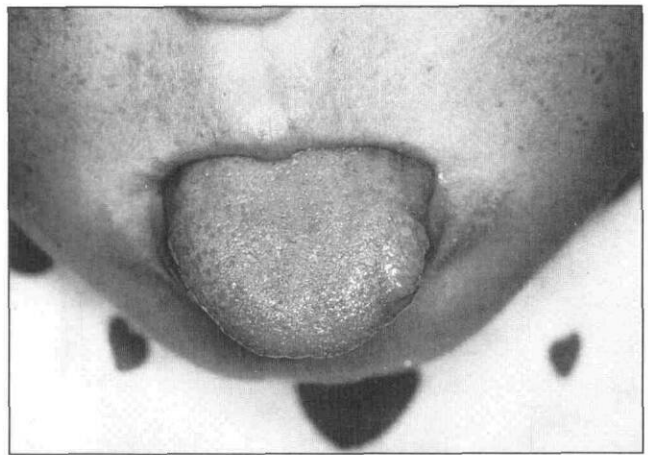
One of the more serious concerns for patients with NF-I is an increased risk for developing malignancies. The most common form of cancer which may occur with NF-I is neurofibrosarcoma, or malignant schwannoma; however, other neurogenic cancers may be found in association with NF-I as well.<sup>2</sup>

Lisch nodule of the iris is another clinical finding which is pathognomonic of NF-I. These nodules are described pathologically as melanocyte hamartomas.<sup>2</sup> They occur bilaterally and develop gradually with age. By age 6 years, they are found in 10% or less of all patients, 50% by age 29, and nearly 100% by age 60.<sup>2</sup> Lisch nodules appear as small dark nodules on light-colored irises (i.e., blue, hazel, or light brown) and light masses on brown or dark-brown irises. They often can be visualized by using an ordinary hand held ophthalmoscope, and require no intervention. It should be noted that there are other serious ocular complications (i.e., neurofibroma of the eyelid and orbit, optic glioma, and glaucoma) which may be associated with neurofibromatosis and may require treatment.<sup>12</sup>

### Oral Findings in NF-I

The frequency of oral manifestations of neurofibromatosis varies from between 4–7% to as high as 72% of cases.<sup>7, 13, 14</sup> In a more recent study, the frequency of oral involvement was shown to be approximately 92%.<sup>1</sup> These differences were due in part to the absence of panoramic radiographs for evaluation of bony findings in some of the earlier studies. Neurofibromas of the oral soft tissue have been reported in the literature; the tongue, being the most common site (Fig 1), usually is macroglossic.<sup>4, 7</sup> Other areas of oral soft tissue involvement include the buccal mucosa, the alveolar ridge, gingiva, lips, the palate, the floor of the mouth, and the pharyngomaxillary space.<sup>4, 15–18</sup> Another report on 24 patients with neurofibromatosis noted enlargement of the fungiform papillae in seven patients (31.89%), a wide inferior alveolar canal in six patients (27.2%), an enlarged mandibular foramina in six patients (27.2%), oral soft tissue neurofibromas in six patients (27.2%), and intrabony lesions in four patients (18%).<sup>8</sup>

Intrabony mandibular neurofibromas have been reported in the literature, but are considered quite uncommon.<sup>1, 8, 9, 16, 19</sup> Shapiro and co-workers found from radiographs that four of 24 patients had intrabony lesions.<sup>8</sup> A radiographic study by D' Ambrosio and coworkers of 38 patients with neurofibromatosis revealed that four had intraosseous lesions.<sup>1</sup> Hypoplastic areas of the orofacial complex have been shown in patients with neurofibromatosis.<sup>1, 20</sup> Areas noted to be hypoplastic include the maxillae, the zygomatic bone, the temporomandibular joint, and the ramus of the



**Fig 1.** Neurofibroma on the border of the tongue in a child patient.

mandible. Shortening of the ramus, notching of the inferior border of the mandible, and enlarged lingual openings are other hard tissue findings reported in the literature.<sup>4</sup>

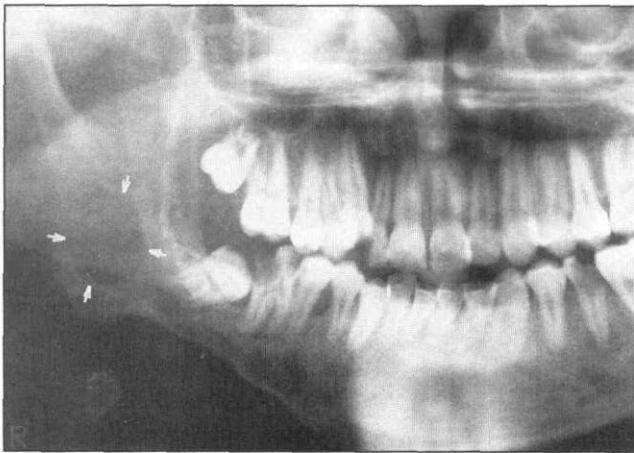
Intracranial nerves also can be involved in NF-I. Cranial nerve VII and IX involvement results in decreased taste and gag reflexes. If cranial nerves V or VII are affected, the tongue can deviate to one side and the patient may experience altered sensation.<sup>4</sup>

### Case Report

A 15-year-old African-American male came to the dental clinic at The Children's Hospital in Birmingham, Alabama, in May of 1991, with a chief complaint of severe pain in the right posterior mandibular area. Clinical examination revealed mild swelling and asymmetry on the right side of the jaw and multiple, firm, mobile nodules in the right submandibular area, the submental region, and the area of the tail of the parotid gland. There was a moderate intraoral swelling on the right side of the posterior mandible, which was hard to palpation. The mandibular right permanent first molar was severely decayed and a periapical radiograph showed a radiolucency involving apices of the roots and extending into the furcation area. A panoramic radiograph (Fig 2, page 349) revealed an impacted mandibular right second molar and a large intrabony lesion in the ramus on the same side. This lesion appeared to extend into the body of the mandible near the premolars. The radiograph also showed severe hypoplasia of the right mandibular angle, the posterior body, and the condylar neck and head.

### Past Medical and Family History

The patient had been diagnosed with neurofibromatosis at age 9 years. In 1981, he had a

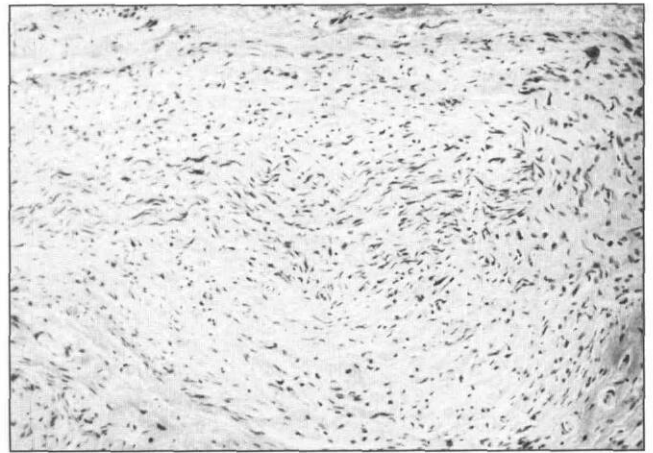


**Fig 2.** The plexiform neurofibroma is in right side of the mandible (see arrows), and hypoplasia of the mandible is noted on the same side along the posterior border of the body, at the angle, and involving the condyle.

tumor removed from the right posterior area of the mandible. The diagnosis at that time indicated that the lesion was an odontogenic fibroma. A mass was excised in 1984 from the right submandibular area. This mass was described as not being well-encapsulated and had multiple pseudopods of tumor proliferating throughout his neck in the submandibular area. According to the surgical report, the complete tumor could not be removed and appeared to arise from a single enlarged nerve trunk which emerged from the area of the angle of the mandible. The lesion was diagnosed as a plexiform neurofibroma, based on histology. Shortly after this, a neurofibroma was removed from his right posterior iliac crest. Since 1984, his compliance has been poor and he has only been seen sporadically at Children's Hospital for emergency dental care. At the time of this dental visit, the patient was not taking any medications and denied any allergies. His mother reported that her son had experienced a decrease in visual acuity secondary to cataracts, frequent headaches, and multiple cafe-au-lait spots on his back, chest, and extremities. She also reported that he had scoliosis in the lower thoracic and the lumbar spine. He had a history of a ventricular septal defect with spontaneous closure. Lastly, the family history revealed that his mother, maternal aunt, and grandfather also have neurofibromatosis.

### Clinical Course

This patient was referred to the Department of Oral and Maxillofacial Surgery at the University of Alabama School of Dentistry to assess the intrabony lesion and to extract several teeth. Before admission to the hospital for surgery, an ECG and a CT scan were performed to determine the size and location of the lesion. Treatment was rendered without complication and the patient



**Fig 3.** Histological section of plexiform neurofibroma biopsied from the mandibular lesion.

was released from the hospital after surgery. Histological sections showed interlacing of nerve tissue set in a fibrous connective tissue matrix (Fig 3). The nerve tissue contained numerous Schwann cells containing fusiform nuclei. Focal areas of myxoid change were noted. Numerous mast cells were seen scattered throughout the lesion. These features were consistent with a plexiform neurofibroma, commonly associated with neurofibromatosis but never reported in the mandible. The plexiform neurofibroma of the neck and submandibular area extended into the mandible. After consulting an ENT specialist, it was decided that surgery would not resolve this lesion because of its size and the extensive infiltration of adjacent tissues.

### Discussion

A case of neurofibromatosis of the more common von Recklinghausen's type (NF-I) in a 15-year-old patient has been presented. The major dental feature of this case from a dental perspective is the large plexiform neurofibroma located in the mandible involving the surrounding soft tissue in the submandibular area and neck. There is a strong possibility that this lesion may have evolved from the mass excised from his right submandibular area in 1984, which was diagnosed as a plexiform neurofibroma. Even though oral manifestations are possible with NF-I, there is wide variability in the reporting on the frequency of oral findings. One certainty in the oral involvement of NF-I is that soft tissue (i.e., tongue, buccal mucosa, gingiva, and palate) appears to be the most common site for neurofibroma formation, especially the tongue.<sup>1, 8</sup> Oral intrabony lesions, on the other hand, occur with less frequency and, according to some reports, may be rather uncommon.<sup>16, 21</sup> This point, however, could be debated if

other reports are reviewed which showed intrabony lesions occurring in the approximate range of 11–18%.<sup>1, 8</sup> Other reports on intrabony lesions provide sparse information on the lesions and no histological reports or diagnoses of the lesions. Only two radiographs were found in the case reports, and these showed relatively small and fairly well-encapsulated lesions.

The uniqueness of this case report is the type, size, and extensiveness of the lesion, which was biopsied and diagnosed as a plexiform neurofibroma. Also unusual was the severe hypoplasia of the mandible on the same side as the lesion. Such a case has not appeared in the literature. Hypoplasia was described in two of the few reports available, and was referred to as osseous dysplasia in one report and hypoplasia in the other.<sup>1, 20</sup>

This case has an uncertain prognosis due to the nature of the plexiform neurofibroma, the extent of involvement, and the fact that this lesion is inoperable. Some of the problems associated with this lesion as it continues to enlarge are undermining of the mandible in the area of the lesion leading to pathologic fracture, and cosmetic disfigurement.

Dr. Thornton is associate professor, Pediatric Dentistry and director, Postdoctoral Program in Pediatric Dentistry; Dr. Tomaselli is resident, Pediatric Dentistry; Dr. Rodu is professor, Oral Pathology; and Dr. Creath is assistant professor, Pediatric Dentistry, University of Alabama at Birmingham.

1. D'Ambrosio JA, Landlais RP, Young RS: Jaw and skull changes in neurofibromatosis. *Oral Surg* 66:391–96, 1988.
2. Reynolds RL, Pineda CA: Neurofibromatosis: review and report of cases. *J Am Dent Assoc* 117:735–37, 1988.
3. Riccardi VM, Eichner JE: Neurofibromatosis: Phenotype, Natural History, and Pathogenesis, 1st ed. Baltimore, MD: The John Hopkins University Press, 1986, pp 37–55.
4. Arendt DM, Schaberg SJ, Meadows JT: Multiple radiolucent areas of the jaw. *J Am Dent Assoc* 115:597–99, 1987.
5. Riccardi VM: von Recklinghausen neurofibromatosis. *N Engl J Med* 305:1617–27, 1981.
6. Riccardi VM: Neurofibromatosis: clinical heterogeneity. *Current Problems in Cancer* 8:3–24, 1982.
7. Smith PW: Recognizable Patterns of Human Malformation, 3rd ed. Philadelphia: WB Saunders Co, 1982, pp 377–79.
8. Shapiro SD, Abramovitch K, Van Dis ML et al: Neurofibromatosis: oral and radiologic manifestations. *Oral Surg* 58:493–98, 1984.
9. Gorlin RJ, Pindborg JJ, Cohen Jr MM: Syndromes of the Head and Neck, 2nd ed. New York: McGraw-Hill Book Co, 1976, pp 622, 704.
10. Shafer WG, Hine MK, Levy BM: A Textbook of Oral Pathology, 4th ed. Philadelphia: WB Saunders Co, 1983, pp 8–9.
11. Skouteris C, Sotereanos G, Strauss R: Parotid mass in a patient with von Recklinghausen's disease. *J Oral Maxillofac Surg* 47:495–501, 1989.
12. Brownstein S: Neurofibromatosis, in the Eye in Systemic Disease, DH Gold, TA Weingeist eds. Philadelphia: JB Lippincott, 1990, pp 447–50.
13. Borberg A: Tuberosus sclerosis and von Recklinghausen's neurofibromatosis. *Acta Psychiatr Neurol Scand* 71 (Suppl): 1–239, 1951.
14. Preston FW, Walsh NS, Clarke TH: Cutaneous neurofibromatosis (von Recklinghausen's disease): clinical manifestations and incidences of sarcoma in sixty-one patients. *Arch Surg* 64:813–27, 1952.
15. Miles DA, Wright BA: Palatal swelling associated with multilesional disorders: report of cases. *J Oral Maxillofac Surg* 44:666–68, 1986.
16. Polak M, Polak G, Brocherion C et al: Solitary neurofibroma of the mandible: case report and review of the literature. *J Oral Maxillofac Surg* 47:65–68, 1989.
17. Watts P, Theaker J: A rare cause of maxillary enlargement: von Recklinghausen's neurofibromatosis. *Brit J Oral and Maxillofac Surg* 24:452–58, 1986.
18. Baden E, Pierce HE, Jackson WF: Multiple neurofibromatosis with oral lesions. *Oral Surg* 8:263–80, 1955.
19. Freedus MS, Doyle PK: Multiple neurofibromas with crab manifestations. *J Oral Surg* 33:360–63, 1975.
20. Koblin I, Reid B: Changes in the facial skeleton in cases of neurofibromatosis. *J Maxillo Facial Surg* 3:23–27, 1975.
21. Das Gupta TK, Brasfield RD, Strong EW et al: Benign solitary schwannomas (neurilemmomas). *Cancer* 24:355–66, 1969.