



## Dental agenesis in hemifacial microsomia

A. Silvestri, MD, ENT, DDS G. Natali, MD M.T. Fadda, DDS

### Abstract

*Hemifacial microsomia (HM) is an asymmetrical congenital deformity of the head and face caused by anomalous development of the structures derived from the first and second branchial arches. This study evaluates the incidence of agenesis and dental inclusions in HM patients. Sixty-three HM patients, 27 male and 36 female, ranging from 7 to 43 years had monolateral (61) and bilateral (2) presentation. From clinical examination, photographs, and various radiographs, the following manifestations were noted: 11 patients had tooth agenesis with at least one on affected side and 5 patients had dental inclusions. The greater the severity of HM, the greater likelihood of agenesis. Third molars were most commonly missing. Dental inclusions did not show a relationship to severity. (Pediatr Dent 18:48-51, 1996)*

**H**emifacial microsomia (HM) is classified as an asymmetrical congenital deformity of the head and face caused by anomalous development of the structures originating from the first and second branchial arches.<sup>1,2</sup>

The first two branchial arches evolve into the skeletal, muscular, vascular, neural, and epithelial structures of the frontal block.<sup>3</sup> The first branchial arch or mandibular arch develops into the maxillary process and the maxillary, palatine, and zygomatic bones. The mandibular process becomes the mandible, the trigeminal nerve and the anterior part of the pavilion of the ear, and the sphenomandibular ligament. The second or hyoid arch is the embryonic precursor of the posterior portion of the pavilion of the ear, the stapes, the anvil, the anterior part of the hyoid bone, and the facial nerve.<sup>1</sup>

Irregular development of the first and second branchial arches comes from vascular alterations (stapedial artery damage)<sup>4</sup> and causes malformations of the outer ear, middle ear, mandible and temporomandibular articulation, masticatory muscles, facial muscles, and other soft tissues on the affected side. In more severe cases, other facial structures such as the orbit, eye, nose, skull, and neck may be involved.

Any structure originating from the first and second branchial arches may be involved by the malformation to some extent. The clinical picture may vary considerably.

### Etiopathological considerations

The etiopathogenesis of hemifacial microsomia is not entirely clear. The most plausible hypothesis is that the stapedial artery is responsible for all the developmental alterations of those structures derived from the first and second branchial arches.

From studies regarding evolution of the cranial arteries in human embryos, Padgett demonstrated that facial vascular development is determined by a series of passages and anastomoses including the primitive aortic arches. The first aortic arch rapidly disappears but not before a small mandibular artery has irrigated the anterior maxilla.

As the first arch regresses, the stapedial artery is forming from the second arch (around the 33rd day). This artery irrigates the facial structures until they are reached by the external carotid artery around the 45th day.

The stapedial artery divides into a supraorbital branch and an infraorbital branch. The supraorbital anastomoses with the ophthalmic branch of the internal carotid to provide the necessary circulation for development of the eye and the periorbital structures. The infraorbital branch is required for development of the pavilion of the ear, stapedius, maxilla, and the mandible until these structures begin to get their blood supply from the internal maxillary artery, a branch of the external carotid. The most distant branch of the stapedial artery anastomoses with branches of the internal carotid to form the middle meningeal artery.<sup>5</sup>

Poswillo et al<sup>4</sup> administered triazene to pregnant rats and thalidomide to pregnant monkeys, thus producing a hemorrhage of the stapedial artery together with hematoma. The animals' offspring presented craniofacial asymmetry in the region of the first and second branchial arches. Poswillo hypothesized that rupture of the stapedial artery could be responsible for the first and

**TABLE 1. CLASSIFICATION OF HEMIFACIAL MICROSOMIA ACCORDING TO JD DAVID ET AL, THE SAT MULTISYSTEM CLASSIFICATION**

*Skeletal categories*

---

S<sub>1</sub> = Small mandible with normal shape  
 S<sub>2</sub> = Condyle, ramus, and sigmoid notch identifiable but grossly distorted; mandible strikingly different in size and shape from normal  
 S<sub>3</sub> = Mandible severely malformed, ranging from poorly identifiable ramal components to complete agenesis of ramus  
 S<sub>4</sub> = An S<sub>3</sub> mandible plus orbital involvement with gross posterior recession of lateral and inferior orbital rims  
 S<sub>5</sub> = The S<sub>4</sub> defects plus orbital dystopia and frequently hypoplasia and asymmetrical neurocranium with a flat temporal fossa

---

*Auricle categories*

---

A<sub>0</sub> = Normal  
 A<sub>1</sub> = Small, malformed auricle retaining characteristic features  
 A<sub>2</sub> = Rudimentary auricle with hook at cranial end corresponding to the helix  
 A<sub>3</sub> = Malformed lobule with rest of pinna absent

---

*Soft-tissue categories*

---

T<sub>1</sub> = Minimal contour defect with no cranial nerve involvement  
 T<sub>2</sub> = Moderate defect  
 T<sub>3</sub> = Major defect with obvious facial scoliosis, possibly severe hypoplasia of cranial nerves, parotid gland, muscles of mastication; eye involvement; clefts of face or lips

second branchial arch syndrome. He demonstrated that the extent of the damage varies according to the extent of the hematoma. In smaller lesions, the hematoma was confined to the area where the pavilion and middle ear would later be. In cases of more severe damage, the hemorrhage also affected the outlying areas of the first and second branchial arches. In fact, the first and second branchial arch syndrome often involves part of the temporal bone, even though it does not originate from these structures.

### Clinical assessment

The clinical presentation of hemifacial microsomia generally manifests as one of three principal deformities:<sup>6</sup> 1) auricular hypoplasia, 2) mandibular hypoplasia, or 3) hypoplasia of the soft tissues.

However, other anatomical structures may be involved by the malformation such as the cheekbone, pterygoid process, sphenoid bone, temporal bone, mastoid process, facial nerve and muscles, parotid gland, cutaneous and subcutaneous tissues, tongue, soft palate, pharynx, and nasal floor.<sup>1,7-9</sup>

The malformation always affects the condyle, and this represents an important parameter for diagnosis and therapeutic management. In fact, mandibular malformation and degree of facial asymmetry are closely correlated to the extent of condylar hypoplasia.<sup>1</sup> Skeletal malformation is related to dental malocclusion, which may take the form of dental crowding (more severe on the affected side), inclination of the anterior teeth toward the side of the malformation, cross-bite on the same side as the lesion, as well as dental agenesis and altered dental eruption.

Despite the fact that dental malocclusion is strictly proportionate to the skeletal malformation, no scientific proof indicates that the embryological damage respon-

**TABLE 2. DISTRIBUTION OF MISSING TEETH, INCLUSIONS, AND POTENTIAL INCLUSIONS BY CASE TYPE\***

Clinical case	Case type	Side H.M.	Missing Teeth*				Inclusions*			Potential Inclusions		
			Incisors	Premolars	Molars	Total	Premolars	Molars	Total	Canine	Molars	Total
1	S <sub>1</sub> A <sub>0</sub> T <sub>1</sub>	L	7. 10. 23.			3						
2	S <sub>1</sub> A <sub>0</sub> T <sub>1</sub>	R			1. 17. 32.	3						
3	S <sub>2</sub> A <sub>0</sub> T <sub>1</sub>	L			1. 16. 17.	3						
4	S <sub>2</sub> A <sub>0</sub> T <sub>1</sub>	R			1. 32.	2		30.	1		31.	1
5	S <sub>2</sub> A <sub>2</sub> T <sub>1</sub>	R			1. 16. 17. 32.	4						
6	S <sub>2</sub> A <sub>3</sub> T <sub>2</sub>	R			30.	1						
7	S <sub>3</sub> A <sub>1</sub> T <sub>2</sub>	R			32.	1						
8	S <sub>3</sub> A <sub>3</sub> T <sub>2</sub>	L	23. 26.		1. 16. 17.	5						
9	S <sub>3</sub> A <sub>1</sub> T <sub>3</sub>	R		29.		1						
10	S <sub>3</sub> A <sub>3</sub> T <sub>3</sub>	R		4. 13. 29.		3						
11	S <sub>4</sub> A <sub>3</sub> T <sub>2</sub>	R		4. 13. 28.		3				22.		1
12	S <sub>2</sub> A <sub>0</sub> T <sub>1</sub>	R					20.		1			
13	S <sub>2</sub> A <sub>0</sub> T <sub>1</sub>	L						17.	1			
14	S <sub>2</sub> A <sub>0</sub> T <sub>1</sub>	L									17.	1
Total			5	7	17	29	1	2	3	1	2	3

\* Tooth identified by 1-32 numbering system.

sible for the malformation directly involves the dentogingival lamina and subsequently odontogenesis.

This study evaluated the incidence of agenesis and dental inclusions of patients with hemifacial microsomia.

## Methods and materials

This study was performed on patients with hemifacial microsomia who were referred to the maxillofacial surgery division of Rome "La Sapienza" University.

The sample consisted of 63 patients (27 male, 36 female) ranging from 7 to 43 years old (average 18.7). Hemifacial microsomia was monolateral in 61 (36 right, 25 left) and bilateral in two.

Each patient was examined clinically, photographically, and radiographically with lateral, A-P, and axial views; panoramic projections; and TMJ tomograms and was classified according to the S.A.T. scale used in our center (Table 1).<sup>10</sup>

The panoramic films allowed evaluation of any agenesis or dental inclusions of the various sectors of the arch.

Dental agenesis was evaluated, except for III molars, at a minimum age of 7 years whereas agenesis of III molars was not assessed prior to 8 years of age in cases where development of other III molar buds was already appreciable.

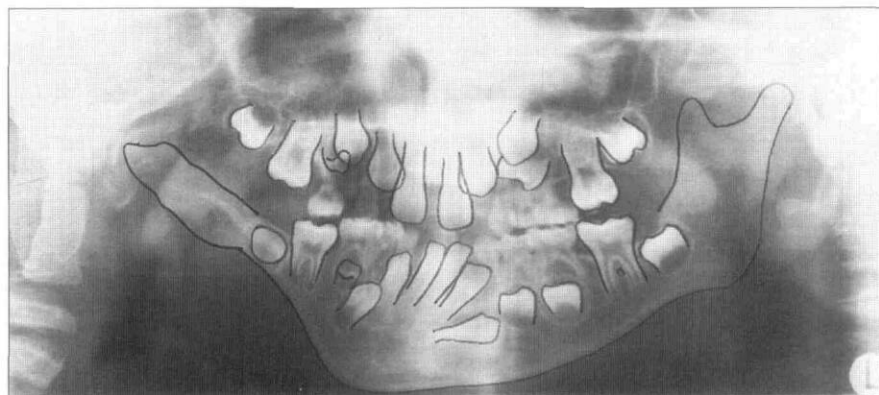


Figure. (case No. 11) Panoramic films showing agenesis of the I premolar on the affected side and of the II premolars of the maxillary arch associated with potential inclusion of 22.

Patients aged 8 years or younger with no sign of III molar buds were not considered to have agenesis of these teeth. Teeth that had reached the stage of physiological eruption but had still not erupted were classified as inclusions, whereas those that had not reached the stage of physiological eruption but whose conditions excluded the possibility of future physiological eruption were classified as potential inclusions.

## Results

The results of this study are presented in Tables 2 and 3.

### Agenesis (Tables 2–3; Figure)

In 11 cases (six female, five male; average age 12.2 years; range = 8–24 years) of 63 (17.4%) there was agenesis for a total of 29 missing teeth. Excluding III molars the number of missing teeth was 13 (44.8%, 13/29) in five cases (7.9%, 5/63). Taking into consideration only the mandible on the affected side, there were 12 missing teeth (41.3%, 12/29) including III molars and six missing teeth (46.1%, 6/13) excluding III molars.

In all 11 cases there was at least one missing tooth on the affected arch, associated in eight cases with at least one missing tooth of another arch. In 10 cases only one

type of tooth was affected by agenesis: premolar, lateral incisor, I molar, or III molar, while one case presented mixed agenesis involving lateral incisors and III molars.

By dividing the 63 cases according to the grade of skeletal malformation, it is evident that the greater the structural deficit the higher the percentage of cases with agenesis; it is also clear that agenesis of III molars most frequently occurs in medium-grade cases (S2), agenesis of premolars only occurs in more severe cases (S3–S4) (Figure) and agenesis of incisors does not seem to be influenced by the grade of the malformation (Table 3).

The type of tooth most frequently affected by agenesis was the III molar (58.6%, 16/29) followed by I and II premolars (24.1%, 7/29) and (53.8%, 7/13), excluding III molars.

Again, agenesis of the inferior lateral incisors, which affects 3.9% of patients with malocclusion, was present in 10.3% (3/29) of patients and in 23% (3/13) (excluding III molars).

Agenesis of a I molar was observed in only one case.

TABLE 3. SUBDIVISION OF CASES ACCORDING TO SKELETAL CLASSIFICATION (S). NUMBER OF CASES WITH AGENESIS AND THEIR PERCENTAGE IN RELATION TO THE NUMBER OF CASES CLASSIFIED AS ABOVE.

Grade of Malformation	N cases	%	Cases Agenesis Total		Cases Agenesis III Molars	Cases Agenesis Premolars	Cases Agenesis Incisors
			Cases	%			
S <sub>1</sub>	21	33.3	2	9.5	1	0	1
S <sub>2</sub>	31	49.2	4	12.9	4	0	0
S <sub>3</sub>	10	15.9	4	40.0	1	2	1
S <sub>4</sub>	1	1.6	1	100.0	0	1	0
Total	63	100.0	11		6	3	2

Evaluation of the affected side alone showed the most frequently missing teeth to be III molars (50%; 6:12) followed by premolars (25%; 3:12), lateral incisors (16.7%; 2:12), and I molars (8.3%; 1:12).

Only case No. 11 (S4) (Figure) presented agenesis of the I premolar in the affected arch and of the II premolars of the superior arch (Table 2).

Our results (Table 3) show that the more severe the skeletal malformation the greater the probability of agenesis. Furthermore, agenesis of premolars was only observed in S3 and S4, while in other teeth it was also present in less severe malformations.

### Inclusions (Table 2; Figure)

In five cases (two female, three male; average age 15.8; range = 8–29) of 63 (7.9%) proper and/or potential inclusions were observed.

Three teeth were included (two molars and one premolar) and three potentially included (two molars and one canine); five of these were on the affected side and one (premolar) contralateral. In two cases (Nos. 4, 11) the inclusion (proper or potential) was associated with dental agenesis.

Dental inclusions differed from agenesis in that they were mainly observed in S2 with the exception of the case with S4 (No. 11) — the only case with agenesis of a I premolar (Fig 1).

### Discussion

The results of this study show a correlation between hemifacial microsomia and dental anomalies, agenesis and inclusions, as other authors have already reported.<sup>11–13</sup> A comparison of our results and those of sample studies of patients not affected by hemifacial microsomia showed significant differences in terms of dental agenesis. In fact, the percentage of patients with agenesis, excluding III molars, was higher in those with hemifacial microsomia than in those with simple malocclusion (Pachì, 7.8%; Lind, 7.4%; Pagnacco, 7.2%)<sup>14–16</sup> and was as much as two or three times that found in a random sample (Caprioglio, 4.6%; Dolder, 3.4%).<sup>17, 18</sup>

Of the missing teeth, 46.1% (excluding III molars) were on the side affected by microsomia; which is higher than the 35.7% reported by Pachì,<sup>15</sup> who took into consideration the entire inferior arch. This signifies that in cases of hemifacial microsomia with agenesis there is always at least one missing tooth on the affected side.

Our results also show that the more severe the skeletal malformation and mandibular underdevelopment, the greater the probability of dental agenesis, particularly of premolars.

The same method was used to assess dental inclusions. Of the 63 sample cases, 7.9% presented inclusions. In these cases too, the skeletal malformation ranged

from grade S2 to S4 and the mandibular anatomy was noticeably malformed, producing inclusions and potential inclusions of molars in particular.

Our results indicate that patients with hemifacial microsomia are more likely than unaffected patients to present agenesis or dental inclusions. For this reason, it seems safe to say that the vascular damage responsible for pathogenesis of the malformation also may affect the dentogingival lamina and consequently physiological dental development, too.

Dr. Silvestri is assistant chair, Maxillo-Facial Surgery, and head, Orthodontic Out-Patient Department, Rome University "La Sapienza"; Dr. Natali is a private practitioner in Rome; Dr. Fadda is a research fellow; Rome University "La Sapienza", Rome, Italy.

1. Converse JM, Cocco PJ, Becker M, Woodsmith D: On Hemifacial Microsomia—The first and second branchial arch syndrome. *Plast Reconstr Surg* 51(3):268–79, 1973.
2. Obwegeser HL, Lello GL, Sailer HS: Otomandibular dysostosis. In: *Surgical Correction of Dento-Facial Deformities*, Bell W, Ed. (III Vol.) Philadelphia: WB Saunders Co, 1985.
3. Stricker M, Raphael B, Van Der Menten J, Mazzola R, et al: *Craniofacial Malformations*. Edinburgh, London, Melbourne, and New York: Churchill Livingstone, 1990.
4. Poswillo D: The pathogenesis of the first and second branchial arch syndrome. *Oral Surg* 35(3):302–28; 1973.
5. Robinson LK, Hoyme HE, Edward DK, Jones KL: Vascular pathogenesis of unilateral craniofacial defects. *J Pediatr* 111(2):236–39, 1987.
6. Murray JE, Kaban LB, Mulliken JB: Analysis and treatment of hemifacial microsomia. *Plast Reconstr Surg* 74(2):186–99, 1984.
7. Figueroa AA, Pruzansky S: The external ear, mandible and other components of hemifacial microsomia. *J Maxillofacial Surg* 10:200–11, 1982.
8. Phelps PD, Lloyd GA, Poswillo DE: The ear deformities in craniofacial microsomia and oculo-auriculo-vertebral dysplasia. *J Laryngol Otol* 97:995–1005, 1983.
9. Tulasne JF, Manach Y, Hamann C: Anomalies maxillo-faciales des syndromes du 1er arc branchial. *Ann Otolaryngol Chir Cervicofac (Paris)* 104:614–18; 1987.
10. David JD, Mahatumarat C, Cooter RD: Hemifacial microsomia: a multysystem classification. *Plast Reconstr Surg* 80(4):525–35, 1987.
11. Cranin N, Gallo L: Hemifacial microsomia with an edentulous mandible: forme frustae or a new syndrome?. *Oral Surg Oral Med Oral Pathol* 70:29–33, 1990.
12. Farias M, Vargervik K: Dental development in hemifacial microsomia I. Eruption and agenesis. *Pediatr Dent* 10(2):140–43, 1988.
13. Loevy HT, Shore SW: Dental maturation in hemifacial microsomia. *J Craniofac Genet Dev Biol* 1:267–72, 1985. (Suppl)
14. Lind V: Medfödda antalsvarianter i permanenta dentitionen. *Odont Revy (Malmö)*, 10:176–89, 1959.
15. Pachì F, Di Girolamo R: Le agenesie dentarie. Prima parte: indagine epidemiologica su un campione di popolazione italiana. *Ortogonatodonzia Italiana* 1(6):767–74, 1992.
16. Pagnacco A, Vangelisti R, Randon C, Tessari S, et al: Anomalie della dentizione, le agenesie dentarie. *Dent Cadmos* 55(11):73–76, 1987.
17. Caprioglio D, Vernole B, et al: *Le Agenesie Dentali*. Milano Masson 1988.
18. Dolder E: Deficient dentition. *Dent Pract Dent Rec* 57:142–48, 1937.