



Evaluation of aggressive pulp therapy in a population of vitamin D-resistant rickets patients: a follow-up of 4 cases

Deven V. Shroff, DMD Alton G. McWhorter, DDS, MS N. Sue Seale, DDS, MSD

Dr. Shroff is a major in the Dental Corps, United States Army, Seoul, Korea; Dr. McWhorter is associate professor and Dr. Seale is regents professor and chairman, Department of Pediatric Dentistry, Baylor College of Dentistry, Texas A&M University System Health Science Center, Dallas, Tex.

Correspond with Dr. McWhorter at amcwhorter@tambcd.edu

Abstract

This investigation collected clinical and radiographic data from a retrospective chart review of 4 patients receiving prophylactic formocresol pulpotomies and stainless steel crowns following a dental abscess associated with a medical diagnosis of vitamin-D resistant rickets (VDRR) at Texas Scottish Rite Hospital for Children in Dallas, Tex. Clinical and radiographic data were available for 29 primary teeth in 4 children, with follow-up times ranging from 2 years, 1 month to 5 years, 6 months. Based on available recalls of 29 teeth treated following the prophylactic formocresol pulpotomy, 22 failed clinically. The earliest failure occurred at 3 months; the longest time to failure was 3 years, 9 months. No trends were discernable between tooth type and failure rate, although the shorter the time between eruption of the tooth and pulpotomy treatment, the greater the chance of success. Presently, there is not enough evidence to suggest that prophylactic pulpotomy therapy in VDRR patients is beneficial in preserving their primary dentition. (*Pediatr Dent.* 2002;24:347-349)

KEYWORDS: RICKETS, PULP THERAPY

Received June 3, 2001 Revision Accepted February 26, 2002

Vitamin-D resistant rickets (VDRR), also known as hereditary or familial hypophosphatemia, phosphate diabetes, and refractory rickets, is characterized by a metabolic disturbance which causes defective calcification of mineralized structures.¹ It is predominantly an X-linked dominant disease, affecting males more often than females.¹⁻³ Generally, affected males tend to show a greater penetrance of disease, resulting in a more severe form of VDRR than in females.

Harris and Sullivan⁴ (1960) first reported the dental findings that are often characteristic and may be the first clinically noticeable signs of the disease. Commonly reported dental abnormalities include normal but thin enamel, interglobular dentin, and enlarged pulp chambers with the pulp horns reaching to and beyond the dentinoenamel junction (DEJ).^{3,5,6} Any combination of these factors can lead to pulpal abscess if the integrity of the enamel is compromised. In many instances, minor caries or physiologic attrition can remove the thin enamel covering the pulp horn and allow microorganisms access to the pulp.^{5,6} The poorly formed dentin and close proximity of the pulp to the tooth surface are problematic and can potentiate the infective

process, allowing healthy appearing teeth to “spontaneously” abscess.⁵ Figure 1 demonstrates the enlarged chamber and the pulp horn’s proximity to the incisal edge in an extracted central incisor of a VDRR patient.

In 1991, McWhorter and Seale reported that 25% of patients diagnosed with VDRR in the dental clinic at Texas Scottish Rite Hospital, Dallas, Tex (TSRH), manifested abscesses in the primary dentition and that the abscess of one tooth indicated that at least one other tooth would be affected. Since a prediction of the occurrence of abscesses in the population could not be made either by analysis of radiographs or medication doses, they recommended that aggressive preventive dental treatment would be beneficial. Therefore, in a patient who is susceptible to abscesses, (ie, one who has had an abscess of one or more primary teeth uninvolved with caries or trauma) prophylactic treatment of all posterior primary teeth with pulpotomies and stainless steel crowns was recommended.⁵

Since this recommendation was made, there has been no systematic approach to reexamine the patient population being treated using it. Therefore, the purpose of this investigation was to examine the records of all patients at the

Texas Scottish Rite Hospital for Children in Dallas, Tex, who were diagnosed with VDRR and who have received the aggressive pulp treatment to determine its effectiveness in saving primary teeth from extraction.

Case reports

This investigation collected clinical and radiographic data from a retrospective chart review of patients diagnosed with VDRR and treated dentally since the pulp therapy recommendation was made in 1991.

All cases were patients with at least one posterior primary tooth treated with a standard 5-minute formocresol pulpotomy using a 1:5 dilution of formocresol. The patient record was screened to meet the following criteria for acceptance into the study: (1) a medical diagnosis of VDRR, with an abscess of one or more primary teeth uninvolved with caries or trauma, (2) posterior primary teeth with no carious exposures requiring and receiving prophylactic pulpotomies, (3) a posterior tooth restored with a pulpotomy and stainless steel crown that remained intact at future recalls until the tooth exfoliated or was extracted, and (4) at least one recall visit following the pulpotomy treatment.

Case 1

A 7-year, 10-month-old white male had a total of 12 teeth treated with prophylactic formocresol pulpotomy therapy under general anesthesia. He was followed for 2 years, 1 month until he was lost to follow-up. During that time, 8 teeth failed clinically. Five of the 8 teeth showed furcation involvement and the other 3 showed a periapical radiolucency on radiographs. The failure time ranged from 3 months to 1 year, 7 months post treatment. The overall success rate of the prophylactic pulpotomy and stainless steel crown therapy was 33% for the teeth followed until the patient was lost to follow-up. No discernable pattern of tooth failure was evident. The results are summarized in Table 1.

Case 2

A 3-year, 9-month-old Hispanic male received a total of 9 prophylactic formocresol pulpotomies under general anesthesia. He was followed for 4 years until he was lost to follow-up. During that time, 3 teeth failed clinically. Radiographically, all 3 teeth showed furcation involvement. The time between treatment and failure was 3 years, 9 months. The overall success rate of the prophylactic pulpotomy and stainless steel crown therapy was 66% for the teeth followed until the patient was lost to recall. A noticeable pattern emerged between the length of time the tooth was present in the oral cavity prior to treatment and the time between treatment and failure. The longer the tooth was present in the mouth prior to the prophylactic pulpotomy treatment, the more rapid the failure. The results are summarized in Table 1.

Case 3

A 3-year, 3-month-old white male represented the youngest of the 4 cases. Eight teeth were treated with prophylactic formocresol pulpotomy therapy under general anesthesia.

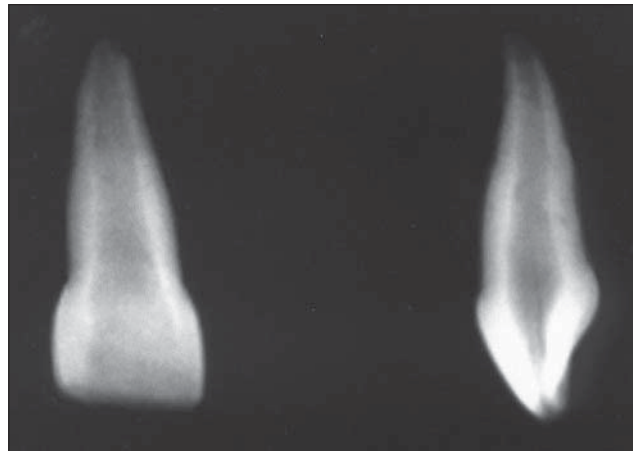


Fig 1. The extracted central incisor from a patient diagnosed with VDRR that demonstrates the enlarged pulp chamber. The extension to the incisal edge is shown in the lateral view of the tooth.

Table 1. VDRR Patient Composite

Case	1	2	3	4
Sex	Male	Male	Male	Female
Age at 1 st abscess	Unknown	3y3mo	3y3mo	2y3mo
Age at treatment	7y10mo	3y9mo	3y3mo	4y5mo
Time between treatment and abscess	3mo to 1y7mo	3y9mo	1y2mo	1y0mo to 2y2mo
Total teeth treated	12	9	8	10
Total number of failures	8	3	5	6
Available recall time	2y1mo	4y0mo	4y0mo	5y6mo
Pulpal success	33%	66%	38%	40%

The available recall time for all 8 treated teeth has been 4 years to date. The first recall was at 1 year, 2 months, at which time 5 teeth were observed to have failed clinically. Radiographs showed furcation involvement of 3 teeth but films were unavailable for the remaining 2 treated teeth. Of the 8 treated teeth, 3 are considered to be successful since their post-treatment course has been uneventful. The overall success rate of the prophylactic pulpotomy and stainless steel crown therapy was 38% for this patient. No discernable pattern of tooth failure was evident. The results are summarized in Table 1.

Case 4

A 4-year, 5-month-old white female received treatment in a similar manner. Ten teeth were treated with prophylactic formocresol pulpotomies under general anesthesia. The available recall time for all 10 treated teeth was 5 years, 6 months. Six teeth failed clinically. Of these 6 teeth, 5 showed internal resorption and 1 exhibited external resorption radiographically. The time between treatment and failure ranged from 1 year to 2 years, 2 months. Four of the 10 treated teeth were deemed to be successes as they exfoliated uneventfully. The overall success rate of the prophylactic pulpotomy and stainless steel crown therapy was 40% for this patient. No discernable pattern of tooth failure was evident. The results are summarized in Table 1.

Discussion

In an attempt to preserve the primary dentition, the recommendation was made that all patients diagnosed with VDRR and who demonstrated primary tooth abscesses be treated with prophylactic pulpotomies and stainless steel crowns.⁵ This paper reports the findings of 4 cases treated following this recommendation. Even with a small sample size, there is overwhelming evidence to discontinue prophylactic pulpotomy treatment in this patient population.

In 3 of the 4 cases presented, the first clinical abscess or “spontaneous” abscess occurred between 2 years, 3 months and 3 years, 3 months of age, which confirms previously reported findings that the first clinical abscess occurs prior to age 3 years, 9 months.⁵ In Case 1, however, the age of first clinical abscess was unknown; at a treatment age of 7 years, 10 months, he represents the oldest treated patient. The primary teeth in this patient had the longest time between eruption and treatment, thus allowing for increased attrition of the primary dentition and a greater likelihood of inflammation or bacterial infection. An increase in failures and clinical abscesses could have been anticipated in this patient due to the delayed treatment age. However, in the remaining 3 patients receiving early intervention, the resulting pulpotomy failures were not expected.

The average clinical success of a formocresol pulpotomy in a tooth with caries is 85%, with radiographic success averaging 90%.⁷⁻⁹ In this population, the formocresol pulpotomies were prophylactic and performed on teeth that were caries-free with healthy pulps, and the success rate was 44% for the 4 cases discussed.

While there have been documented studies in the literature describing the dentin formation and composition, there are no studies regarding the pulpal tissues in teeth in VDRR patients. However, there is no reason to believe that the pulpal tissue in these patients is genetically predisposed to abscess. It seems reasonable to assume that if the pulps were healthy, the teeth would react in a manner predictable for prophylactic formocresol pulpotomy therapy in caries-free teeth with a high rate of success.

The methodical failure of these treated teeth suggests nonhealthy pulps. The general assumption in VDRR patients that microorganisms gain access to the pulp following physiologic attrition may not be entirely accurate. These teeth may erupt with pulpal extensions that communicate with the oral cavity, resulting in microscopic exposures from the time of eruption. Perhaps the prophylactic pulpotomies are being performed on pulp tissue that is not as healthy as previously believed. Perhaps the pulps were already infected and the existing condition continued to progress undetected. Since the pulpal health of teeth in these patients may be suspect, a more radical treatment approach of prophylactic pulpectomy may be more beneficial.^{10,11}

The question of when the pulp in these patients becomes infected—whether it is following physiologic attrition or immediately following eruption—needs to be answered. Additionally follow-up studies of prophylactic pulpectomy

therapy in VDRR patients would be beneficial in determining the best course of treatment for these patients in an effort to preserve their primary dentition.

Since only 25% of all patients diagnosed with VDRR are prone to exhibit “spontaneous” abscesses,⁵ it would seem prudent to wait until the first clinical abscess prior to aggressive prophylactic treatment. However, waiting for the first clinical abscess in these patients may be too late for a successful outcome. Other confounding variables—such as pulpal vitality, pulpal extensions, dentinal morphology, the likelihood of a “spontaneous” abscess, and the time between eruption and treatment—are involved, making treatment outcomes difficult to predict.

Conclusions

The results reported from these 4 cases indicate that prophylactic pulpotomy therapy in patients with vitamin D-resistant rickets does not appear to be successful. At this time, there is insufficient evidence to suggest that the recommendation for prophylactic pulpotomy therapy⁵ is beneficial in preserving primary dentition in this patient population. Therefore, prophylactic pulpotomy therapy cannot be recommended.

References

1. Albright F, Butler AM, Bloomberg E. Rickets resistant to vitamin D therapy. *Am J Dis Child.* 1937;54:529-547.
2. Hillman G, Geurtsen W. Pathohistology of undecalcified primary teeth in vitamin D-resistant rickets: review and report of two cases. *Oral Surg.* 1996;82(2):218-224.
3. Christensen JF. Three familial cases of atypical late rickets. *Acta Paediatr.* 1941;28:247-270.
4. Harris R, Sullivan HR. Dental sequelae in deciduous dentition in vitamin D-resistant rickets. *Aus Dent J.* 1960;5:200-203.
5. McWhorter AG, Seale NS. Prevalence of dental abscess in a population with vitamin D-resistant rickets. *Pediatr Dent.* 1991;13(2):91-96.
6. Goodman JR, Gelbier MJ. Dental problems associated with hypophosphataemic vitamin D-resistant rickets. *Int J Ped Dent.* 1998;8(1):19-28.
7. Camp JH. Pulp therapy for primary and young permanent teeth. *Dent Clin North Am.* 1984;28:651-668.
8. Fuks AB, Bimstein E. Clinical evaluation of diluted formocresol pulpotomies in primary teeth of school children. *Pediatr Dent.* 1981;3:321-324.
9. Goering AC, Camp JH. Root canal treatment in primary teeth: a review. *Pediatr Dent.* 1983;5:33-37.
10. Seale NS, McWhorter AG. Verbal communication. Baylor College of Dentistry, a member of Texas A & M University System, Dallas, Tex.
11. Rakocz M, Keating J, Johnson R. Management of the primary dentition in vitamin D-resistant rickets. *Oral Surg.* 1982;54(2):166-171.