



## Dentin malformation with alveolar bone loss and periapical abscess formation

Seiko Shintani, DDS, PhD Akiko Okamoto, DDS Ichie Yoshida-Minami, DDS Shizuo Sobue, DDS, PhD Takashi Ooshima, DDS, PhD

*Dr. Seiko Shintani is Senior Instructor, Dr. Akiko Okamoto is Instructor, Dr. Ichie Yoshida-Minami is Senior Instructor, Dr. Shizuo Sobue is Professor, and Dr. Takashi Ooshima is Associate Professor at the Osaka University Faculty of Dentistry in Osaka, Japan.*

Abnormalities of dentin formation have been classified into two large categories: those that are primarily diseases of the dentin itself and those in which the dentin defect accompanies defects in other tissue systems.<sup>1</sup> For example, the former category contains dentin dysplasia types I and II, dentinogenesis imperfecta types II and III and regional odontodysplasia, while the latter contains osteogenesis imperfecta (dentinogenesis imperfecta type I) and X-linked hypophosphatemic vitamin D-resistant rickets (XLH).<sup>2</sup> Characteristic defects of the dentin are found in each disease. However, there are some cases difficult to diagnose because of a dearth of documented case reports for comparison, some confusion in the published literature or an in-definite manifestation of symptoms. This report presents a rare case of dentin malformation with periapical abscess formation and alveolar bone loss.

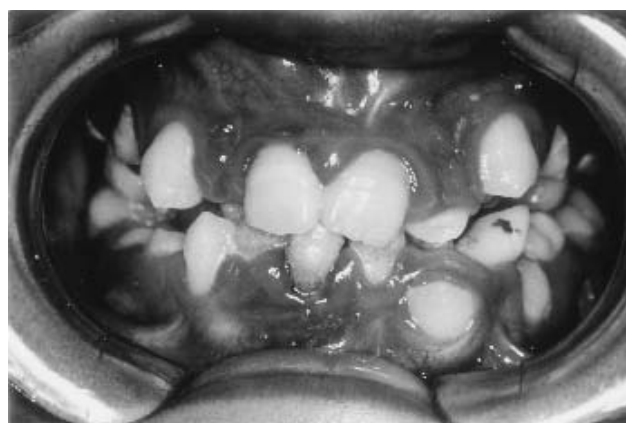

Fig 1. The clinical appearance at first examination.

### Case report

An 11-year-old Japanese boy was referred to the Pedodontic Clinic of Osaka University Dental Hospital with gingival swelling and bleeding around the regions of the upper posterior molars. He had suffered from gingival bleeding on brushing since about 6 years old. The patient appeared to be well-developed and well-nourished, and had no history of serious illness or injury. His mother stated that her pregnancy with him and birth were normal and that she had not taken any special medications. His parents are not consanguineous. Medical examination at the Osaka University Medical Hospital revealed no outstanding findings, and laboratory tests, including for concentrations of calcium and inorganic phosphate and the activity of alkaline phosphatase, performed several times on peripheral blood samples showed normal values. Both parents and an older brother had normal dentition, and there was no family history of dental anomalies.

Clinical examination revealed poor oral hygiene (Fig. 1). Severe gingival inflammation and depositions of plaque and calculus were found around all of the erupted permanent

teeth. Mobility was found at all the permanent teeth erupted into the oral cavity, and the probing depths of the molar teeth were more than 3 mm (Table 1). He had neither dental caries nor restorations, but a primary canine and primary molars were left without extraction even though their successive permanent teeth had already erupted. Until that time, he had

Table 1. The Composition of Subgingival Anaerobic Microflora and the Periodontal Conditions at the First Examination

	Tooth Number			
	11	26	36	46
Gram (-) rod	%	%	%	%
<i>Capnocytophaga sp.</i>	1.9	15.3	0.0	0.0
<i>Fusobacterium sp.</i>	25.9	22.0	2.9	2.3
<i>P. intermedia</i>	0.0	0.0	8.6	8.3
other gram (-) rod	37.0	2.5	22.9	56.3
Gram(-) cocci	1.9	6.8	0.0	4.5
Gram (+) rod				
<i>Actinomyces sp.</i>	0.0	0.0	0.0	0.0
other gram (+) rod	12.9	13.6	48.5	0.8
Gram (+) cocci	5.6	0.0	0.0	27.0
undetectable	14.8	16.9	17.1	0.8
<i>A. actinomycetemcomitans</i> (CFU/total CFU)	0.03%	2.37%	0.85%	0.05%
Pocket depth (mm)	4.0	3.0	3.0	5.0
Alveolar bone loss	moderate	moderate	moderate	severe
Mobility	M1	M2	M1	M2

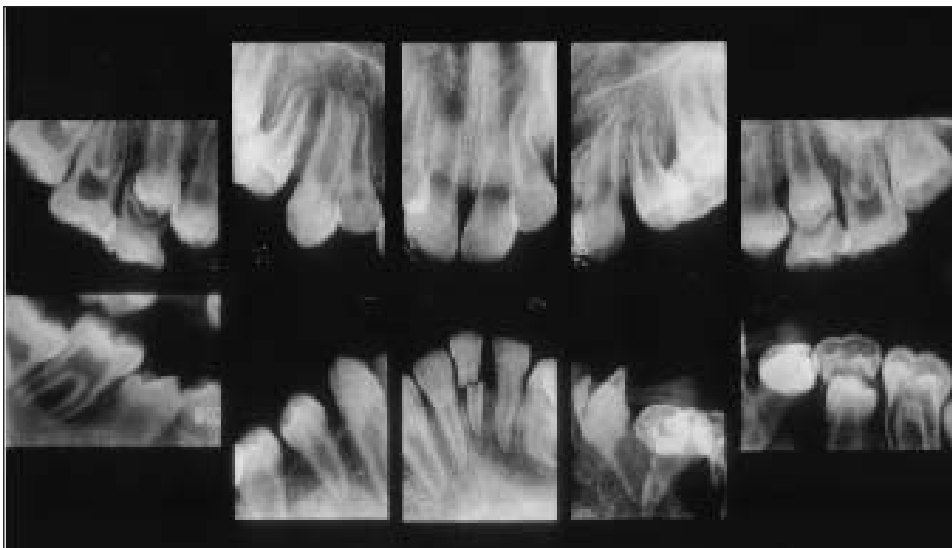


Fig 2. Dental radiographs at first examination.

never received any dental treatments because of religious reasons of his mother. The permanent teeth appeared to be normal in color, size, and morphology, but fistulae were present at the regions of the upper left molar and right premolar.

Radiographic examination showed large pulp chambers in the permanent teeth and a significant loss of alveolar bone at the lower right first permanent molar and left second premolar (Fig. 2). The lower left central incisor had been left fractured. An orthopantomogram taken after the extraction of 5 primary teeth (lower left canine, first molar and second molar, and upper second molars) showed an irregular mineralization of the mandibular bone and the periapical radiolucent areas at almost all of the sites where the permanent teeth had erupted into the oral cavity (Fig. 3). Almost all of the root apices of the permanent teeth remained open.

After the extraction of the primary teeth, the patient received oral hygiene instruction and scaling. Concurrently, minocycline paste (Perioline®, Sunster Co., Osaka, Japan) was

applied locally once a week. After the oral hygiene instruction, the lower right permanent first molar and central incisor were extracted because of severe mobility and root fracture, respectively. Endodontic treatment was performed on almost all of the permanent teeth erupted into the oral cavity. After removal of the necrotic pulp tissues, the canals were irrigated with sterilized saline and filled with calcium hydroxide and iodoform paste (Vitapex®, Neo Dental Chemical Products Co., Tokyo, Japan). The access cavities were restored with resin fillings. Consequently, the periapical bone resorption gradually recovered and all of the teeth in the oral cavity became less mobile. Gingival inflammation and fistulae also disappeared (Fig. 4).

The first microbiological examination of subgingival plaque was done after the extraction of the primary teeth. Subgingival plaque samples from around the upper right central incisor (tooth number:11), upper left first molar (26) and lower first molars (36, 46) were obtained by inserting three paper points. The subgingival microflora at the active sites was mainly composed of gram-negative rods or gram-

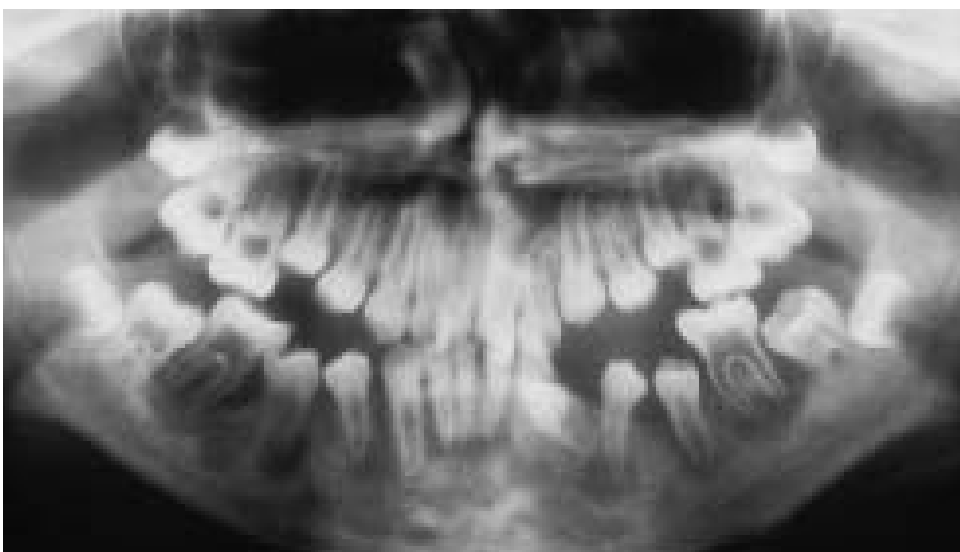

Fig 3. Orthopantomogram after extraction of primary teeth.

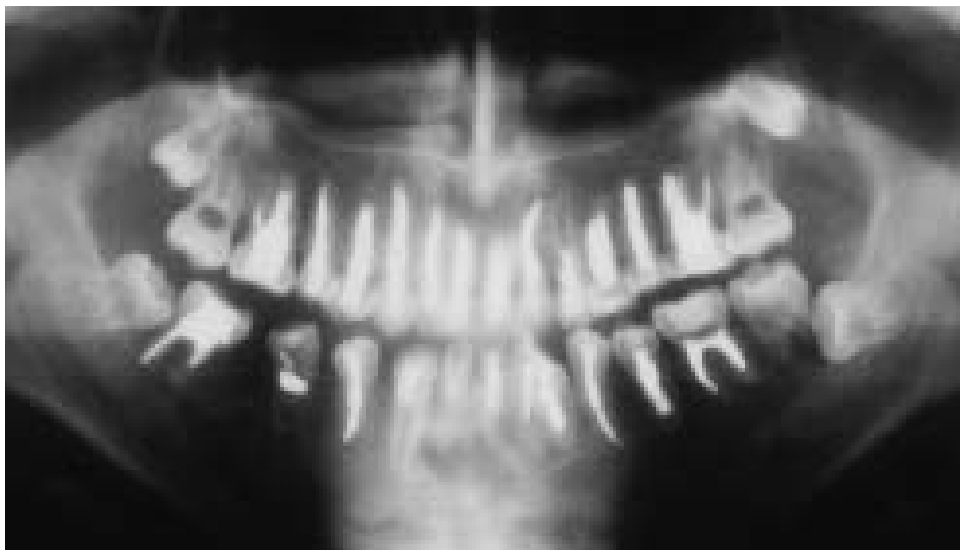

Fig 4. Orthopantomogram 2 years after canal treatments.

positive rods (Table 1). *Fusobacterium* and *Actinobacillus actinomycetemcomitans* (*A. actinomycetemcomitans*) were isolated from all of the examined teeth, while *Porphyromonas gingivalis* was not detectable anywhere. *Prevotella intermedia* (*P. intermedia*) was isolated in moderate percentages from the lower first molars, and *Capnocytophaga* from the upper first molar in a high percentage. The second microbiological examination was done after the extraction of the permanent incisor and first molar. The percentages of *A. actinomycetemcomitans* and *P. intermedia* had increased in the subgingival microflora of the upper incisor, the mobility of which was recognized at the second examination (data not shown).

The extracted teeth (lower right first molar and lower left primary canine: M1 and c samples, respectively) and an enamel-dentin block (ED sample) cut off from the upper right first molar at the opening of the pulp chamber were prepared for histopathological examination. A dissecting microscopic examination of the M1 polyester resin block sample showed the extremely large space of the pulpal chamber and its pulp horns extending to the cuspal enamel (photographs not shown). Some hard tissue structures resembling pulp stones were found in the canal regions of the pulpal chamber.

The contact microradiograph of sample M1 showed a deep fissure at the enamel, long pulp horns, many holes and clefts in the dentin and irregular calcification of the dentin (Fig. 5a).

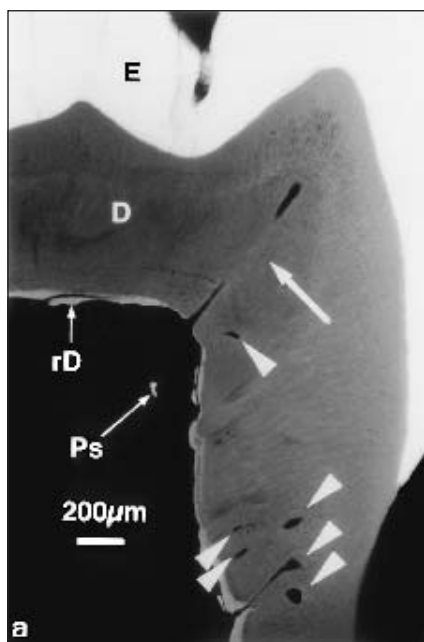


Fig 5a. Contact microradiographs of ground sections of the lower right first molar, crown region. Arrow heads indicate clefts and holes in dentin and the arrow indicates a long pulp horn. E= enamel, D=dentin, rD=reparative dentin, Ps=pulp stone

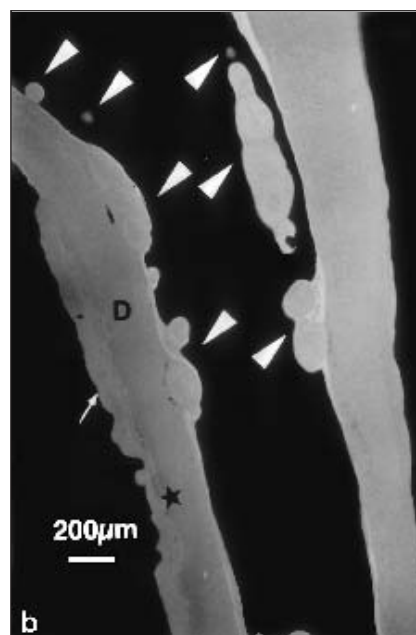


Fig 5b. Contact microradiographs of ground sections of the lower right first molar, root region. Arrow heads indicate pulp stone and the arrow indicates hyperplastic cementum.

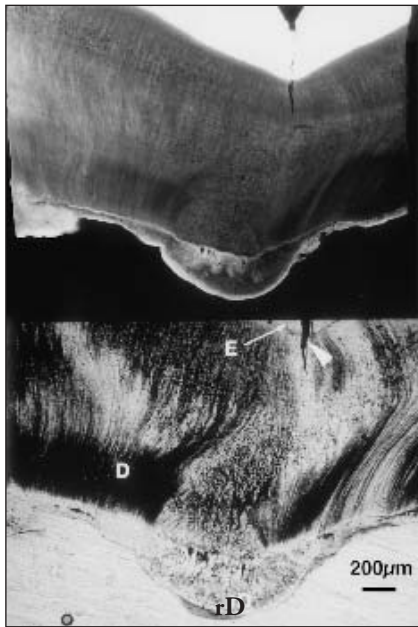


Fig 6. Ground section of the enamel-dentin complex from the upper right first molar. The upper photo is a contact microradiograph, and the lower is transmitted light micrograph. The arrow head indicates a crack in the enamel. E=enamel, D=dentin, rD=reparative dentin.

Furthermore, the radio-opacity of the enamel appeared to be somewhat low. In addition, many pulp stones of various sizes and shapes were found especially in the canal regions (Fig. 5b). The cementum was hyperplastic in places, and varied in thickness. The microradiograph of the ED sample also demonstrated invaginated fissures extending from the enamel surface into the dentin, and reparative dentin formations were found at the underlying areas of invagination (Fig. 6). The dentinal tubules were wide, reduced in number, irregularly distributed and abnormally oriented.

The demineralized sections of sample M1 showed residual enamel matrixes and a porous structure of dentin with many clefts and holes which appeared to be empty or contain acellular materials. The dentinal tubes were wide, reduced in number and irregularly oriented. In some of the dentin clefts, right under the fissure of the enamel, bacteria stained with Brown-Brenn were observed. In addition, porous dentin, together with hypocalcified amorphous areas, was found in every area of the dentin, where the deposition of collagen was disturbed. However, the mantle dentin appeared to be normal. Laminated pulp stones or denticles without dentinal tubules were found in the pulp space or fused with the root dentin, and occasionally coalesced to each other. The pulp remaining in the mesial root canal was infiltrated by a number of inflammatory cells and covered with stratified epithelium.

The histopathological examination of the lower left primary canine revealed similar findings to those of the permanent teeth (Fig. 7). The dentin calcification was irregular and the dentinal tubules were wide, reduced in number and irregularly oriented. A number of clefts and holes were observed in the dentin, and reparative dentin had formed in the wide region of the cuspal pulp.

## Discussion

The clinical features in the present case were the occurrence of periapical abscess and alveolar bone loss. The former is a typical finding of X-linked hypophosphatemic vitamin D-resistant rickets (XLH), which is induced when the enamel is worn away by attrition and the pulp horns are exposed to the oral environment, although an obvious cause such as tooth fracture or dental caries was not found.<sup>3</sup> Furthermore, histopathological examinations showed some findings similar to XLH, such as elongated pulp horns, an enlarged pulpal space and the presence of hypocalcified dentin. However, the periapical findings in the present case were recognized in the premolar teeth before the establishment of their occlusal function, suggesting that the structure and/or calcification of the enamel may be more of a hazard than that of XLH teeth. In addition, laboratory examinations showed normal levels of serum calcium and phosphorus, and the present case was not associated with XLH. The latter finding is one of the typical findings of hypophosphatasia, which is associated with a lack or abnormal formation of cementum.<sup>4</sup> However, the histopathological examinations showed hyperplastic cementum. In addition, the laboratory examinations showed normal levels of alkaline phosphatase activity, and the present case was not associated with hypophosphatasia.

On the other hand, alveolar bone resorption demonstrated in the present case did not seem to be caused by only the inadequacy of oral hygiene, since *A. actinomycetemcomitans* was isolated from all of the teeth examined at the first examination. *A. actinomycetemcomitans* is considered to be a main pathogenic microorganism in juvenile periodontitis, in which some defects are found in host defense mechanisms.<sup>5</sup> Furthermore, the possibility that the significant loss of alveolar bone at the lower right first molar caused by the intercourse between the periodontal pocket and periapical abscess should not be discounted. The irregular mineralization of the mandibular bone shown in the orthopantomogram suggested some trouble in osteogenesis, and some defects in the host defense mechanisms at undetectable levels may have enhanced bone resorption from both the periapical site and gingival sulcus.

Conditions which show similar dentin defects to the present case are recognized in dentinogenesis imperfecta, dentin dysplasia, regional odontodysplasia, and XLH.<sup>1,2,6</sup> However, most of the teeth associated with dentinogenesis imperfecta or dentin dysplasia show an early obliteration of the pulp chamber and/or root canals, which were not found in the present case.

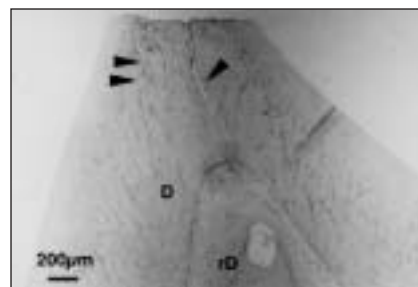


Fig 7. Demineralized section of lower left primary canine stained with hematoxylin-eosin. The arrow head indicates clefts and holes in dentin. D=dentin, rD=reparative dentin

In a few cases of dentinogenesis imperfecta Shields type III (Brandywine type), enlarged pulp chambers and periapical radiolucencies were observed as those in the present case.<sup>7</sup> In addition, Boughman *et al.*<sup>8</sup> described a long, five generation kindred that revealed both dentinogenesis imperfecta type III and a localized type of juvenile periodontitis, suggesting that the present case may be a variant of dentinogenesis imperfecta type III. However, the present case revealed neither a family history of dental defects nor the characteristic tooth color of opalescent brown, so we did not associate this case with a variant of dentinogenesis imperfecta.

The present case may have similar conditions as a generalized type of regional odontodysplasia, such as the thinness of both enamel and dentin, open apical foramina, enlarged pulp chambers, and pulp stones.<sup>9</sup> In addition, histopathological examinations demonstrated deep fissures in the enamel, hypocalcified enamel (as shown from residual enamel matrixes in the demineralized sections), irregularly calcified and porous dentin structures, irregular patterns of dentinal tubules, and a disturbance of the collagen deposition in the dentin. In a typical case of regional odontodysplasia, the teeth are discolored (yellow-brown or brown), have a very irregular shape with hypoplastic and irregularly mineralized enamel, and a reduced radiopacity with a loss of distinction between the enamel and dentine, which has given rise to the term "ghost teeth".<sup>10</sup> In the present case, however, the shape and color of the teeth appeared to be normal and the radiographic examination showed a distinction between the enamel and dentine.

As described above, we could not arrive at a diagnosis for the present case. Considering the severe dentin malformation, mild enamel defects, and no family history of dental defects, it may be reasonable to diagnose the present case as either a sporadic variant of dentinogenesis imperfecta type III or a generalized type of regional odontodysplasia with mild defects of the epithelial components.

## Reference

1. Bixler D: Developmental abnormalities of dentin. In Pediatric Dentistry. Scientific Foundation and Clinical Practice, RE Stewart, TK Barber, KC Troutman, SHY Wei, EDS, St. Louis, CV Mosby Co, 1982: pp. 117 - 134.
2. Witkop CJ: Hereditary defects of dentin. Dent Clin North Amer 19: 25-45, 1975.
3. Abe K, Ooshima T, Tong S M L, Yasufuku Y, Sobue S: Structural deformities of deciduous teeth in patients with hypophosphatemic vitamin D-resistant rickets. Oral Surg Oral Med Oral Pathol 65 : 191-198, 1988.
4. Bruckner RJ, Rickles NH, Porter DR: Hypophosphatasia with premature shedding of teeth and aplasia of cementum. Oral Surg Oral Med Oral Pathol 15: 1351- 1369, 1962.
5. Slots J, Schonfeld SE: *Actinobacillus actinomycetemcomitans* in localized juvenile periodontitis. In Periodontal disease: Pathogen and Host Immune responses. S Hamada, SC Holts, JR McGhee EDS, Tokyo, Quintessence Publishing Co, 1991: pp. 53 - 64.
6. Shield ED, Bixler D, El-Kafrawy AM: A proposed classification of heritable human dentine defects with a description of a new entity. Arch Oral Biol 18: 543-553, 1973.
7. Levin LS, Leaf SH, Jelmini RJ, Rose JJ, Rosenbaum KN: Dentinogenesis imperfecta in the Brandywine isolate (DI type III): Clinical, radiologic, and scanning electron microscopic studies of the dentition. Oral Surg Oral Med Oral Path 56: 267- 274, 1983.
8. Boughman JA, Halloran SL, Roulston D, Schwartz S, Suzuki JB, Weitkamp LR, Wenk RE, Wooten R, Cohen MM: An autosomal-dominant form of juvenile periodontitis: Its localization to chromosome 4 and linkage to dentinogenesis imperfecta and Gc. J Craniofac Gen Develop Biol 6: 341-350, 1986.
9. Crawford PJM, Aldred MJ. Regional odontodysplasia: a bibliography. J Oral Pathol Med 18: 251-263, 1989.
10. Rushton MA: Odontodysplasia: ghost teeth. Br Dent J 119: 109-113, 1965.

## ABSTRACT OF THE SCIENTIFIC LITERATURE



### LEARNING DISABILITIES, DYSLEXIA, AND VISION

The etiology of learning disabilities are multifactorial, reflecting genetic influences and abnormalities of brain structure and function. Early recognition and referral to qualified educational professionals is critical for the best possible outcome. Visual problems are rarely responsible for learning difficulties. No scientific evidence exists for efficacy of eye exercises ("vision therapy") or the use of specail tinted lenses in the remediation of these complex pediatric developmental and neurologic conditions.

**Comments:** This is an excellent short report on learning disabilities, dyslexia, and vision from The Committee on Children with Disabilities, AAP, and the American Academy of Ophthalmology (AAO) and the American Association for Pediatric Ophthalmology and Strabismus (AAPOS). As learning disabilities are an increasing public concern, it behooves the pediatric dentist to be at the leading edge of knowledge in this area. LPN

AAP Committee Report: Learning disabilities, dyslexia, and vision : A subject review. Pediatrics 102:1217-1219, 1998.

*No reprint request contact person.*  
24 references.