



# Dental development in amelogenesis imperfecta: a controlled study

W. Kim Seow, BDS, MDS, DDS, PhD

## Abstract

*The present investigation studied dental development in 23 subjects with amelogenesis imperfecta (AI), aged 4.2 to 15.6 years, compared with 46 race-, age-, and sex-matched, healthy, normal controls. The dental ages of the children were assessed from panoramic radiographs using previously established methods. Their chronologic ages at the time of radiographic examination were compared with their dental ages. The results showed that all subjects with AI showed a significant acceleration of dental age of approximately  $1.13 \pm 0.78$  years compared with control children ( $P < 0.001$ ). All children were consistently affected regardless of the AI variant. Furthermore, the study found a six-fold increase (26.1 vs. 4.3%) in tendency of AI patients to show impaction of the permanent teeth and associated anomalies such as follicular cysts. These results may be important in planning orthodontic treatment in AI patients, and indicate that they should have early screening to detect these abnormalities. (Pediatr Dent 17:26-30, 1995)*

**A**melogenesis imperfecta (AI) is a group of inherited abnormalities of dental enamel<sup>1-3</sup> It may be differentiated into three main groups: hypoplastic, hypocalcified, and hypomature, depending on the clinical presentation of the defects and the likely stage of enamel formation that is primarily affected.<sup>1</sup> Each main clinical group of AI may be further divided into several subgroups depending on the mode of inheritance, as well as the clinical appearance of the defective enamel,<sup>1, 3</sup> although in some cases, overlapping clinical features may make distinction difficult.

The clinical appearances of the different variants of AI have been well described in many studies involving single cases, as well as large series of patients.<sup>3-5</sup> In addition, a recent investigation<sup>6</sup> studied the clinical complications associated with the enamel defects, and their management. However, little is known regarding whether dental development or the rate of formation of the dentition is altered in AI. While a few studies<sup>2, 3, 7, 8</sup> have mentioned in passing that some affected patients showed delayed eruption and impaction of teeth, no studies are available on the rate of permanent teeth development.

Although gingival emergence, or eruption, is sometimes used as a clinical criterion of dental age assessment, it may not accurately reflect dental development, as emergence may be influenced by local factors such as ankylosis, early or delayed extraction of primary teeth, and permanent teeth crowding.<sup>9-11</sup> In contrast, permanent teeth formation rate is not affected by premature loss of the primary teeth.<sup>9, 12</sup> In the case of AI, knowledge of dental development alterations may be significant in planning orthodontic and related treatment. The purposes of this controlled study are to determine the changes in dental development in AI and to survey the common eruptive pathosis associated with the condition.

## Subjects and methods

### AI subjects

The AI subjects were previously referred to the author from general practitioners for further dental management. Altogether, there were 23 subjects (10 males and 13 females) suitable for dental age assessment who had panoramic radiographs exposed at or below 16 years of age. They were all Caucasian, and did not suffer other significant medical conditions apart from AI. Their mean chronologic age at panoramic examination was  $10.40 \pm 3.31$  years (range 4.2-15.6 years).

### Control subjects

For every AI subject, two normal healthy subjects, matched for sex, and age at the time of panoramic radiographic examination, were selected at random from the dental school records. Altogether, a total of 46 (20 males and 26 females) normal, control subjects were obtained. The controls were also Caucasian and did not suffer from significant medical conditions. In addition, they did not show dental abnormalities known to be associated with abnormal dental development such as hypodontia.<sup>13</sup>

### Assessment of chronologic and dental ages

The chronologic ages of the children at time of radiographic exposure, were obtained by noting their respective dates of birth and the dates of panoramic examination.

Dental ages were evaluated from panoramic radiographs using the method of Demirjian et al.<sup>11</sup> In this

method, the radiological appearances of the seven teeth on the left side of the mandible were examined. Each tooth was rated into one of eight developmental stages according to developmental criteria. A score for each stage of development of each tooth was available from standard charts.<sup>11</sup> The total score for all seven teeth in each patient gave a dental maturity score, which was then directly converted into a dental age from standard conversion charts.

Intraexaminer variability in the scoring of dental ages was previously checked using panoramic radiographs of three subjects who were not part of the study. Each radiograph was scored three times, and analysis of variance (ANOVA) tests showed no significant variability among the results.

It was not possible to score the radiographs blind as AI patients were readily identified from their enamel defects.

### Assessment of pathology associated with dental eruption

The panoramic radiograph of each subject also was examined for pathology that may be associated with abnormal dental eruption. If abnormalities were observed, the final clinical diagnosis, including results of tissue pathology and/or surgical intervention were recorded. In particular, enlarged follicles, over-retained primary teeth and impacted permanent teeth, as well as ectopic eruption were noted. In all cases, the pathology had been confirmed by prior diagnosis/history of clinical intervention.

### Statistical analysis

Student's *t*-test, ANOVA and chi-square tests, where appropriate, were used for statistical analysis. Statistical significance was established at the 0.05 level.

## Results

### Comparison of chronologic and dental ages in AI and control subjects

The normal control children had a mean chronological age ( $10.46 \pm 3.19$  years, range 4.2–16.0 years) that was comparable to that of the AI subjects ( $10.40 \pm 3.3$  years, range 4.2–15.6 years). The mean dental age of the controls was  $10.49 \pm 3.09$  years (range 4.5–16 years) while that of the AI subjects was  $11.51 \pm 3.5$  years (range 5.0–16.0 years).

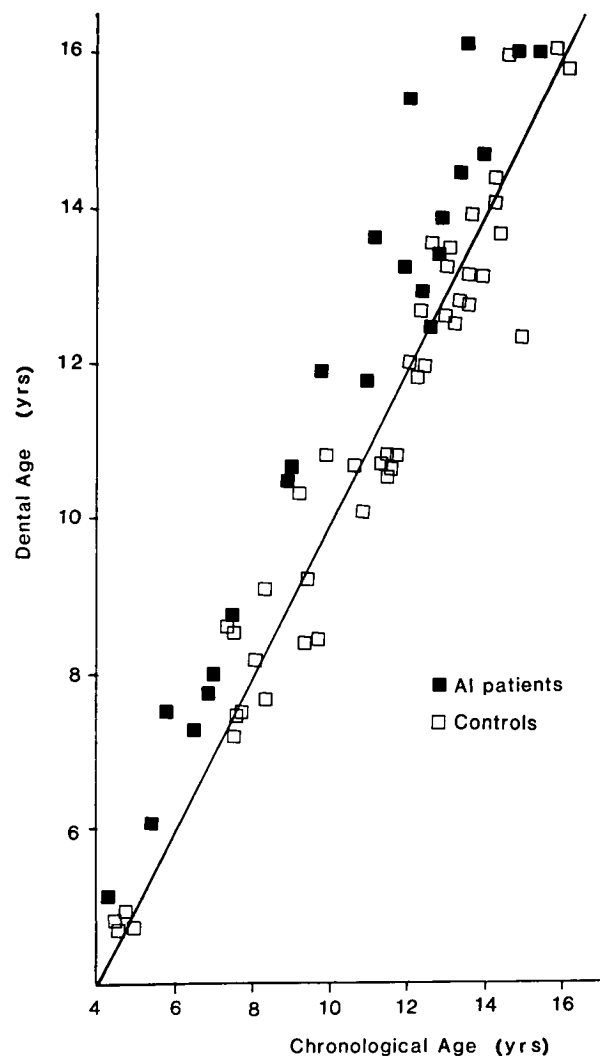
**TABLE 1. COMPARING CHRONOLOGICAL AND DENTAL AGES IN AI AND CONTROL PATIENTS**

Dental Age Minus Chronological Age	AI (N = 23)	Controls (N = 46)
Mean $\pm$ SD (yrs)	$1.1 \pm 0.78^*$	$0.03 \pm 0.77$
Range (yrs)	0.1 – 3.3	-2.5 – 1.9

\*  $P < 0.001$ ,  $t = 4.6$ ,  $df = 23$ .

Chronologic ages of the subjects were plotted against their dental ages (Fig 1). The results indicated that in the case of the normal control subjects, the dental ages were scattered evenly on both sides of the isochrone line, which is the line joining the points of identical chronological and dental ages. In contrast, in the case of the AI subjects, the dental ages were located to the left of the isochrone line, indicating that the dental ages were all greater than their respective chronological ages.

The mean difference between chronological and dental ages were compared in the two groups. As shown in Table 1, in the case of AI subjects, the mean difference was  $1.13 \pm 0.78$  years compared with  $0.03 \pm 0.77$



**Fig 1. Scattergraph of chronological ages plotted against dental ages. The results showed clearly that in the case of normal controls, the dental ages were evenly distributed on either side of the isochrone line (the line where the dental ages are identical to the chronological ages). By contrast, in the case of all the AI patients, the dental ages were located to the left side of the line, indicating that their dental ages were greater than their corresponding chronological ages.**

years in the controls. This increase in the AI subjects' mean dental age of 1.10 years was statistically significant ( $P < 0.001$ ) compared with the controls.

### Chronologic and dental ages in different AI variants

To determine if particular variants of AI were associated with increased dental ages, the mean chronologic and dental ages of subjects with different AI variants were compared, and analyzed by ANOVA tests. The results (Table 2) indicated that differences between the subgroups of AI subjects were not statistically significant ( $P > 0.1$ ).

### Pathology associated with abnormal eruption

Table 3 lists the pathology detected from examination of the panoramic radiographs of AI and control subjects. Six of 23 (26.1%) AI subjects showed evidence of pathology associated with abnormal dental eruption. These included follicular cysts (Fig 2), impacted teeth, and ectopic eruption (Fig 3). By contrast, only two of 46 (4.3%) healthy control children showed pathology on their panoramic radiographs. In both of these cases, the abnormalities were over-retained maxillary primary canines. The difference in prevalence of eruption abnormalities between the two groups is statistically significant ( $P < 0.001$ ).

In addition to the above eruption abnormalities, another pathologic entity noted was agenesis of two second permanent molars in a subject with the pitted hypoplastic variant of AI.

### Discussion

Amelogenesis imperfecta, a group of hereditary diseases of dental enamel is of interest to pediatric dentists because of its clinical and pathological implications.<sup>14</sup> Although the availability of molecular techniques has identified the likely genes involved in some X-linked types of AI,<sup>15-17</sup> and improved biochemical techniques have identified the protein abnormali-

ties in some types of AI,<sup>18</sup> the pathogenesis of the enamel lesions has not been well researched. Furthermore, while the direct clinical implications of the enamel defects have been reported,<sup>3-4</sup> other complications associated with the condition have not been investigated systematically.

This study showed that dental development was accelerated in all AI subjects compared with age- and sex-matched, healthy controls. The mean increase in dental developmental time was approximately a year, and the increase was consistent in all affected patients regardless of the AI variant. Thus, this study has provided insight into an important developmental aspect of the condition, although it is limited by the author's inability to perform the dental assessment blind due to easy radiographic identification of AI patients, and the relatively small numbers of each AI subtype.

The acceleration of dental development in AI may be due to several possibilities. Since development of both the crown and root are important in assessing dental development,<sup>11</sup> changes in the rate of development of either structure may affect the overall rate. First, dental crown development may be hastened because smaller quantities of enamel may take comparatively less time to form in the case of the hypoplastic

**TABLE 3. PATHOLOGICAL CONDITIONS THAT MAY BE ASSOCIATED WITH ABNORMAL ERUPTION IN PATIENTS WITH AMELOGENESIS IMPERFECTA**

<i>Amelogenesis Imperfecta Variant</i>	<i>Pathology</i>
Hypoplastic — pitted (N = 1)	Agenesis of $\frac{7}{17}$
Hypoplastic — rough (N = 1)	Follicular cyst $\frac{3}{1}$ Over-retained $\frac{1}{1}$
X-Linked — female (N = 1)	Follicular cyst $\frac{4}{5}$ Over-retained $\frac{1}{1}$
X-Linked — female (N = 1)	Ectopic (mesial) eruption $\frac{1}{17}$
Hypocalcified (N = 1)	Impacted $\frac{3}{5}$ $\frac{3}{7}$
Hypocalcified (N = 1)	Impacted $\frac{5}{5}$
Total AI with eruption pathology = 6 (26.1%)*	

\* In the case of control patients, there were only two patients (4.3%) with eruption pathology. Both of these were over-retained  $\frac{1}{1}$ . The number of AI patients with pathology associated with eruption is significantly different from that of normal controls ( $\chi^2 = 18.4$ ,  $df = 1$ ,  $P < 0.001$ ).

**TABLE 2. CHRONOLOGIC AND DENTAL AGES IN DIFFERENT VARIANTS OF AMELOGENESIS IMPERFECTA**

<i>Amelogenesis Imperfecta Variant</i>	<i>Chronologic Age (CA) Mean ± SD (Yrs)</i>	<i>Dental Age (DA) Mean ± SD (Yrs)</i>	<i>Mean Difference (DA - CA) ± SD (Yrs)</i>
Hypoplastic			
pitted (N = 3)	11.21 ± 3.40	11.90 ± 3.78	0.73 ± 0.33
rough (N = 5)	10.53 ± 2.70	11.91 ± 2.70	1.14 ± 0.50
local (N = 1)	13.21	14.42	1.11
X-Linked			
males (N = 2)	8.24 ± 0.71	9.50 ± 0.90	0.75 ± 0.35
females (N = 6)	10.41 ± 3.13	11.28 ± 3.30	0.88 ± 0.79
Hypocalcification (N = 6)	10.31 ± 4.06	11.81 ± 4.40	1.57 ± 1.03

ANOVA tests showed that the differences between the subgroups of AI were not statistically significant ( $P > 0.1$ ).

variants. Second, in the case of the hypocalcified types, the decreased length of time in crown development may be a reflection of the decreased time required for lesser amounts of enamel mineralization. Alternatively, it is possible that alterations in rate of root development may occur in association with the enamel defects.

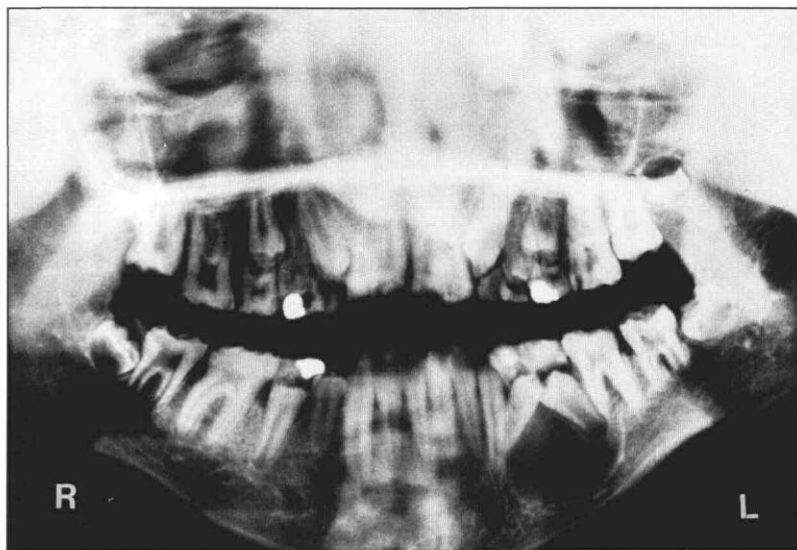
This study also found that AI subjects suffered a significantly higher prevalence of dental eruptive problems including dental impaction and follicular cysts. Previous authors<sup>2,3,7,8</sup> also have observed that dental impaction may lead to noneruption of some teeth in AI. In a few AI cases, failure of eruption was associated with resorption of the enamel and tooth ankylosis.<sup>19</sup> Although reasons for the eruptive pathosis are unclear, it is likely that the exposure of dentin caused by abnormal enamel leads to resorption of the tooth and resultant ankylosis.<sup>19</sup>

Previous studies have established that rate of dental development is independent of local factors such as early or delayed loss of primary teeth.<sup>9-11</sup> On the other hand, gingival emergence or eruption may be influenced by local conditions such as impaction.<sup>11</sup> Thus, although general accelerated dental development can lead to early eruption in patients with AI, this may be modified by the local factors such as impaction and early extraction of unrestorable and pulpally involved teeth, which are commonly encountered in AI. These effects have obvious implications in clinical management and suggest early screening for these abnormalities in AI so that interceptive and preventive procedures can be instituted early.

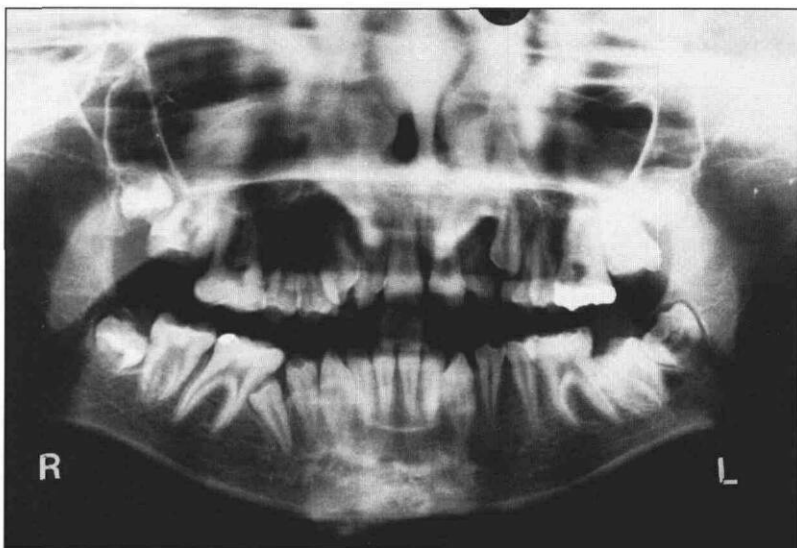
## Conclusions

Subjects with AI show accelerated dental development compared to sex- and age-matched control children. In addition, a relatively high prevalence of dental impaction and associated abnormalities such as follicular cysts are present. The presence of these abnormalities should be considered in the management of all patients with AI.

Dr. Seow is associate professor in pediatric dentistry, University of Queensland Dental School, and visiting professor, Harvard School of Dental Medicine and Children's Hospital, Boston, Massachusetts.



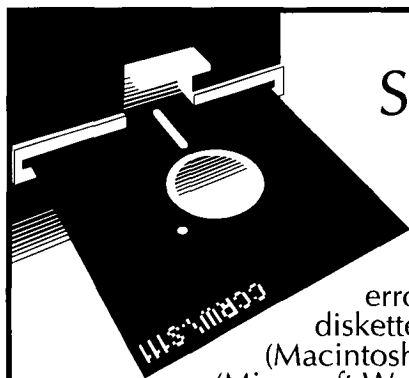
**Fig 2. Panoramic radiograph of a female patient with the X-linked variant of AI showing a large radiolucency around the developing mandibular left premolars. The lesion is asymptomatic, and discovered incidentally. The cyst was successfully enucleated, and the histopathological report indicated it to be benign and lined with squamous epithelium.**



**Fig 3. Panoramic radiograph of a male patient affected with the hypocalcified variant of AI. Note impaction of maxillary canines and mandibular right second premolar and left second permanent molar.**

- 1 Witkop CJ: Amelogenesis imperfecta, dentinogenesis imperfecta and dentin dysplasia revisited: problems in classification. *J Oral Pathol Med* 17:547-43, 1989.
- 2 Weinmann JP, Svoboda JF, Woods PW: Hereditary disturbances of enamel formation and calcification. *J Am Dent Assoc* 32:397-18, 1945.
- 3 Sundell S, Koch G: Hereditary amelogenesis imperfecta. I. Epidemiology and clinical classification in a Swedish child population. *Swed Dent J* 9:157-69, 1985.
- 4 Sundell S, Valentine J: Hereditary aspects and classification of hereditary amelogenesis imperfecta. *Comm Dent Oral Epidemiol* 14:211-16, 1986.

5. Backman B: Amelogenesis imperfecta — clinical manifestations in 51 families in a northern Swedish county. *Scand J Dent Res* 96:505–16, 1988.
6. Seow WK: Clinical diagnosis and management strategies for amelogenesis imperfecta variants. *Pediatr Dent* 15:384–93, 1993.
7. Winter GB, Brook AH: Enamel hypoplasia and anomalies of the enamel. *Dent Clin North Am* 19:3–24, 1975.
8. Fritz GW: Amelogenesis imperfecta and multiple impactions. *Oral Surg* 51:460–62, 1981.
9. Fanning EA: Effect of extraction of deciduous molars on the formation and eruption of their successors. *Angle Orthod* 32:44–53, 1962.
10. Posen AL: The effect of premature loss of deciduous molars on premolar eruption. *Angle Orthod* 35:249–52, 1965.
11. Demirjian A, Goldstein H, Tanner JM: A new system of dental age assessment. *Hum Biol* 45:211–27, 1973.
12. Sapoka AAM, Demirjian A: Dental development of the French Canadian child. *J Can Dent Assoc* 37:100–4, 1971.
13. Schalk-van der Weide Y, Prahl-Andersen B, Bosman F: Tooth formation in patients with oligodontia. *Angle Orthod* 63:31–37, 1993.
14. Seow WK: Enamel hypoplasia in the primary dentition: a review. *ASDC J Dent Child* 58:441–52, 1991.
15. Lagerstrom M, Dahl N, Nakahori Y, Nakagome Y, Bäckman B, Landegren U, Pettersson U: A deletion in the amelogenin gene (AMG) causes X-linked amelogenesis imperfecta (AIH1). *Genomics* 10:971–75, 1991.
16. Lau EC, Slavkin HC, Snead ML: Analysis of human enamel genes: insights into genetic disorders of enamel. *Cleft Palate J* 27:121–30, 1990.
17. Salido EC, Yen HP, Koprivnikar P, Yu LC, Shapiro JL: The human enamel protein gene amelogenin is expressed from both the X and Y chromosomes. *Am J Hum Genet* 50:303–16, 1992.
18. Wright JT, Robinson C, Kirkham J: Characterization of enamel proteins in hypoplastic amelogenesis imperfecta. *Pediatr Dent* 14:331–37, 1992.
19. Sauk JJ: Genetic disorders involving tooth eruption anomalies. In: *Biological Mechanisms of Tooth Eruption and Root Resorption*. Z Davidovitch, Ed. Birmingham, Alabama: EBSCO Media, 1988, pp 171–79.



## Send us your manuscript on disk...

To expedite publication of manuscripts in *Pediatric Dentistry* and to reduce the chance of introducing errors, we now require that all submissions include a diskette. Mark clearly on the disk the type of computer (Macintosh, IBM, etc.) and the word processing software (Microsoft Word, WordPerfect, etc.) you used. Please continue to send four copies of the text, and four originals of all photographs and figures.

Thanks for your cooperation.