

Spectrum of dentin dysplasia in a family: case report and literature review

W. Kim Seow, BDS, MDS, DDS, PhD Stephen Shusterman, DMD

Abstract

The dentin dysplasias (DD), which may be classified as type 1 (DD1) or type 2 (DD2), form a group of rare, inherited dentin abnormalities that are clinically distinct from dentinogenesis imperfecta. Studies of affected families may help to distinguish different types of DD and provide further insight into their etiology and clinical management. This report describes a family that showed characteristic dental features of DD1, including clinically normal crowns in both primary and permanent dentitions, and mobile teeth that may be associated with premature exfoliation. Radiographic features included calcification of the pulp with crescent-shaped, radiolucent pulp remnants, short, tapering, taurodontic roots, and many periapical pathoses that may be cysts or granulomas. A spectrum of dentin dysplasia was noted within the family. Strategies to prevent pulp and periapical infections and early exfoliation of the teeth include meticulous oral hygiene and effective caries-preventive measures. (Pediatr Dent 16:437-42, 1994)

Introduction and literature review

Dentin dysplasias (DD) form a group of rare dentin abnormalities that are clinically distinct from dentinogenesis imperfecta.¹⁻³ Since its recognition in 1920³ as "rootless teeth" and as "dentin dysplasia" by Rushton in 1933,⁴ the clinical features of DD have been well described. However, to date, relatively little is known about the pathogenesis of the dentin defects, or their pathological and clinical implications. As overlapping pathological features may be present in the various types of DD, studies of affected families may help to delineate different types and provide further insight into the etiology and clinical management of these conditions.

Classification of dentin dysplasias

Generally, two main classes of DD are recognized based on clinical and radiographic appearance. Shields et al.² proposed the classifications — type I, or "dentin dysplasia," and type II or "anomalous dysplasia of dentin." Witkop¹ later described type I as "radicular dentin dysplasia" and type II as "coronal dentin dysplasia" to indicate the parts of the teeth that are primarily involved. A third type of dentin dysplasia, DD3 or focal odontoblastic dysplasia, also has been proposed.⁵

Dentin dysplasia, type I (DD1)

The classical features in DD1, which have been well documented by several case reports,³⁻⁹ are: 1) normal-appearing clinical crowns in both dentitions; 2) short, conical, or absent roots that may lead to mobility and early exfoliation of the teeth; 3) total obliteration of the pulps except for thin, crescent-shaped pulpal remnants parallel to the cemento-enamel junctions; and 4) periapical radiolucent areas, which may be granulomas or cysts associated with noncarious teeth.

Histologically, in DD1, most of the coronal and mantle dentin of the root is usually reported to be normal, and the dentin defect is confined mainly to the root.^{1, 8, 10} The dysplastic dentin has been reported to consist of numerous denticles, containing whorls of osteodentin that block the normal course of the dentinal tubules.^{8, 10, 11}

A recent suggestion¹² to subclassify DD1 into four subdivisions based on the radiographic appearance of the pulp chambers is not likely to be clinically feasible due to the simultaneous presence of all varieties of the pulp chambers in any particular patient. Simpler subclassifications¹³ into either mild or severe may be more clinically relevant.

Dentin dysplasia, type II (DD2)

The clinical features of DD2 contrast sharply with those of DD1, and consist classically of: primary teeth that have a bluish or amber discoloration, and permanent teeth that appear normal;¹⁴⁻¹⁷ and primary teeth that show total pulp obliteration, and permanent teeth that show thistle-tube pulp configuration and pulp stones in pulp chambers.¹⁴⁻¹⁷

Histologically, the affected teeth in DD2 typically show a thin layer of normal coronal dentin and a sudden transition to dysplastic dentin, which is sclerotic and amorphous with few tubules.^{2, 3, 17}

Mode of inheritance

In both types of DD, the mode of inheritance is autosomal dominant.^{1, 2} However, there is no information regarding the gene defects in any type of DD.

Etiology

The etiology of DD1 remains speculative. Logan et al.¹⁸ suggested that abnormal calcification of the pulp is

related to degeneration of the dental papilla, whereas Sauk and coworkers¹⁰ postulated that premature invagination of the epithelial root sheath is associated with abnormal dentin deposition. An alternative hypothesis⁸ that has received greater attention is that the primary defect in DD1 resides in the ectomesenchymally derived odontoblasts, and that the abnormal root morphology is secondary to abnormal odontoblastic function or differentiation. Supporting this hypothesis is a further suggestion that as the early formed mantle dentin is normal, and the later-formed dentin is abnormal, the defect may be related to defective interaction of odontoblasts with the ameloblastic layer.¹⁹

As is the case with DD1, the etiology of the dentin defects in DD2 is enigmatic. As in DD1, the change to the formation of abnormal dentin after a period of normal dentin formation suggests a genetically based defect of an enzyme system involved in the normal induction of odontoblast function.

Differential diagnosis

Differential diagnosis of DD from dentinogenesis imperfecta (DI) is important, since there are several overlapping features in these conditions (Table 1). In DI, the mode of inheritance is also autosomal dominant.^{20, 21} However, in DI, there is amber-gray opalescence associated with marked attrition of both dentitions,²⁰⁻²¹ whereas in DD2, the discoloration and attrition are limited to only the primary dentition, and in DD1, the teeth are clinically normal. Radiographically, DI presents with bulbous crowns and short roots,²⁰⁻²¹ whereas DD1 shows taurodontism, and DD2 usually shows normal crown and root outlines. In addition, while all three entities show pulp obliteration, only DD2 shows typical thistle-shaped pulp chambers.

In addition to local primary defects of dentin, a few generalized, systemic conditions may show extensive obliteration of the pulp resembling the dental defects

of DD. These generalized conditions include tumoral calcinosis,²² which shows extensive calcification of joints and the pulps of the teeth, as well as the brachio-skeletogenital syndrome,²³ which shows mental retardation, abnormal ribs, bone sclerosis, and hypospadias. In addition, a possibly new syndrome of dentinal dysplasia occurring with general bone sclerosis also had been described.²⁴

Case report

Proband

Medical and dental histories

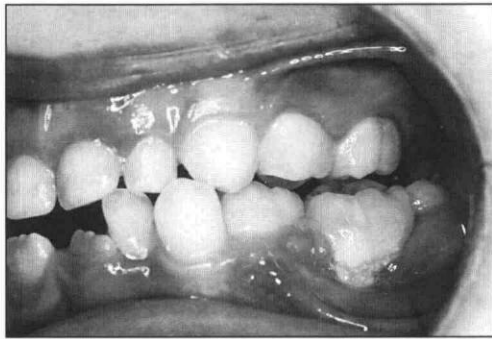
The proband was an 8-year-old male who was referred by his general dentist for further dental management, his father having been previously diagnosed with dentin dysplasia. The medical history was noncontributory. In particular, there was no history of bone disease or unusual bone fractures. He was the product of a full-term, uncomplicated pregnancy, birthweight 7 lbs.

His dental history revealed that eruption of the primary dentition was un-

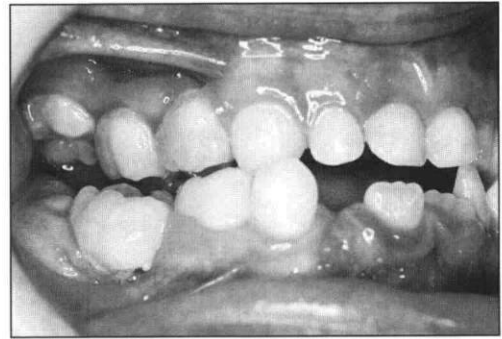
Table. Characteristic features of dentin dysplasia and dentinogenesis imperfecta

	<i>Dentin Dysplasia (DD)</i>		<i>Dentinogenesis Imperfecta (DI)</i>
	<i>Type 1 (DD1)</i>	<i>Type 2 (DD2)</i>	
Inheritance	AD	AD	AD
Clinical			
Appearance	Prim. & perm. teeth – normal	Prim. teeth – discolored* Perm. teeth – normal	Prim. & perm. teeth discolored*
Mobility	++	–	–
Attrition	–	+ (Prim. teeth)	++
Radiographic			
Bulbous crowns	–	–	++
Short roots	++	–	+
Taurodontism	++	–	–
Periapical radiolucencies	++	+	+
Pulp obliteration	++	++	++
Pulp remnants	Horizontal line at CEJ	Thistle-shaped pulp chambers	Minimal pulp remaining
Histologic			
Mantle dentin	Normal	Normal	Normal
Coronal dentin	Irregular tubules, whorls of osteodentin	Prim. teeth – irregular tubules Perm. teeth – normal	Mainly atubular dentin, laminations, some denticles.
Root dentin		True denticles, excessive dentin remodelling	

* The discolored teeth in both cases usually appear opalescent and amber or gray.
AD = autosomal dominant.



Figs 1, 2. Buccal views of the left (left) and right (right) posterior teeth showing the loss of periodontal attachment of the mandibular second molars, and the buccal crossbites of the maxillary primary canines.



remarkable in timing and sequence. Mobility of the teeth had been noticed by the parents. There was no history of dental infection, and no restorations had been placed.

General examination

General examination revealed a healthy, intelligent 8-year-old of normal height (48 in.), and weight (65 lbs). His face was normal, orthognathic, and symmetrical with Class 1 profile.

Dental examination

The patient had an early mixed dentition with all first permanent molars and mandibular central incisors partially erupted. The crowns of the primary teeth and erupting permanent teeth had normal shape and color, except that the cervical thirds appeared opaque. Mobility of the teeth was severe for all second primary molars and incisors, moderate in the first primary molars, and minimal in the primary canines.

The occlusion was Angle's Class I with minimal overjet and overbite. The maxillary primary canines were in buccal crossbite, resulting most likely from buccal migration of the mandibular primary canines. There was severe buccal displacement of the mandibular second primary molars with exposure of the resorbed radicular borders of these teeth (Figs 1 and 2). Around these mobile teeth were gross accumulations of plaque and severe periodontal inflammation. In other teeth, plaque and gingivitis was minimal. There was no periodontal pocketing greater than 2 mm.

Radiographic examination

A panoramic radiograph (Fig 3) showed the presence of all permanent teeth except the third molars. Positions of the developing permanent teeth were normal except for the maxillary right second premolar, which was rotated.

All teeth showed calcification and obliteration of the pulp including those of the developing permanent teeth. Horizontal radiolucent lines approximately parallel to

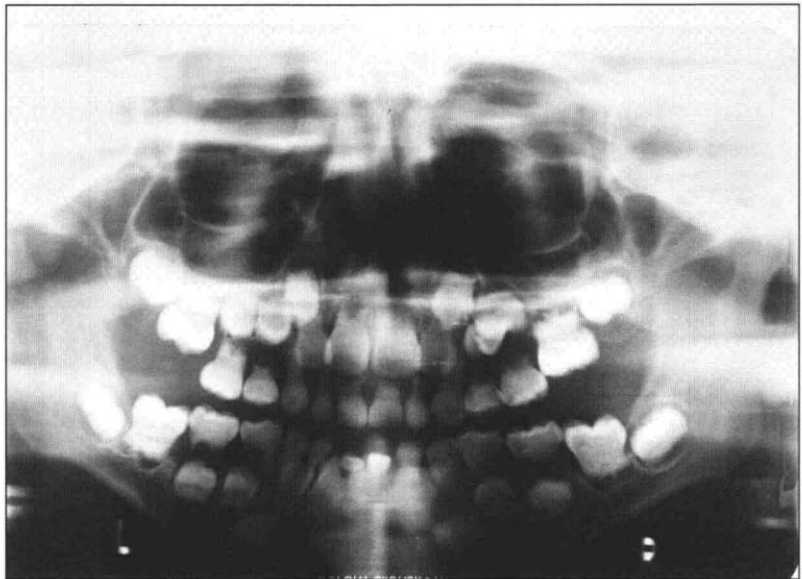


Fig 3. Panoramic radiograph of proband showing calcification and obliteration of all the dental pulps including those of the developing teeth. Note horizontal radiolucent lines approximately parallel to the cemento-enamel junctions and the large periapical radiolucencies around the resorbed roots of the primary molars.

the cemento-enamel junctions, probably representing remnants of the pulp, were noted. In addition, large radiolucencies were observed apical to the roots of the primary molars, which were severely resorbed. The left mandibular first permanent molar and the left maxillary second primary molar both appeared taurodontic. It was difficult to assess the remaining teeth because of the significant amount of root resorption.

Histopathological examination

A naturally exfoliated primary incisor tooth was available for histological examination. A ground section (Fig 4) showed a normal outline of the tooth and normal enamel formation. The coronal dentin, immediately subjacent to the enamel, appeared normal. There was an abrupt transition of the dentin to an abnormal pattern in the deeper layers. The abnormal dentin appeared to contain multiple foci of calcification surrounded by whorls of irregular tubular dentin. These calcified masses were separated by fine channels.

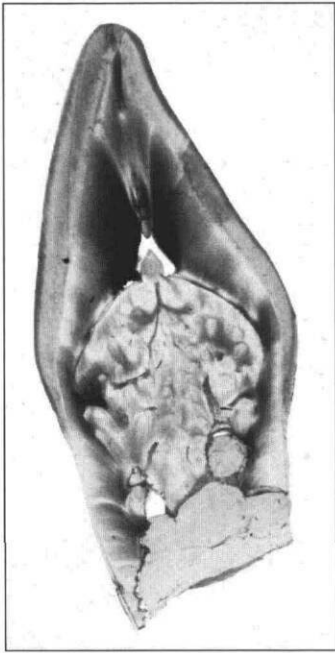


Fig 4. Ground section of a naturally exfoliated primary incisor from the proband. Note normal outline of the tooth and normal enamel. The coronal dentin appears normal from the incisal edge to a level approximately parallel to the cemento enamel junction, after which there is an abrupt change to dysmorphic dentin. The abnormal dentin consists of many foci of calcification containing whorls of irregular tubular dentin. Fine channels are present between the calcified masses.

Affected sibling

Medical and dental histories

An affected 10-year-old brother was available for dental examination. His medical history was noncontributory although he suffered from mild asthma for which he took prophylactic cromoglycate. At birth he was full-term following an uncomplicated pregnancy, and weighed 7 lb 12 oz. At 9 weeks, he was treated for pyloric stenosis, and at 12 weeks, he underwent surgical correction for an inguinal hernia.

General examination

At the initial dental visit, he was a healthy, intelligent boy of normal height (56 in.) and weight (65 lbs). His face was symmetrical, and his profile straight.

Dental examination

Dental examination revealed good oral hygiene and minimal plaque and gingivitis. There was no periodontal pocketing greater than 3 mm.

The patient was in the mixed dentition appropriate for his age. The first permanent molars, all incisors, and the maxillary right first premolar were fully erupted. A well-fitting band-loop space maintainer had been placed on the maxillary right second primary molar. The maxillary right first primary molar had been extracted approximately a year earlier due to an "abscess."

Like his brother, all the primary and

permanent teeth were normal shape and size. Mild, diffuse brown opacities were noted on the facial surfaces of all the incisors and first permanent molars. The occlusion was Class I, with normal overjet and overbite. Except for a moderately mobile mandibular left first primary molar, all the other teeth exhibited normal mobility.

Radiographic examination

A panoramic radiograph (Fig 5) revealed all permanent teeth to be present, including the crypts of the developing mandibular third molars. The radiographic appearance of the teeth was similar to those noted in the proband. Calcification of the pulp was noted in both erupted and developing permanent teeth as well as the remaining primary teeth. In both primary and permanent molars, horizontal radiolucent lines parallel to the cemento enamel junctions were noted, representing remnants of the pulp. In the developing premolars, these pulp chambers were larger and more triangular, with fine extensions communicating with the bone on the mesial and distal surfaces of the root. In addition, all the permanent and primary molars appeared taurodontic.

Affected father

General examination

The affected father also had an unremarkable medical history. He had no dysmorphic features and was normal height (6 ft) and weight (170 lbs).

Dental examination

Dental examination revealed very good oral hygiene with minimal gingivitis. The maxillary left first premolar and first molar, the mandibular left first molar, and the

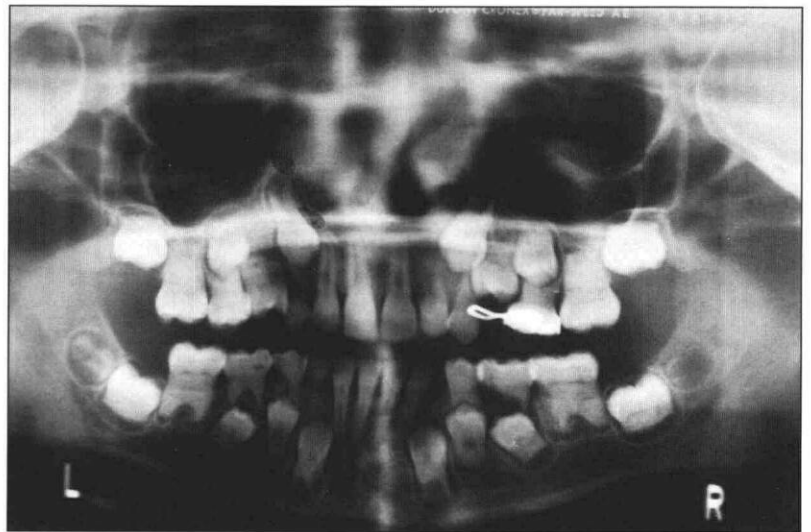


Fig 5. Panoramic radiograph of proband's brother. Note severe calcification and obliteration of the pulps of the posterior teeth, but relatively normal pulp chambers in the anterior teeth.

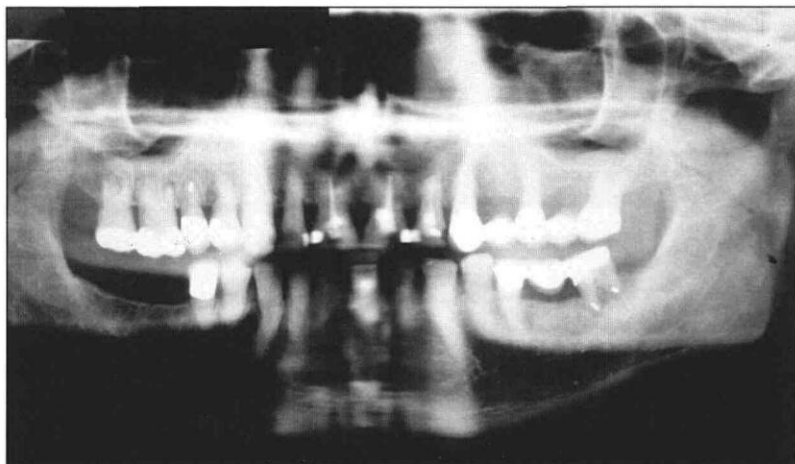


Fig 6. Panoramic radiograph of affected father of proband shows severe calcification of the pulps of the molars. Fine, thread-like remnants of the pulps are discernible on those anterior teeth that had not had endodontic treatment. Note successful retrograde endodontic fillings on the mandibular right second molar, and maxillary left second premolar. The roots of the mandibular canines and the maxillary left first premolar appear dilacerated.

mandibular right first and second molars had been previously extracted due to infection. A five-unit left maxillary and a three-unit left mandibular bridge replaced the missing teeth. The anterior teeth appeared discolored, most likely secondary to endodontic therapy. There was minimal tooth mobility.

Radiographic examination

A panoramic radiograph (Fig 6) revealed successful conventional root canal treatment in both maxillary central and left lateral incisors, and the mandibular left central incisor. In addition, successful retrograde metallic restorations were noted in the root apices of the maxillary right second premolar and the mandibular left second molar. Dilaceration of the root was noted in both mandibular canines and the maxillary right first premolar. In addition, the maxillary molars were taurodontic. Significant periodontal bone loss was noted around most teeth. A periapical full-mouth radiographic survey confirmed these findings. In addition, thread-like remnants of the pulp were noted on nonendodontically treated teeth.

Family pedigree

A family pedigree (Fig 7) showed that the most likely mode of inheritance is autosomal dominant with a high degree of penetrance.

Discussion

The family in this report has clear features of DD1 such as clinically normal crowns, mobility of the teeth, pulp obliteration with horizontal crescent-shaped pulp remnants at cemento-enamel junctions, multiple radiolucencies, taurodontism and short, tapering roots. The defect in this family may be considered relatively

mild as the root lengths were not excessively short, and the father had been able to retain his teeth well into middle age.

However, in addition to the typical features of DD1, the family also showed certain features found in DD2. Of note were the fully erupted maxillary and mandibular anterior teeth of the older child, which appeared to have radiographically patent radicular pulp chambers. This feature of uncalcified pulp chambers at the time of eruption is considered a characteristic feature of DD2.^{9, 15, 16} Furthermore, in the father, narrow but patent pulp chambers were still discernible in the anterior and premolar teeth.

This family thus shows a spectrum of DD with features of both types 1 and 2, and resembles a previously reported family⁹ that showed similar dental findings. In this regard, this report supports the theory that a range of severity occurs in this

condition, and that subclassifications of DD1 into further divisions is not warranted based on currently available information.

One of the main clinical problems encountered in DD1 are short, tapering roots associated with tooth mobility and premature exfoliation.¹⁻³ In this family, however, the root lengths were not excessively shortened, and mobility was observed in the primary dentition only. Furthermore, the excellent oral hygiene practiced by the patients has prevented further attachment loss from periodontal infections. In the father, the presence of a maxillary five-unit bridge that had lasted approximately 10 years further attests to the slow rate of periodontal bone loss in this patient. As intrinsic abnormalities of the cementum are not consistent fea-

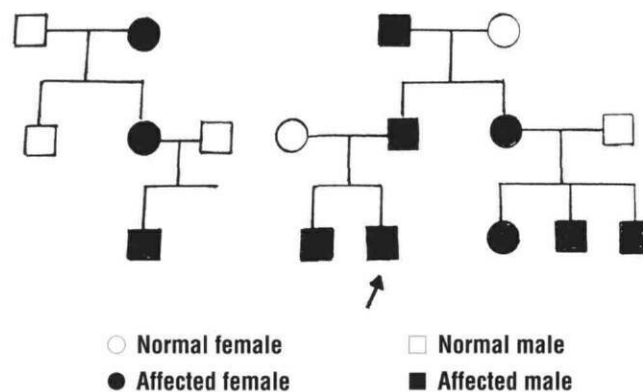


Fig 7. Pedigree of proband's family shows autosomal dominant mode of transmission of condition, and high degree of penetrance (arrow shows proband).

tures^{8,17} of DD, it is likely that loss of periodontal attachment may be adequately prevented through effective oral hygiene.

Although not histologically identified in the present family, periapical granulomas and apical cysts¹⁻⁴ present another important management problem. These are likely to have resulted from "spontaneous" pulp infections associated with severe pulp obliteration. In addition, abnormal extensions of the pulp occlusally may cause pulp exposures from minimal dental caries.³ Thus, effective preventive measures for dental caries such as fissure sealants and topical fluoride are important aspects of patient management. Prophylactic stainless steel crowns may be considered for patients with accompanying enamel hypoplasia, but care must be taken to prevent periodontal inflammation, which may exacerbate the likelihood of early exfoliation.

In the primary dentition, extraction of involved teeth and space maintenance are the obvious treatments for pulpal infections. However, in the permanent dentition, both conventional and retrograde root fillings have been successful, as demonstrated in the present and previous cases.^{11,25}

In conclusion, DD is a rare, inherited abnormality of dentin that may lead to early exfoliation of the teeth. Early diagnosis of the condition and application of effective preventive strategies may help prevent or delay loss of the dentition.

Dr. Seow is associate professor, pediatric dentistry, University of Queensland Dental School, Brisbane, Australia, and visiting professor, Harvard School of Dental Medicine and the Children's Hospital and Dr. Shusterman is chief of dentistry, Children's Hospital, Boston, Massachusetts.

1. Witkop CJ Jr: Hereditary defects of dentin. *Dent Clin North Am* 19:25-45, 1975.
2. Shields ED, Bixler D, El Kafrawy AM: A proposed classification for heritable human dentine defects with a description of a new entity. *Arch Oral Biol* 18:543-53, 1973.
3. Steidler NE, Radden BG, Reade PC: Dentinal dysplasia: a clinicopathological study of eight cases and review of the literature. *Br J Oral Maxillofac Surg* 22:274-86, 1984.
4. Rushton MA: A case of dentinal dysplasia. *Guys Hosp Rep* 89:369-73, 1931.
5. Eastman JR, Melnick M, Goldblatt LI: Focal odontoblastic dysplasia: dentin dysplasia Type III? *Oral Surg* 44:909-14, 1977.
6. Brenneise CV, Dwornik RM, Brenneise EE: Clinical radiographic, and histological manifestations of dentin dysplasia,

- type I: report of a case. *J Am Dent Assoc* 119:721-23, 1989.
7. Meirs DR, Herbert FL: Dentinal dysplasia type I: report of case. *ASDC J Dent Child* 57: 299-302, 1990.
8. Melnick M, Levin LS, Brady J: Dentin dysplasia type I: a scanning electron microscopic analysis of the primary dentition. *Oral Surg Oral Med Oral Pathol* 50:335-40, 1980.
9. Ciola B, Bahn SL, Goviea GL: Radiographic manifestations of an unusual combination of Type I and Type II dentin dysplasia. *Oral Surg Oral Med Oral Pathol* 45:317-22, 1978.
10. Sauk JJ, Lyons HW, Trowbridge Ho, Witkop CJ: An electronoptical analysis and explanation for the etiology of dentin dysplasia. *Oral Surg Oral Med Oral Pathol* 33:763-71, 1972.
11. Tidwell E, Cunningham CJ: Dentinal dysplasia: endodontic treatment, with case report. *J Endodont* 5:372-76, 1979.
12. O'Carroll MK, Duncan WK, Perkins TM: Dentin dysplasia: review of the literature and a proposed subclassification based on radiographic findings. *Oral Surg Oral Med Oral Pathol* 72:119-25, 1991.
13. Scola SM, Watts PG: Dentinal dysplasia Type 1. A subclassification. *Br J Orthod* 14:175-79, 1987.
14. Rosenberg LR, Phelan JA: Dentin dysplasia type II: review of the literature and report of a family. *ASDC J Dent Child* 50:372-75, 1983.
15. Bixler D: Heritable disorders affecting dentin. In: *Oral Facial Genetics*, Stewart RE, Prescott GH, Eds. St Louis: CV Mosby Co, 1976, pp 227-61.
16. Burkes EJ Jr, Aquilino SA, Bost ME: Dentin dysplasia II. *J Endodont* 5:277-81, 1979.
17. Jasmin JR, Clergeau-Guerithault S: A scanning electron microscopic study of dentin dysplasia type II in primary dentition. *Oral Surg Oral Med Oral Pathol* 58:57-63, 1984.
18. Logan J, Becks H, Silverman S Jr: Dentinal dysplasia. *Oral Surg Oral Med Oral Pathol* 15:317-33, 1962.
19. Wesley RK, Wysocki GP, Mintz SM, Jackson J: Dentin dysplasia type I: Clinical, morphologic and genetic studies of a case. *Oral Surg Oral Med Oral Pathol* 41:516-24, 1976.
20. Bixler D, Conneally PM, Christen AG: Dentinogenesis imperfecta: genetic variation in a six-generation family. *J Dent Res* 48:1196-99, 1969.
21. Levin LS: The dentition in the osteogenesis imperfecta syndromes. *Clin Orthop* 159:64-74, 1981.
22. Witcher SL Jr, Drinkard DW, Shapiro RD, Schow CE Jr: Tumoral calcinosis with unusual dental radiographic findings. *Oral Surg Oral Med Oral Pathol* 68: 104-7, 1989.
23. Gorlin RJ, Cohen MM Jr, Levin LS: *Syndromes of the Head and Neck*, 3rd ed. Oxford: Oxford University Press, 1990, pp 801-10.
24. Morris ME, Augsburger RH: Dentine dysplasia with sclerotic bone and skeletal anomalies inherited as an autosomal dominant trait: a new syndrome. *Oral Surg Oral Med Oral Pathol* 43:267-83, 1977.
25. Coke JM, Del Rosso G, Remeikis N, Van Cura JE: Dentinal dysplasia, Type I: report of a case with endodontic therapy. *Oral Surg Oral Med Oral Pathol* 48:262-68, 1979.