

Root agenesis associated with chronic infection and traumatic curettage of the maxillary sinus

W. Kim Seow, BDS, MDS, DSc, PhD, FRACDS

Abstract

A healthy 13-year-old female was found to have no roots on the maxillary left second premolar and permanent first and second molars. Her history included chronic sinus infections treated with maxillary sinus curettage at approximately 4 years of age. The infection, or more likely the trauma associated with the surgery, may have caused agenesis of the roots. Other causes of rootless teeth such as odontodysplasia, dentin dysplasia, trauma, infection, radiation therapy, and neoplasia were excluded from her history and clinical and radiographic findings. This report suggests that damage to the developing dentition may be a serious complication of maxillary sinus surgery or chronic infection. (*Pediatr Dent* 16:227-30, 1994)

Introduction

Teeth without roots represent one of the most challenging diagnostic and management problems for the pediatric dentist. Absence of roots may be the result of many diverse etiological factors (Table). The condition may arise from many developmental aberrations involving the radicular structures,¹⁻⁹ or may be the result of resorption of normally developed roots.¹⁰⁻¹⁹

Surgery or radiation of surrounding tissues may cause inadvertent damage to developing radicular tissues of immature teeth. In this report, complete destruction of the root structures of three maxillary permanent teeth was associated with chronic infection of

the maxillary sinus and antral curettage performed during the developmental stages of these teeth.

Case report

Medical and dental histories

The patient, a well-nourished and well-developed 13-year-old female was referred to the author by her orthodontist for abnormally developed left maxillary teeth. The abnormalities had been discovered during initial orthodontic evaluation, and the teeth were asymptomatic. The patient was allergic to penicillin and had mild asthma, which was controlled by bronchodilator sprays. Her mother reported that in early childhood, the patient had enlarged adenoids and chronic sinus infections, which prompted a maxillary sinus curettage operation at approximately age 4 years.

Her previous dental treatment had been routine re-

Table. Differential diagnosis of rootless teeth

- | |
|--|
| I. Lack of radicular development |
| (a) Developmental disorder of dentin: dentin dysplasia type 1 |
| (b) Regional developmental disorder: odontodysplasia |
| (c) Generalized dysmorphic disorder: brachio-skeletal-syndrome |
| II. Arrest of root development |
| (a) Trauma — orofacial accidents
— surgical procedures |
| (b) Infections |
| (c) Radiation therapy during root development |
| III. Resorption of previously developed roots |
| (a) Pressure — impacted teeth
— excessive orthodontic forces |
| (a) Trauma — orofacial accidents
— surgical procedures |
| (b) Infections |
| (c) Cysts |
| (d) Neoplasia — giant cell tumors, fibro-osseous lesions, ameloblastomas |
| (e) Endocrine disturbances |

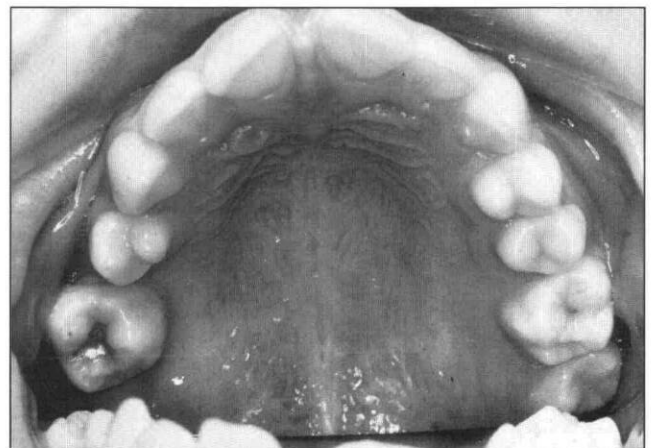


Fig 1. Occlusal view of the maxillary teeth. Note rotation of the maxillary left second premolar and first permanent molar into the space of the second premolar.

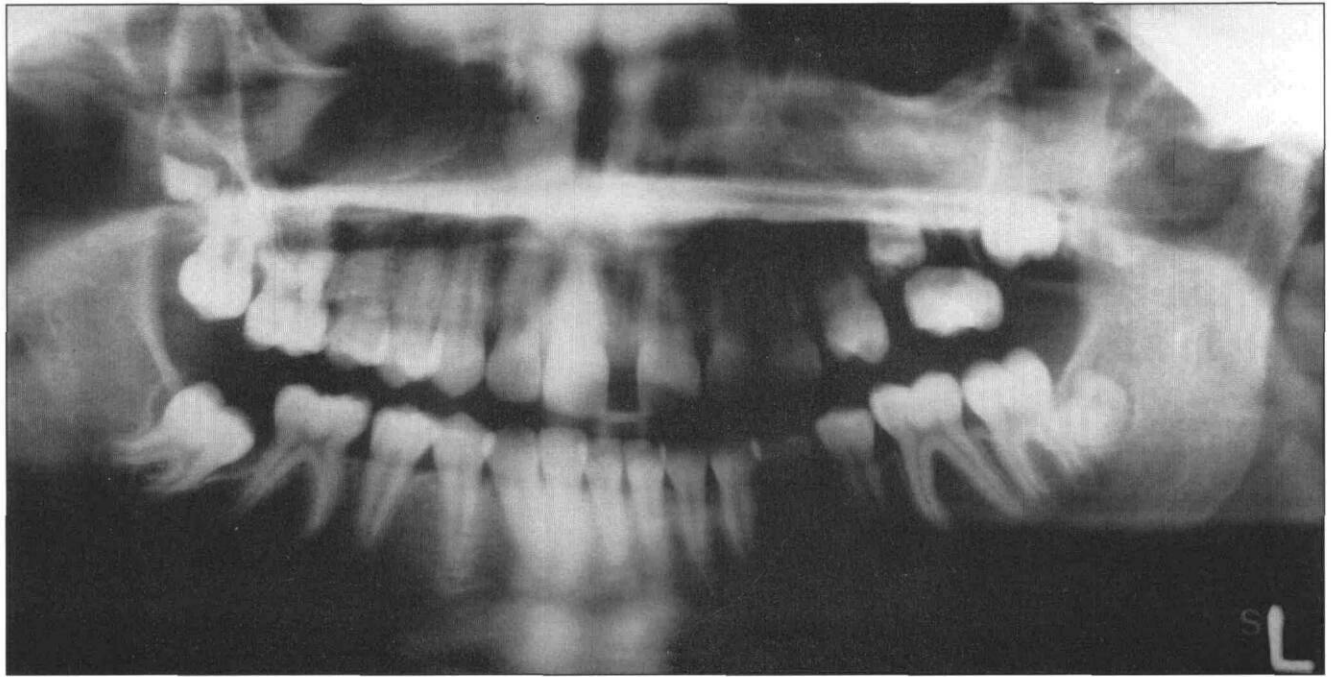


Fig 2. Panoramic radiograph showing agenesis of the roots of the maxillary left second premolar and first and second molars. Abnormal mesial angulation of the mandibular second right molar with dilacerated roots and follicular cyst were noted.

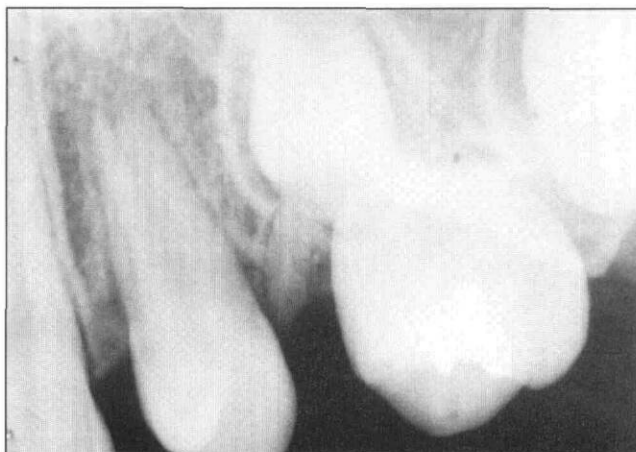

Fig 3. Periapical radiographs showing absence of roots on the maxillary left first molar and second premolar. A retained primary tooth root was also present between the first premolar and first molar.

storative and preventive care at the school dental service and private general practitioners' offices. The primary dentition was reported to have been unremarkable in its presentation, eruption, and exfoliation patterns.

Dental examination

The patient had a generally symmetrical face with no dysmorphic features or lymphadenopathy. Soft tissues were generally healthy and oral hygiene was good.

She had a full permanent dentition except for the maxillary left second premolar and permanent second molar, and the mandibular second right permanent

molar. Mild crowding of the mandibular anterior teeth was noted and there was a diastema of approximately 3 mm between the central permanent incisors. In the maxillary left quadrant, the first premolar and the first permanent molar appeared rotated into the space of the missing second premolar (Fig 1). Also, the maxillary left first permanent molar appeared to be ankylosed on percussion, although it occluded with the mandibular teeth. Pulp tests revealed a mild response of this tooth to cold.

A panoramic radiograph (Fig 2) revealed all the permanent teeth to be present, except for the mandibular right third molar. The maxillary left permanent first and second molars and the second premolar appeared to have no root structures. The crowns of these teeth appeared to be completely formed, and the radiodensity of enamel and dentin appeared normal. In addition, the mandibular right second permanent molar was noted to be erupting ectopically. Periapical radiographs (Fig 3) of the maxillary left first and second molars and the second premolar confirmed the radiographic features noted on the panoramic radiograph, including lack of root development. In addition, a retained primary tooth root was noted between the maxillary left second premolar and the maxillary permanent first molar. The bone surrounding the rootless teeth appeared normal.

Differential diagnosis and dental management

The radiographic and clinical appearances of the rootless teeth suggested an arrest of root development after normal, complete crown formation. The history of sinus curettage at approximately 4 years of age suggests

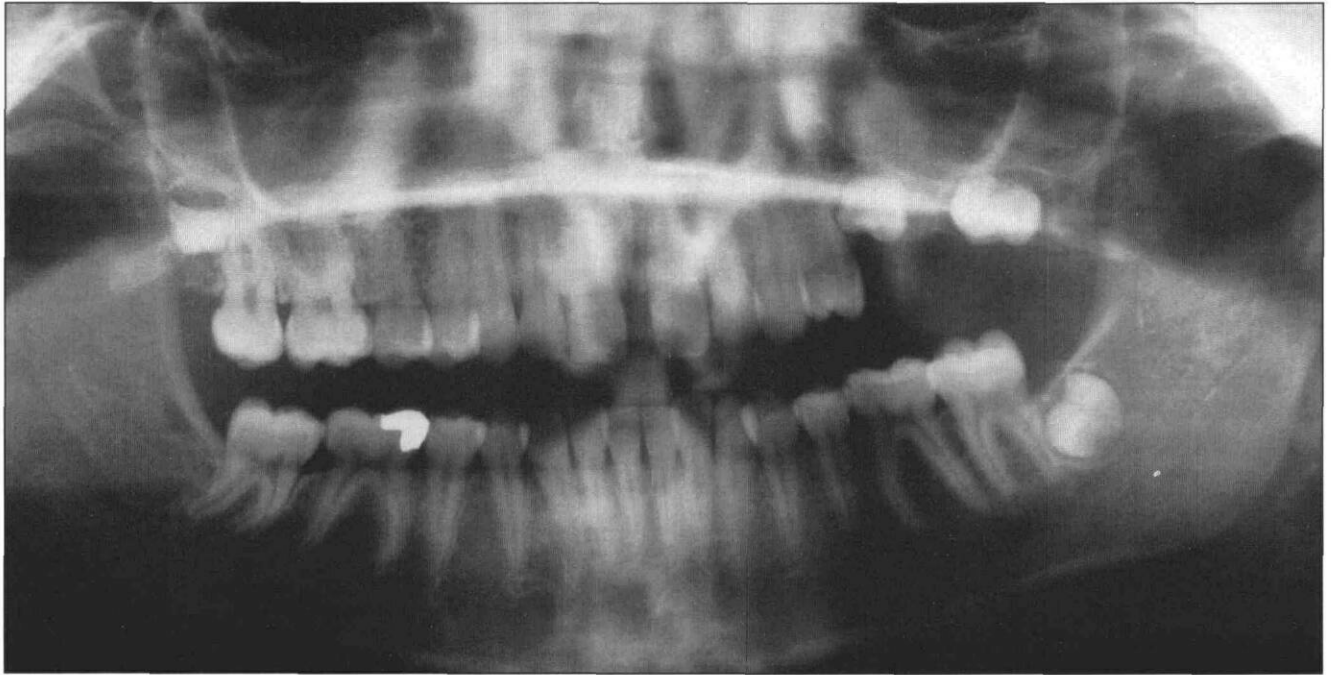


Fig 4. Panoramic radiograph of patient taken approximately 6 months after initial examination, confirming the arrest of root development of the maxillary left second premolar and second permanent molar. The surrounding bone appeared normal. The maxillary left first permanent molar had been extracted.

the etiology was likely trauma from this surgical procedure or the underlying infection. Other conditions presenting with rootless teeth such as neoplasias, post-radiation therapy, odontodysplasia, or dentin dysplasia were excluded from the history and clinical presentations.

The erupted maxillary left first permanent molar and the retained root tip were extracted first under local anesthesia, and a piece of surrounding bone was sent for biopsy; it proved to be normal. Healing was uneventful. The patient was followed up at 6-month recall intervals to monitor the eruption of all the permanent teeth. The other rootless teeth would be extracted as they erupted into the oral cavity. A prosthesis to replace the missing teeth would then be considered.

A second panoramic radiograph exposed 6 months later confirmed the arrested root development on the second premolar and second molar (Fig 4).

An alternative plan to transplant the permanent right second molar into the socket of the left first permanent molar was unacceptable to the parent.

Discussion

The differential diagnosis of rootless teeth must consider whether the absence of roots has resulted from a primary maldevelopment of the radicular structures or secondarily from the resorption of already formed roots. As shown in the Table, a few developmental conditions are associated with absence of roots. Of importance is a genetic dental condition known as dentin dysplasia type I,^{1,2} an autosomal dominant condition with a popu-

lation frequency of approximately 1:100,000. In this condition the dental crowns are usually normal size, shape, and color, but the teeth are usually malaligned and mobile. Radiographically, the roots are typically short with sharp, conical constrictions, and show extensive pulp obliterations associated with periapical radiolucencies.^{1,2}

Regional odontodysplasia^{3,4} is a developmental aberration in which all the dental structures in a section of dental arch are abnormally formed. Regional disturbances in vascular supply have been suggested as etiological factors. Typically, both crown and root development are affected, the enamel and dentin are severely hypoplastic, and the outlines of the teeth appear as "ghost" structures.^{3,4} Very often, abscesses of the teeth occur early.

Rootless teeth are also encountered in the brachioskeletal genital syndrome, a rare, generalized dysmorphic disorder characterized by abnormal facies (brachycephaly, midface hypoplasia, hypertelorism), eye defects (nystagmus, strabismus, ptosis), skeletal defects, as well as genital defects (hypospadias).^{5,6} Oral manifestations of this condition include multiple dentigerous cysts, cleft of the soft palate, and teeth having obliterated pulps and dysplastic dentin.^{5,6}

Arrest of root development may occur as a result of trauma⁷ from orofacial accidents as well as from surgery. Local infections secondary to trauma or dental caries have also been reported to arrest root development.⁷ Furthermore, children subjected to radiation for leukemia often show arrest of root formation of the

teeth developing at that time.^{8,9}

Resorption of normally formed roots often may result from trauma^{7,10,11} or infection of the surrounding tissues,^{7,10,12} and less often, from pressure from impacted teeth,¹³ or expanding lesions such as cysts^{10,14} or neoplasias.¹⁵⁻¹⁸ In children, neoplasias commonly associated with root resorption include giant cell tumors,¹⁶ fibro-osseous lesions,¹⁷ and ameloblastomas.¹⁸ Rarely, endocrine disturbances — particularly those related to parathyroid dysfunction — have been associated with generalized root resorption.¹⁹

In this report, pathology was localized to one quadrant of the mouth. Therefore, generalized medical or dental disorders were excluded in diagnosis. Also, clinical and radiographic examinations showed normal crowns of affected teeth, thus excluding the diagnosis of odontodysplasia. The normal alveolar bone in the region excluded the possibilities of expanding lesions. Histories negative for local odontogenic infections, orofacial trauma, and radiation therapy also excluded these causes.

It is most likely that the absence of roots of the maxillary second premolar and first and second permanent molars of this patient is associated with maxillary antral curettage performed at approximately 4 years old. At this age, the affected first permanent molar would have completed its crown formation, and the root development would have been in initial stages.²⁰ The second premolar and second permanent molar would have been at the final stages of crown development.²⁰ At this intermediate stage of odontogenesis, the developing roots may be prone to trauma to the surrounding areas. In this case, it is most probable that the Hertwig's root sheaths responsible for root development have been irreparably damaged or removed during surgery, causing root agenesis.

Maxillary sinus surgery is also associated with other local complications such as damage to the infraorbital nerve, resulting in anesthesia or paresthesia of the cheek and maxillary teeth.²¹ Excessive bleeding, postsurgical chronic infection and oroantral fistula have also been reported.²¹

This report thus demonstrates another dental complication that may be associated with chronic maxillary sinus infection and surgery in the young patient, and shows further that trauma sustained during odontogenesis may lead to permanent damage to the dentition.^{7,22,23}

Conclusions

In this case report, the absence of roots in the posterior left quadrant has most likely resulted from traumatic curettage of the maxillary sinus. This etiological factor may be included in the differential diagnosis of rootless teeth.

Dr. Seow is associate professor in pediatric dentistry, University of

Queensland Dental School, Brisbane, Australia, and visiting professor, Harvard School of Dental Medicine, and Children's Hospital, Boston.

1. O'Carroll MK, Duncan WK, Perkins TM: Dentin dysplasia: review of the literature and a proposed subclassification based on radiographic findings. *Oral Surg* 72:119-25, 1991.
2. Seow WK, Shusterman S: Dentin dysplasia type I: case report and review of the literature. *Pediatr Dent* (in press).
3. Kerebel B, Kerebel LM, Heron D, Le Cabellac MT: Regional odontodysplasia: new histological data. *J Biol Buccale* 17:121-28, 1989.
4. Guzman R, Elliot MA, Rossie KM: Odontodysplasia in a pediatric patient: literature review and case report. *Pediatr Dent* 12:45-8, 1990.
5. Gorlin RJ, Cohen MMJ, Levin LS: *Syndromes of the head and neck*, 3rd ED, Oxford: Oxford University Press, 1990, pp 801-2.
6. Wedgwood DL, Curran JB, Lavelle CL, Trott JR: Cranio-facial and dental anomalies in the Branchio-Skeleto-Genital (BSG) syndrome with suggestions for more appropriate nomenclature. *Br J Oral Surg* 21:94-102, 1983.
7. Andreasen JO: *Essentials of traumatic injuries of the teeth*. 3rd ed, Copenhagen: Munksgaard, 1990, pp 273-320.
8. Jaffe N, Toth BB, Hoar RE, Reid HL, Sullivan MP, McNeese MD: Dental and maxillofacial abnormalities in long-term survivors of childhood cancer: Effects of treatment with chemotherapy and radiation to the head and neck. *Pediatrics* 73:816-22, 1984.
9. Sonis AL, Tarbell N, Valachovic RW, Gelber R, Schwenn M, Sallan S: Dentofacial development in long-term survivors of acute lymphoblastic leukemia: a comparison of three treatment modalities. *Cancer* 66:2645-52, 1990.
10. Tronstad L: Root resorption — etiology, terminology and clinical manifestations. *Endo Dent Traumatol* 4:241-52, 1988.
11. Gerner NW, Hurlen B, Bergland O, et al: External root resorption in patients with secondary bone grafting of alveolar clefts. *Endodont Dent Traumatol* 2:263-66, 1986.
12. Solomon CS, Coffiner MO, Chalfin HE: Herpes zoster revisited: implications in root resorption. *J Endodont* 12:210-13, 1986.
13. Peterson LJ: Rationale for removing impacted teeth: when to extract or not to extract. *J Am Dent Assoc* 123:198-204, 1992.
14. Andreasen JO: External root resorption: its implication in dental traumatology, paedodontics, periodontics, orthodontics and endodontics. *Int Endodont J* 18:109-18, 1985.
15. Chuong R, Kaban LB: Diagnosis and treatment of jaw tumors in children. *J Oral Maxillofac Surg* 43:323-32, 1985.
16. Chuong R, Kaban LB, Kozakewitch H, Perez-Atayde A: Central giant cell lesions of the jaws: A clinicopathologic and cytometric study. *J Oral Max Surg* 44:708-13, 1986.
17. Houston WO: Fibrous dysplasia of maxilla and mandible: Clinicopathologic study and comparison of facial bone lesions with lesions affecting general skeleton. *J Oral Surg* 23:17-39, 1965.
18. Robinson L, Martinez MG: Unicystic ameloblastoma: A prognostically distinct entity. *Cancer* 40:2278-85, 1977.
19. Croft LK, Witkop CJ, Glas JE: Pseudohypoparathyroidism. *Oral Surg* 20:758-62, 1965.
20. Nolla CM: Development of the permanent teeth. *J Dent Child* 27:254-66, 1960.
21. Kylander CE: Complications of surgery of the paranasal sinuses. *Surg Clin North Amer* 48:269-475, 1968.
22. Seow WK, Brown JP, Tudehope DI, O'Callaghan M: Developmental defects in the primary dentition of very low birthweight infants: adverse effects of laryngoscopy and prolonged endotracheal intubation. *Pediatr Dent* 6:28-31, 1984.
23. Seow WK, Perham S, Young WG, Daley T: Dilaceration of primary maxillary incisor associated with neonatal laryngoscopy. *Pediatr Dent* 12:321-24, 1990.