

## Complete overlay dentures for the pediatric patient: case reports

Erle Schneidman, BS, DDS Stephen Wilson, MA, DMD, PhD  
Richard L. Spuller, DDS

### Abstract

*Overlay dentures are complete or partial removable dentures that are fabricated over retained teeth or roots that are not specially prepared to accept copings. The following report will review overlay dentures for the pediatric patient with respect to considerations in fabrication and advantages. Also, 2 reports of children who were treated with complete overlay dentures are presented.*

An overlay denture is a complete or partial removable denture fabricated over retained teeth or roots that are not prepared with a coping to interface with the denture (Brewer and Fenton 1973). This is in contrast to an overdenture in which the remaining teeth require endodontic treatment and cast gold copings (Lord and Teel 1969).

Indications of an overlay denture include congenital disorders (e.g., cleft palate), oligodontia, ectodermal dysplasia, and cleidocranial dysplasia. The fabrication of overlay dentures also may be the treatment of choice for other disorders that are associated with malformed or missing teeth, and for patients with severely eroded or abraded teeth (Johnson and Winstanley 1987).

The following report will review overlay dentures for the pediatric patient with respect to considerations in fabrication and advantages to the patient. Also, it will present 2 case reports in which children were treated with complete overlay dentures.

### Treatment Considerations

Although similar in construction to an adult complete denture, certain important considerations should be addressed in the fabrication of a pediatric overlay denture. Prior to denture fabrication, all carious teeth should be restored, the patient should be given proper oral hygiene instruction, and should also demonstrate acquisition of oral hygiene skills.

Alginate impressions are taken and study models are made of stone. The models are surveyed to locate any tooth undercuts that may prevent the denture from seating into its proper position. Once identified, malaligned teeth may be crowned with stainless steel crowns, enameloplasty performed, or may be extracted in order to establish an adequate insertion path. Custom acrylic trays are made and are border molded similarly to an adult denture. To ensure proper fit, care should be taken when border molding, as the vestibule is relatively shallow compared to that of an adult due to lack of development of the alveolar bone in younger children. A final rubber base impression is taken and a cast made of stone. Acrylic base plates with occlusal rims are made and the vertical dimension of occlusion is established.

Due to tooth loss, lack of alveolar ridge development, and severe tooth wear, the patient's vertical dimension may be considerably diminished. This condition usually necessitates steps designed to increase the vertical dimension of occlusion. However, these steps may inadvertently create an esthetic problem in that the alveolar ridges in the posterior region become separated by increasing the vertical dimension. As a result of this rotation of the mandible, a relatively wider space occurs between the alveolar ridges in the anterior region. In these conditions, a proper overbite and overjet relationship is difficult to establish. Therefore, the anterior teeth may have to be set in a slightly opened position.

A facebow transfer and jaw relation records are taken to relate the casts which are mounted on a suitable articulator. A Class III relationship between mandible and maxilla may be encountered due to a lack of development of maxillary alveolar bone, and should be addressed when setting the teeth.

Since the child may be in primary or transitional dentition, consideration of tooth selection may be difficult and should be made in consultation with the patient

and parent. For primary dentition, Bambino® denture teeth (OSE Dental Supplies and Equipment, Division Orthodontic Supply and Equipment Co., Inc.; Gaithersburg, MD) can be used. The selected denture teeth are arranged in wax and tried in the patient's mouth for evaluation of function and esthetics. After a satisfactory try-in, the denture is processed, remounted to adjust the occlusion, and then delivered to the patient. During the final try-in, the denture is seated and the occlusal and flange portions of the denture are adjusted if necessary. Home care instructions are given which include removal of the dentures at night and brushing both the dentures and natural teeth after every meal. For caries-prone children, fluoride gels may be placed inside the dentures to help protect the patient's remaining dentition. An example of an overlay denture can be seen in Figures 1a and 1b.

Follow-up care is most important. Patients are recalled on a regular basis for dental prophylaxis, examinations, oral hygiene instruction, and denture adjustments. The dentures can be modified by adding acrylic as teeth exfoliate or by grinding concavities into the denture for erupting teeth. It may be necessary to relin the denture or remake it as the child grows and develops.

#### Advantages of Overlay Dentures

The complete overlay denture has numerous advantages for the pediatric patient. Enhanced mastication and esthetics are the more obvious benefits and speech also may be improved. The alveolar bone is maintained by the retention of teeth compared to its loss when teeth are extracted. With the retained teeth and their periodontal ligament, there is increased proprioception compared to a complete denture that is fabricated over an edentulous ridge (Loiselle et al. 1972). Compared to an overdenture, an overlay denture is less expensive, requires less chair time, and does not require any specialized tooth preparation. When fabricated properly,

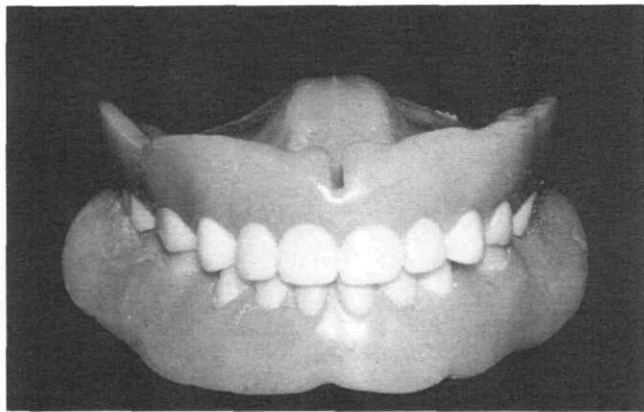


FIG 1a. Overlay denture shown in occlusion.

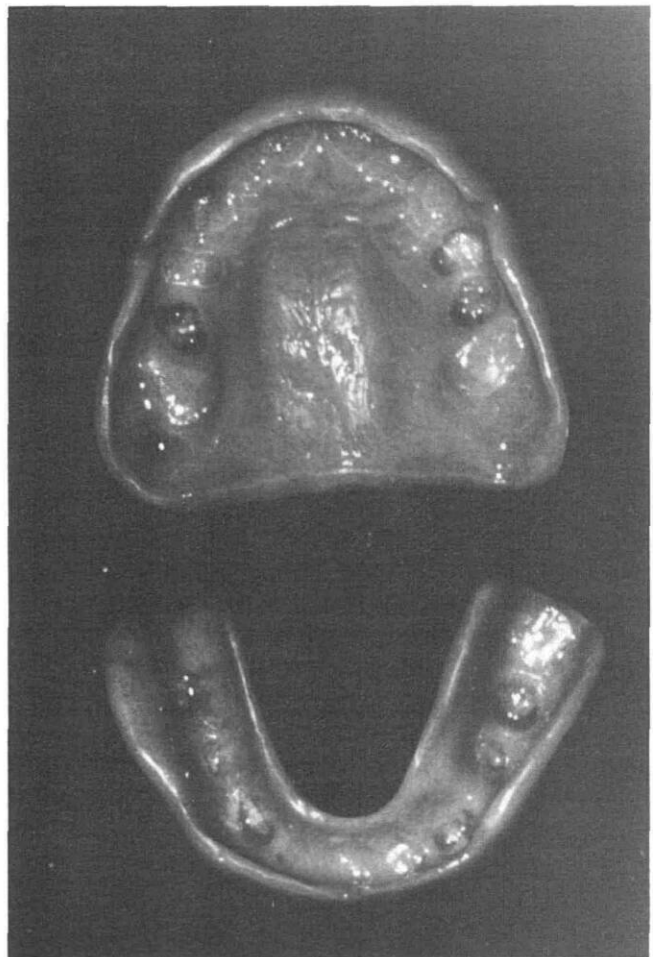


FIG 1b. Tissue-bearing view of the same overlay dentures. Note the impressions in the denture that fits over the patient's retained teeth.

an overlay denture has excellent retention and stability.

Possibly, the most important advantage of an overlay denture is the positive psychological support for the child. The child may no longer be ridiculed by peers and this situation may result in increased self esteem and confidence. Frequently, parents request a dental prosthesis before their child begins school, and assuming the child is mature enough, this is an excellent time to fabricate an overlay denture.

#### Case Reports

##### Case 1

A 10-year-old white female (Figs 2, 3 – next page) with a history of ectodermal dysplasia presented to the dental clinic with a denture that had been fabricated 4 years earlier, but no longer fit.

Initially, a relin of the old denture was attempted. However, this did not succeed and a new denture was



FIG 2. A 10-year-old female with a history of ectodermal dysplasia exhibiting a relatively short lower facial height and oligodontia.

fabricated. Important considerations in fabricating the new denture were the patient's loss of vertical dimension of occlusion and Class III profile. The overlay denture was completed with the vertical dimension increased and the profile improved. Most noticeably, the patient's attitude and disposition had changed (Fig 4).

### Case 2

A 13-year-old white male (Fig. 5) whose diagnosis was dentinogenesis imperfecta type II (Shields et al. 1973) presented to the dental clinic complaining of constant peer harassment. Dentinogenesis imperfecta type II, or hereditary opalescent dentin, is inherited as an autosomal dominant trait affecting approximately 1:3000 persons. Clinical features include a characteristic translucent or opalescent hue of the teeth and rapid abrasion of occlusal surfaces due to brittle enamel (Fig. 6). Radiographically, there may be partial or total obliteration of pulp chambers and canals, and short, blunted roots.

Following extraction of the abscessed maxillary right primary canine and mandibular left first permanent molar, a complete overlay denture was fabricated following the technique of Rivers and Staffanau (1985). It was necessary to leave a slight anterior open bite in order to meet esthetic and functional requirements (Fig. 7). During the 6-month recall, the patient reported that he was satisfied with his dentures and that the teasing in school had stopped.

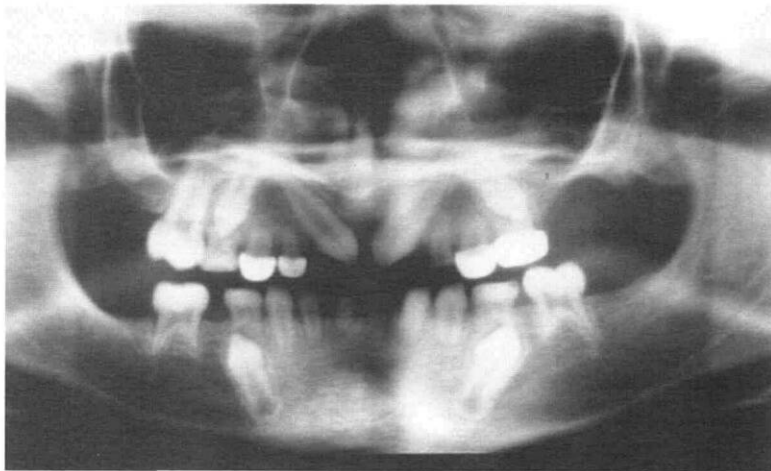


FIG 3. Oligodontia and malformed teeth typical of ectodermal dysplasia.

### Summary

Complete overlay dentures are relatively easy to fabricate and render satisfactory results for the pediatric patient. Certain considerations should be addressed while designing these prostheses, including vertical dimension, overbite, and overjet relationships. Advantages of an overlay denture include: im-



FIG 4 (left). Patient displaying her overlay dentures. Her disposition and attitude improved following the delivery of the dentures.

FIG 5 (right). Patient with dentinogenesis imperfecta. Note the "old man" appearance.



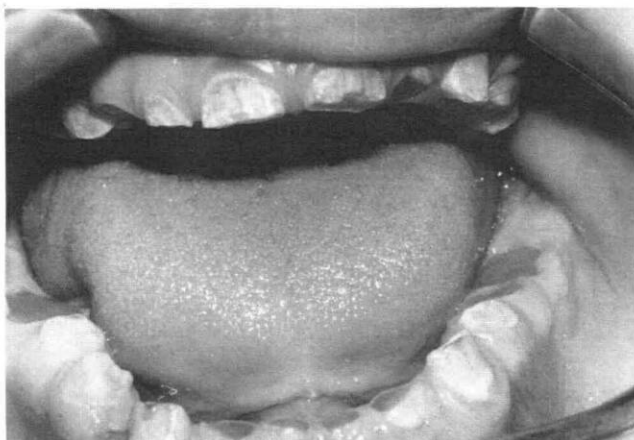



FIG 6. Dentition of patient with dentinogenesis imperfecta. Severe attrition was observed.

proved esthetics, speech, and mastication; low cost; little chair time; reversibility; alterability; maintenance of alveolar bone and proprioception; and excellent retention and stability. Most importantly, there is a great psychological benefit to the young patient.

At the time of the study Dr. Schneidman was chief resident, Children's Hospital, Columbus, Ohio; Dr. Wilson is an assistant professor, pediatric dentistry, The Ohio State University; and Dr. Spuller is in the private practice of pediatric dentistry, Findlay, Ohio. Reprint requests should be sent to: Dr. Stephen Wilson, Dept. of Pediatric Dentistry, The Ohio State University College of Dentistry, 305 W. 12th Ave., Columbus, OH 43210-1241.

FIG 7 (right). Patient displaying dentures in occlusion. The slight anterior open bite is noticeable, but does not deter from the esthetics.



Brewer AA, Fenton AH: The overdenture. *Dent Clin North Am* 17:723-46, 1973.

Johnson A, Winstanley RB: Use of simple overdentures in the treatment of young patients with developmental anomalies. *Quintessence* 11: 27-33, 1987.

Loiselle RJ, Crum RJ, Rooney GE, Stuever CH: The physiological basis for the overlay denture. *J Prosthet Dent* 28:4-12, 1972.

Lord JL, Teel S: The overdenture. *Dent Clin North Am* 13:871-81, 1969.

Rivers JA, Staffanau RS: Restorative treatment of dentinogenesis imperfecta in a young adult. *Compendium of Continuing Education in Dentistry* 6:548-54, 1985.

Shields ED, Bixler D, El-Kafrawy AM: Heritable dentin defects: dentine dysplasia type II. *Arch Oral Biol* 18:543, 1973.

## Freeze-dried dentin

Allogenic freeze-dried dentin is being used to repair periodontal osseous defects. The product is made from recently extracted, caries-free teeth. The dentin is ground to 300-500- $\mu$ m size, then freeze-dried, sterilized, and packaged in 1-g pouches. Just before using, the dentin is hydrated for 20 min with sterile saline solution and is then placed with minimal compression to the rims of the periodontal defects.

In a clinical study of 16 cases where freeze-dried dentin was placed in a variety of osseous defects, in every case there was significant clinical osseous regeneration.