



# Aberrant Root Formation: Review of Root Genesis and Three Case Reports

Tarnjit S. Saini, DDS, MS   Nicole S. Kimmes, BS, DDS   Gary H. Westerman, DDS, MS

*Dr. Saini is associate professor of general dentistry, Dr. Kimmes is assistant professor of general dentistry, and Dr. Westerman is professor and chair, Department of Community and Preventive Dentistry, Creighton University, School of Dentistry, Omaha, Neb.*

*Correspond with Dr. Westerman at ghweste@creighton.edu*

---

## Abstract

The mechanism of root formation and tooth eruption is a complex process which is not fully understood. Prior to a tooth emerging into the oral cavity, root genesis is initiated by derivatives of the enamel organ. The dental follicle mediates an eruption pathway allowing for movement of the developing tooth in a coronal direction. As the tooth moves towards the oral cavity, root formation occurs passively in the resulting space. Failure of the enamel organ and dental follicle to properly coordinate may result in complications in the eruption process. This clinical report presents 3 cases of isolated, unerupted teeth with dysmorphology of the roots. The process of root development and tooth eruption is also briefly reviewed. (*Pediatr Dent.* 2004;26:261-265)

**KEYWORDS:** ROOT GENESIS, SUPERNUMERARY PREMOLARS, IMPACTED PRIMARY MOLAR, TOOTH ERUPTION, DENTAL FOLLICLE

---

*Received June 9, 2003   Revision Accepted February 11, 2004*

Root genesis occurs following the completion of crown formation as a result of intricate interactions between dental epithelial and mesenchymal tissues.<sup>1</sup> After root formation is initiated, an eruption pathway is laid down by the dental follicle, allowing for movement of the developing tooth towards the oral cavity. The coronal movement of the developing tooth is accompanied by passive root growth to fill the resulting space.<sup>2</sup>

The developmental process of root formation is phylogenetically conserved and provides a characteristic range of morphological patterns.<sup>3</sup> Environmental factors such as chemotherapy, radiation therapy, and trauma may affect the morphology of the developing root.<sup>4</sup> Hereditary anomalies, such as dentin dysplasia type I, have been reported to result in marked root aberrations.<sup>5</sup> The rate of root genesis can be slowed down unduly in second premolars with delayed development<sup>6</sup> or in supernumerary premolars.<sup>7</sup> Idiopathic root agenesis of 2 maxillary right premolars was reported by Held and Alexander<sup>8</sup> in a 15-year-old white male. The rootless premolars with diminutive crowns demonstrated pulpal obliteration and had erupted into the coronal one third of the alveolar process. The authors referred to 2 other case reports describing diminished or stunted root formation that should not be considered as cases of idiopathic root agenesis.

This clinical report presents 3 cases of isolated, unerupted teeth with dysmorphology of the roots. In each of the cases, clinical examination did not reveal congenital abnormalities or systemic disease. The process of root development and tooth eruption also is reviewed briefly.

## Case 1

A 14-year-old Hispanic female reported for a routine dental examination. An intraoral examination revealed a retained carious and nonrestorable maxillary right primary second molar. A radiograph (Figure 1A) showed an impacted maxillary right second premolar with completed crown formation. The tooth was located close to the floor of the maxillary sinus near the apical third of the mesiobuccal root of the maxillary right permanent first molar. The buccal and lingual cusps were visible in the radiograph due to the existing rotated position of the crown. Radiographically, there was no evidence of pulpal obliteration or internal resorption. The absence of root formation was noticed around the impacted tooth. No history of trauma or significant medical history was recalled by the patient. Second premolars in the other 3 quadrants had erupted and demonstrated complete root formation. A 1-year follow-up radiograph (Figure 1B) revealed no change in location or evidence of root development of the second premolar. Mesial tipping of the maxillary

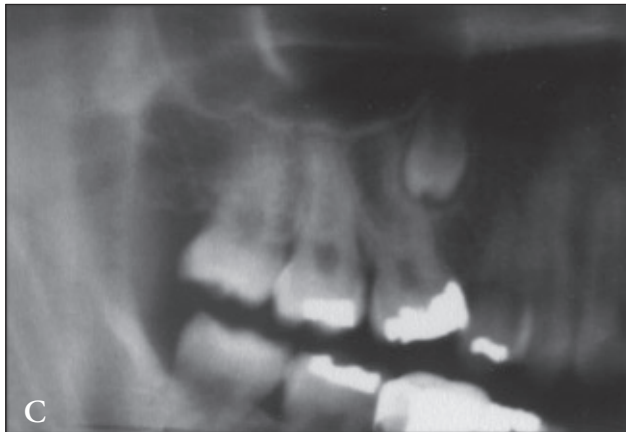
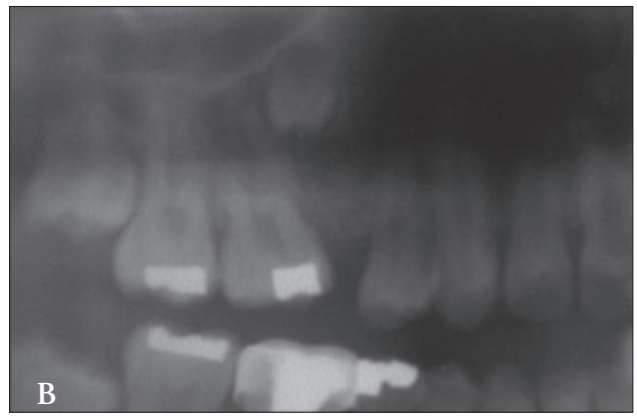
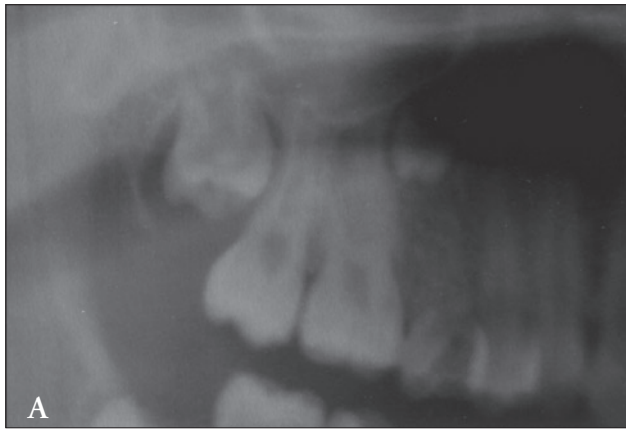


Figure 1A. Radiograph of a 14-year-old female depicting an impacted maxillary right second premolar with completed crown formation. Figure 1B. One year follow-up radiograph showing no evidence of root formation or eruption of the impacted maxillary right second premolar. Figure 1C. Three years later, the impacted maxillary right second premolar is showing that root trunk formation has been initiated. However, no significant change in coronal position is evident. Also evident is the completed eruption of maxillary and mandibular third molars.

right permanent first molar was evident, and the patient was advised to have a fixed space maintainer placed or receive orthodontic intervention.

When the patient returned for a recall examination 2 years later, it was noted radiographically that the root trunk appeared to have begun to form, but neither the coronal position of the crown nor the floor of the sinus showed any change (Figure 1C). The mesially tipped maxillary right permanent first molar was in contact with the maxillary right first premolar. In addition, the maxillary right permanent third molar had erupted and was nearing completion of root development. Orthodontic intervention to correct the occlusal dysfunction was once again recommended to the patient.

### Case 2

A 30-year-old Hispanic male reported for a routine dental examination. Panoramic radiography showed eruption of all permanent teeth with the exception of an impacted maxillary right second premolar. The patient's medical history was noncontributory, and no history of trauma was recalled. A periapical radiograph (Figure 2) of the area confirmed the presence of an impacted second premolar adjacent to the floor of the maxillary sinus. The tooth was located near the apical third of the mesiobuccal root of the maxillary right permanent first molar. The floor of the maxillary sinus was in close approximation to the distal aspect of the crown. A total lack of root formation was suspected due to the knife-

edge appearance of the enamel near the cemento-enamel junction of the crown. The radiograph also demonstrated evidence of the crown undergoing resorption. The mesially tipped maxillary right permanent first molar was in contact with the maxillary right first premolar. Clinically, the crown of the impacted tooth was palpable near the vestibule as a well-circumscribed bony hard swelling. Periodic radiographic examination of the area was suggested to the patient to monitor resorption of the adjacent roots or cystic transformation of the involved tooth.

### Case 3

A 14-year-old white female complained of a broken (missing) filling in her mandibular left permanent first molar. A clinical intraoral examination revealed in the maxillary right posterior quadrant the presence of an ectopically erupted permanent canine in contact with a mesially tipped permanent first molar and a retained primary canine. The mandibular right posterior quadrant consisted of the first premolar, a retained primary second molar, and the permanent first molar. Radiographic examination (Figure 3) of these 2 same quadrants revealed several missing permanent teeth; maxillary third molar, maxillary first and second premolars, mandibular second premolar, and the mandibular second and third molars. The radiograph also revealed the presence of an unerupted maxillary permanent second molar and an image morphologically interpreted to be consistent with that of a primary molar, hence, it was diagnosed to be a retained primary second molar. However, it could be further argued that the impacted tooth was a malformed premolar. Familial incidence of congenital anomalies, history of trauma, and significant medical history could not be obtained. Surgical intervention to extract the primary molar was not recommended, as it was already showing

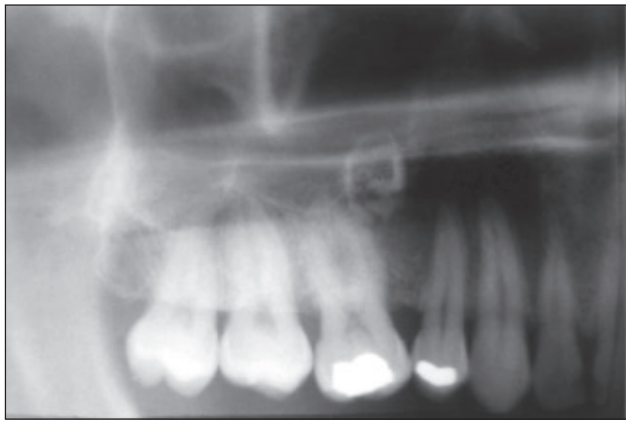

Figure 2. Periapical radiograph of a 30-year-old male with an impacted maxillary right second premolar showing evidence of resorption.

signs of internal resorption. The patient did seek out orthodontic treatment.

### Discussion

Root genesis, cementogenesis, and tooth eruption are interrelated processes. Prefunctional development of the roots of permanent teeth is a protracted phenomenon in humans and may continue for 5 to 7 years prior to the tooth emerging into the oral cavity.<sup>9</sup> After the completion of crown formation, inner and outer enamel epithelial cells of the enamel organ join together at the cervical end to form the epithelial root sheath of Hertwig (ERSH). The ERSH is oriented 45 degrees to the crown margin and appears like a diaphragm delineating the dental papilla from the dental follicle. Inner enamel epithelial components of the ERSH mediate transformation of peripheral cells of the dental papilla (ectomesenchymal origin) into odontoblasts.

The odontoblasts undergo proliferation and secrete a predentin matrix in an orderly gradient fashion. Initiation of mineralization of predentin signals the cells of the ERSH to uncouple from the dentinal surface and move a distance to form the epithelial rests of Malassez. This uncoupling creates fenestrations or holes, like those of a fish net, in the ERSH. Ectomesenchymal cells of the dental follicle migrate through these fenestrations to come in contact with the dentinal surface, which modulates their transformation into cementoblasts. The cementoblasts will secrete a cementum matrix which mineralizes, resulting in a layer of cementum overlying the dentin.<sup>1</sup>

Surrounding the enamel organ of the developing crown is a thin, dense ectomesenchymal connective tissue termed the dental follicle.<sup>2</sup> Shortly after root formation begins, the dental follicle lays down an eruption pathway which is traversed by the developing tooth on its way toward the oral mucosa. The formation of this pathway is the rate-limiting step of early eruption.<sup>10</sup> Specialized cells in the dental follicle result in selective bone turnover, which occurs in a polarized manner. Bone resorption occurs occlusal to the developing tooth and bone apposition occurs apical to the developing root.<sup>2</sup> As the tooth moves coronally, additional

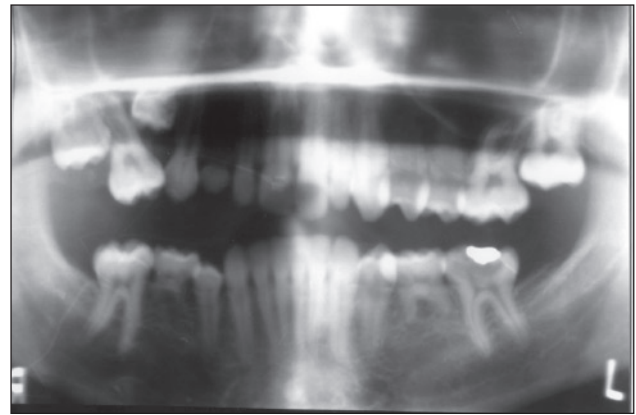


Figure 3. Panoramic radiograph of a 14-year-old female showing an impacted maxillary right primary second molar and no evidence of the development of several permanent teeth.

root growth occurs, filling the space passively.<sup>11</sup> Iizuka et al<sup>12</sup> stated that each tooth is characterized by a temporal phase of eruption in which a specific tooth is capable of eruption. Normal eruption is compromised if the eruption pathway is not manifested during this period, resulting in ankylosis in some cases.

Genetic and biochemical information about root genesis and eruption is limited.<sup>13</sup> Rodent studies have demonstrated that eruption is a localized phenomenon involving polygenetic interactions in which the genes exhibit a redundancy of function.<sup>14</sup> The cells of the ERSH elaborate the transcription factors of homeobox genes *Dlx-2* and *Msx-2*, which may play a role in early differentiation of epithelium.<sup>15,16</sup> Recent research has shown that agenesis of molar roots occurs in mice devoid of the gene *Nfic*. Mutations of the *Tabby* (*Ta*) and *Downless* (*Dl*) genes in mice result in defects in the later stages of odontogenesis.<sup>17</sup> A noncollagenous sialoprotein, *DF-95*, is expressed during early cementogenesis and may aid in initiating the formation of the cementum matrix and cementum mineralization by helping the migratory precemetoblasts attach to the newly formed root dentin. Sialoprotein fragmentation during the initiation of cementogenesis has been considered a biochemical marker for eruption.

The localization of *DF-95* to reduced enamel epithelium (REE) provides biochemical evidence of the REE involvement and initiation of eruption.<sup>18</sup> The activation of proteases in the enamel organ after crown formation is thought to cause *DF-95* fragmentation and release of metalloproteinases by the dental follicle to initiate eruption.<sup>2</sup> Growth factors such as *TGF-B*, *EGF*, *Interleukin-alpha-1*, and *CSF-1* have been demonstrated to act as molecular regulators of eruption. The timing of the cascade of biochemical processes that trigger the initiation of root genesis in congruence with the rate of eruption is not known.<sup>19</sup>

The first case in the present series was interpreted as an impacted maxillary right second premolar. Lack of eruption was evidenced by the fact that the developed crown did not demonstrate bodily movement during the observed period. Developing enamel organs and developing crowns have been

reported to undergo pre-eruptional positional changes.<sup>20</sup> It might be inferred that the crown had completed development but was not followed immediately by root formation due to a delayed onset of root genesis. The postulation can also be made that the concerned tooth is a supernumerary premolar and the second premolar of the normal series did not develop due to localized oligodontia. Supernumerary premolars often have a severely delayed onset of root formation.<sup>7</sup> Inflammation associated with primary teeth can interrupt normal amelogenesis in the developing permanent teeth, as seen in a condition termed Turner's tooth. In severe cases, the crown appears shriveled and shell shaped. Root agenesis has been described to occur in nonvital Turner's tooth due to infective pulpal necrosis. The causative inflammation in these teeth may show evidence of follicle destruction or concomitant osseous changes in the surrounding bone around the dental crypt.<sup>21</sup> Such changes were not seen in this case.

Retrospective observation indicates that the nonresorbing premolar showing a lack of root formation and delayed eruption should have been extracted. The rate of root formation can be gauged by comparing the status of root genesis on the contralateral side. A fixed space maintainer should have been placed until the premolar was either replaced or orthodontic treatment was initiated.

The second case in the study involved a 30-year-old patient with an impacted maxillary right second premolar in an advanced stage of internal resorption. The dental crypt and associated REE/follicle space around the embedded crown were evidenced radiographically. It may be suspected that the dental follicle or enamel organ had undergone certain changes which failed to initiate eruption. Evidence exists which supports the eruption of rootless teeth, suggesting complications in the root-forming mechanisms, but not in the formation of the eruption pathway. Removal of the dental follicle has shown cessation of eruption of the developing tooth. It is difficult to establish whether the dental follicle or the enamel organ act independently or in combination to mediate eruption. There are practical limitations in surgically separating the tissues during experimentation.<sup>22</sup>

Replacement resorption usually ensues in embedded teeth which have long passed their normal time of eruption. Embedded teeth undergoing extensive resorption are often ankylosed due to osseous ingrowths into resorbed areas. The involved crown becomes fragile, and clinical distinction between dental and osseous structures may become very difficult during surgical exploration.<sup>23</sup> Due to the resorptive stage and posteruption age of the patient in the second case, extraction of the tooth was not recommended.

The third case demonstrated an embedded tooth which was interpreted radiographically as a maxillary right primary second molar. Since this patient had other missing teeth, it was difficult to determine whether the embedded primary molar was related to the overall development process in this patient. In humans, genes *MSX-1* and *PAX-9* have been shown to be associated with selective tooth agenesis.<sup>24</sup> It can

also be suspected that the roots of the embedded primary molar had undergone physiological resorption. Gibilisco<sup>25</sup> states that "almost all primary teeth that do not erupt undergo marked resorption". One could also suspect that the root agenesis resulted secondarily due to the failure of eruption. Agenesis of primary molar root has not been reported in the literature except for natal teeth.<sup>26</sup>

Incidentally, involved teeth in this series were located near the floor of the maxillary sinus. A review of the literature did not reveal any study regarding the effect of pneumatization of the maxillary sinus on the developing roots of maxillary premolars. The maxillary sinus begins as a shallow groove on the lateral wall of the nose during the sixteenth week of intrauterine life. The hard palate is located in close proximity to the floor of the orbit in infants, and the size of the sinus approximates the size of a small pea at this time.<sup>27</sup> The descending palate carries the alveolar process with the developing teeth downward and forward away from the passively enlarging sinus.<sup>28</sup> Initiation and mineralization of the second premolar occurs during the second year after birth. Dental crypts are carried away from the sinus with the growth of a maxillary alveolar process in a vertical plane. During the ninth year, the maxillary sinus attains an appreciable size in vertical dimension.<sup>29</sup>

It can be argued that the floor of the sinus might have inhibited the root formation, but it should be stressed that root genesis is not an active growth process in an apical direction.<sup>22</sup> Therefore, the location of the floor of the maxillary sinus should not have affected the root genesis and status of eruption in this series. Surgical intervention for sinus afflictions have been reported to adversely affect the root formation of teeth in the vicinity,<sup>30</sup> but such was not the case in this series. Yamazaki et al<sup>31</sup> reported a case of a maxillary odontogenic keratocyst with extension into the maxillary sinus enveloping an impacted rootless second premolar in a 29-year-old Japanese female.

Certain developmental anomalies are known to cause aberrations of root genesis. Rootless teeth are seen in dentin dysplasia type I, but the condition is generalized in nature. The teeth are characterized by pulpal obliteration, normal eruption, multiple periapical radiolucencies, and early exfoliation.<sup>5</sup> Roots could be adversely affected in localized odontodysplasia, but the condition demonstrates lack of qualitative and quantitative healthy dental tissues.<sup>32</sup> The thickness of enamel and dentin appeared to be normal in this series.

The exact mechanism behind tooth eruption and root genesis is unknown. Both the enamel organ and dental follicle play a significant role in initiating and organizing the eruption mechanism. If individual steps fail to synchronize, complications in eruption can arise. In the presented series, cessation of eruption and root formation could be due to some unknown aberration of the dental follicle or enamel organ. However, due to the multitude of factors involved in tooth eruption, it is difficult to determine the exact cause of the failure of eruption of these teeth.

## References

1. ElNesr NM, Avery JK. Development of teeth: Root and supporting structures. In: Avery JK, Steele PF, eds. *Oral Development and Histology*. 2nd ed. New York: Thieme Medical Pub Inc; 1994:94-108.
2. Marks SC, Jr, Schroeder HE. Tooth eruption: Theories and facts. *The Anatomical Record*. 1996;245:374-393.
3. Smith BH. 'Schultz's rule' and the evolution of tooth emergence and replacement patterns in primates and ungulates. In: Teaford M, Smith MM, Ferguson MWJ, eds. *Development, Function and Evolution of Teeth*. 1st ed. Cambridge, UK: Cambridge University Press; 2000:212.
4. Minicucci EM, Lopes LF, Crocci AJ. Dental abnormalities in children after chemotherapy treatment for acute lymphoid leukemia. *Leukemia Research*. 2003;27:45-50.
5. Olsson A, Matsson L, Blomquist HK, Larsson A, Sjodin B. Hypophosphatasia affecting the permanent dentition. *J Oral Pathol*. 1996;25:343-347.
6. Ravn JJ, Nielsen HG. A longitudinal radiographic study of the mineralization of second premolars. *Scand J Dent Res*. 1977;85:232-236.
7. Cochrane SM, Clark JR, Hunt NP. Late developing supernumerary teeth in the mandible. *Br J Orthod*. 1997;24:293-296.
8. Held M, Alexander SA. Multiple localized root agenesis. *J Dent Child*. 1985;52:45-47.
9. Bosshardt DD, Schroeder HE. Cementogenesis reviewed: A comparison between human premolars and rodent molars. *Anat Rec*. 1996;245:267-292.
10. Cahill DR. The histology and rate of tooth eruption with and without temporary impaction in the dog. *Anat Rec*. 1970;166:225-238.
11. Gregg JM. Immobilization of the erupting molar in the syrian hamster. *J Dent Res*. 1965;44:1219-1226.
12. Iizuka T, Cielinski M, Aukerman SL, Marks SC, Jr. The effects of colony-stimulating factor-1 on tooth eruption in the toothless (osteopetrotic) rat in relation to the critical periods for bone resorption during tooth eruption. *Arch Oral Biol*. 1992;37:629-636.
13. Paulsen HU, Shi XQ, Welander U, Huggare J, Scheutz F. Eruption pattern of autotransplanted premolars visualized by radiographic color-coding. *Am J Orthod Dentofacial Orthop*. 2001;119:338-345.
14. Wise GE, Frazier-Bowers S, D'Souza RN. Cellular, molecular, and genetic determinants of tooth eruption. *Crit Rev Oral Biol Med*. 2002;13:323-335.
15. Yamashiro T, Tummers M, Thesleff I. Expression of bone morphogenetic proteins and MSX genes during root formation. *J Dent Res*. 2003;82:172-176.
16. Lezot F, Davideau JL, Thomas B, Sharpe P, Forest N, Berdal A. Epithelial homeogene expression and cementogenesis. *J Histochem Cytochem*. 2000;48:277-283.
17. Steele-Perkins G, Butz KB, Lyons GE, Zeichner-David M, Kim HJ, Cho MI, Gronostajski RM. Essential role for NFI-C/CTF transcription-replication factor in tooth root development. *Mol Cell Biol*. 2003;23:1075-1084.
18. Gorski JP, Brown KM, Marvin M, Wise GF, Marks SC, Jr. Production and characterization of antibodies against DF-95, a dental follicle protein selectively degraded at onset of tooth eruption. In: Davidovitch Z, ed. *Proceedings of the International Conference on Biological Mechanisms of Tooth Eruption, Resorption and Replacement by Implants*. Birmingham, Ala: EBSCO Press; 1994:397-406.
19. Bsoul S, Terezhalmay G, Abboud H, Woodruff K, Abboud SL. PDGF BB and bFGF stimulate DNA synthesis and upregulate CSF-1 and MCP-1 gene expression in dental follicle cells. *Arch Oral Biol*. 2003;48:459-465.
20. Ten Cate AR. Physiologic tooth movement: Eruption and shedding. In: Ten Cate R. *Oral Histology Development, Structure, and Function*. 5th ed. St. Louis: Mosby-Year Book, Inc; 1998:289-314.
21. Worth HM. Developmental variations and abnormalities. In: *Principles and Practice of Oral Radiologic Interpretation*. Chicago: Year Book Medical Pub, Inc; 1963:88-89.
22. Marks SC, Jr. The basic and applied biology of tooth eruption. *Connect Tissue Res*. 1995;32:149-157.
23. Worth HM. Acquired abnormalities of the teeth. In: *Principles and Practice of Oral Radiologic Interpretation*. Chicago: Year Book Medical Pub, Inc; 1963:171-173.
24. Mostowska A, Kobiela A, Biedziak B, Trzeciak WH. Novel mutation in the paired box sequence of PAX9 gene in a sporadic form of oligodontia. *Eur J Oral Sci*. 2003;111:272-276.
25. Gibilisco JA. Resorptive processes. In: Gibilisco JA, ed. *Stafne's Oral Radiographic Diagnosis*. 5th ed. Philadelphia: WB Saunders Co; 1985:125-139.
26. Friend GW, Mincer HH, Carruth KR, Jones JE. Natal primary molar: Case report. *Pediatr Dent*. 1991;13:173-175.
27. Ten Cate AR. Embryology of the head, face, and oral cavity. In: *Oral Histology Development, Structure, and Function*. 5th ed. St. Louis: Mosby-Year Book, Inc; 1998:24-49.
28. Enlow DH, Dale JG. Childhood facial growth and development. In: Ten Cate R. *Oral Histology Development, Structure, and Function*. 5th ed. St. Louis: Mosby-Year Book, Inc; 1998:424-471.
29. Ruprecht A. Paranasal sinuses. In: White S, Pharoah M. *Oral Radiology Principles and Interpretation*. 4th ed. St. Louis: Mosby-Year Book, Inc; 2000:529-551.
30. Seow WK. Root agenesis associated with chronic infection and traumatic curettage of the maxillary sinus. *Pediatr Dent*. 1994;16:227-230.
31. Yamazaki M, Cheng J, Nomura T, Saito C, Hayashi T, Saku T. Maxillary odontogenic keratocyst with respiratory epithelium: A case report. *J Oral Pathol*. 2003;32:496-498.
32. Courson F, Bdeoui F, Danan M, Degrange M, Gogly B. Regional odontodysplasia: Expression of matrix metalloproteinases and their natural inhibitors. *Oral Surg Oral Med Oral Pathol*. 2003;95:60-66.