

## Partial pulpotomy in a traumatized primary incisor with pulp exposure: case report

Diana Ram, Dr. Odontol. Gideon Holan, DMD

### Abstract

*Crown fracture with pulp exposure in primary incisors is a rare condition. Despite the fact that the vitality of the pulp can be preserved, such teeth are usually extracted due to lack of patient cooperation. This article reports a successful conservative treatment of a fractured primary incisors with pulp exposure and undeveloped root. The child was sedated with midazolam and nitrous oxide, and partial pulpotomy was performed using calcium hydroxide. Follow-up radiographs 21 weeks later revealed closure of the apex and apposition of a dentin bridge close to the amputation site. (Pediatr Dent 16:46-48, 1994)*

### Introduction

The prevalence of crown fracture with pulp exposure (complicated crown fracture) in primary incisors varies between 0 and 3.2% of traumatized teeth.<sup>1-5</sup> It occurs because of the large size of the pulp chamber.<sup>6</sup> Due to its infrequent occurrence it has gained little attention in the literature.<sup>7</sup> Most researchers agree that efforts should be made to preserve the vitality of the pulp by pulp capping or pulpotomy. This is more important when the pulp was exposed before the apex was closed.<sup>8,9</sup> This procedure should leave the radicular pulp vital, allowing root development and apical closure. However, in many cases the treatment of choice suggested by many authors is extraction due to lack of child cooperation.<sup>6,10-13</sup>

In permanent teeth, partial pulpotomy with calcium hydroxide may be the treatment of choice following crown fracture with pulp exposure.<sup>14,15</sup> In this technique, 2 mm of pulp close to the exposure site is removed and the amputated pulp is covered with calcium hydroxide. After 3-12 weeks, a dentin bridge is observed, separating the exposure site from the remaining pulp. The exposure size and the time interval between the accident and the treatment were not found to be critical for healing of the primarily healthy pulp.<sup>14</sup>

No previous report of calcium hydroxide use for partial pulpotomy in primary teeth was found in the literature.

The purpose of this report is to present a conservative approach to the treatment of complicated crown fracture in a young primary incisor.

### Case report

A healthy 14-month-old male infant was examined at the emergency clinic of the Department of Pediatric Dentistry at the Hadassah Faculty of Dental Medicine in Jerusalem. The parents reported that the child fell at home the day before. They said there was no previous trauma to the teeth.

Clinical examination revealed that the only teeth erupted were the maxillary and mandibular incisors. Fractures of the enamel and dentin were observed in both maxillary primary central incisors with exposure of the pulp of the right incisor (Fig 1). The teeth were caries-free and neither mobile nor discolored. Sensitivity to percussion could not be determined (due to lack of cooperation). The oral soft tissue was not injured.

A periapical radiograph (Fig 2) showed four maxillary primary incisors with wide pulp chambers, incompletely formed roots, thin dentinal walls, and open apices. The permanent successors were in early stages of coronal calcification.

Since the child had been NPO for several hours, it was decided to treat the tooth without delay. After parental consent, the child was premedicated with 2 mg (0.2 mg/kg body weight) of midazolam (Dormicum—F. Hoffman La Roche Ltd. Basel, Switzerland), which was dripped gently into the nostrils. Ten minutes after administering the drug, he was restrained in a Papoose Board®, (Olympic Medical Group, Seattle, WA) and nitrous oxide-oxygen inhalation (2L:2L) was

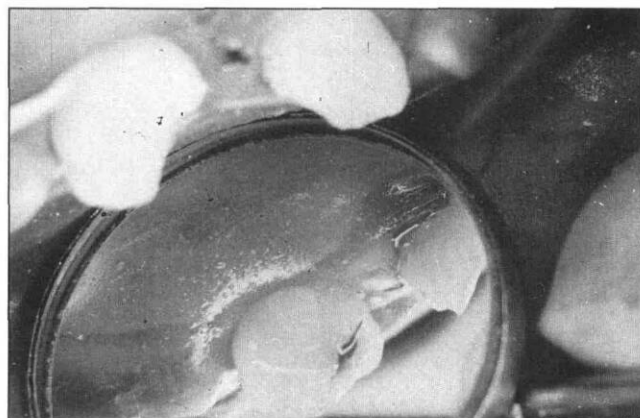
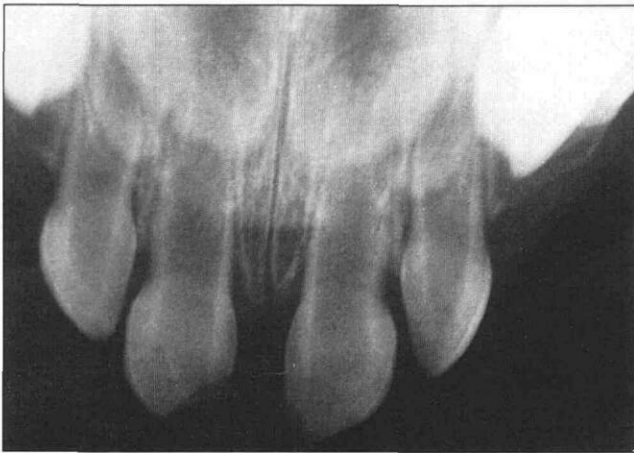

Fig 1. Clinical mirror view of the fractured incisors. Note the exposed pulp of the right maxillary primary central incisor.



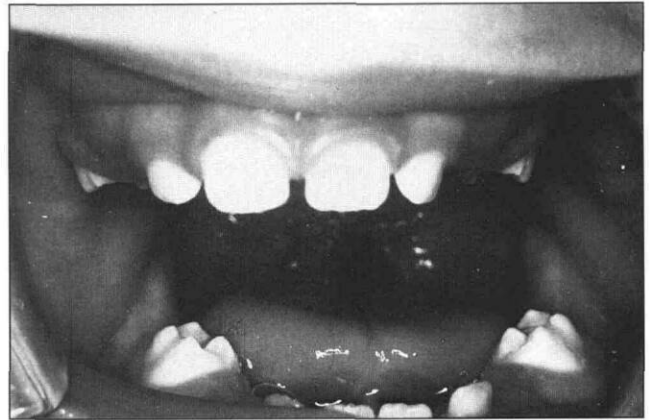
**Fig 2.** Periapical radiograph of the maxillary primary incisors less than 24 hr after injury. Note the wide pulp chambers, incompletely formed roots, thin dentinal walls, and open apices.

started and continued during the dental procedure. The child's vital signs were monitored during the whole procedure using a pulse oximeter. The child was fully cooperative during the dental procedure with no disruptive behavior. Local anesthesia was achieved by infiltrating 2% lidocaine (1 cc) with epinephrine 1:100,000 and the teeth were isolated with a rubber dam. Partial pulpotomy (Cvek technique) was performed on the right central incisor. A #330 tungsten bur was used to amputate 2 mm of the pulp close to the exposure site. Continuous rinsing of the amputated pulp with sterile saline allowed hemostasis without blood clot formation. Calcium hydroxide paste (Calxyl, Dental preparation. Otto & Co. Frankfurt/Main, Germany) was used as dressing for the pulp, covered by IRM (Bayer—Leverkussen, Germany). The remaining exposed dentin was lined with Dycal (L.D. Caulk, Milford, DE). Both teeth were restored using Vitrebond (#7510 3M Dental Products Division, St. Paul, MN) and Durafill (Kulzer & Co. GmbH, Wehrheim, Germany) (Fig 3).

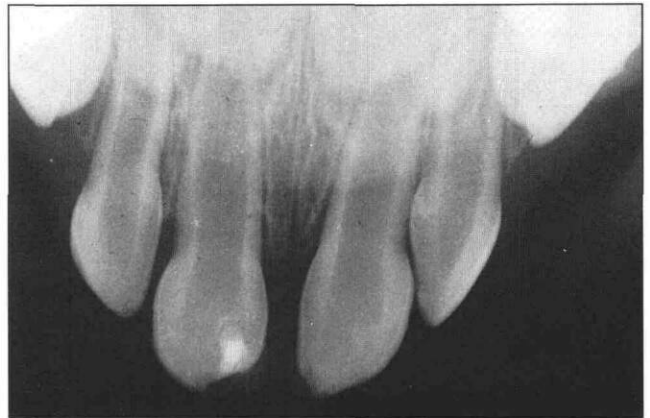The parents were provided with postoperative and oral hygiene instructions and the child was discharged when fully conscious. Parents were asked to return for followup after 6 weeks if the child was asymptomatic, or immediately if they observed any untoward development.

The six-week period was uneventful, and, at the recall examination, the child was absolutely cooperative. Clinical examination of the traumatized teeth revealed no excessive mobility, no discoloration, and no sensitivity to percussion. The surrounding soft tissues appeared normal. The periapical radiograph did not present any further development of the roots, but the beginning of a dentinal bridge could be seen in close proximity to the exposure site.

Twenty-one weeks after the treatment, the central incisors were not sensitive to percussion and had no



**Fig 3.** Clinical view of the restored maxillary primary central incisors.



**Fig 4.** Periapical radiograph of the maxillary primary incisors three months after treatment. Notice the dentinal bridge, width of the dentin walls of the roots and development of both incisors.

discoloration or excessive mobility. The soft tissue adjacent to the traumatized teeth was healthy.

The periapical radiograph (Fig 4) showed a clear dentinal bridge apical to the calcium hydroxide and continuing root development.

## Discussion

Preserving dental arch integrity is a basic principle of dental treatment, which is no less applicable when dealing with the anterior segment of the primary dentition. Several clinicians advocate extracting primary incisors with complicated crown fractures, because it is difficult to achieve the child's cooperation.<sup>6, 10-13</sup> However, controlling the child's behavior using conscious sedation techniques is an integral part of modern pediatric dentistry. Moreover, extracting the traumatized incisor does not bypass the need to address the child's behavior and often requires the same considerations as a conservative treatment. The restorability of the tooth, length of time elapsed since the pulp has been exposed, root length, and vitality of the pulp tissue should be considered before determining the treatment for the fractured primary incisors with exposed pulp.<sup>16</sup>

Several alternative treatments for teeth with a complicated crown fracture have been suggested. McTigue<sup>17</sup> advocated a formocresol pulpotomy for teeth in which the injury has exposed the pulp within the last several hours and the pulp in the canal is judged to be vital. Formocresol is the suitable medication for fully developed roots, but may not allow closure of the apex in young and undeveloped incisors. Hawes<sup>8</sup> and Harrison<sup>9</sup> advocated calcium hydroxide cervical pulpotomy in case the pulp was exposed before closure of the apex. However, this procedure seems impractical in immature primary incisors due to the extremely thin dentin walls at the cervical region of the teeth. A complete root canal treatment could be another choice, but the vital pulp, thin dentinal walls of the root, and the open apex in this case were contraindications.

Calcium hydroxide is believed to lead to internal resorption when used for pulpotomy in primary teeth with carious exposure.<sup>18</sup> This is probably due to an inflammatory response present in the radicular pulp. Cvek<sup>19</sup> demonstrated inflammatory changes reaching the depth of 2 mm in monkeys' incisors following mechanical exposure of the pulp. Since calcium hydroxide failed to induce the formation of a dentin barrier under an exposed and inflamed pulp,<sup>20</sup> using calcium hydroxide in primary teeth was recommended only for small mechanical or traumatic exposures when conditions for a favorable response are optimal.<sup>21</sup>

Cvek<sup>14,19</sup> suggested the partial pulpotomy in which excision of 1–2 mm of the pulp tissue adjacent the exposure site results in removing the infected part of the pulp, allowing application of calcium hydroxide on the healthy tissue. In addition, a better control of the surgical wound and retention of the sealing material are achieved. Cvek<sup>14</sup> reported 96% success of partial pulpotomy in permanent teeth, and found that success was not dependent on the size of the exposure or the time since the injury.

The present report describes a fractured young primary incisor with pulp exposure treated with a procedure performed, to date, only on permanent teeth. Radiographic evidence observed after 21 weeks of the formation of a dentin bridge and continued root development with no clinical and radiographic pathology is an early sign of success. Signs of a calcified tissue close to the calcium hydroxide layer, could be seen in the radiograph exposed as early as six weeks after treatment. More cases with longer follow-up periods should be reported and studies conducted before assessing the success rate of partial pulpotomy in traumatized primary incisors. However, the present report should encourage other clinicians to try a conservative approach in similar conditions.

Dr. Ram is senior resident and Dr. Holan is lecturer, Department of Pediatric Dentistry, The Hebrew University—Hadassah Faculty of Dental Medicine, Founded by the Alpha Omega Fraternity, Jerusalem, Israel.

1. Andreasen JO, Ravn JJ: Epidemiology of traumatic dental injuries to primary and permanent teeth in a Danish population sample. *Int J Oral Surg* 1:235–39, 1972.
2. Zadik D: A survey of traumatized primary anterior teeth in Jerusalem preschool children. *Community Dent Oral Epidemiol* 4:149–51, 1976.
3. Garcia-Godoy F, Garcia-Godoy F, Olivo M: Injuries to primary and permanent teeth treated in a private paedodontic practice. *J Can Dent Assoc* 6:281–84, 1979.
4. Ferguson FS, Ripa LW: Prevalence and type of traumatic injuries to the anterior teeth of preschool children. *J Pedod* 4:3–8, 1979.
5. Garcia-Godoy F, Garcia-Godoy F, Garcia-Godoy FM: Primary teeth traumatic injuries at a private pediatric dental center. *Endod Dent Traumatol* 3:126–29, 1987.
6. Bennet DT: Traumatized anterior teeth. *Br Dent J* 116:52–5, 1964.
7. Hargreaves JA, Craig JW: *The Management of Traumatized Anterior Teeth of Children*. London: E & S Livingstone, 1970, pp 113–25.
8. Hawes RR: Traumatized primary teeth. *Dent Clin North Am* 10:391–404 1966.
9. Harrison LM Jr: Treatment of traumatized primary anterior teeth. *J Louis Dent Assoc* 26:12–7, 1968.
10. Andreasen JO: *Traumatic Injuries of the Teeth*, 2nd Ed. Copenhagen: Munksgaard, 1981, pp 88.
11. Mackie IC, Warren VN: Dental trauma: 1. General aspects of management, and trauma to the primary dentition. *Dent Update* 15:155–56, 158–59, 1988.
12. Kenny DJ, Yacobi R: Management of trauma to the primary dentition Ontario Dent 65:27–9, 1988.
13. Johnson R: Traumatic dental injuries in children. Part I: Evaluation of traumatic dental injuries and treatment of injuries to primary teeth. *Update Pediatr Dent* 2:1–4, 6–7, 1989.
14. Cvek M: A clinical report on partial pulpotomy and capping with calcium hydroxide in permanent incisors with complicated crown fracture. *J Endod* 4:232–37, 1978.
15. Klein H, Fuks A, Eidelman E, Chosack A: Partial pulpotomy following complicated crown fracture in permanent incisors: A clinical and radiographical study. *J Pedod* 9:142–49, 1985.
16. Wright GZ, Friedman CM: Management of dental trauma. In *Textbook of Pediatric Dentistry*. 2nd Ed. Braham RL, Morris ME, EDS. Baltimore: Williams & Wilkins, 1985, pp 565–92.
17. McTigue DJ: Introduction to dental trauma: managing traumatic injuries in the primary dentition. In *Pediatric Dentistry: Infancy Through Adolescence*. Pinkham JR, ED. Philadelphia: WB Saunders, pp 171–82, 1988.
18. Via W: Evaluation of deciduous molars treated by pulpotomy and calcium hydroxide. *J Am Dent Assoc* 50:34–43, 1955.
19. Cvek M, Cleaton-Jones PE, Austin JC, Andreasen JO: Pulp reactions to exposure after experimental crown fractures or grinding in adult monkeys. *J Endod* 8:391–97, 1982.
20. Tronstad L, Mjor IA: Capping of the inflamed pulp. *Oral Surg Oral Med Oral Pathol* 34:477–85, 1972.
21. Fuks A, Eidelman E: Pulp therapy in the primary dentition. *Curr Opin Dent* 1:556–63, 1991.