

Complications occurring resultant to dens invaginatus: case report

George M. Rakes, BS, DDS, MS Anne S. Aiello, BS, DMD

Curtis G. Kuster, BS, DDS, MS Wayne A. Labart, BS, DDS, MS

Abstract

This case report describes the anomalous development of maxillary permanent lateral incisors in a seven-year-old white male. The maxillary right permanent lateral incisor radiographically demonstrated anomalous development characteristic of dens invaginatus. A coincidental finding of a microdontic maxillary left permanent lateral incisor also was observed at this time. This patient presented with a cellulitis of odontogenic origin in the area of the dens invaginatus. Upon resolution of the cellulitis and removal of the dens invaginatus, microscopic examination of the tooth and surrounding soft tissue fragments revealed the pathway of the infection to be periodontal in nature.

Dens invaginatus and microdontia are conditions which most commonly affect the morphology of maxillary permanent lateral incisors. Although often observed, these anomalous teeth present a challenge to the dental practitioner. Morphologically anomalous teeth may cause esthetic, orthodontic, and prosthetic problems. In addition, due to the caries susceptibility of teeth demonstrating dens invaginatus, acute odontogenic infection is a possible sequela. This article illustrates a case in which a child demonstrated both a microdontic maxillary left permanent lateral incisor and an erupting malformed maxillary right permanent lateral incisor indicative of dens invaginatus. The many problems associated with the presence of such teeth are discussed.

Literature Review

The literature is replete with descriptions of the dental anomaly known as dens invaginatus (dens in dente, dilated composite odontome) dating to 1856. Attempts to categorize these teeth have resulted in various classifications. Dens invaginatus has been described as occurring in three forms (Hicks and Flaitz 1985):

Type 1 — an enamel-lined cavity confined within the crown of the tooth, not extending beyond the cementoenamel junction

Type 2 — an enamel-lined cavity which invades the root, but remains within its confines (There may or may not be communication with the dental pulp.)

Type 3 — invagination extends beyond the CEJ and perforates apically or laterally at a foramen (There is no communication with the pulp.).

The abnormal morphology of these teeth often produces infections of odontogenic origin. The caries-prone invagination of tooth structure which may communicate with the dental pulp often produces necrosis with a resultant periapical infection. Without early resolution of the infection a cellulitis may occur. It is thus important that an early diagnosis of the presence of such teeth be made in order to avoid serious complications.¹

The incidence of dens invaginatus has been reported to occur more frequently in the maxillary dentition. The frequency of occurrence in descending order is: (1) lateral incisor; (2) central incisor; (3) premolar; and (4) molar. Dens invaginatus may occur in 6.6-9.7% of maxillary incisors. Bilateral involvement often is reported.²

Microdontia is a condition in which either the crown or root of a tooth is shorter or smaller than that observed by the general population. Microdontia has been seen localized, most often affecting the maxillary lateral incisor and third molar. Although these teeth are also frequently congenitally missing, other teeth also known to be congenitally missing (maxillary and mandibular second premolars) rarely exhibit microdontia. Generalized microdontia, a condition affecting the entire dentition, has been associated with defects such as pituitary

¹ Gustafson and Sunberg 1950; Beynon 1982; Bohn 1984.

² Amos 1955; Shafer et al. 1974; Augspurger and Brandenbura 1978; Conklin 1978; Gotoh et al. 1979.

dwarfism, congenital heart disease, and Down's syndrome (Trisomy 21). Since microdontic teeth are normal in structure, treatment considerations are based upon esthetic and orthodontic status (Shafer et al. 1974).

Case Report

A seven-year-old white male was referred by his private dentist to the pediatric dentistry department at Creighton University School of Dentistry for treatment of a cellulitis in the area of the maxillary right permanent lateral incisor. The child had a normal medical history with no complicating illnesses and his family history was found to be noncontributory. On physical examination he appeared to be of appropriate stature and weight and in no apparent distress. His oral temperature was slightly elevated (99.8° F) and a diffuse swelling lateral to the ala of the nose was observable. The parent reported that the swelling in this area began four days prior to the examination and at that time the private dentist placed the child on a regimen of erythromycin 250 mg — one tablet every six hours.

Intraorally, the cusp tip of the maxillary right permanent lateral incisor was visible and a slight enamel defect could be probed. The vestibule in this area was swollen, tender to palpation, and somewhat fluctuant. Radiographic evaluation revealed an abnormally shaped maxillary right permanent lateral incisor and a microdontic maxillary left permanent lateral incisor (Figs 1, 2). It was thought that the cellulitis was resultant to the necrosis of the morphologically abnormal maxillary right permanent lateral incisor which clinically resembled a dens invaginatus. After conferring with the parent, the fluctuancy in the vestibule overlaying the maxillary right permanent lateral incisor was incised and drainage was established. The child's antibiotic regimen was changed to penicillin-V 250 mg (one tablet every six hours) because no allergy to penicillin could be ascertained and penicillin was considered to be the drug of choice for the oral infection. A follow-up appointment was scheduled in three days to evaluate the status of the infection.

Upon follow-up examination, the child's temperature had returned to normal (98.6° F) and all intraoral and extraoral swelling had resolved. Following a discussion of treatment alternatives with the parent, it was agreed that the offending tooth should

be removed. After anesthetizing the area with Lidocaine 1:100,000, a full-thickness mucoperiosteal flap was elevated from the distal of the maxillary left permanent central incisor to the mesial of the primary right first molar. To facilitate the extraction of the dens invaginatus, the primary right canine was removed, as well as a small amount of overlying alveolar bone. After completing the surgical procedure, interrupted sutures were placed, and both the tooth and soft tissue fragments were sent for microscopic evaluation. The parent was instructed to continue the antibiotic regime. A postsurgical appointment was scheduled to evaluate healing and to remove sutures.

Both the anomalous tooth (Fig 1) and several fragments of soft tissue were presented for histopathologic examination. The residual soft tissues removed from the tooth were processed and stained with hematoxylin and eosin. Microscopic examination of the soft tissue revealed fibrous connective tissue partially edged by thin, proliferating, nonkeratinized stratified squamous epithelium. Present within both the epithelium and connective tissue was a diffuse, focally dense, inflammatory infiltrate of lymphocytes, plasma cells, and histiocytes characteristic of a chronic inflammatory process (Fig 3).

The anomalous tooth was serially cross sectioned utilizing a diamond wheel. These sections then were mounted for microscopic evaluation (Fig 4). Coronally, the tooth demonstrated layers of enamel surrounding an infrastructural void leading to an enamel defect. The cervical area of this tooth revealed a thin extension of pulp surrounded by dentin and varying types of cemen-

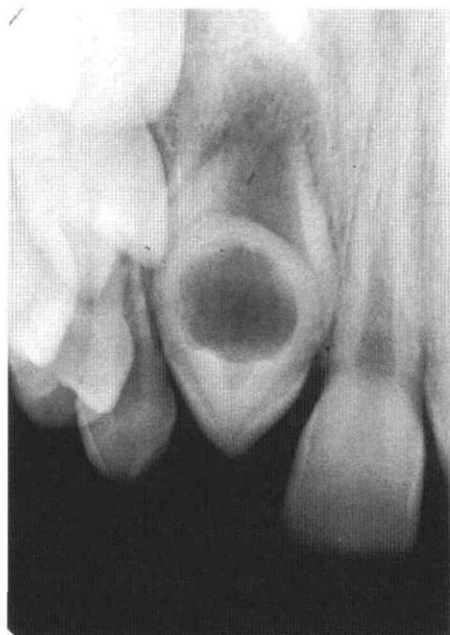


FIG 1. Periapical radiograph of maxillary right permanent lateral incisor (dens invaginatus).

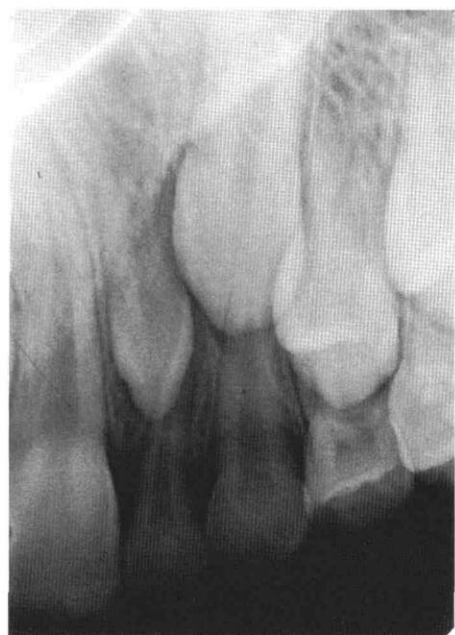

FIG 2. Periapical radiograph of pegged maxillary left permanent lateral incisor.



FIG 3. Histopathologic section of residual soft tissue fragments removed from maxillary right permanent lateral incisor (dens invaginatus). The scale bar indicates 20 μ m.

tum. At the apical end of the tooth, well organized pulpal tissue was visible and, as in normal tooth morphology, it was surrounded by dentin and cementum. These findings confirm the clinical impression of a Type II dens invaginatus.

After performing a detailed examination of all the serial sections, no communication among the enamel defect, the infrastructural void, and the well organized pulp tissue could be demonstrated. It is thus presumed that the cause of the infection was resultant to the spread of microorganisms through a poorly defined epithelial attachment and periodontal ligament. Therefore, the etiology of this infection is believed to have originated via the periodontium and not through the enamel defect which has been reported often.

Discussion

The prevalence and consequences of malformed teeth underscore the necessity for an early radiographic

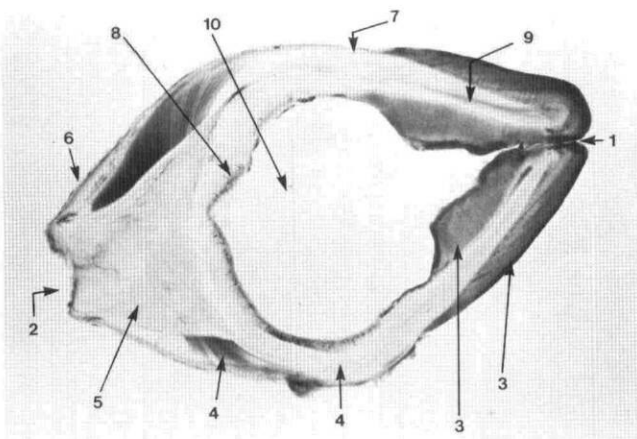


FIG 4. Serial cross section of maxillary right permanent lateral incisor (dens invaginatus): (1) incisal enamel defect; (2) foramen; (3) enamel; (4) dentin; (5) pulpal tissue; (6) cellular cementum; (7) acellular cementum; (8) intermediate cementum; (9) dead track; (10) infrastructural void.

survey. Upon diagnosis of such teeth, the practitioner should at that time evaluate the prognosis of the tooth in terms of long-term stability. Such factors including restorability, periodontal status, and the patient's overall orthodontic condition must be taken into account. If extraction of the tooth is indicated, it may be beneficial to perform the extraction of the tooth prior to eruption to avoid the sequelae presented in this case.

The early removal of such teeth compels one to consider long-term orthodontic treatment planning at an early age. In the presented case there are numerous potential resolutions. In cases with significant arch length to tooth size discrepancies, one must anticipate the probability of a midline shift. In order to prevent such a shift from occurring, the removal of the contralateral primary canine should be undertaken. In addition, in crowded cases, one may choose to extract the remaining peg lateral incisor, allowing for the symmetrical forward migration of the posterior segments. Eventually, the maxillary permanent canines would be utilized as replacements for the missing maxillary permanent lateral incisors.

The patient in this case report exhibited a Class I, uncrowded dentition, indicating that an anterior midline shift with resultant arch length loss would be unlikely, and thus the contralateral primary canine was not removed. A periodic observation schedule with orthodontic treatment to align the dentition for the eventual prosthetic replacement of the missing lateral incisor, combined with the cosmetic restoration of the pegged lateral incisor, would be an effective treatment plan.

There are numerous potential problems to resolve when a malformed anterior tooth is discovered. The key to treatment is an early diagnosis coupled with a treatment plan of continuity and long-term objectives.

Conclusion

This report described a case in which a Type II dens invaginatus produced a cellulitis in a seven-year-old white male. Also present was a contralateral microdontic permanent lateral incisor. Through histopathologic section it was illustrated that the source of the infection was periodontal in nature and not secondary to pulpal involvement. Management of the infection and long-term possible sequelae were detailed.

Drs. Rakes, Aiello, and Labart are assistant professors, pediatric dentistry and orthodontics, Creighton University; and Dr. Kuster is an associate professor, University of Nebraska, Lincoln. Reprint requests should be sent to: Dr. George M. Rakes, Dept. of Pediatric Dentistry and Orthodontics, Creighton University, Boyne School of Dentistry, Omaha, NE 68178.

Amos ER: Incidence of the small dens in dente. *J Am Dent Assoc* 51:31-33, 1955.

Augsburger RA, Brandenbura J: Bilateral dens invaginatus with associated radicular cysts. *Oral Surg* 46:260-64, 1978.

Beynon AD: Developing dens invaginatus (dens in dente). *A quan-*

- titative microradiographic study and a reconsideration of the histogenesis of this condition. Br Dent J 153:255-60, 1982.
- Bohn A: Dens in dente. Acta Odontol Scand 8:55-80, 1948.
- Conklin WW: Bilateral dens in dente in the mandibular incisor region. Oral Surg 45:905-8, 1978.
- Gotoh T, Kawahara K, Imai K et al.: Clinical and radiographic study of dens invaginatus. Oral Surg 48:88-91, 1979.
- Gustafson G, Sunberg S: Dens in dente. Br Dent J 88:83-88, 111-22, 144-46, 1950.
- Hicks MJ, Flaitz CM: Dens invaginatus with partial coronal agenesis: report of case. J Dent Child 52:217-19, 1985.
- Shafer WG, Hine MK, Levy BM: A Textbook of Oral Pathology, 3rd ed. Philadelphia; WB Saunders Co, 1974 pp 34-35, 38-39.
-

Pediatric AIDS

U.S. Surgeon General C. Everett Koop, speaking at a conference on pediatric AIDS, announced the following.

1. A new CDC-approved definition of AIDS cases will be published soon
2. A pediatric AIDS registry has been developed by Dr. Virginia Anderson at the Armed Forces Institute of Pathology
3. Child welfare agencies will be educated about AIDS and treatment protocols
4. Child abuse is emerging as one means of transmission
5. His support for a conference statement urging better detection methods in the newborn
6. His recommendation *against* discouraging breast feeding in developing countries at this time
7. An immediate need for more intensified programs for IV drug users
8. An effort to bring together representatives from the office of Human Development Services and the Health Care Financing Administration to discuss a network of "nurturing homes" to ensure access to comprehensive services for children with AIDS
9. A plan to bring together representatives from public and private sector organizations to discuss possible partnerships that will guarantee the availability of and access to such services
10. The need for better minority educational efforts
11. The need to develop a standard glossary of terms for use by media, community organizations, and the dental and medical professions.