

A simple method for treating ectopic eruption of the first permanent molar

Franklin Pulver, DDS, MS, FRCD(C)
William Croft, DDS, DIP. PAEDO.

Abstract

A simple method of treating an ectopically erupting first permanent molar is presented which utilizes both a molar band with helical finger springs cemented to a second primary molar, and a curved tag of composite resin which is acid-etched to the occlusal surface of the affected first permanent molar. When activated and placed into proper position, the springs act at right angles to the long axis of the first permanent molar, enabling it to assume a normal path of eruption into occlusion with a minimal number of adjustments.

Various authors¹⁻³ have concluded that an atypical downward and mesial inclination of the maxillary first permanent molar may lead to ectopic eruption. Pulver¹ and Young⁴ both have reported an incidence of this condition in the population of about 3%. Whenever ectopic eruption does occur, it results in varying degrees of premature atypical resorption of the second primary molar.

Numerous reports⁵⁻¹⁰ have appeared in the dental literature concerning the treatment of this condition, especially when it is evident that the first permanent molar will not erupt normally and when there has not been gross destruction of the roots of the second primary molar.

Recently Croll and Barney¹¹ recommended an appliance which consists of a band placed on a second primary molar with a single .032 mm stainless steel wire attachment. The free end was "fixed", by means of a composite resin, to the occlusal surface of an ectopically erupting first permanent molar.

This paper presents an alternative, simple, unilateral appliance which has been used effectively on several patients. This appliance combines many of the previous treatment modalities which have been described.

Case Report

The case of a 10-year-old Caucasian male patient who was successfully treated in the pedodontic clinic at the University of Toronto is presented. The preoperative radiograph is shown (Figure 1). We emphasize that the second primary molar must have sufficient root structure present for the stability of the appliance. Buccal and lingual helical springs of .018 mm wire are fabricated and soldered to a band which is adapted to the affected second primary molar. The free ends of the two springs engage in a concavity created within a composite resin tag which is added to the occlusal surface of the ectopically erupting first permanent molar (Figure 2). We recommend that an available-light rather than a chemically activated system be used for this procedure to allow increased working time if necessary. The two springs are activated initially by about one-third the mesiodistal diameter of the first permanent molar.

At the three-week recall the molar usually shows significant distal movement. If the permanent molar has not cleared the distal portion of the second primary molar completely, a further adjustment of one-third of the mesiodistal diameter of the permanent molar can be made

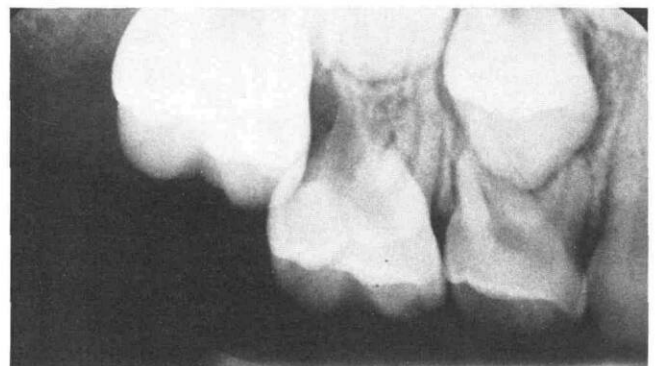


Figure 1. Radiograph of the ectopically erupting maxillary first permanent molar.

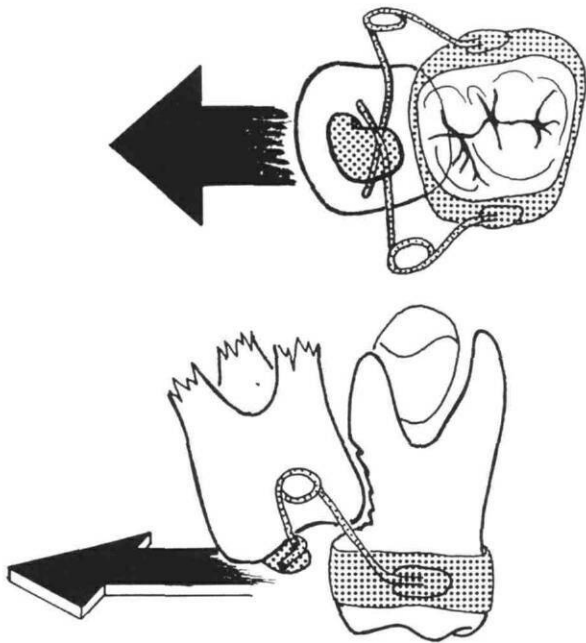


Figure 2. (Top) Occlusal view of appliance showing springs in place to distalize the first permanent molar. (Bottom) Buccal view of same.

easily in the mouth without removing the appliance. In the case presented, only two such appointments were necessary. When the first permanent molar has cleared the second primary molar completely, the appliance is removed (Figure 3).

The permanent molar now will continue to erupt in its normal path. The resin button is reduced to the height of the occlusal surface with a round carbide finishing bur. A residue of the resin can be left to afford future caries protection.

Discussion

During the past two decades many methods for treating this condition (except for that of Croll and Barney¹¹), have been tried with varying degrees of success. The new simple appliance described in this paper is a combination of many previous treatment techniques. It effectively corrects the ectopically erupting permanent molars and promotes a normal eruptive path. Since two springs are utilized, an even force from both the buccal and lingual sides of the tooth is directed at approximately right angles to the long axis of the ectopically erupting first perma-

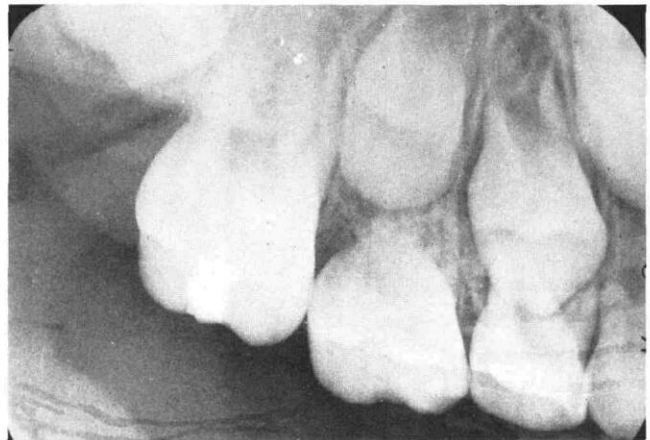

Figure 3. Radiograph of the corrected condition.

nent molar. Rotations of the affected permanent molar virtually can be eliminated. At the time of this study 15 patients had been treated successfully.

Dr. Pulver is assistant professor, Department of Pedodontics, University of Toronto, 124 Edward St., Toronto, Ontario, Canada M5G 1G6, and is in private pedodontic practice in Toronto. Dr. Croft is in private pedodontic practice in Nanaimo, British Columbia, Canada. Requests for reprints should be sent to Dr. Pulver.

1. Pulver, F. The etiology and prevalence of ectopic eruption of the maxillary first permanent molar. *J Dent Child* 35:138-46, 1968.
2. McDonald, R., Avery, D. *Dentistry for the Child and Adolescent*, 3rd ed. St. Louis: C.V. Mosby, 1978, pp 435-42.
3. Braden, R.E. Ectopic eruption of maxillary permanent first molars. *Dent Clin North Am* July:441-48, 1964.
4. Young, D.H. Ectopic eruption of the first permanent molar. *J Dent Child* 24:153-62, 1957.
5. Starkey, P. Infection following ectopic eruption of first permanent molars: case report. *J Dent Child* 28:327-30, 1961.
6. MacGregor, S. Ectopic Eruption, *Can Dent Assoc J* 11:211-15, 1945.
7. Levitas, T.C. A simple technique for correcting an ectopically erupting maxillary first permanent molar. *J Dent Child* 3:16-18, 1964.
8. Herman, E. The malposed first permanent molar. *NY State Dent J* 35:343-50, 1969.
9. Humphrey, W.P. A simple technique for correcting an ectopically erupting maxillary first permanent molar. *J Dent Child* 29:176-78, 1962.
10. Bayardo, R.E., Grandel, E.R., Milos, W. E. New concept in treatment of ectopically erupting maxillary first permanent molars. *J Dent Child* 46:214-18, 1979.
11. Croll, T., Barney, J. An acid-etch composite resin retained wire for correction of an ectopically erupting permanent first molar. *Pediatr Dent* 4:61-63, 1982.