

Radiographic anatomy of pulpal chambers of primary molars

Paninee Puddhikarant, DDS, MDS
Robert Rapp, DDS, MS, FRCD(C)

Abstract

The radiographic anatomy of the superior borders of pulpal chambers of primary molars was studied to clarify interpretation of superimposing cuspal images. First and second maxillary and mandibular molars were sectioned transaxially in the cervical region. The pulpal tissue was replaced by radiopaque resin before embedding the crowns in clear plastic blocks and obtaining buccolingual radiographs. The embedded crowns were then sectioned mesiodistally and radiographed buccolingually. The postsectional radiographic outlines of the pulpal chambers then were compared to presectional radiographs. An average radiographic image for each tooth type was constructed from a median of the aggregate tracings of the particular tooth. The radiographic appearance of each primary molar presented two to five overlapping pulpal horns, corresponding to their morphological anatomies. On dental radiographs, the lingual pulpal outline is sharper and more radiopaque than the buccal pulpal outline.

The majority of studies of pulp cavity morphology during the last 70 years have concentrated on the permanent teeth—only a few have described primary teeth. A literature review revealed a lack of studies of the radiographic anatomy of pulpal cavities of primary teeth. Many investigators¹⁻¹⁵ illustrated the relationship of the pulp cavity to the whole tooth using a variety of injected materials. Their findings were found, in general, to be similar and accurate. Barker et al.⁵⁻¹⁰ developed two techniques for injecting pulpal chambers and root canals. The first method used papain hydrochloride solution to macerate the pulp tissue, injection of a silicone elastomer, and then radiographic examination. The second method consisted of filling the pulpal chamber and root canals with red epoxy resin. While these two approaches illustrated the complexities of pulpal chamber and root canal anatomy of primary and permanent teeth, attention was not directed specifically toward the cuspal outlines of the pulpal chambers.

The purpose of this study, therefore, was to determine the radiographic anatomy of the occlusal border of pulpal chambers of primary molars in order to clarify interpretation of superimposing cuspal images, as well as to obtain an average radiographic image of each primary molar (Figure 1).

Methods and Materials

Twenty human primary teeth of children between the ages of 6 and 12 years ($\bar{x} = 8.5$) were selected for this study. These teeth were extracted for orthodontic purposes. When compared to average measurements,¹⁶ they were found to have at least one-third of the root structure intact. Inspection and radiographs revealed that they were either caries-free (75%) or had only incipient carious lesions (25%). On the basis of the above factors, four study groups were formed (Table 1).

Following storage in 50% glycerine in ethyl alcohol solution, each tooth was divided at the cervical region into apical and coronal portions. The crowns were then hydrolyzed in 1% papain hydrochloride solution¹⁷ at

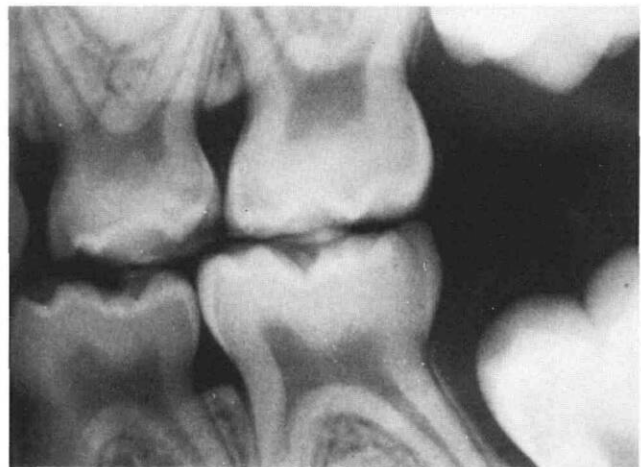


Figure 1. Radiograph of the occlusal borders of pulpal chambers of primary molars shows superimposing cuspal images. Clarification of these overlapping images would aid radiographic interpretation and planning of treatment.

Table 1. Type and Condition of Tooth Specimens

Study Group	N	Type of Specimen	N	Carious Lesions
I (Mandibular)	7	Right second primary molars	3	0
		Left second primary molars	4	
II (Mandibular)	5	Left first primary molars	2	4
		Right first primary molars	3	
III (Maxillary)	5	Right second primary molars	2	0
		Left second primary molars	3	
IV (Maxillary)	3	Right first primary molars	1	1
		Left first primary molars	2	

37°C for 48–72 hours¹⁸ to macerate the remaining pulpal tissue. Following washing in running water and dehydration in absolute alcohol, the crowns were warmed to remove any liquid residue.

A radiopaque material consisting of equal portions of lead dioxide^a and polymethyl methacrylate resin^b was placed into each crown through the cervical opening and centrifuged to thoroughly fill the pulpal chamber. The filled crowns then were embedded in clear plastic resin^c rectangular blocks with sides parallel to the surfaces of the tooth crown. The cervical portions of the blocks and teeth were notched in a buccolingual direction so that the notches would lie close to the mesial and distal surfaces. These notches served as guides for aligning the tooth sections in the radiographic films.

Radiographs were taken in a buccolingual direction using a “film-tooth” holding device which positioned a long-cone tube in a consistent relationship to the tooth and film (Figure 2).

The embedded crowns then were sectioned mesiodistally through the central fissure to produce a buccal and a lingual segment. Radiographs were obtained, as described above, for each segment of the crown. In all instances, the x rays were directed at the buccal aspects of the intact teeth and sections.

The radiographs of the crowns and crown sections were projected onto a screen at a constant distance and magnification. Outlines of the crowns and pulpal chambers were drawn on paper and cut. The ensuing tracings, oriented on the mesial and distal identification notches, were assembled on plastic posts mounted on a rigid base. This assembly method allowed the position differences between the radiographs of the buccal and lingual portions to be compared to the presectioned radiographic image (Figure 3).

An average radiographic image (ARI) of each primary molar was obtained by drawing a line approximately horizontal to the occlusal surface in the cervical area of each tracing and drawing vertical lines to the greatest convexity and the greatest concavity of the pulp chamber outline (Figure 4). An ‘R’ (registration) point was created

^a Certified A.C.S. Lead dioxide powder, Fisher Scientific Co., Fair Lawn, N.J.

^b Raypaque, COE Laboratories, Chicago, Ill.

^c Ward’s Bioplastic, Ward’s Natural Science Establishment, Rochester, N.Y.

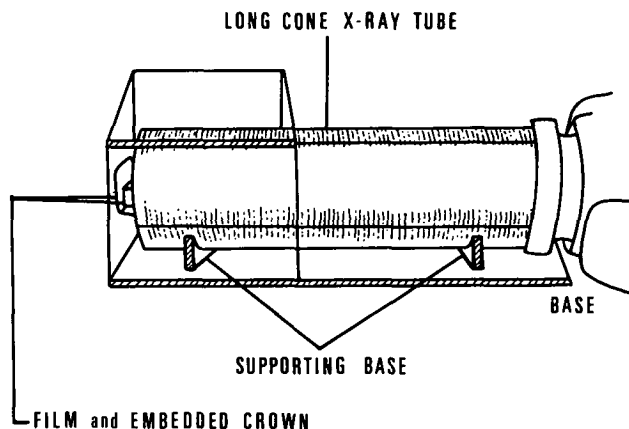


Figure 2. A “film-tooth” holding device used to obtain a constant positioning of a long-cone x-ray tube to an extracted tooth and radiographic film.

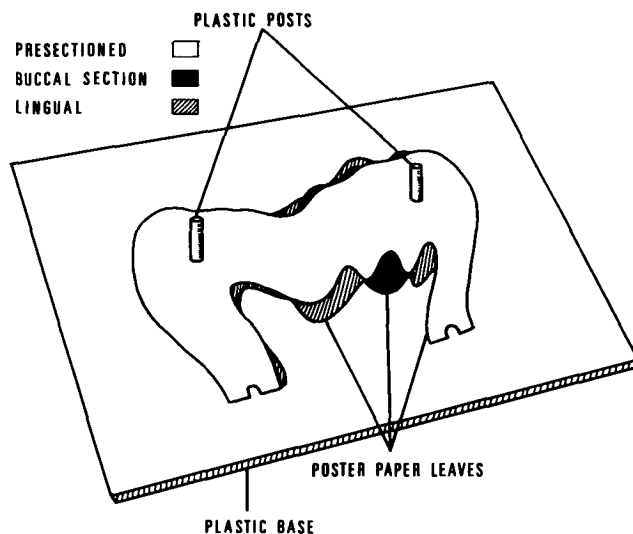


Figure 3. Assembling the projected and cut tracings of pulp chamber outlines onto mounted posts allows study of the positional differences between presectioned, buccal, and lingual sections of primary molars.

to be the midpoint between ‘M’ (midpoint of the greatest convexity vertical line) and ‘N’ (midpoint of the greatest concavity vertical line) on the horizontal line. A horizontal line and ‘R’ point was obtained for each radiographic tracing which served as an independent starting point. From this, the alignment of each tracing onto a grid acetate sheet could be done. The ARI of the presections and buccal and lingual postsections were constructed to serve as a median line for each type of primary molar.

Findings

The radiopaque resin totally filled the pulpal chambers of the presectioned and buccal and lingual sections of 10 specimens and partially filled the remaining specimens. Visual inspection of the partially filled specimens revealed the voids to be small enough to not interfere with subsequent tracings. The radiographs of the presections and buccal and lingual sections are shown collectively in Figure 5.

Group I: Mandibular Second Primary Molars

The radiographs of the presectioned mandibular second primary molar crowns revealed three to four pulpal horns. The largest pulpal horn was adjacent to the mesial coronal surface. Two small pulpal horns were located in the mid-third of the crown or were superimposed in the mid-third between the mesial and distal surfaces. The distal horn was adjacent to the distal surface.

The radiograph of the buccal sections showed three pulpal horns; the mesiobuccal pulpal horn was larger and extended more coronally than the distobuccal or distal horns. The radiographs of the lingual sections revealed mesiolingual and distolingual pulpal horns; the mesiolingual pulpal horns were slightly larger.

Group II: Mandibular First Primary Molar

The radiographs of the presectioned mandibular first primary molar crowns showed two pulpal horns; the mesial horns were larger than the distal horns. The radiographs of the buccal sections showed two pulpal horns; the mesiobuccal and the distobuccal. The mesiobuccal horns were larger and extended more coronally.

The radiographs of the lingual sections presented a mesiolingual and a distolingual horn. The mesiolingual horns were comprised of two small pulpal horns whose outlines curved according to the cuspal outline; the mesiolingual horns were larger than the distolingual horns.

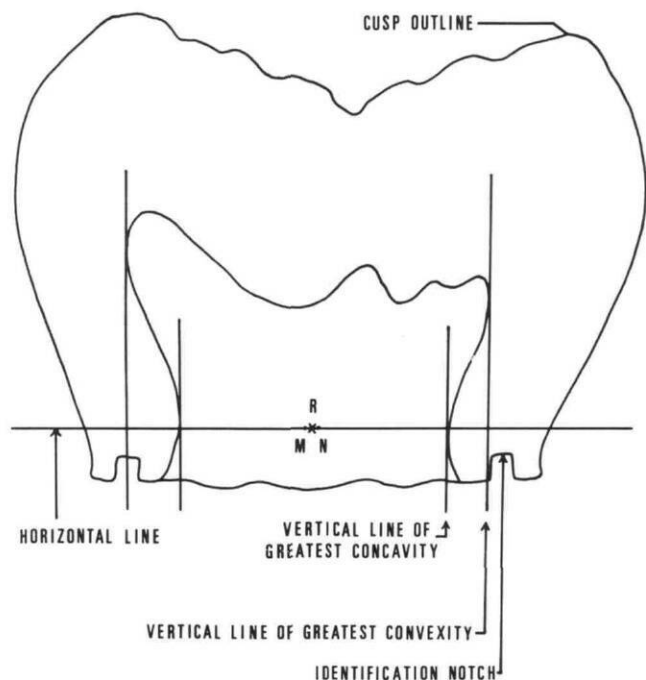


Figure 4. Tracing of a radiographic image of a primary molar in which a horizontal line was drawn in the cervical area. From this, vertical lines were drawn to the greatest convexity or greatest concavity of the pulp chamber. Use of 'R', 'M', and 'N' points allows an "average" radiographic image of the presectioned and buccal and lingual sections to be constructed.

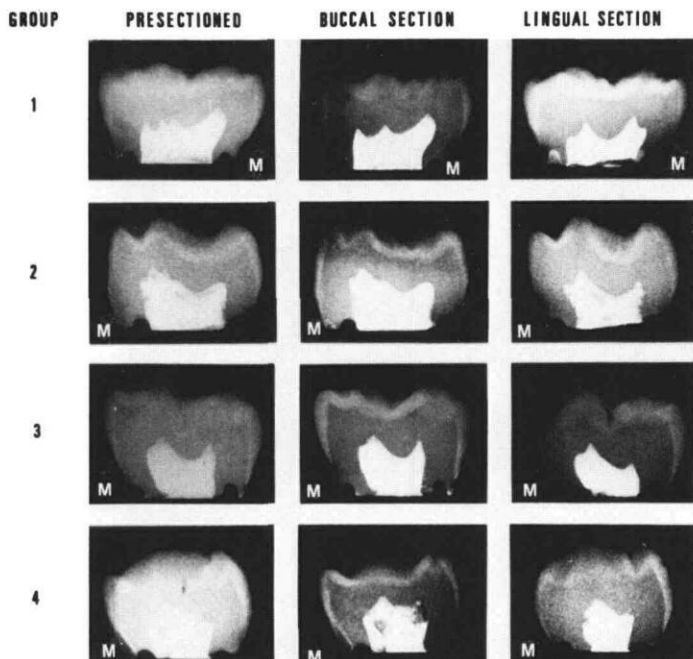


Figure 5. Radiographs of presectioned, buccal, and lingual sections of each of the four primary molar types. Note the overlapping of the cuspal outlines of the buccal and lingual sections on the presectioned films (M — Mesial).

Group III: Maxillary Second Primary Molar

The radiographs of the presectioned maxillary second primary molar crowns revealed two to four pulpal horns, in which there was overlapping of the mesiobuccal and the mesiolingual horns on the mesial aspect, and the distobuccal and distolingual horns on the distal aspect, respectively. The mesial horns were larger and extended more coronally than the distal pulpal horns.

The radiographs of the buccal sections presented mesiobuccal and distobuccal pulpal horns; the mesiobuccal horns were larger and extended more coronally than the distobuccal horns.

The radiographs of the lingual sections showed mesiolingual and distolingual horns. The mesiolingual horns had a minute projection pointed mesio-occlusally, while the mesiolingual horns pointed occlusally. The mesiolingual horns were larger and extended more coronally than the distolingual horns.

Group IV: Maxillary First Primary Molar

The radiographs of the presectioned maxillary first primary molar crowns presented mesial and distal pulpal horns. The radiographs of the buccal sections revealed mesiobuccal and distobuccal horns; the mesiobuccal horns were slightly larger and extended more coronally than the distobuccal horns.

The radiographs of the lingual sections showed mesiolingual and distolingual horns; the mesiolingual horns were larger than the distolingual horns.

Average Radiographic Images (ARI)

Group I: Mandibular Second Primary Molar

The ARI of seven presectioned mandibular second

primary molars showed three pulpal horns; the mesial, the distobuccal in the mid-third, and the distal. In the distal horn there was a slight superimposition of the images of the distal horn and the distolingual horn.

The ARI of the buccal sections showed three pulpal horns; the mesiobuccal, the distobuccal, and the distal. The ARI of the lingual sections showed two pulpal horns; the mesiolingual and the distolingual.

The average tracing of the buccal and lingual sections compared to the average presectioned tracings indicated that the most mesial radiopaque image contained two pulpal horns; the mesiobuccal and the mesiolingual. The middle image represented the distobuccal pulpal horn. The radiopaque image on the distal aspect showed two pulp horns; the distal and the distolingual.

Group II: Mandibular First Primary Molar

The ARI of presectioned mandibular first primary molars showed two pulpal horns in which the mesial horn was larger than the distal horn. The ARI of the buccal sections showed a mesiobuccal and a distobuccal pulpal horn. The ARI of the lingual sections showed a mesiolingual and a distolingual horn.

The average of the buccal and the lingual radiographic tracing, when compared to the presectioned radiographic tracings, indicated that the first pulpal horn on the mesial aspect contained a mesiobuccal horn which superimposed the mesiolingual horn. The pulpal horn on the distal aspect contained a distobuccal and a distolingual horn.

Group III: Maxillary Second Primary Molar

The ARI of the presectioned maxillary second primary molars showed a mesial and a distal horn. The ARI of the buccal sections showed a mesiobuccal and a distobuccal horn. The ARI of the lingual sections showed a mesiolingual and a distolingual horn. From the average of the buccal and lingual radiographic tracings, the first pulp horn on the mesial aspect contained a mesiobuccal and a mesiolingual horn. The pulp horn on the distal aspect contained a distobuccal and a distolingual horn.

Group IV: Maxillary First Primary Molar

The ARI of the presectioned maxillary first primary molars showed a mesial and a distal horn. The ARI of the buccal sections showed a mesiobuccal and a distobuccal horn. The ARI of the lingual sections showed a large mesiolingual horn and a small distolingual horn.

The average of the buccal and lingual radiographic tracings, as compared to the presectioned radiographic tracings, indicated that the first pulp horn on the mesial aspect was the mesiobuccal horn. The mesiolingual horn was overlapping in the mid-third of the crown. The pulp horn on the distal aspect contained a distobuccal horn overlapping the distolingual horn.

Discussion

Interpretation of the size and position of pulpal horns of primary molars in radiographs frequently is difficult because of a superimposition of buccal and lingual structures (Figure 1). The radiopaque resin introduced into the pulp chamber created a clear delineation between the dentin and pulp chamber, thereby clarifying many aspects of radiographic interpretation of pulp chamber morphology.

Recognizing that single-dimension radiographic views are obtained with the methods used in this study, the findings of prior injection mass studies that pulp horns are positioned beneath the coronal cusp tips are only partially confirmed. Mesiodistal films—a feature not possible in this study because of the mesiodistal sectioning of the specimens—would confirm the above cusp/pulp horn positional relationship described by others using different techniques.

Radiographic images of intact crowns tend to be influenced by the buccal pulpal images superimposed upon the lingual pulpal outlines. The outlines of the lingual images in this study were found to be contained within the buccal pulpal images, providing the lingual images with more radiopaque delineation and sharper outlines. Knowing this, one may distinguish overlapping images seen on a typical radiographic film.

Variations in the sizes of pulp chambers, as illustrated by the collected tracings, were found to exist when the "average" tracings were being constructed. The variations found for each tooth type probably were due to the fact that sample teeth were obtained from a variety of patients of different ages, tooth size, and environmental influences, and because of the presence or absence of dental caries.¹⁹ Little is known about the influence of these variables on pulp chamber morphology or on radiographic morphology of pulp chambers.

The determination of the radiographic appearance of reparative dentin response, if any, to age, caries, attrition, tooth size, and/or pulp chamber size would be useful. While dimensional studies of enamel, dentin, and pulp chambers do exist,^{20, 21} the conditions under which they were derived tend to be sufficiently diverse to render comparisons unreliable. Kramer and McLean²² found that while histologic findings of the reparative dentin formation changed over a period of time, reparative dentin formation is so uniform that little variation between the specimens might be observed. Philippas,²³ while studying the influence of occlusal wear and age on formation of dentin and size of pulp chambers in permanent teeth, noted no significant change at the roof of the pulp chamber with age and occlusal wear.

Those specimens in the present study having small carious lesions showed no overt evidence of large deposits of reparative dentin at the radiographic level. While such a factor undoubtedly produces an influence on pulp chamber morphology, it has yet to be deter-

mined if the change is sufficiently large to be determined radiographically.

Conclusions

The following conclusions can be drawn from this study:

1. The radiographic appearance of each extracted primary molar pulp chamber contained two to five overlapping pulpal horns.
2. The radiographic pulpal images of the filled presectioned crowns resembled more closely the radiographic pulpal images of the buccal sections of these crowns.
3. The radiographic pulpal images of the lingual crown sections were superimposed by the larger radiographic pulpal images of the buccal crown sections.
4. Radiographs of the presectioned crowns show the lingual pulpal images to be within the buccal pulpal images.
5. The lingual pulpal radiographic images have more radiodensity and sharper outlines than the superimposing buccal pulpal images.

Dr. Puddhikarant is a resident, and Dr. Rapp is professor and chairman, Department of Pedodontics, School of Dental Medicine, University of Pittsburgh, Pittsburgh, Pa. 15261. Requests for reprints should be sent to Dr. Rapp.

1. Adloff, P. Ueber das uurchsichtigmachen von zahnin und unsere wurzel full ung smethoden. De utsche Monatsschrift fur Zahnkeilk unde, He ft 6, 1914.
2. Moral, H. The occurrence of a fourth root canal in upper molars. Dent Cosmos 63:455, Abstr, 1916.
3. Hess, W. The anatomy of the root canals of the teeth of the permanent dentition. New York: William Wood, 1925, p 199.

4. Fischer, G. Ueber die feinere anatomie der Wurzelkanale menschlicher Zahne. Deutsche Monatsschrift Fur Zahheilkinde, Sept. 1907.
5. Barker, B.C. et al. Anatomy of root canals: II Permanent maxillary molars. Aust Dent J 19:46, 1974.
6. Barker, B.C. et al. The demonstration of root canal anatomy. Aust Dent J 14:37, 1969.
7. Barker, B.C. et al. Teaching aids in dental anatomy. Aust J Med Tech 2:53, 1972.
8. Barker, B.C. et al. Anatomy of root canals: I Permanent incisors, canines and premolars. Aust Dent J 18:320, 1973.
9. Barker, B.C. et al. Anatomy of root canals: III Permanent mandibular molars. Aust Dent J 19:408, 1974.
10. Barker, B.C. et al. Anatomy of root canals: IV Deciduous teeth. Aust Dent J 20:101, 1975.
11. Hess, W., Zurcher, E. The anatomy of the root canals of the teeth of the deciduous dentition and of the first permanent molars. New York: William Wood, 1925, p 173.
12. Meyer, J. Anatomy of root canals. Dent Abstr 1:131, 1956.
13. Rosensteil, E. Transparent model teeth with pulps. Dent Dig 63:154, 1957.
14. Hibbard, E.D., Ireland, R.L. Morphology of the root canals of the primary molar teeth. J Dent Child 24:250, 1957.
15. Simpson, W.J. An examination of root canal anatomy of primary teeth. Can Dent Assoc J, 39:367, 1973.
16. Kramer, W.S., Ireland, R.L. Measurements of the primary teeth. J Dent Child 26:252, 1959.
17. Winter, G.B. Abscess formation in connection with deciduous molar teeth. Arch Oral Biol 7:373, 1962.
18. Bernick, S. Differences in nerve distribution between erupted and unerupted human teeth. J Dent Res 43:406, 1964.
19. Stanley, H.R. The factors of age and tooth size in human pulpal reaction. Oral Surg, Oral Med, Oral Path 14:498, 1961.
20. Kramer, W.S., Ireland, R.L. Measurements of the primary teeth. J Dent Child 26:252, 1956.
21. Arnim, S.S., Doyle, M.P. Dentin dimensions of primary teeth. J Dent Child 26:191, 1959.
22. Kramer, I., McLean, J. Response of the human pulp to self-polymerizing acrylic restorations. Br Dent J 92:255, 1952.
23. Philippas, G.G. Influence of occlusal wear and age on formation of dentin and size of pulp chamber. J Dent Res 40:1186-98, 1961.

Please Note!

The location of the editorial office for the American Academy of Pedodontics has changed. Effective immediately, all correspondence with this office including manuscripts submitted for publication should be sent to: Mr. John B. Ferguson, Managing Editor, American Academy of Pedodontics, 1411 Hollywood Blvd, Iowa City, IA 52240 (319)351-8387.