



# Enamel hypoplasia secondary to candidiasis endocrinopathy syndrome: case report

S.R. Porter, PhD, MD, FDSRCS, FDSRCSE J.W. Eveson, PhD, FDSRCPs, FDSRCS, FRCPath  
C. Scully, PhD, MD, MDS, FDSRCPs, FFDRCSI, FDSRCS, FRCPath

### Abstract

The clinical features of a 7-year-old girl with enamel hypoplasia secondary to autoimmune hypoparathyroidism and chronic mucocutaneous candidiasis are detailed. The combination of features are typical of a rare, probably genetically determined immunodeficiency termed candidiasis endocrinopathy syndrome (CES). Affected individuals have chronic mucocutaneous candidiasis and a spectrum of autoimmune endocrinopathies, including hypoparathyroidism, adrenocortical hypofunction, and diabetes mellitus. Treatment includes long-term management of the candidal infection and correction of any associated endocrinopathy. (*Pediatr Dent* 17:216-19, 1995)

Candidiasis endocrinopathy syndrome (CES) is a rare, probably genetically determined immunodeficiency disorder characterized by recurrent and chronic candidal infections of the skin and mucosae (typically presenting in early childhood), and type 1 autoimmune polyendocrinopathy, usually hypoparathyroidism and/or hypoadrenocorticism.<sup>1</sup> There are few reports of this disorder in the pediatric dental literature.

This report details the clinical features of a child whose main clinical feature was enamel hypoplasia due to hypoparathyroidism associated with CES.

### Case report

A 7-year-old girl was referred for treatment of enlarged, nonpainful maxillary anterior gingivae, which had been present for several months. There was no associated gingival bleeding or pain.

There was a vague history of intermittent cramp-like pain in the thighs, unrelated to exercise or time of day. Of note, the patient had experienced episodes of oral pseudomembranous candidiasis and angular stomatitis that responded to short courses of topical nystatin and/or miconazole gel. The child had mild asthma for which she regularly used a beta-adrenergic inhaler. She had received immunizations against diphtheria, tetanus, pertussis, and poliomyelitis with no

untoward reactions. The parents and two younger sisters all were healthy.

Extraoral examination revealed a painless granulomatous lesion of the right thumb nail (Fig 1) that had been present for at least 6 months. The other fingernails were normal, but several toenails were brittle and shortened. There were no oral mucosal anomalies, but the maxillary labial gingivae were slightly enlarged due to mild gingivitis.

Enamel hypoplasia affected the crowns of the right and left maxillary central and lateral incisors and both mandibular central incisors (Fig 2), but there was no hypoplasia of the first permanent molars or the primary teeth.

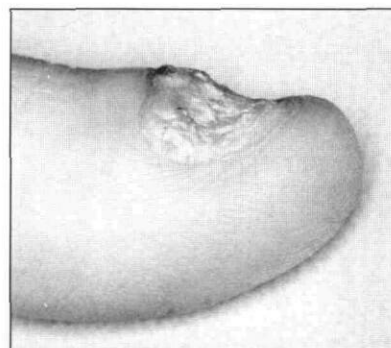


Fig 1. Candidal granuloma at right thumb. Note the distortion of the nail plate and nail bed.

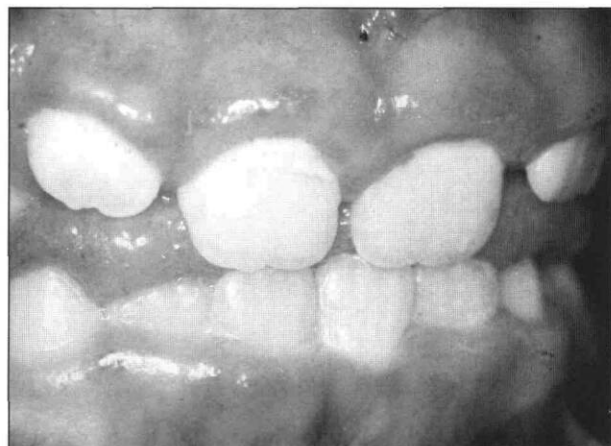

Fig 2. Enamel hypoplasia affecting the crowns of the maxillary permanent incisors.

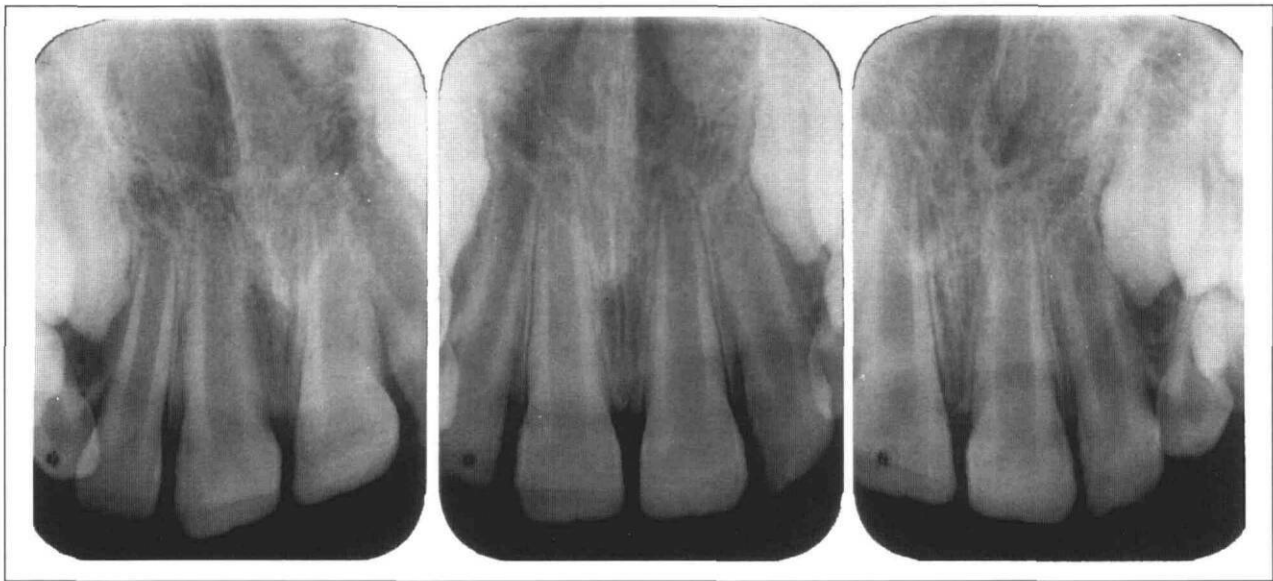

Fig 3. Hypoplasia affecting crowns of developing permanent canines and premolars.

Radiographs indicated horizontal ridging of the crowns of the maxillary right and left central and lateral incisors and enamel hypoplasia of the unerupted permanent canines (Fig 3).

In view of the previous history of intermittent oral candidiasis and probable candidal granuloma of the thumb nail, a provisional diagnosis of chronic mucocutaneous candidiasis (CMC) was made. The enamel hypoplasia suggested that there might also be associated hypoparathyroidism and therefore, CES.

The diagnosis was confirmed by hematological and serological investigations, which indicated that the child was hypocalcemic and hyperphosphatemic. The hypocalcemia was found to be secondary to hypoparathyroidism as shown by the almost undetectable levels of parathyroid hormone (Table 1). There was no evidence of hypoadrenocorticism or any other endocrine disorder. The child did not have autoantibodies to parietal cells, mitochondria, smooth muscle, or reticulin and hence was unlikely to have autoimmune hepatic disease, coeliac disease, or pernicious anemia. Vitamin D supplements were prescribed to correct the hypocalcemia, and the child was referred to a pediatric dentist who is currently advocating an intensive program of preventive measures to minimize any dental caries or gingivitis.

## Discussion

Mucocutaneous candidiasis can give rise to a variety of clinical problems that include thrush (pseudomembranous candidiasis), median rhomboid glossitis, chronic atrophic candidiasis (denture-sore mouth), chronic hyperplastic candidiasis, and angular stomatitis. Oral candidiasis almost always

reflects immunosuppression, tobacco smoking, xerostomia, or use of broad-spectrum antibiotics. CMC is the most rare and severe chronic candidal infection, characterized by recurrent and chronic disease of the skin and mucosae. In CMC the candidal infection typically affects the mouth and much less frequently the genitalia, conjunctivae, and other mucosae. Candidal infection of the nail bed gives rise to dystrophic nail changes and skin infection, which manifests as wart-like granulomas. CMC either can occur in isolation or in association with a variety of other systemic disorders (Table 2).<sup>2,3</sup>

CES, also sometimes termed autoimmune polyendocrinopathy candidiasis-ectodermal dystrophy (APECED) or autoimmune polyglandular disease (type 1), is probably the most common variant of CMC and can arise spontaneously or may have an autosomal recessive mode of inheritance. Girls are affected more

TABLE 1. INVESTIGATION OF PRESENT PATIENT

	Normal Findings	Abnormal Findings
Hematological	Hemoglobin Total and differential white cell counts Platelet counts Red cell folate	
Serological	Ferritin Vitamin B <sub>12</sub> Urea Sodium Potassium Alkaline phosphatase	Calcium — reduced Phosphate — elevated Parathyroid hormone — absent
Microbiological		<i>Candida albicans</i> isolated from saliva

commonly than boys. Candidal infection of the mouth manifesting as recurrent thrush and chronic hyperplastic candidiasis is often the initial presenting feature and clinical features of any associated endocrinopathy may not manifest for 10–15 years; occasionally, however, the sequence is reversed. There is no evidence that candidiasis is due to the endocrine anomalies, or vice versa.<sup>5-7</sup>

Hypoparathyroidism is the endocrinopathy most commonly associated with CES but Addisonian adrenocortical hypofunction, autoimmune thyroid disease, vitiligo, diabetes mellitus, and other autoimmune disorders also can arise.<sup>4,6,8</sup>

The immunodeficiency in CES particularly involves defective T-cell function, but neutrophil and monocyte function also can be impaired. However, not all affected patients have defined immune defects, and individuals with similar immunodeficiencies do not all develop chronic candidal infection.<sup>1,2,9</sup>

Oral features of CES include pseudomembranous candidiasis and recurrent angular stomatitis. Enamel hypoplasia may be seen secondary to hypoparathyroidism, usually affecting the permanent dentition, reflecting the early postnatal onset of the autoimmune hypoparathyroidism.<sup>10-14</sup>

CES management requires antifungal therapy and treatment of the endocrinopathy. Candidal infection of the mouth usually is responsive to topical antifungal therapy, particularly with nystatin or amphotericin B. However, in CMC the infection can be recalcitrant to such measures, hence systemic antifungals such as fluconazole or ketoconazole often are required.<sup>1-14</sup> Correction of the endocrinopathy usually requires replacement of any absent hormones. Hypoparathyroidism requires vitamin D analogue therapy to maximize gut absorption of calcium and, calcium supplements also may be required.<sup>14</sup>

In summary, the oral features of a child with CES have been detailed. The young girl presented with enamel hypoplasia, a history of previous oral candidiasis and subsequently was found to have CES, the enamel hypoplasia due to accompanying hypoparathyroidism. Because of its rarity, CES probably represents one of the less likely primary immunodeficiency disorders to give rise to oral manifestations.

Dr. Porter is senior lecturer and head and Dr. Scully is professor, Department of Oral Medicine, Eastman Dental Institute, London. Dr. Eveson is reader, University Department of Oral and Dental Science, Division of Medicine, Pathology and Microbiology, Bristol Dental Hospital and School, Bristol, England.

**TABLE 2. CHRONIC MUCOCUTANEOUS CANDIDIASIS AND RELATED DISORDERS\***

Type	Inheritance	Principal Other Features	Candidosis	
			Oral	Cutaneous
Early onset	Autosomal recessive	Occasional iron deficiency	++	+
Diffuse	Autosomal recessive or sporadic	Granuloma formation Candidal blepharitis, pharyngitis, laryngitis Occasional bacterial and viral infection High prevalence of iron deficiency	+++	+++
Candidiasis endocrinopathy syndrome	Autosomal recessive or sporadic	Hypoparathyroidism (enamel hypoplasia) Addison's disease Thyroid disease Diabetes mellitus Vitiligo Other autoimmune disorders	++/+++	++/+++
Late onset	Sporadic	Thymoma Myasthenia gravis Polymyositis Hypogammaglobulinemia Bone marrow changes	+	+

+ = Mild; ++ = Moderate; +++ = Severe candidosis.

\* Not including CMC associated with primary immunodeficiency or HIV disease.

1. Porter SR, Scully C: Chronic mucocutaneous candidosis and related syndromes. In: Oral Candidosis. Samaranayake LP, MacFarlane GJ, Eds. London: Wright, 1990, pp 200-12.
2. Cleary TG: Chronic mucocutaneous candidiasis. In: Candidiasis, Pathogenesis, Diagnosis and Treatment. Bodey GP, Ed. New York: Raven Press 1993, pp 241-52.
3. Odds FC: Chronic mucocutaneous candidosis. In: Candida and Candidosis, London: Bailliere Tindal 1990, pp 143-52.
4. Ahonen P, Sinikka M, Sipila I, Perheentupa J: Clinical variation of autoimmune polyendocrinopathy-candidiasis ectodermal dystrophy (APECED) in a series of 68 patients. New Engl J Med 322:1829-36, 1990.
5. Mathes-Alguire B, Alguire PC: Autoimmune polyglandular syndromes. Am Fam Physician 29:149-52, 1984.
6. Trencle DL, Morley JE, Hardwergar BS: Polyglandular autoimmune syndromes. Amer J Med 77:107-16, 1984.
7. Ahonen P: Autoimmune polyendocrinopathy candidosis ectodermal dystrophy (APECED); autosomal recessive inheritance. Clin Genet 27:535-42, 1985.
8. Price ML, MacDonald DM: Candida endocrinopathy syndrome. Clin Exp Dermatol 9:105-9, 1984.
9. Edwards JE, Lehrer RJ, Stiehm ER, Fischer TJ, Young LS: Severe candidal infections: clinical perceptives, immune defense mechanisms, and current concepts of therapy. Ann Intern Med 89:91-106, 1978.
10. Greenberg M, Brightman V, Lynch M, Ship I: Idiopathic hypoparathyroidism, chronic candidiasis and dental hypoplasia. Oral Surg Oral Med Oral Pathol 28:42-53, 1968.
11. Riley DJ: Dental changes in patients with idiopathic hypoparathyroidism: report of two cases. J Oral Surg 27:44-47, 1969.
12. Nally FF: Idiopathic juvenile hypoparathyroidism with superficial moniliasis. Oral Surg Oral Med Oral Pathol 30:356-65, 1970.
13. Myllarniemi S, Perheentupa J: Oral findings in the autoimmune polyendocrinopathy-candidosis syndrome (APECS) and other forms of parathyroidism. Oral Surg Oral Med Oral Pathol 45:721-29, 1978.
14. Porter SR, Scully C: Candidiasis endocrinopathy syndrome. Oral Surg Oral Med Oral Pathol 61:573-78, 1986.

## ***Pediatric Dentistry* can now communicate on line!**

Please direct questions, comments, or letters to the editor to:

**Dr. Paul Casamassimo, Editor in Chief**  
**casamassimo.1@osu.edu (Internet)**

You may also send correspondence or questions about manuscript preparation or status to:

**Sara Pullan, Managing Editor**  
**75471.3203@compuserve.com (Internet)**  
**75471,3203 (Compuserve)**

We welcome your comments and questions. However, please follow the Instructions to Contributors on the inside cover of this journal for manuscript submission procedures.

