

Case Report

The reinforced laryngeal mask airway (LMA) as an alternative airway device to manage the difficult airway

Mark L. Pinosky, MD Cynthia L. Hardin, DDS Durwood E. Bach, DMD Kate Shuman, CRNA

Care of the pediatric patient presenting to the operating room for dental restoration requires a multidisciplinary approach with good communication between pediatric dentist and anesthesiologist. Patients with mental retardation must often present to the operating room for otherwise routine procedures due to their inability to cooperate with the dentist. The major objective for the anesthesiologist in these cases is to provide a quiet surgical field while subjecting the patient to the least amount of potential side effects from general anesthesia as possible. The stimulus from the proposed surgical procedure is less than that created by direct laryngoscopy and tracheal intubation. The laryngeal mask airway (LMA) is an airway device that fulfills the objectives of both the anesthesiologist and surgeon. This technique utilizing the reinforced LMA provides a good benefit-to-risk ratio. The LMA was approved in 1991 by the U.S. Food and Drug Administration as a device to assist in management of the pediatric and adult airway. The LMA is simple to use, atraumatic to insert, and may be helpful in overcoming an obstructed airway. In 1992, an LMA with a reinforced flexometallic tube for greater access to the oral cavity was made available. We present a case of a mentally retarded pediatric patient with a difficult airway who presented for dental restoration and teeth extraction. The case demonstrates an alternative airway device to the dental practitioner.

Case report

The patient was a 16-year-old African-American male with a history of mental retardation with a developmental age of 4 years. He was referred to the Pediatric Dentistry Clinic at the Medical University of South Carolina for full dental restoration and teeth extraction under general anesthesia. The patient's past medical history was significant for seizure disorder, severe mental retardation, and cleft lip, cleft palate syndrome. Physical examination of the patient was significant for microcephaly, micrognathia, and a thick neck with apparent limited mobility. Mouth opening was difficult to assess preoperatively due to the inability

of the patient to cooperate. The patient had an intact pharyngeal flap for the treatment of his cleft palate, further potentially complicating the airway for nasal intubation. The patient's mother stated that there were no complications with the patient's previous surgeries, which included cleft palate repair at ages 1 and 2. The patient also underwent clubfoot repair at age 2 without any difficulty.

Due to the previous cleft palate repair, nasotracheal intubation was contraindicated for management of the patient's airway. Preoperative assessment of the airway revealed the potential of a difficult airway with conventional laryngoscopy and orotracheal intubation. The patient was unable to cooperate with the anesthesiologist for a complete preoperative assessment, however, the patient appeared to have a significant amount of limited cervical mobility and a small mouth opening. Considering these facts, it was felt that the reinforced LMA would be the first choice for airway management. The reinforced LMA was chosen because it gives the most range of manipulation of the tube by the operating surgeon with the least risk of loss of the patient's airway. After communication among the anesthesiologist, pediatric dentist and oral surgeon, a decision was made to insert a # 4 reinforced LMA in the oral pharynx. The patient underwent

a smooth inhalational induction of general anesthesia and the LMA was placed without difficulty. It was determined by the dentist and the oral surgeon that surgical

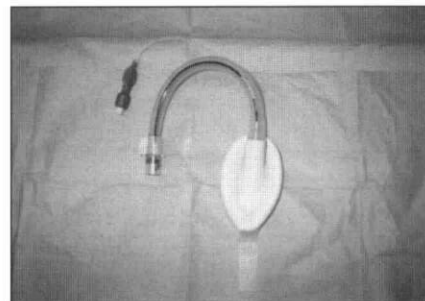


Fig 1. Reinforced laryngeal mask airway.

access to the oral cavity was excellent (Fig 1). The pediatric dentist decided that a smaller gauze dental

pack was indicated to prevent encroachment on the LMA. The procedure was performed without complication and the patient was sent home later that day.

Discussion

This case describes a 16-year-old child with severe mental retardation who presented to the operating room for dental restoration and teeth extraction. The significance of this case report is that the conditions provided by the reinforced LMA during dental surgery are satisfactory from both the anesthesiologists' and dentists' perspective.

The LMA consists of an elliptical spoon-shaped mask with an inflatable rim resembling a miniature face mask. The mask is attached to a shaft that has an internal diameter between 5.25 to 12 mm depending on the size of the LMA. The LMA is available in assorted sizes, accommodating infants to adults. It is made of soft medical-grade silicone and is designed for reuse after autoclaving. The cost of the device is approximately \$200.00 US.

Unlike the standard LMA with a black line along the posterior aspect of the shaft that corresponds to the midsurface of the outer aspect of the mask, the reinforced LMA's shaft does not have the line because the shaft can be moved within the oral cavity without increasing the potential for displacement of the LMA. This feature is the major advantage of the reinforced LMA with regard to dentoalveolar surgery.

The advantages of the reinforced LMA over nasotracheal intubation with an endotracheal tube are reflected in the three phases of anesthetic management: induction, maintenance, and emergence. Placement of the reinforced LMA can be accomplished without the aid of muscle relaxants and laryngoscopy. Insertion of the LMA is designed to mimic deglutition. For routine use, insertion of the LMA requires a depth of anesthesia similar to that which allows insertion of an oropharyngeal airway. Maintenance of anesthetic depth for a patient with a LMA in place is less than that required for the same patient with an endotracheal tube.^{1,2} An added advantage of the LMA is its capability of being placed in the awake patient with application of topical local anesthetic.

The LMA is also well tolerated on emergence from anesthesia with a lower incidence of hyperactive respiratory occurrences than with an endotracheal tube.³ The incidence of post-operative sore throat as well as hoarseness is less with the LMA than with the endotracheal tube.

The primary disadvantage of the LMA is that it is contraindicated if an increased risk of aspiration exists.^{4,5} Patients who present with full stomachs during an emergency procedure or the parturient are examples of patients in whom the LMA would not be recom-

mended. The inflatable cuff does not guarantee an airtight seal to protect the larynx from aspiration of regurgitated gastric contents. In addition, the LMA is not recommended in patients with high inflation pressures (more than 20 cm H₂O).

Intraoral surgery presents its own unique set of challenges to both the dentist and anesthesiologist. The most obvious challenge is that the oral cavity is in continuity with the larynx. Thus, the patient is at increased risk of airway obstruction and unwanted airway stimulation. These factors can lead to laryngospasm and hypoxia. Even with the use of a pharyngeal curtain to minimize possible aspiration of surgical debris, the lower airway remains at risk. The LMA provides an excellent barrier to aspiration of saliva and blood from the surgical field.⁶

A recent study sought to assess conditions provided by the reinforced LMA during oral surgery compared with nasotracheal intubation.⁷ One hundred patients were randomly assigned to receive a reinforced LMA or nasotracheal tube for extraction of wisdom teeth. The study examined incidence of difficulty with insertion, laryngotracheal soiling with blood or surgical debris, and overall satisfaction with the airway as judged by the anesthesiologist, operating surgeon, and patient. They reported no significant differences with regards to insertion difficulty. One interesting note was the finding on fiberoptic examination to evaluate laryngotracheal soiling; three of the 50 patients who had a nasotracheal tube had some evidence of tracheal soiling. There was no soiling present in any of the patients in the LMA group. This probably correlated to the higher incidence of epistaxis (38%) in the nasotracheal tube group. Most importantly, the study showed that there was no significant difference in overall satisfaction with either airway in both the surgeon and anesthesiologist questionnaires. On no occasion was either airway described as poor. There was no reportable difference in patient satisfaction between the two airways, however, there was a higher rate of complaint of jaw pain and sore throat in the reinforced LMA group. This may be reflective of the experience of the anesthesia care team inserting the LMA.

Care of the pediatric patient presenting to the operating room for dental restoration requires a multidisciplinary approach with good communication between pediatric dentist and anesthesiologist. We present the use of the reinforced LMA as an effective alternative to traditional airway management of patients coming to the operating room for dental procedures.

Dr. Pinosky is assistant professor of anesthesia, Dr. Hardin is assistant professor of pediatric dentistry, Dr. Bach is professor of oral and maxillofacial surgery, and Ms. Shuman is nurse anesthetist, at the Medical University of South Carolina, Charleston, South Carolina.

References


1. Taguchi M, Watanabe S, Asakura N, Inomata S: End-tidal sevoflurane concentrations for laryngeal mask airway insertion and for tracheal intubation in children. *Anesthesiology* 81:628-31, 1994.
2. Wilkins CJ, Cramp PGW, Staples J, Stevens WC: Comparison of the anesthetic requirement for tolerance of laryngeal mask airway and endotracheal tube. *Anesth Analg* 75:794-97, 1992.
3. Bennett J, Petito A, Zandsberg S: Use of the laryngeal mask airway in oral and maxillofacial surgery. *J Oral Maxillofac Surg* 54:1346-51, 1996.
4. Pennant JH, White PF: The laryngeal mask airway. Its uses in anesthesiology. *Anesthesiology* 79:144-63, 1993.
5. Pinosky ML: Laryngeal Mask Airway: Uses in anesthesiology. *Progress in Anesthesiology*. Vol XI:343-52, 1997.
6. Webster AC, Morley-Forster PK, Dain S, Ganapathy S, Ruby R, Au A, Cook MJ: Anaesthesia for adenotonsillectomy: a comparison between tracheal intubation and the armoured laryngeal mask airway. *Can J Anaesth* 40:1171-77, 1993.
7. Quinn AC, Samaan A, McAteer EM, Moss E, Vucevic M: The reinforced laryngeal mask airway for dento-alveolar surgery. *Br J Anaesth* 77:185-88, 1996.

MEDLINE on the Web

Literature searches are at your fingertips, from the National Library of Medicine. Choose "Search MEDLINE Free" and you have full, FREE access to both PubMed and Internet Grateful Med.

It's fast, it's easy, and it's free.

The AAPD website now has a link to NLM at <http://aapd.org> or visit NLM's homepage directly at <http://www.nlm.nih.gov>.



Guidance Partnering for Practice Success



Consulting

Dental Meeting & Study
Club Presentations

Appreciation Seminars

Linda Drevenstedt, MS

- Over 15 years in dental practice management and consulting
- Speaks regularly to national, regional, and local organizations
- Frequent contributor to national and state publications and journals



Fitting the Pieces Together
Management Consulting • Seminars • Training

Toll Free: 1-800-242-7648
e-mail: Drevgrp@aol.com