

## Advanced periodontitis in the primary dentition: case report

Peter W.H. Ngan, DMD    Chi-Cheng Tsai, PhD  
Edward Sweeney, DMD

### Abstract

*Juvenile periodontitis (periodontosis) is observed in early puberty with the initial manifestation of rapid bone loss around permanent first molars and incisors. Periodontitis in the primary dentition is rare. The relationship between periodontitis in the primary dentition and the manifestation in the permanent dentition is not known. This report describes a case of advanced periodontitis in the primary dentition and its treatment.*

Juvenile periodontitis (periodontosis) first was described by Gottlieb<sup>1</sup> in 1920 as a noninflammatory degenerative disease of the supporting tissues with diffuse atrophy of the alveolar bone. In 1942 Orban and Weinmann<sup>2</sup> renamed the condition periodontosis. A recently proposed definition of periodontosis is a disease of the periodontium occurring in an otherwise apparently healthy adolescent characterized by a rapid loss of alveolar bone around more than one tooth.<sup>3</sup> More recently, this form of periodontitis has become known as juvenile periodontitis (JP) and is no longer considered a degenerative disease but a bacterial-related inflammatory disease.<sup>4</sup>

Periodontitis in the primary dentition was considered rare if it occurred at all. Page et al. reported 4 different forms of periodontitis: prepubertal, juvenile, rapidly progressive, and adult; however, no clinical case was reported in the primary dentition.<sup>5</sup> Several authors have reported idiopathic bone loss in the primary dentition.<sup>6-11</sup> Since the etiology of the disease is unknown and the reported cases are so few, the treatment of periodontitis in the primary dentition is not well documented. Recently, Cogen et al. reported 5 cases of advanced alveolar bone resorption in the primary dentition of healthy black

children; they concluded that rapidly destructive periodontitis could affect the primary as well as the permanent dentition.<sup>12</sup>

Periodontitis in the permanent dentition is characterized by healthy-appearing gingiva in the early stages of the disease. The diagnosis usually is made radiographically on the basis of large vertical osseous defects initially confined to the regions of the first molars and incisors.<sup>13</sup> In the primary dentition, however, there may be inflamed and swollen gingiva and accumulations of gross subgingival plaque and calculus.<sup>10</sup> A radiographic examination reveals advanced alveolar bone loss around the interproximal areas of the primary molars. In advanced cases, the bifurcation and periapical areas also may be involved.

While the etiology of JP is still unknown, there is a report indicating a familial tendency.<sup>14</sup> Recent studies also have implicated specific microorganisms, immunological deficiencies, and polymorphonuclear leukocyte dysfunction. Newman and Socransky<sup>15</sup> initially reported an association between JP and certain capnophilic gram-negative, fusiform, and surface-translocating microorganisms. These microorganisms later were classified as the new genus *Capnocytophaga*.<sup>16</sup> In addition to *Capnocytophaga*, a gram-negative, anaerobic rod also was found to be associated with JP. This microorganism recently has been identified as *Haemophilus actinomycetemcomitans* (*Ha*) (formerly *Actinobacillus*).<sup>17</sup>

In contrast to *Capnocytophaga*, which may be cultured from individuals without periodontal disease, *Ha* appears to be associated primarily with rapidly progressing alveolar bone loss in young individuals. Of particular interest regarding the pathogenic potential of *Ha* strains is that the leukotoxin isolated from these strains conceivably could affect the normal function of polymorphonuclear leukocytes in individ-

uals with JP.<sup>18</sup> Other studies have shown that in patients with JP there is a significant decrease in the function of polymorphonuclear leukocytes.<sup>19</sup> Possibly the development of JP requires both neutrophil dysfunction and a specific bacterial flora.

Apart from the laboratory findings, Down's syndrome, Papillon-Lefèvre syndrome, cyclic neutropenia, agranulocytosis, and Chédiak-Higashi syndrome also have been associated with bone loss.<sup>20-24</sup>

## Case Report

An 8½-year-old black male presented with a chief complaint of "bleeding gums." His mother found clotted blood around the gingiva in the morning and the bleeding was exacerbated by brushing. The past medical history was noncontributory except for mouth breathing and there was no apparent family history of periodontal disease. An initial radiographic examination indicated severe periodontal destruction around the posterior primary molars. A complete blood test revealed: hematocrit, 30%; hemoglobin, 9.9 gm%; and red blood cell count, 4.2 million/mm<sup>3</sup>. A test for sickle cell anemia proved negative. The white blood cell count was 5600/mm<sup>3</sup> with 58% neutrophils, 28% lymphocytes, 12% monocytes, and 1% eosinophils present. Apart from an elevated alkaline phosphatase level, which is normal for periods of active bone growth, all other results, including a fasting blood sugar level of 108 mg/Dl, a calcium and phosphate level of 9.4 mg/Dl and 4.1 mg/Dl, respectively, were tested normal. The pediatrician concluded that the patient was only slightly anemic due to iron deficiency.

All primary canines and molars and permanent first molars were present and caries free. Permanent incisors were erupting with decalcified areas noted on the labial surface of the maxillary central incisors. Plaque and calculus were present throughout the dentition. Purulent exudate was present only in the mandibular right quadrant. There was severe inflammation of the marginal, papillary, and attached gingiva; the tissue was generally edematous and hyperplastic. Pocket depths ranged from 2 to 5 mm with the deepest pockets occurring in the interproximal areas of the primary molars (Fig 1).

Radiographic examination indicated extensive, bilaterally symmetrical alveolar bone loss with gross involvement of the molar furcations. Radiographically, calculus was seen in many areas — especially the interproximal areas where evident bone loss involved the tooth bud of succedaneous teeth (Fig 2).

The child had an Angle Class I occlusion and tooth mobility was minimal except for the primary molars in the mandibular right quadrants.

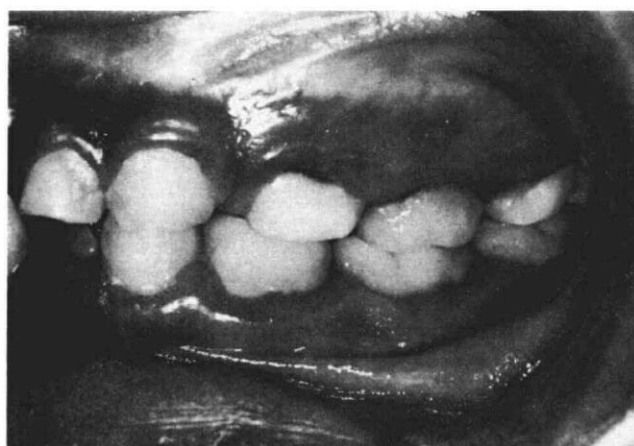

FIG 1. Clinical features of JP in the primary dentition showing grossly inflamed and swollen marginal and attached gingiva.

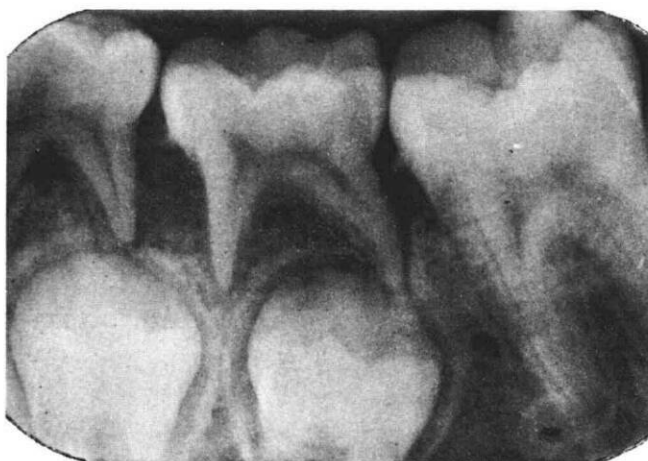

FIG 2. Radiographic features of JP in the primary dentition showing extensive alveolar bone loss with furcation involvement of primary molars.

## Diagnosis and Treatment

Since *Ha* has been implicated in the etiology of JP, a subgingival plaque culture was obtained to test the presence of *Ha* in the gingival pockets according to the method of Taichman et al.<sup>25</sup> Subgingival plaque samples were plated onto a semiselective medium for *Ha*. Following incubation, plates containing well-separated colonies were replica plated onto immunotargeting plates to identify *Ha*. Colonies identified as *Ha* were picked and grown in fluid thioglycollate broth and subjected to a series of tests to identify the different strains. *Ha* (strain JP2), which has been reported as belonging to the leukotoxic Y4 serogroup, was obtained.<sup>26</sup>

Tsai et al. had reported that a vast majority of JP patients have high titers of serum neutralizing anti-

bodies to *Ha* leukotoxin<sup>26</sup> as compared to control serum from healthy individuals.

The patient's treatment included the extraction of all primary molars which had extensive alveolar bone loss and the fabrication of space maintenance appliances. Oral prophylaxis and scaling were performed on routine 6-month recall visits. Since this patient was infected by *Ha* which has been shown to be sensitive to tetracycline, the patient was treated with tetracycline therapy, 250 mg 4 times a day for 1 month.<sup>27</sup>

To follow the periodontal changes after treatment, clinical and radiographic examinations as well as plaque cultures and serum anti-*Ha* antibodies were performed at 6-month intervals for 2½ years. Results indicated normal pocket depths and absence of radiographic bone destruction in the permanent dentition. (Figs 3,4). Plaque culture revealed an absence of *Ha*.

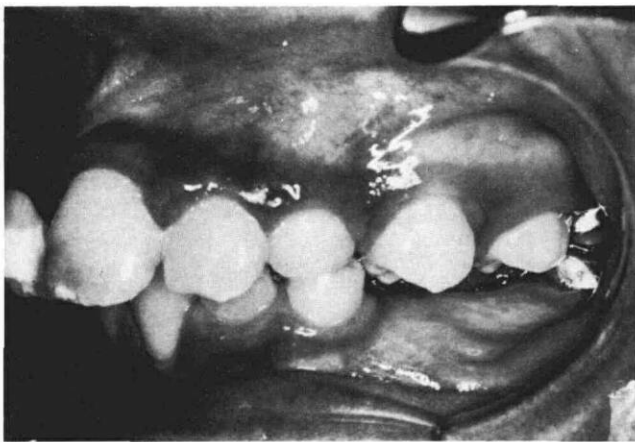

FIG 3. Clinical picture of the patient 2 and a half years post-treatment showing improved gingival health.

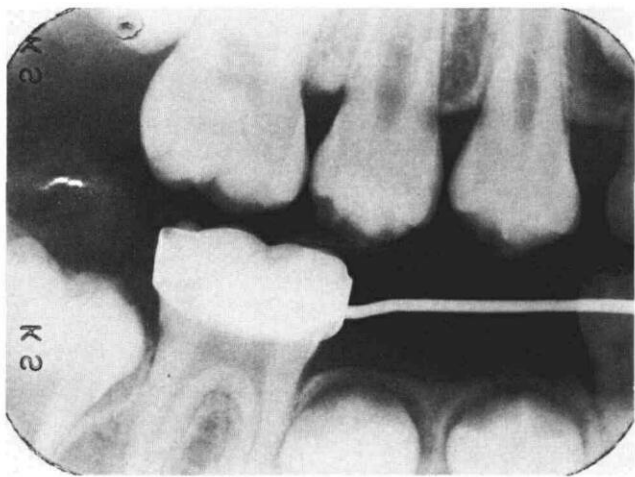


FIG 4. Radiographic survey of patient 2 and a half years post-treatment showing absence of bone destruction around the permanent dentition.

A drop in serum anti-*Ha* leukotoxin titer by one-half after 2 years also was noted.

## Discussion

Advanced periodontitis in the primary dentition is rare in a healthy child without identifiable systemic diseases. The presence of advanced alveolar bone loss in an 8-year-old child indicates that some factor or factors had altered the resistance of the periodontium to virulent local agents. The identification of the organism *Ha* would seem to indicate an etiology of the disease since *Ha* has been found to be associated with JP in older children. The recent identification of several biologically active factors elaborated by *Ha* would support the pathogenesis of this disease.

The relationship between periodontitis in the primary dentition and the subsequent manifestation in the permanent dentition is not known. The extraction of the diseased primary molars and the initiation of antibiotic therapy may have eliminated the foci of the virulent local agent such as *Ha*. In this report, the patient was followed until the permanent dentition had erupted and there was an improved periodontium without evidence of alveolar bone destruction around the permanent dentition.

## Conclusions

A child with advanced alveolar bone loss in the primary dentition has been observed. The diagnosis of advanced periodontitis was based on a complete medical and dental history, clinical and radiographic examination as well as laboratory data. The subgingival plaque culture identified the presence of the microorganism *Ha* in the gingival crevices. The serum neutralizing activity to *Ha* leukotoxin tests confirmed the leukotoxic activity of the microorganisms which could be the pathogenic mechanism of the disease. Treatment of the patient included extraction of the primary teeth, antibiotic therapy, and oral prophylaxis and scaling every 6 months. Two and a half years following initial treatment there was an improved periodontium without evidence of alveolar bone loss around the permanent dentition. It is premature to conclude that extraction and antibiotic treatment are the treatments of choice for JP in the primary dentition.

Dr. Ngan is an assistant professor, orthodontics, The Ohio State University, College of Dentistry, 305 W. 12th Ave., Columbus, OH 43210. Dr. Chi-Cheng is an associate research professor, Center for Oral Health Research, and Dr. Sweeney is acting chairman, Department of Pedodontics, University of Pennsylvania. Reprint requests should be sent to Dr. Ngan.

1. Gottlieb B: Die diffuse Atrophie des Alveolarknochens. Weitere Beiträge zur Kenntnis des Alveolar schwundes und des-

- sen Wiedergutmachung durch Zementwachstum. Zeitschrift für stomatologie 21:195-262, 1923.
2. Orban B, Weinmann J: Diffuse atrophy of the alveolar bone (periodontitis). J Periodontol 13:31-45, 1942.
  3. Baer PN: The case for periodontosis as a clinical entity. J Periodontol 42:516-19, 1971.
  4. Manson JD, Lehner T: Clinical features of juvenile periodontitis (periodontosis). J Periodontol 45:636-40, 1974.
  5. Page RC, Altman LC, Ebersole JL, Vandestein GE, Dahlberg V, Williams BS, Osterberg SK: Rapidly progressive periodontitis: a distinct clinical condition. J Periodontol 54:197-209, 1982.
  6. Butler JH: A familial pattern of juvenile periodontitis (periodontosis). J Periodontol 40:115-18, 1969.
  7. Fourel J: Periodontosis: a periodontal syndrome. J Periodontol 43:240-55, 1973.
  8. Mofitt JH: Juvenile periodontosis: report of a case. J Dent Child 41:30-33, 1974.
  9. Pleasant JE, Nelson DW: Pleasant's disease. Oral Surg 39:686-91, 1975.
  10. Sonis AL: Periodontosis of the primary dentition: a case report. Pediatr Dent 2:53-55, 1979.
  11. Goepferd SJ: Advanced alveolar bone loss in the primary dentition: a case report. J Periodontol 52:753-57, 1981.
  12. Cogen RB, Al-Joburi W, Canfield PW, Stanley HP, Kerwin D: Periodontal disease in healthy children: two clinical reports. Pediatr Dent 6:41-45, 1984.
  13. Baer PN, Benjamin SD: Periodontal Disease in Children and Adolescence. Philadelphia; JP Lippincott Co, 1974 pp 38-39, 158-59.
  14. Vogel RI, Deasy MJ: Familial occurrence of juvenile periodontitis. Ann Dent 39:31-36, 1980.
  15. Newman MG, Socransky SS: Predominant cultivable microbiota in periodontosis. J Periodont Res 12:120-28, 1977.
  16. Socransky SS, Holt SC, Leadbetter ER, Tanner ACR, Savitt E, Hammond BF: Capnocytophaga: new genus of gram-negative gliding bacteria. III. Physiological characterization. Arch Microbiol 122:29-33, 1979.
  17. Tanner ACR, Haffer C, Bratthall GT, Visconti RA, Socransky SS: A study of the bacteria associated with advancing periodontitis in man. J Clin Periodontol 6:278-307, 1979.
  18. Tsai CC, McArthur WP, Baehni PC, Hammond BF, Taichman NS: Extraction and partial characterization of a leukotoxin from a plaque-derived, gram-negative microorganism. Infect Immun 25:427-39, 1979.
  19. Cianciola LJ, Genco RJ, Patters MR, McKenna J, van Oss DJ: Defective polymorphonuclear leukocyte function in a human periodontal disease. Nature 265:445-47, 1977.
  20. Saxén L, Aula S, Westermarck T: Periodontal disease associated with Down's syndrome: an orthopantomographic evaluation. J Periodontol 48:337-40, 1977.
  21. Farzim I, Edalat E: Periodontosis with hyperkeratosis palmaris et plantaris (the Papillon-Lefèvre syndrome): a case report. J Periodontol 45:316-18, 1974.
  22. Cohen DW, Morris AL: Periodontal manifestations of cyclic neutropenia. J Periodontol 32:150-68, 1961.
  23. Bauer WH: The supporting tissues of the tooth in acute secondary agranulocytosis (arsphenamin neutropenia). J Dent Res 25:501-8, 1946.
  24. Tempel TR, Kimball HR, Kakehashi S, Amen CR: Host factors in periodontal disease: periodontal manifestations of Chédiak-Higashi syndrome. J Periodont Res 7:26-27, 1972.
  25. Taichman NS, Shenker BJ, Tsai CC, Glickman LT, Baehni PC, Stevens R, Hammond BF: Cytopathic effects of Actinobacillus actinomycetemcomitans on blood leukocytes. J Periodont Res 19:133-45, 1984.
  26. Tsai CC, Shenker BJ, Dirienzo JM, Malamud D, Taichman NS: Extraction and isolation of a leukotoxin from Actinobacillus actinomycetemcomitans with Polymyxin B. Infect Immun 43:700-705, 1984.
  27. Genco RJ: Antibiotics in the treatment of human periodontal diseases. J Periodontol 52:545-58, 1984.

## Table of Contents

The Table of contents is now on the back cover of the *Journal*. This placement should help readers to find articles of interest and favorite departments quickly.

If you have other suggestions which will make *Pediatric Dentistry* a more useful publication for you, please forward them to: Mr. John Bruce Ferguson, Managing Editor, American Academy of Pediatric Dentistry, 1411 Hollywood Boulevard, Iowa City, IA 52240.