



Extraction of natal and neonatal teeth can leave odontogenic remnants

Michael P. Nedley, DDS Robert T. Stanley, DDS Donald M. Cohen, DMD, MS, MBA

Following extraction of a natal or neonatal tooth, continued growth of the dental papilla may occur and a tooth-like form may develop.¹⁻⁶ This report describes an atypical tooth form (probably the result of continued growth of the retained dental papilla) that abscessed and may have caused delayed eruption of the adjacent primary lateral incisor.

A 13-month-old white male presented to the author's private office (MPN) for evaluation of an atypical tooth in the mandibular anterior segment. At birth, two natal teeth had been present. At 2 weeks of age, a diagnosis of Riga-Fede disease was made and the natal teeth were extracted without complications.

At this exam, an atypical tooth form was noted in the position of the mandibular right primary central incisor (Fig 1). The mandibular left primary lateral incisor was present and erupted; the mandibular right primary lateral incisor was not yet erupted. The atypical tooth form was very narrow mesiodistally and buccolingually (length 9.2 mm, buccolingual width 2.2 mm, mesiodistal width 3.7 mm) and was slightly mobile. The patient was asymptomatic with no difficulty eating. The root structure was long and narrow with a very small pulp canal throughout the length of the tooth. Treatment was deemed unnecessary at that time.

Two months later, PJ presented with an abscess associated with the atypical tooth form. The tooth was extracted under local anesthesia and restraint by mother.

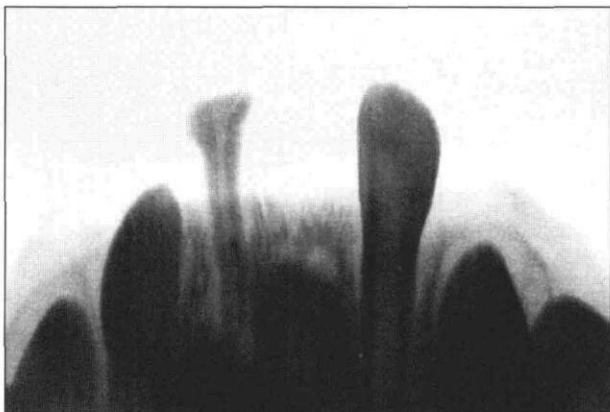


Fig 1. Radiographic presentation.

There were no complications. One week later PJ's mother indicated that the adjacent primary lateral incisor had erupted with some mild discomfort.

Extraction of the natal tooth must have left an intact vital root sheath that continued development into the tooth form that presented at 13 months. The atypical tooth form in this case may have caused delayed eruption of the mandibular right primary lateral incisor. The "normal" eruption time of the mandibular primary lateral incisors is around 7 months.⁷ In this case the mandibular right primary lateral incisor erupted around 15 months. The difference between the "normal" eruption time and the eruption time in this case may be a result of 1) the atypical tooth form in the adjacent position mesially, 2) the asymmetric eruption pattern, or 3) local changes in the nature of the gingival tissues secondary to extraction of the natal teeth.

The phenomenon of continued growth of the dental papilla following extraction of a natal or neonatal tooth is rare. The literature has reported this or similar clinical cases since 1950.¹⁻⁶ Management of these teeth is based on the clinical findings and, due to the nature of the condition, seems to be limited to extraction of involved teeth or no treatment.

Dr. Nedley is in private practice in Grand Island, Nebraska; Dr. Stanley is in private practice in Omaha; and Dr. Cohen is associate professor, oral pathology, diagnosis and radiology, University of Nebraska Medical Center.

1. Ooshima T, Mihara J, Saito T, Sobue S: Eruption of tooth-like structure following exfoliation of natal tooth: report of a case. *ASDC J Dent Child* 53:275-78, 1986.
2. Kates GA, Needleman HL, Holmes LB: Natal and neonatal teeth: a clinical study. *J Am Dent Assoc* 109:441-43, 1984.
3. Massler M, Savara BS: Natal and neonatal teeth. Review of 24 cases reported in the literature. *Pediatrics* 36:349-59, 1950.
4. Berman DS, Silverstone LM: Natal and neonatal teeth. A clinical and histologic study. *Br Dent J* 139:361-65, 1975.
5. Berendsen WJ, Wakkerman HL: Continued growth of the dental papillae after extraction of neonatal teeth: report of a case. *ASDC J Dent Child* 55:139-41, 1988.
6. Ryba GE, Kramer IRH: Continued growth of human dental papillae following removal of the crown of partly formed deciduous teeth. *Oral Surg Oral Med Oral Path* 15:867-75, 1962.
7. Ash MM: *Wheeler's Dental Anatomy Physiology and Occlusion*. 5th Ed. Philadelphia: WB Saunders Co, 1984, p 24.