

# The acute toxicity of high doses of systemically administered formocresol in dogs

David R. Myers, DDS, MS

David H. Pashley, DDS, PhD

Gary M. Whitford, PhD, DMD

Robert E. Sobel, MS, PhD

Ralph V. McKinney, DDS, PhD

## Abstract

*Formocresol applied to vital pulp tissue may be absorbed systemically. The possible effect of the systemic absorption of formocresol is unknown. The purpose of this project was to determine the acute toxic effect of systemically administered formocresol. Two dogs were anesthetized and Buckley's formocresol was administered i.v. at doses of 0.05 and 0.15 ml/kg respectively. Blood pressure and heart rate were continuously recorded. Blood samples and timed urine collections were made for chemical analyses and tissue samples were collected for histological evaluation. Transient cardiac arrhythmias occurred in both dogs. A decrease in blood pressure and heart rate occurred in the dog receiving the higher dose. Following formocresol administration, the plasma enzyme profiles demonstrated an elevation in LDH, SGOT and alkaline phosphatase. The urinary SGOT levels were below plasma levels while urinary LDH and alkaline phosphatase paralleled plasma levels. Blood was detected in the urine of each animal. Histologically the kidneys revealed glomerular edema, cloudy swelling and hydropic change of the tubular epithelium. The lungs exhibited an atypical pneumonitis with septal fibrin deposition.*

## Introduction

Formocresol applied to vital pulp tissue is readily absorbed into the systemic circulation and distributed throughout the body.<sup>1,2</sup> A portion of the absorbed formocresol is metabolized and excreted by the kidney and lungs. The remaining formocresol is bound to tissue with the kidney, liver and lung as the predominant sites.<sup>2</sup> Formocresol is toxic to cells and appears to interfere with RNA synthesis, enzyme recovery and<sup>3</sup> H-proline uptake.<sup>3-5</sup> Autologous pulp tissue treated with formocresol has been shown to elicit an immune response in dogs.<sup>6</sup> The absorption of formocresol fol-

lowing application to vital pulp tissue raises questions regarding its potential toxic effects. The purpose of this project was to determine the acute toxic reaction to systemically administered formocresol.

## Methods and Materials

Two dogs were anesthetized with pentobarbital and intubated with a cuffed endotracheal tube. Catheters were placed in the femoral artery for blood pressure and heart rate measurements and in the femoral vein for formocresol administration. The catheter in the femoral vein was advanced until it was approximately 10cm into the inferior vena cava to insure that the injected formocresol quickly mixed with the central venous volume. Each dog then received an intravenous injection of Buckley's formocresol.

The first dog received 1.0 ml or the equivalent of 0.048 ml/kg. The second dog received 2.5 ml or the equivalent of 0.149 ml/kg. The doses were based on a report that intravenous formaldehyde administration to dogs at levels above 1 mg/kg results in decreases in blood pressure.<sup>7</sup>

In order to avoid doses of formaldehyde that would cause rapid cardiovascular deterioration, we lowered the dose to a level of approximately 0.01 mg formaldehyde/kg i.v., recognizing that we were injecting both formaldehyde and cresol. The published LD50 data for these two substances indicates that formaldehyde is by far the most toxic of the two.

The dog receiving the lowest dose (i.e., 0.05 ml formocresol/Kg x 19% = 0.0097 or 0.01 mg formaldehyde/kg, dog #1) did not demonstrate a fall in blood pressure. Several ectopic heart beats occurred but the animal was surprisingly stable. This prompted us to increase the dose three-fold which produced more

Accepted: March 26, 1980

cardiac arrhythmias and a transient fall in blood pressure.

Blood samples were taken at 0, 30, and 60 minutes, and then hourly for six hours following formocresol administration. Urine collections were made from -30 to 0, 0 to 30, 30 to 60 minutes and then hourly for six hours. Blood pressure and heart rate were recorded continuously. By collecting blood and urine prior to formocresol administration, each day served as its own control.

Immediately following blood collections, the plasma was separated and subjected to sequential multiple analyses (SMA 6 and SMA 12). The following substances were measured in plasma and urine: sodium, potassium, chloride, total CO<sub>2</sub>, glucose, urea nitrogen, total protein, albumin, calcium, inorganic phosphorus, uric acid, creatinine, total bilirubin, iron, serum oxalo-glutamic transaminase (SGOT) alkaline phosphatase (AP) and lactic dehydrogenase (LDH). In addition, aliquots of all urine samples were centrifuged and examined microscopically for cells, casts, bacteria and crystals within 30 minutes of collection. All urine samples were also tested for protein, ketones, pH, hemoglobin, bilirubin and urobilinogen by dip sticks.\*

The dogs were sacrificed after six hours, and tissue samples were taken of the heart, liver, kidney and lung, immediately placed in 10% neutral buffered formalin, and then processed on an Autotechnican II for routine paraffin embedding. Five nanometer sections were cut on a rotary microtome, stained with hematoxylin and eosin and evaluated histologically.

## Results

**I. Physiological** The heart rate in both dogs decreased transiently upon administration of formocresol. In the first dog, which received the lower dose of formocresol, the heart rate gradually returned to the pre-formocresol administration level. The heart rate in the second dog, which received the higher dose of formocresol, was erratic during the first hour, then gradually declined and abruptly dropped toward the end of the experiment (Table 1).

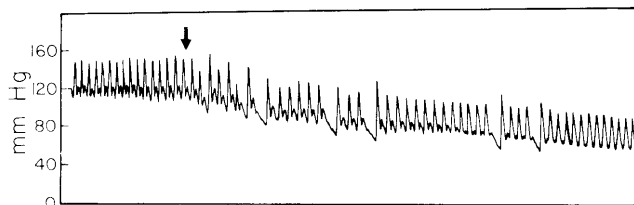
**Table 1.** Heart rate estimated to nearest five beats per minute.

| TIME (Min) | Heart Rate |    |     |    |     |     |     |     |     |  |
|------------|------------|----|-----|----|-----|-----|-----|-----|-----|--|
|            | 0          | 15 | 30  | 60 | 120 | 180 | 240 | 300 | 360 |  |
| Dog I      | 110        | 90 | 65  | 95 | 90  | 105 | 110 | 115 | 120 |  |
| Dog II     | 103        | 65 | 100 | 90 | 95  | 90  | 85  | 80  | 55  |  |

\*Multistix, Ames Company, Division of Miles Lab, Inc., Elkhart, Indiana 46514

Cardiac arrhythmias were noted in both dogs during the first minute following formocresol administration (Figure 1). The dog which received the highest dose exhibited random, isolated arrhythmias for several hours.

The mean blood pressure fell in both dogs following the injection of formocresol, with the largest fall occurring in the dog that received the higher dose. The blood pressure returned to the pre-treatment level during the course of the experiment in both dogs (Table 2).



**Figure 1.** Blood pressure tracing displaying arrhythmia following formocresol administration (dog II).

**Table 2.** Mean blood pressure mm Hg. Estimated to nearest 5 mm Hg.

| TIME (Min) | Mean Blood Pressure |     |     |     |     |     |     |     |     |  |
|------------|---------------------|-----|-----|-----|-----|-----|-----|-----|-----|--|
|            | 0                   | 15  | 30  | 60  | 120 | 180 | 240 | 300 | 360 |  |
| Dog I      | 130                 | 185 | 130 | 130 | 135 | 130 | 130 | 140 | 150 |  |
| Dog II     | 130                 | 60  | 95  | 130 | 135 | 150 | 140 | 140 | 130 |  |

Blood quickly appeared in the urine of dog II which received the higher dose of formocresol. The level peaked in sixty minutes and remained constant. In the dog receiving the lower dose of formocresol, no blood was evident in the urine until five hours into the experiment. At this point it rose quickly and by the completion of the experiment, both animals had comparable levels of blood in the urine, as detected by both dip stick and direct microscopic examination.

Unless specifically discussed, all plasma values for the substances analyzed in the sequential multiple analyses (SMA Series) were within normal limits. The following substances deviated from normal.

In the first dog, the plasma LDH level rose slightly through the experiment. In the second dog, there was an early increase in plasma LDH which gradually declined. The plasma alkaline phosphatase levels and the plasma SGOT levels did not change significantly in the dog receiving the lowest formocresol dose but

did increase and remain elevated in the dog receiving the highest dose (Figure 2).

The urinary LDH level in the first dog fell sharply during the first 60 minutes, remained constant from 60-300 minutes and then increased. In the second dog, the LDH level rose throughout the first 120 minutes and then declined (Figure 3).

The urinary alkaline phosphatase level did not change in the dog receiving 0.048 ml/kg formocresol, but did rise over the first 120 minutes in the dog that received 0.149 ml/kg. The SGOT level remained unchanged in both animals (Figure 3).

Multistix analysis confirmed, in a qualitative manner, the results of the quantitative enzyme analyses. No direct microscopic evidence of renal casts was noted.

**II. Histological** Histological evaluation revealed evidence of cell and tissue injury. The extent of the injury was greater in the second dog, which had received the higher dose of formocresol.

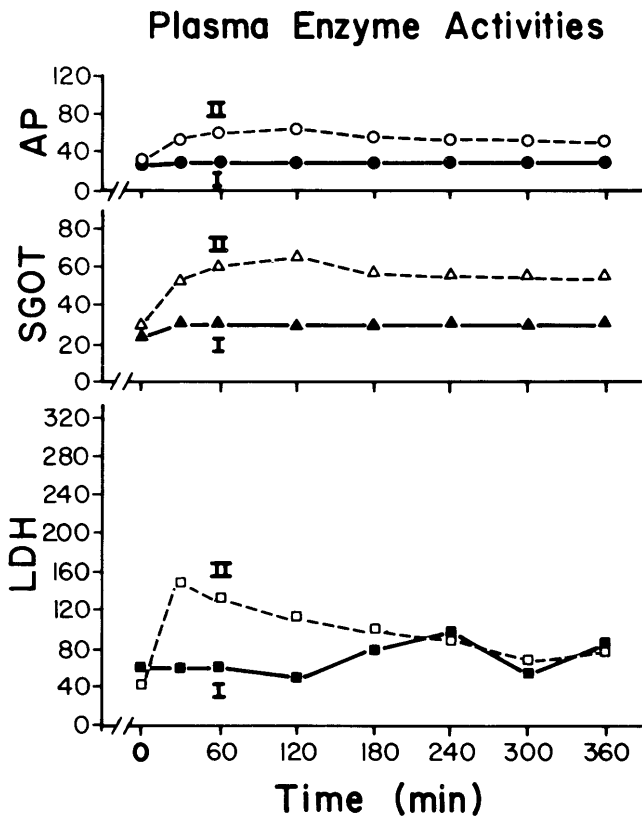
The kidney of the second dog displayed terseness of the glomerular tuft and hyperemia of the glomerular capillaries. Edema of Bowman's space was evident with red blood cells present in the space. The kidney tubules exhibited a foamy or vesiculated cytoplasm,

changes consistent with a form of reversible cell injury called cloudy swelling and hydropic change (Figure 4A).

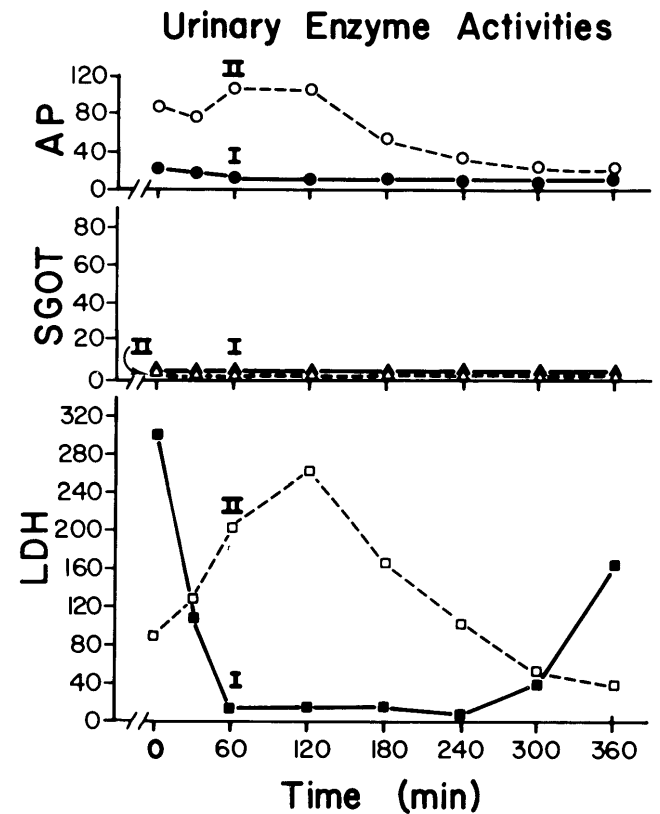
Sections taken from the liver also exhibited foamy and vesiculated cytoplasm, changes consistent with cloudy swelling and hydropic change (Figure 4B). No evidence of active or passive venous congestion was observed in the liver sinusoids (Figure 4B).

The lung demonstrated some surprising changes; an acute and chronic inflammatory cell infiltrate was observed throughout much of the lung parenchyma (Figure 4C), however, this infiltrate was confined to the septal wall suggesting an atypical pneumonitis. In addition, some fibrin deposition was observed adjacent to the septal capillaries (Figure 4C). The alveolar air spaces seemed to remain remarkably free of inflammatory cell infiltrate. In some observed fields there was focal collapse of alveolar air sacs, suggesting focal atelectasis. The exact mechanism for this latter phenomenon is not clear.

Sections from the dog heart revealed slight edema between cardiac muscle bundles. Further, some of the individual muscle bundles showed evidence of cloudy swelling. These heart changes would be consistent



**Figure 2.** Plasma enzyme profile. Note that the appearance of LDH in plasma is similar to the appearance of LDH in the urine, dog I (low dose) and dog II (high dose).



**Figure 3.** Urinary enzyme profile. Note the sharp LDH fall 60 minutes after formocresol administration in dog I. In contrast, the urinary LDH level rose in dog II during the first two hours after administration before falling.

with a hypoxic injury to the cardiac muscle (Figure 4D).

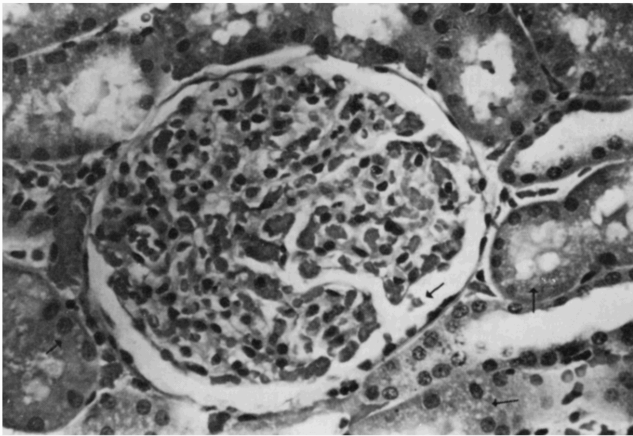
## Discussion

Formocresol is never administered in the manner described in this study. However, since it has been shown to be readily absorbed systemically following its application to vital pulp tissue,<sup>1-2</sup> the present study seems appropriate to identify the potential sites and the nature of the acute toxic reactions to systemically administered formocresol. The results of this study suggest that the acute toxic effects of systemically administered formocresol include cardiovascular changes, plasma and urinary enzyme changes and his-

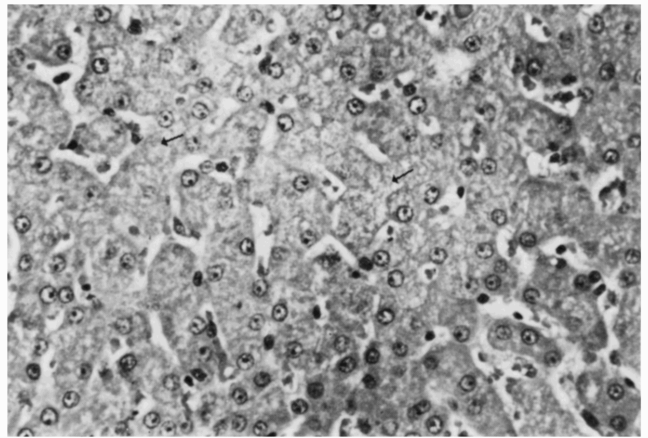
tological evidence of cellular injury to the vital organs.

In the urinary enzyme profile, the abrupt drop in LDH level in the first dog may have been the result of the mannitol-induced diuresis. The increase in LDH seen in the first dog at five hours and in the second dog at one hour correlates well with the appearance of blood in the urine. The increase in LDH may have been due to red blood cells or their contents in the urine.

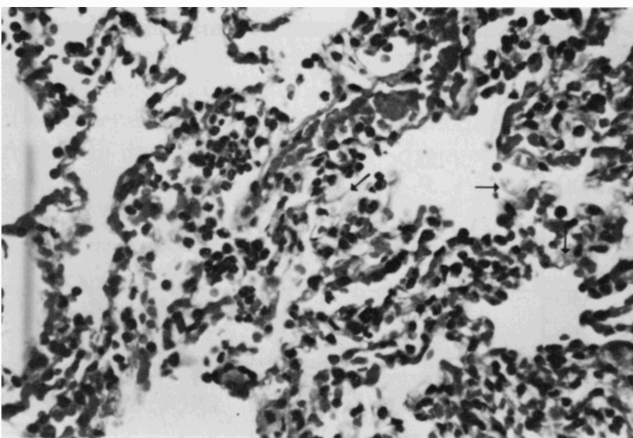
The appearance of LDH and alkaline phosphatase in the urine paralleled similar changes in the plasma. The urinary enzymes are apparently due to hemolyzed red blood cells, rather than of renal origin, due to the similarity of the rate of change of plasma and urinary enzymes. Although LDH and alkaline phosphatase are found in both red cells and the kidney, little SGOT was found in the urine. Since the kid-



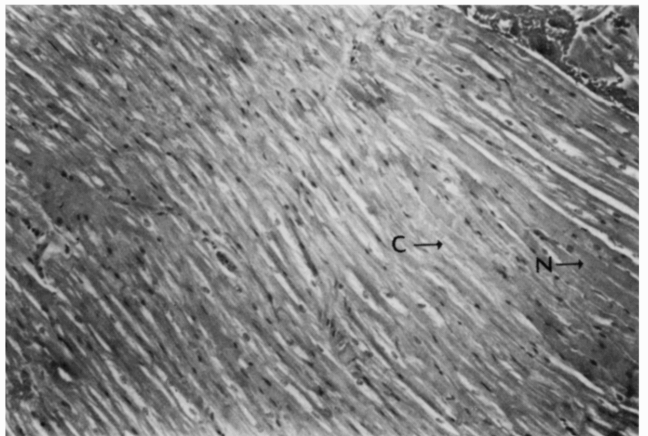
**Figure 4A:** The kidney cortex exhibits terse glomerular tufts with increased width of Bowman's space, hyperemia of the glomerular capillaries, and red blood cells in Bowman's space (arrow). The tubules in this section exhibit foamy and vesiculated cytoplasm (arrows). Original magnification X 40 (dog II).



**Figure 4B:** A section from the liver parenchyma showing extensive foamy and vesiculated cytoplasm (arrows). Note the liver sinusoids are essentially normal and do not exhibit any active sinusoidal congestion. Original magnification X 100 (dog II).



**Figure 4C:** A section of lung tissue showing both acute and chronic inflammatory cellular infiltrate in the lung septal walls. Note that the alveolar air spaces are relatively free of inflammatory cell infiltrate. Septal fibrin deposition is evident in several locations (arrows). Original magnification X 40 (dog II).



**Figure 4D:** Dog heart cardiac muscle exhibiting slight edema between muscle bundles. Also a number of the cardiac muscle bundles exhibit cloudy swelling (C), while adjacent muscle bundles appear normal (N). Original magnification X 40 (dog II).

ney is a rich source of SGOT, its absence suggests minor renal contribution and points more to hemolyzed red cells as the major source of enzymes in the urine.

The degree of tissue injury appears to be dose related as the dog receiving the higher dose of formocresol demonstrated more marked biochemical and histological evidence of tissue injury. However, the observed nature of the cellular injury suggests that some of these tissue changes may be reversible, at least in the early stages.

This study has localized the sites of potential toxic reactions resulting from systemic formocresol. Further studies are indicated to determine the acute effects of quantities of formocresol more closely approximating those which might be absorbed following single or multiple pulpotomies. The duration and reversibility of any toxic reactions should also be investigated. The kidney appears to be the most susceptible site for potential injury and should be examined by both light and electron microscopic technics. Until such studies have been completed, this data should not be extrapolated to clinical dental practice.

---

Dr. Myers is professor and chairman of the pedodontics department, Dr. Pashley is professor of oral biology, Dr. Whitford is associate professor of oral biology and physiology, Dr. Sobel is assistant professor of cell and molecular biology, and associate professor of pathology, and Dr. McKinney is professor of oral pathology and oral biology, the Medical College of Georgia, Augusta, Georgia 30912. Requests for reprints should be sent to Dr. Myers at that address.

---

---

A portion of this paper was presented at the 57th annual session of the American Association for Dental Research, New Orleans, 1979.

---

#### References

1. Myers, D. R., Shoaf, H. K., Dirksen, T. R., Pashley, D. H., Whitford, G. M., and Reynolds, K. E.: "Distribution of  $^{14}\text{C}$ -formaldehyde after pulpotomy with formocresol," *J Am Dent Assoc*, 96:805, 1978.
2. Myers, D. R., Pashley, D. H., Whitford, G. M., McKinney, R. and Sobel, R.: "Acute toxicity of systemically administered formocresol," *J Dent Res*, Special Issue A, 58: Abstract 803, 293, 1978.
3. Straffon, L. H. and Han, S. S.: "The effect of formocresol on hamster connective tissue cells, a histologic and quantitative radioautographic study with proline- $\text{H}^3$ ," *Arch Oral Biol*, 13: 271, 1968.
4. Straffon, L. H. and Han, S. S.: "Effects of varying concentrations of formocresol on RNA synthesis of connective tissue in sponge implants," *Oral Surg*, 29:915, June, 1970.
5. Loos, P. J. and Han, S. S.: "An enzyme histochemical study of the effect of various concentrations of formocresol on connective tissue," *Oral Surg*, 31:571, 1971.
6. Block, R. M., Lewis, R. D., Sheats, J. B., Berke, S. H., and Fawley, J.: "Antibody formation and cell mediated immunity to dog pulp tissue altered by formocresol within the root canal," *J Dent Res*, Special Issue B, 56: Abstract 758, 241, 1977.
7. Tani, T., Satoh, S. and Horiguchi, Y.: "The vasodilator action of formaldehyde in dogs," *Toxicology and Applied Pharmacology*, 43:493-499, 1978.