



Eruption of an impacted second premolar after marsupialization of a large dentigerous cyst: case report

Atsuko Murakami, DDS Keiko Kawabata, DDS Atsuko Suzuki, DDS
Shumei Murakami, DDS, PhD Takashi Ooshima, DDS, PhD

Dentigerous or follicular cysts are one of the most prevalent types of odontogenic cysts and are associated with the crown of an unerupted or developing tooth.^{1,2} The cyst enclosing the crown of the unerupted tooth also is attached to the tooth along the cervical region. The teeth most often involved are mandibular third molars, maxillary canines, and mandibular premolars.³ Usually, dentigerous cysts begin to develop through an accumulation of fluid between the remnants of the enamel organ and the subjacent tooth crown shortly after complete formation of the crown. The expansion of dentigerous cysts is related to a secondary increase in cyst fluid osmolality as a result of passage of inflammatory cells and desquamated epithelial cells into the cyst lumen.⁴ In rare cases, the dentigerous cyst develops as a result of the intra-follicular spread of periapical inflammation from an overlying primary tooth.^{1,3} The purpose of this report is to describe a case of a large dentigerous cyst that impacted a second premolar, which erupted naturally after marsupialization of the cyst.

Case report

A 12-year, 8-month-old Japanese boy was referred to The Pedodontic Clinic of Osaka University Dental Hospital with the complaint of a painless expansion of the region around the mandibular left primary second molar. Clinical examination revealed a retained mandibular left

primary second molar that was mobile and gray (Fig 1a). The patient had noticed a painless expansion of the alveolus around the primary tooth about 2 weeks before without signs of acute or chronic infection. The tooth had been treated endodontically about 4 years prior and had the remains of occlusal resin.

Radiographic examination showed a large, circular, well-defined and a unilocular radiolucent area surrounding the crown of the mandibular left second premolar with the tooth displaced horizontally under the nonvital endodontically treated primary second molar (Fig 2a). There had been considerable resorption of the pulp chamber floor of the primary molar, but its roots had failed to resorb physiologically. The apices of the primary second molar appeared to project into the lumen of the cystic cavity and were not resorbed

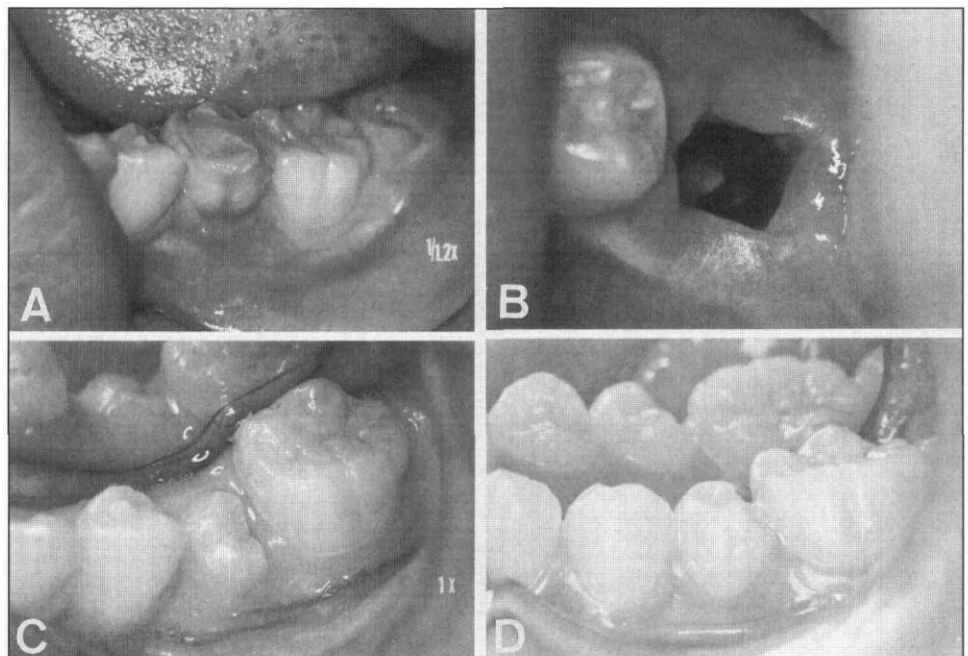


Fig 1. Oral photographs: a) On initial examination; b) Just after extraction of the primary second molar; c) 5 months after the operation; the permanent tooth erupted naturally; d) About 1 year postoperatively.

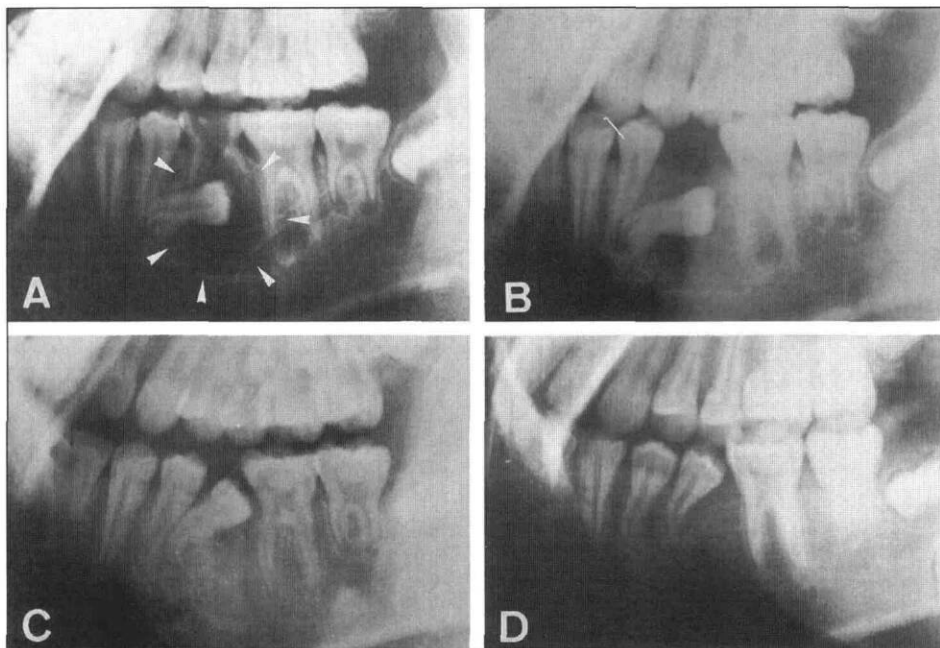


Fig 2. Lateral radiographs: a) On initial examination; b) 1 month after the operation; c) 5 months after the operation; d) About 1 year postoperatively.

abnormally, suggesting the possibility — albeit low — of unicystic ameloblastoma. An occlusal radiograph revealed buccal expansion of bone at the affected site.

The mandibular primary second molar was extracted under infiltration anesthesia and an opening was made through the exposed cyst to give a good view of the cyst lining and the unerupted tooth (Fig 1b). Histological examination was not done because the cyst lining under the primary second molar could not be excised. Antibiotics were administered for 2 days to prevent postoperative infection and the operative site was irrigated with saline for a month after the extraction. Radiographic examination a month after extraction revealed the circular radiolucent area had become smaller, but the second premolar was still impacted horizontally (Fig 2b). About 5 months postoperatively, the affected tooth had partially erupted (Fig 1c). The radiolucent area had disappeared and repair by new bone tissue was observed (Fig 2c). After a year, the affected second premolar had erupted almost completely, but was displaced slightly distally with incomplete formation of the bent root observed on radiographic examination (Figs 1d & 2d). There were no other remarkable findings. Eight months after the operation, the right primary second molar exfoliated naturally, with the successive second premolar erupting subsequently.

Only observation of the affected site has been continued since the patient refused orthodontic treatment.

Discussion

The association between an infected primary tooth and the development of a dentigerous cyst involving the pre-erupted permanent tooth has long been dis-

cussed. Azaz and Shteyer⁵ proposed that persistent and prolonged inflammation caused chronic irritation to the unerupted premolar's dental sac and might cause a dentigerous cyst. Furthermore, Shaw et al.⁶ presented the possibility in a series of 13 cases that inflammation at the apex of a primary tooth can lead to the development of an inflammatory follicular cyst. On the other hand, Shear³ doubted the association of dentigerous cyst formation with the inflammation around primary teeth and presented a probable relationship wherein the erupting permanent tooth had indented the radicular

cyst wall of primary tooth. Main⁷ categorized the epithelial jaw cysts into two groups — developmental and inflammatory — and added the inflammatory follicular cyst to the latter group as a new type. Seddon et al.⁸ showed an epithelial proliferation of the follicular tissues induced by chronic periapical inflammation of the predecessor as the most likely pathogenesis of cystic transformation. The authors support the term “inflammatory dentigerous cyst” for the dentigerous cyst induced or hastened by periapical inflammation of the primary tooth.

Marsupialization is the best way to conserve a tooth affected by a dentigerous cyst and to permit its eruption, especially in a young person.⁹ Azaz and Shteyer⁵ described marsupialization in four cases of dentigerous cysts involving second premolars that apparently were associated with infected primary predecessors. Four weeks postoperatively, the teeth had erupted. Furthermore, Shaw et al.⁶ reported similar findings in nine cases. In our case, the second premolar, the origin of a dentigerous cyst, showed a marked displacement and was hopelessly impacted. However, marsupialization after the extraction of the infected primary second molar allowed eruption of the permanent premolar without orthodontic treatment. In any case of inflammatory dentigerous cyst associated with an infected primary tooth, marsupialization may be the first choice of treatment to permit eruption of the permanent tooth.


Dr. A. Murakami is clinical instructor, Dr. Kawabata is clinical instructor, Dr. Suzuki is research associate, Dr. S. Murakami is clinical instructor, and Dr. Ooshima is associate professor, Department of Pedodontics, Osaka University Faculty of Dentistry, Osaka, Japan.

1. Main DM: Epithelial jaw cysts: a clinicopathological reappraisal. *Brit J Oral Surg* 8:114-25, 1970.
2. Soames JV, Southam JC: Cysts of the jaws and oral soft tissues. In: *Oral Pathology*, 2nd Ed. Soames JV, Southam JC, Eds. Oxford: Oxford University Press, 1993, pp 69-87.
3. Shear M: Dentigerous (follicular) cyst. In: *Cysts of the Oral Regions*, 3rd Ed. Shear M, Ed. Bristol: Wright PSG, 1992, pp 75-98.
4. Browne RN, Smith AJ: Pathogenesis of odontogenic cyst. In: *Investigative Pathology of the Odontogenic Cysts*. Browne RN, Ed. CRC Press, 1990, pp 88-109.
5. Azaz B, Shteyer A: Dentigerous cysts associated with second mandibular bicuspids in children: report of five cases. *J Dent Child* 40:29-31, 1973.
6. Shaw W, Smith M, Hill F: Inflammatory follicular cysts. *ASDC J Dent Child* 47:97-101, 1980.
7. Main DM: Epithelial jaw cysts: 10 years of the WHO classification. *J Oral Pathol* 14:1-7, 1985.
8. Seddon RP, Fung DE, Barnard KM, Smith PB: Dentigerous cysts involving permanent incisors: four case reports. *Int J Paediat Dent* 2:105-11, 1992.
9. Seward GR: Treatment of cysts. In: *Cysts of the Oral Regions*, 3rd Ed. Shear M, Ed. Bristol: Wright PSG, 1992, pp 227-56.

Future Annual Sessions of the American Academy of Pediatric Dentistry

49th Annual Session

May 24-28, 1996

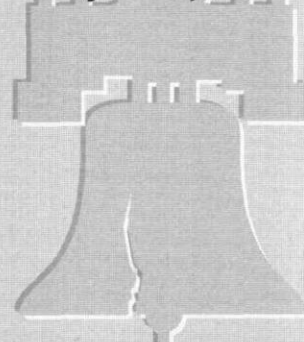


Chicago

Chicago Marriott Hotel

50th Annual Session

May 22-27, 1997



Philadelphia

Philadelphia Marriott Hotel

51st Annual Session

May 21-26, 1998



San Diego

San Diego Marriott Hotel & Marina

52nd Annual Session

May 27-June 1, 1999



Toronto

Sheraton Centre of Toronto Hotel & Towers