



## Delivering supplemental oxygen during sedation via a saliva ejector

Alan R. Milnes, DDS, PhD, FRCO, FICD

*Dr. Milnes is in private practice, Kelowna, British Columbia, Canada.  
Correspond with Dr. Milnes at [angelmanquiel@shaw.ca](mailto:angelmanquiel@shaw.ca)*

---

### Abstract

Intraoperative oxygen supplementation to sedated children has been shown to prevent hemoglobin desaturations even in the presence of apnea during pediatric conscious sedation. Although many practitioners deliver supplemental oxygen via a nasal hood, this method is impractical and often unsuccessful if the child is a mouth breather, has moderate adenotonsillar hypertrophy or occasionally cries during treatment (at which time there will be mouth breathing). This paper describes a method in which the saliva ejector is used to deliver supplemental oxygen to sedated children while they are receiving dental treatment. The advantages of this method and suggestions for its successful application are also included. (*Pediatr Dent.* 2002;24:340-342)

**KEYWORDS:** SEDATION, OXYGEN DELIVERY

---

*Received October 10, 2001    Revision Accepted March 11, 2002*

Respiratory compromise during the delivery of sedation for children who are receiving dental treatment is a significant concern. Inadequate oxygenation or hypoxemia can occur as a result of drug-induced respiratory depression from a decreased rate or depth of respiration or loss of protective airway reflexes secondary to the sedative drug effect. Probably the most common reasons for desaturation during sedation are either mouth breathing or airway obstruction due to large tonsils and/or adenoids.

Administering supplemental oxygen during sedation has been suggested as one method to reduce hemoglobin desaturation during dental treatment. Many practitioners provide supplemental oxygen through a nasal hood while coincidentally administering nitrous oxide. Although it is commonly understood when using nitrous oxide and oxygen for sedation that the child must be able to breathe through the nose, no reports of the impact of nasal vs oral breathing habits have been made in the many publications which document sedation regimens currently employed in pediatric dentistry. Rohlfsing et al<sup>1</sup> have shown that intraoperative oxygen supplementation prevents desaturations even in the presence of apnea during pediatric conscious sedation. However, Rohlfsing et al administered supplemental oxygen through nasal cannula which were also used for end tidal carbon dioxide sampling. Oxygen delivery via a nasal cannula or a nasal hood is successful when the child is breathing through the nose. However, should the child breathe

predominately through the mouth, oxygen supplementation using either of these delivery methods may be inadequate.

A significant amount of dental treatment in the author's practice is provided to children who receive sedative medications intravenously. A previous report has documented this intravenous sedation technique.<sup>2</sup> Each child who receives intravenous sedation undergoes a physical examination which targets the oral cavity, oropharynx, chest and upper airway. The upper airway assessment focuses on tonsil and adenoid size in relation to oropharyngeal volume,<sup>3</sup> as it has been shown by Fishbaugh et al<sup>4</sup> that the likelihood of airway blockage increases with enlarged tonsils. The child's ability to breathe through the nose and the mouth is also assessed both surreptitiously and on command.

The author's experience with intravenous sedation has confirmed that both mouth breathing and adenotonsillar hypertrophy can significantly affect oxygen saturation during conscious sedation, often resulting in desaturations despite head adjustment. Commonly employed procedures to open the airway—including head tilt-chin lift, jaw thrust or displacing the tongue in an anterior direction—while frequently effective in improving oxygenation and ventilation, often disturb the sedated child. This results in an increase in disruptive behavior, which, in turn, complicates the delivery of dental treatment.

Furthermore, these procedures are not always successful at improving oxygenation in the presence of mouth breathing.

**Table 1. The Effect of Oxygen Delivery via Saliva Ejector vs Nasal Hood or Nasal Cannula in 10 Cases in Which Tonsils Occupied 50% or More of the Oropharyngeal Volume or Where Children Were Obvious Mouth Breathers**

Subject	Age (mos)	Tonsil size*	O <sub>2</sub> saturation just before saliva ejector insertion	O <sub>2</sub> saturation after saliva ejector insertion
KT	32	>50%<75%	92	98
AR	49	>50%<75%	90	98
WS	58	>75%	88	99
JY	37	>50%<75%	91	97
RAF	68	>50%<75%	90	99
AS	39	>75%	92	98
RP	34	>75%	90	99
PY	44	>50%<75%	87	99
PQ	46	>50%<75%	87	98
SO	31	>50%<75%	89	97

\*Fishbaugh et al. *Pediatr Dent.* 1997;19:277-281

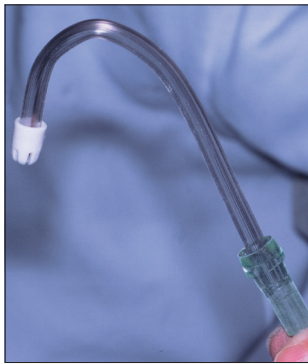

Fig 1. The saliva ejector attached to a standard oxygen hose and contoured for placement in the child's mouth

Although either a nasal cannula or a nasal hood are utilized to administer supplemental oxygen, the author has found these methods are ineffective at maintaining acceptable oxygen saturations in cases where the adenoids and tonsils occupy more than 50% of the oropharyngeal volume or in cases where the child obviously mouth breathes. Rather, the author has discovered that the common disposable saliva ejector adapts well for oxygen delivery, allowing oxygen saturations to be maintained at levels above 95%.

Table 1 summarizes oxygen saturation data for 10 children randomly selected from the author's practice charts, each of whom received dental treatment under intravenous sedation and demonstrated either mouth breathing behavior or had tonsillar/adenoid hypertrophy which was judged preoperatively to be a potential source of nasal airway obstruction. At the beginning of treatment in each case, oxygen was delivered via either nasal hood or nasal cannula.

In each case, when it was observed that oxygen saturations could not be maintained at acceptable levels despite (1) appropriate dosages of sedative medications, (2) demonstration of a patent airway via oral capnography and (3) determination that all other physiologic variables were within normal limits, oxygen supplementation via saliva ejector was initiated. The last column in Table 1 clearly shows that oxygen supplementation through a saliva ejector restored oxygen saturation levels in each case to an acceptable

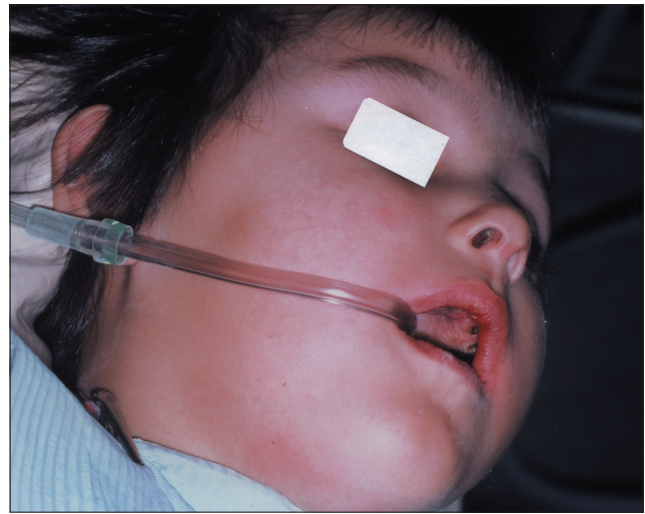

Fig 2. A child receiving intravenous sedation who is also receiving supplemental oxygen via a saliva ejector at a flow of 2 L/min. The rubber dam has been removed to show placement.

level. Administering oxygen through a saliva ejector which is, in turn, attached to a standard oxygen delivery hose (Fig 1) delivers oxygen more effectively than either a nasal cannula or a nasal hood in these cases and obviates the need for jaw thrust or tongue displacement.

The advantages of providing oxygen supplementation via a saliva ejector in these situations are numerous. All dental offices utilize saliva ejectors. Hence, they are readily available. Saliva ejectors are inexpensive and disposable. Saliva ejector size and structure has been standardized. Coincidentally, saliva ejectors fit oxygen hoses, which are commonly used in association with a full face mask to deliver supplemental oxygen. Saliva ejectors can be contoured and recontoured as required to remain in place under the rubber dam and out of the operative field (Fig 2). Moreover, they are much less irritating to a sedated children than a nasal cannula.

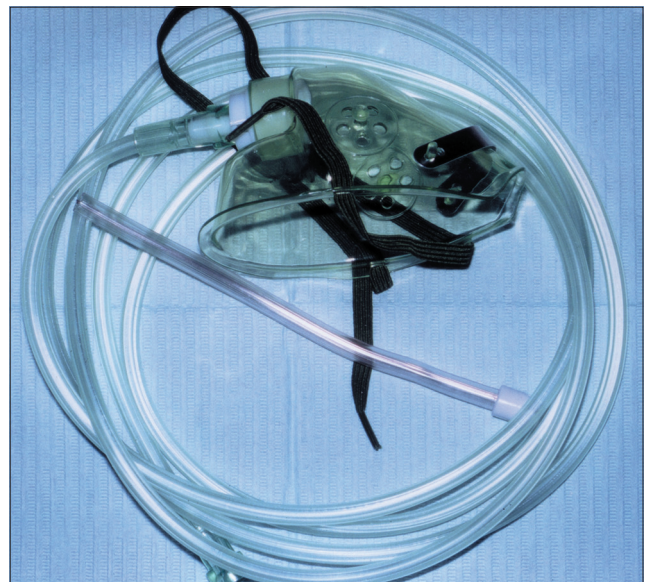


Fig 3. The saliva ejector and standard oxygen full face mask/hose assembly shown together. The face mask can be utilized postoperatively to deliver oxygen should it be necessary.

However, it is important to ensure that the tip of the saliva ejector is tightly attached so as to not dislodge in a child's mouth during use. In general, an oxygen flow of approximately 2 litres per minute is sufficient to maintain oxygen saturations above 95%. The only additional equipment required is a method of connecting the oxygen tank to the saliva ejector. Generic oxygen lines without face masks are available from most medical supply companies. However, removing the full face mask from a standard oxygen mask and hose assembly allows the line to be reattached to the face mask for delivery of oxygen postoperatively. This may be required when the child is recovering from sedation after dental treatment (Fig 3).

To utilize this technique, an oxygen outlet must be available to connect to the hose. In the author's situation, the manifold of the nitrous oxide and oxygen machine has been modified by adding an additional oxygen outlet with a flow meter capable of delivering up to 15 liters of oxygen per minute. However, a standard regulator for E-size oxygen tanks contains a similar oxygen port to which an oxygen hose could be attached for similar purposes.

An alternative method for oxygen delivery during sedation procedures for children who mouth breathe or have enlarged tonsils and/or adenoids has been presented. This method has been effective in all cases in which it has been employed. It requires a simple adaptation of equipment, which all practitioners who provide dental treatment to sedated children will already have in their offices.

### References

1. Rohlfsing GK, Dilley DC, Lucas WJ, Vann WF. The effect of supplemental oxygen on apnea and oxygen saturation during pediatric conscious sedation. *Pediatr Dent.* 1998;20:8-16.
2. Milnes AR, Maupomé G, Cannon J. Intravenous sedation in pediatric dentistry using Midazolam, Nalbuphine and Droperidol. *Pediatr Dent.* 2000; 22:113-119.
3. Brodsky L. Modern assessment of tonsils and adenoids. *Pediatr Clin North Am.* 1989;36:1551-1569.
4. Fishbaugh DF, Wilson S, Preisch JW, Weaver JM. Relationship of tonsil size on an airway blockage maneuver in children during sedation. *Pediatr Dent.* 1997; 19:277-281.

### ABSTRACT OF THE SCIENTIFIC LITERATURE



#### PREDICTORS OF SIGNS AND SYMPTOMS OF TEMPOROMANDIBULAR DISORDERS: A 20-YEAR FOLLOW-UP STUDY FROM CHILDHOOD TO ADULTHOOD

The purpose of this study was to analyze possible predictors of temporomandibular disorder (TMD) signs and symptoms reported at patients examined recently and the data obtained from records 20 years earlier. A detailed description of the subjects examined as well as the methods used were not presented in this article. Instead, the authors referred the reader to two previous papers where these were reportedly reviewed. Originally 402 seven-, 11- and 15-year-old subjects were randomly selected to receive a questionnaire on TMD symptoms, headaches, oral parafunctions and clinical signs of TMD and occlusal factors.

Three hundred and twenty of these same patients were located and received a second questionnaire when they were 27, 31 and 35 years of age, and the 35-year-old group was asked to participate in a clinical examination. Factors identified by various bivariate analyses found that tooth wear index was the strongest predictor for reported TMJ clicking at 20-year follow-up (odds ratio=4.3), while reported TMJ clicking at the start was the only significant predictor for TMD symptoms without clicking 20 years later (odds ratio=2.3). Bruxism, oral parafunctions, TMJ clicking and deep bite were also found to be significant predictors.

The authors concluded that some signs and symptoms might predict TMD signs and symptoms in a long-term perspective, but whether these symptoms recorded in childhood (oral parafunction, tooth wear, TMJ clicking and deep bite) can be used for predicting manifest TMD later in adults cannot be determined from this study.

**Comments:** The authors have used a longitudinal approach and attempted to take a very complex and difficult clinical entity and tease out potential factors by questionnaire and limited clinical examination, which could have an impact on the development of the symptoms of TMD in adulthood. Obviously, as the authors stated, more studies must be completed before a causal relationship can be established. **DARB**

Address correspondence to Dr. Gunnar E. Carlsson, Department of Prosthetic Dentistry/Dental Materials Science, Göteborg University, Box 450, SE-405 30 Göteborg, Sweden. g\_carlsson@odontologi.gu.se

Carlsson GE, Egermark I, Magnusson T. Predictors of signs and symptoms of temporomandibular disorders: a 20-year follow-up study from childhood to adulthood. *Acta Odontol. Scand.* 2002;60:180-185.

35 references