

# Ankylosed primary molars: Results and treatment recommendations from an eight-year longitudinal study

Louise Brearley Messer, B.D.Sc., L.D.S., M.D.Sc.  
Jay T. Cline, D.D.S., M.A.

## Abstract

*A total of 263 ankylosed primary molars in 107 children aged three to 12 years was studied for four years. Forty-six children remained in the study for eight years. Observation of affected dentitions showed that the condition was likely to recur. Three clinical patterns for the condition are described. Typically, maxillary molars became ankylosed earlier and demonstrated more severe infraocclusion than mandibular molars. Mandibular first molars usually remained slightly or moderately infraoccluded; mandibular second molars and maxillary first and second molars showed progressively severe infraocclusion. Following either extraction or exfoliation of the affected molars, the succedaneous bicuspid did not differ in either coronal morphology or in distribution of enamel surface defects from bicuspid preceded by non-ankylosed molars. Mandibular first molars usually exfoliated on schedule; failure to employ timed extraction for severely infraoccluded molars resulted in reduced alveolar bone support for the bicuspid. Treatment recommendations are developed based upon the molar type, clinical pattern, and the severity of infraocclusion.*

## Introduction

Dental ankylosis may be defined as an anatomical fusion of cementum with alveolar bone, occurring at any time during the course of eruption.<sup>1</sup> Occasionally, the tooth may become ankylosed prior to emergence into the oral cavity, or may ankylose during active eruption before contact is made with the opposing dentition.<sup>2</sup> Clinically, the crown is located below the occlusal plane, while the eruption of adjacent teeth

continues concomitantly with vertical alveolar bone growth,<sup>2,3</sup> and the tooth is immobile to manual rocking.<sup>4,5</sup>

The etiology of the condition remains unknown. Extrinsic causative factors implicated are local mechanical trauma,<sup>2</sup> disturbed local metabolism,<sup>2</sup> localized infection,<sup>6</sup> chemical or thermal irritation<sup>7</sup> and tooth reimplantation.<sup>8</sup> Intrinsic factors cited include a genetic or congenital gap in the periodontal ligament. Since both erupting and exfoliating teeth show alternating periods of resorption and deposition of bone and cementum,<sup>9</sup> aberrant deposition of these tissues may produce an area of ankylosing tissue.<sup>2,10</sup>

In a summary of studies reporting the prevalence of ankylosed primary molars, Andlaw (1974) described a range from 1.3% to 38.5%.<sup>11</sup> The differences were attributed to ethnic factors, and also to differing diagnostic criteria. Among healthy Caucasian children of predominantly Scandinavian descent residing in the Minneapolis-St. Paul area of Minnesota, we reported a prevalence of 6.9%.<sup>12</sup> Contrary to studies reporting the mandibular second primary molar to be most frequently affected,<sup>4,13,14</sup> our studies and others have implicated the mandibular first primary molar most frequently.<sup>12,15,16</sup> Multiple instances of ankylosis occur as frequently as single instances,<sup>17</sup> and a patient with one or two ankylosed teeth is likely to have other teeth become ankylosed later.<sup>10,17</sup> Radiographically, the zone of ankylosing tissue may not manifest as a localized obliteration of the periodontal ligament space, since the zone may be only a microscopic repair of cemental resorption by osteoid-like tissue continuous with the alveolar bone.<sup>18-20</sup>

The presence of ankylosed primary molar teeth may complicate the eruption and development of the

Accepted: December 3, 1979

permanent dentition. Typically, there is delayed exfoliation of affected teeth<sup>21</sup> with subsequent complications such as deflected eruption paths for adjacent or opposing teeth,<sup>2</sup> impaction of succedaneous bicuspid,<sup>2,11</sup> localized or generalized loss of needed arch length,<sup>21</sup> and tipping of adjacent teeth over the ankylosed primary molar or supraeruption of opposing teeth.<sup>11,21,22</sup> These sequelae may result in malocclusion.

In the past, the treatment of ankylosed primary molars has been largely empirical. Luxation,<sup>2</sup> restoring the tooth to occlusion with a variety of techniques and materials,<sup>22,23</sup> and extraction,<sup>2,20,21</sup> have all been utilized. While the literature contains many anecdotal reports of the relative success of these treatment approaches, clear documentation of indications, contraindications and possible sequelae is lacking. In order to develop more rational bases for treatment, a two-part clinical investigation comprising a short-term (four-year) study and a long-term (eight-year) study was designed. A group of affected dentitions was followed longitudinally with periodic examinations, radiographs and study models, until complete eruption of all bicuspid, permanent cuspids, and permanent second molars. No attempt was made by the investigators to dictate treatment of the ankylosed molars by the attending dentists in order that currently-employed treatment regimes would be used unhindered.

## Study Design

### Study Population

A total of 107 healthy Caucasian children of predominantly Scandinavian descent, ranging in age from three to 12 years and possessing one or more ankylosed primary molars, was studied in the Pediatric Dentistry Clinic of the University of Minnesota School of Dentistry. Using periodic clinical and radiographic observations, the history of each ankylosed primary molar (test molar), and non-ankylosed primary molar in each dentition was followed and observations recorded on these teeth and their succeeding bicuspid.

The majority of children received their dental care throughout the study at the clinics of the University of Minnesota School of Dentistry; the remainder attended private dentists for regular dental care. In all instances, the ankylosed molar either was observed periodically, or extracted and appropriate space maintenance instituted. No tooth was treated by luxation; only ankylosed teeth with congenitally-missing bicuspid were restored to occlusion with stainless steel crowns.

## Purposes of Short-Term and Long-Term Studies

The purpose of the short-term study was to elucidate the characteristics of ankylosis of individual molars, with respect to age at diagnosis, severity of infraocclusion, and distribution of the condition.

Dentitions in the long-term study were used to study the sequelae of ankylosis with respect to over-retention of the primary molar, and the clinical and radiographic appearance of the succeeding bicuspid in comparison with other bicuspid preceded by non-ankylosed primary molars in the same dentitions.

## Diagnosis of Ankylosis

The diagnosis was based upon two essential criteria:

- (1.) The entire occlusal surface of the primary molar was located at least 1 mm below the expected occlusal plane as judged from the nearest adjacent non-ankylosed teeth in the same quadrant.<sup>5</sup>
- (2.) The molar was immobile when subjected manually to a rocking movement,<sup>4</sup> in contrast to other (non-exfoliating) primary molars in the dentition.

The emission of a sharp clear sound on percussion was not an essential criterion because of its subjectivity.<sup>19</sup> Radiographic evidence of bony union was not required because of its variability.<sup>12</sup>

## Distribution of Primary Molars

The short-term study group comprised 107 dentitions (45 males; 62 females) which at first examination contained a total of 191 ankylosed molars (Table 1). The group included six sibships each containing two affected children. Thirty-five dentitions each contained a single ankylosed molar and 72 dentitions each showed two or more affected molars. The 107 dentitions were studied for four years, during which time 31 dentitions (29%) showed a recurrence of ankylosis involving a further 72 primary molars (Table 1).

Thereafter, the long-term study group contained 46 dentitions (23 males; 23 females; three sibships each with two affected children) totalling 116 ankylosed molars (Table 1). These were followed for eight years. No additional diagnoses were made during the second four years of the study. For this group, the bicuspid preceded by non-ankylosed primary molars in the same dentitions were pooled as a comparison group. These teeth were distributed as follows: mandibular first: 28; mandibular second: 48 (a further three teeth were congenitally absent); maxillary first: 86; and maxillary second: 86 (a further two teeth were congenitally missing). Since many of the dentitions had contralateral molars affected with

**Table 1. Distribution of ankylosed primary molars in 107 affected dentitions (short- and long-term studies)**

Study	Time of diagnosis	No. Ankylosed Primary Molars				Total
		Md 1st	Md 2nd	Mx 1st	Mx 2nd	
Short term	at first exam	131	37	16	7	191
	at later exam	18	40	5	9	72
Total		149	77	21	16	263
Long term	at first or later exam	64	41	7	4	116

ankylosis, teeth could not be pair-matched for comparisons. Therefore, the findings for each group of ankylosed molars were compared with those for the corresponding group of pooled non-ankylosed molars.

## Data Collected in Short-Term Study

### Age at Diagnosis of Primary Molar Ankylosis

The age of each child at the time of diagnosis of each ankylosed molar was recorded, based on clinical observations and from existing clinical and radiographic records maintained by the clinic before commencement of the study.

### Extent of Infraocclusion

Using study models, the extent of infraocclusion of each ankylosed molar was classified at diagnosis as one of the following:

- Slight: The entire occlusal surface was located approximately 1 mm below the expected occlusal plane as judged from the two nearest non-ankylosed teeth in the same quadrant.
- Moderate: The entire occlusal surface was located with both marginal ridges approximately level with, or just cervical to, the contact area of one or both adjacent tooth surfaces. In instances of ankylosis of two adjacent primary molars, the contact area of the first secondary molar was used for reference.
- Severe: The entire occlusal surface was located level with or below the interproximal gingival tissue of one or both adjacent tooth surfaces.

### Distribution Characteristics of Ankylosis

Sequential study models for each child were ex-

amined in order to identify distribution characteristics for the condition.

## Data Collected in Long-Term Study

### Overretention of Ankylosed Primary Molars

A molar was deemed overretained if it was still in position, and immobile, after the contralateral non-ankylosed primary molar had exfoliated. An ankylosed molar which became mobile close to the expected exfoliation time was not considered overretained. In instances of ankylosis of a contralateral pair of molars, reference was made to tables of chronology,<sup>24</sup> in conjunction with an examination of the eruption sequence for the particular dentition and the status of root development of the succedaneous bicuspid.

### Clinical, Radiographic, Occlusal and Periodontal Observations on Bicuspid

When all bicuspid, permanent cuspids and permanent second molars were fully erupted, each bicuspid was air-dried and examined clinically using a mirror and explorer\* for the following: coronal and radicular morphology, hypoplasia and hypomineralization, coronal position, and rotation. The periodontal tissues were examined clinically and radiographically for evidence of pocket-formation, lamina dura thickening, and alveolar bone loss. Observations were made independently by both authors, each unaware of whether the bicuspid was preceded by an ankylosed or non-ankylosed molar. Positive findings were recorded only when there was unanimity between examiners using the following criteria:

#### Coronal and radicular morphology:

The morphological features of contralateral teeth were compared with each other and with those described by Wheeler (1974),<sup>25</sup> and any marked differences recorded.

\* No. 5DE explorer, Hu Friedy Manufacturing Co., Chicago, Illinois 60618.

**Table 2. Extent of infraocclusion of 263 ankylosed primary molars at initial diagnosis (short-term study)**

<i>Infraocclusion</i>	<i>No. Ankylosed Molars (%)</i>				<i>Total</i>
	<i>Md 1st</i>	<i>Md 2nd</i>	<i>Mx 1st</i>	<i>Mx 2nd</i>	
Slight	111 (75)	36 (47)	9 (43)	6 (37)	162
Moderate	36 (24)	32 (41)	10 (48)	7 (44)	85
Severe	2 (1)	9 (12)	2 (9)	3 (19)	16
<b>Total</b>	<b>149</b>	<b>77</b>	<b>21</b>	<b>16</b>	<b>263</b>

*Hypoplasia:*

Non-hereditary hypoplasia was defined after Sicher (1962)<sup>26</sup> as localized, circumscribed pitting, furrowing or absence of enamel which may or may not be associated also with hypomineralization.

*Hypomineralization:*

Non-fluorotic surface enamel defects of hypomineralization were asymmetrical round or oval lesions clearly differentiated from adjacent normal enamel and often creamy yellow or brown in color on normally contoured enamel surfaces.<sup>27</sup> Very mild fluorosis was defined after Russell (1961)<sup>27</sup> as symmetrical small spots or minute, lacy, horizontal lines generally following the incremental lines of enamel development and imperceptibly demarcated from normal enamel and of a "paper white" color. The cusp tips may have a frosted appearance and the condition usually affects the incisal or occlusal half, or more, of contralateral teeth. The enamel is smooth to an explorer.

*Coronal malposition:*

A bicuspid was deemed malpositioned if the entire crown was placed buccally, lingually or in infraocclusion from the expected position of that tooth in the dental arch contour.

*Coronal rotation:*

This was classified as none, slight, moderate or severe, based upon the extent of deviation of the tooth from its expected angulation between the two adjacent teeth, judging on the positioning of the mesial marginal ridge. A bicuspid was deemed slightly rotated if the position of this ridge was deviated, but less than 20°, to either the buccal or lingual of its expected position between the adjacent teeth. If the mesial marginal ridge was deviated by more than 20°, but less than 90°, to either the buccal or lingual, the bicuspid was deemed moderately rotated; a bicuspid rotated 90° or more from its expected position was deemed severely rotated.

*Periodontal pocket formation:*

Periodontal pocket depth was measured beneath

the mesial and distal contact areas using a periodontal probe.\*

*Thickening of lamina dura:*

Thickening of the lamina dura was diagnosed from intraoral radiographs based on the description of Goldman and Cohen (1973).<sup>28</sup>

*Alveolar bone loss:*

Vertical and horizontal bone loss was diagnosed from intraoral radiographs, based on the description of Goldman and Cohen (1973).<sup>28</sup>

A comparison of the binomial distributions<sup>29</sup> was used to test for any statistically significant difference between the distributions of observations for bicuspids preceded by ankylosed and non-ankylosed molars.

**Results of Short-Term Study**

**Age at Diagnosis of Primary Molar Ankylosis**

The mean ages at diagnosis were as follows: mandibular first molar: 7.1 (range 5.2 - 9.2 yrs.); mandibular second molar: 8.0 (range 5.1 - 10.4 yrs.); maxillary first molar: 6.2 (range 4.7 - 8.6 yrs.); maxillary second molar: 4.6 (range 3.0 - 9.4 yrs.). The diagnosis of ankylosis of the maxillary first molars frequently coincided with the eruption of the maxillary first permanent molar. For several of the maxillary second molars in the study, the apparent failure of complete eruption of this tooth was the reason for the patient presenting to the clinic. For all other ankylosed molars, the parents were unaware of the condition until it was brought to their attention.

**Extent of Infraocclusion**

Most maxillary first and second primary molars were in moderate or severe infraocclusion when diagnosed (Table 2). These teeth tended to show a relatively rapid progression toward more severe infraocclusion. Mandibular first molars were only slightly

\* No. 0 periodontal probe, Hu Friedy Manufacturing Co., Chicago, Illinois 60618.

**Table 3. Three clinical patterns of primary molar ankylosis in 107 dentitions diagnosed over four-year observation period (short-term study)**

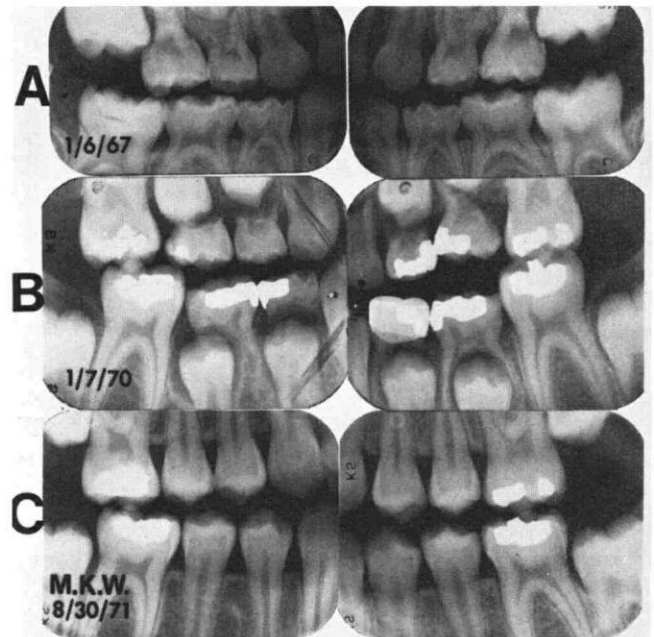
Ankylosis Pattern	Arch	Distribution (no. dentitions)	Total dentitions (%)
I Molar Pair	Mand	1 contralateral pair (29) 2 contralateral pairs (15) 1 adjacent pair (2)	48 (45%)
	Max	1 contralateral pair (2)	
II Single Molar	Mand	1st molar (24) 2nd molar (6)	35 (33%)
	Max	1st molar (4) 2nd molar (1)	
III Multiple Molars	Mand	3 teeth—1 pair plus 1 single (8)	24 (22%)
	and	4 teeth—1 pair plus 2 singles (5)	
	Max	5 teeth—2 pairs plus 1 single (9)	
		6 teeth—3 pairs (1) 7 teeth—3 pairs plus 1 single (1)	

affected (Table 2) and rarely became more severely infraoccluded, whereas most mandibular second molars showed a progressive development of more severe infraocclusion. No molar which became ankylosed late in the development of the succedaneous bicuspid became severely involved and these usually remained in slight or moderate infraocclusion.

Figure 1 shows the intraoral radiographs of one patient over a 55-month period. This patient illustrates several salient features of molar ankylosis. The first radiographs (Figure 1A) show slight infraocclusion of the mandibular left and right first primary molars. Interproximal lesions in these teeth were restored with amalgam (one tooth also later received a stainless steel crown) and both teeth later exfoliated on schedule. Meanwhile, the mandibular left and mandibular right second primary molars became moderately ankylosed (Figure 1B), as did the maxillary left second primary molar (perhaps following the ectopic eruption of the adjacent first permanent molar). The maxillary second primary molar was extracted and a space maintainer placed; the mandibular second molars exfoliated on schedule. A root fragment of the mandibular right second primary molar remained (Figure 1C), probably related to the unequal resorption pattern of the mesial and distal roots.

#### Distribution Characteristics of Ankylosis

Three clinical patterns for the condition were apparent (Table 3). The most frequently occurring was Pattern I (48 dentitions, or 45%) where one or more contralateral molar pairs, or an adjacent pair of molars, were ankylosed. A single molar, Pattern II, was



**Figure 1.** A series of bitewing radiographs of a Caucasian female showing progression of primary molar ankylosis. (A) Note slight infraocclusion of mandibular first primary molars and ectopic eruption of the maxillary left first permanent molar. (B) Note loosening of mandibular first primary molars, moderate infraocclusion of the mandibular second primary molars with an unequal resorption pattern of the roots of the mandibular right second primary molar, and moderate infraocclusion of the maxillary left second primary molar. (C) All bicuspid are fully erupted. Note the residual primary molar root fragment mesial to the mandibular right second bicuspid.

affected in 35 dentitions (33%). Pattern III comprised multiple ankylosed molars ranging from three to seven affected teeth (24 dentitions, or 22%). This pattern was viewed as a combination of one, two, or three molar pairs (as Pattern I), plus one or more single occurrences in any quadrant.

## Results of Long-Term Study

### Overretention of Ankylosed Primary Molars

The treatment histories are summarized in Table 4. Most mandibular first molars exfoliated on schedule, and none left residual root fragments. Mandibular second molars were less prone to exfoliation; residual root fragments were shown by two molars that exfoliated and by four molars that were extracted ahead of exfoliation. None of the 11 maxillary molars that were extracted early left root fragments. Five mandibular second molars without permanent successors were restored with stainless steel crowns. During the observation period, these teeth became severely infraoccluded and radiographically showed extensive replacement of the periodontal ligament with mineralized tissue. Periodic replacement of the crowns was required to maintain occlusion. Eventually, orthodontic treatment was instituted for one child and the tooth was extracted surgically.

### Clinical and Radiographic Appearance of Bicuspid

Table 5 summarizes the clinical and radiographic appearance of the test bicuspid.

Among test mandibular bicuspid, hypoplasia and/or hypomineralization defects were seen in 25 of the 64 (39%) first bicuspid and in eight of the 36 (22%) second bicuspid. In all instances, similar multiple enamel surface defects were seen in other bicuspid in the same dentition, and in no instance could the defects be clearly attributed to ankylosis of the preceding primary molar or to the treatment procedure (observation until exfoliation, or extraction) that had been followed. Very mild fluorosis was seen in 40% of the 46 dentitions studied.

On radiographic examination, four test bicuspid showed "V"-shaped notching of the root outline, located in the middle one-third. In three instances, the preceding primary molar had been overretained and extracted. Of bicuspid preceded by non-ankylosed molars, none showed "V" root notching. The distribution of apical root flexion did not differ significantly between bicuspid preceded by ankylosed or non-ankylosed primary molars.

### Occlusal Observation on Bicuspid

The occlusal observations for test bicuspid are shown in Table 5. Among mandibular first bicuspid, four test teeth (6%) and three unaffected bicuspid (11%) were in infraocclusion; the difference was not statistically significant. Inadequate mesiodistal space was present for 35 test mandibular first bicuspid (55%) and for 15 unaffected mandibular first bicuspid (54%). This difference was not statistically significant. A total of 58 (90.6%) test mandibular first bicuspid showed coronal rotation (slight: 41 teeth, moderate: 17 teeth, severe: none); among unaffected bicuspid, only three (11%) were rotated. Statistically, test mandibular first bicuspid were significantly more frequently rotated than unaffected mandibular first bicuspid ( $Z=7.4672$ ;  $p<0.01$ ).

Among test mandibular second bicuspid, four teeth (11%) were in infraocclusion. This distribution did not differ significantly from that of unaffected mandibular second bicuspid (four teeth or 8% were in infraocclusion). Eleven test mandibular second bicuspid (30%) and four unaffected bicuspid (8%) showed inadequate mesiodistal space. This difference was statistically significant ( $Z=2.6327$ ,  $p<0.01$ ). The distribution of rotated mandibular second bicuspid in the test group (21 rotated or 58%) did not differ significantly from that of the unaffected group (29 rotated or 60%).

None of the eleven test maxillary bicuspid were infraoccluded; one showed mesiodistal space inadequacy and four teeth were rotated. These sample sizes were deemed too small for statistical comparison with unaffected maxillary bicuspid.

### Periodontal Observations on Bicuspid

The periodontal observations on the test bicuspid are shown in Table 5. Among the 64 test mandibular first bicuspid, none of those preceded by first primary molars exfoliating on schedule showed any unusual findings. Of the 11 in the extraction group, the two bicuspid preceded by overretained mandibular first molars both showed periodontal pocketing (3-4 mm), thickening of the lamina dura and inadequate vertical alveolar bone height. The latter two observations were also recorded for one mandibular first bicuspid preceded by a primary molar which was extracted early. None of the unaffected mandibular first bicuspid showed these periodontal findings.

Among the 16 test mandibular second bicuspid in the exfoliation group, one bicuspid showed pocket formation (3-4 mm) and this tooth, plus a second bicuspid in the same group, showed inadequate vertical alveolar bone height. Reduced alveolar bone height was also shown by a further three bicuspid in the

**Table 4. Treatment history for 116 ankylosed molars in 46 affected dentitions (long-term study)**

<i>Treatment History</i>	<i>No. Ankylosed Primary Molars (%)</i>				<i>Total</i>
	<i>Md 1st</i>	<i>Md 2nd</i>	<i>Mx 1st</i>	<i>Mx 2nd</i>	
Exfoliated on schedule	53 (83)	16 (39)	0	0	69
Extracted before exfoliation time	9 (14)	15 (37)	7 (100)	4 (100)	35
Overretained and extracted	2 ( 3)	5 (12)	0	0	7
Occlusion restored with steel crown*	0	5 (12)	0	0	5
<b>Total</b>	<b>64</b>	<b>41</b>	<b>7</b>	<b>4</b>	<b>116</b>

\* Five mandibular second bicusps were congenitally missing.

**Table 5. Coronal, radicular and periodontal observations on 111\* bicusps preceded by ankylosed primary molars in 46 affected dentitions (long-term study)**

<i>Observation</i>	<i>No. Affirmative Observations on Bicusps</i>						<i>Total (n=111)</i>
	<i>Mand 1st</i>		<i>Mand 2nd</i>		<i>Mx 1st Mx 2nd</i>		
	<i>Exfoliated† (n=53)</i>	<i>Extracted†† (n=11)</i>	<i>Exfoliated (n=16)</i>	<i>Extracted (n=20)</i>	<i>Extracted (n=7)</i>	<i>Extracted (n=4)</i>	
<b>Crown</b>							
hypoplasia	2	1	0	1	0	0	4
hypomineralization	17	5	5	2	0	0	29
<b>Root</b>							
"v" notching	1	1	0	2	0	0	4
apical flexion	8	2	1	2	1	0	14
<b>Occlusion</b>							
infraocclusion	2	2	2	2	0	0	8
m-d space inadequate	30	5	4	7	1	0	47
rotation	47	11	13	8	3	1	83
<b>Periodontal</b>							
pocket formation	0	2	1	1	1	0	5
lamina dura thickened	0	3	0	0	1	0	4
alveolar bone loss	0	3	2	4	1	0	10

\* Only 111 of the 116 teeth are shown since five mandibular second bicusps were congenitally absent.

† Preceding primary molar exfoliated on schedule.

†† Preceding primary molar extracted either before exfoliation time or following overretention.

late extraction group. None of the unaffected mandibular second bicuspid showed similar periodontal findings. Of the eleven test maxillary bicuspid, periodontal pathology was seen for one maxillary first bicuspid. The periodontal pocket depth was 3-4 mm. None of the unaffected maxillary bicuspid showed periodontal pocket formation, lamina dura thickening or alveolar bone discrepancy.

## Discussion

### Characteristics of Ankylosed Molars

As shown previously,<sup>12,15</sup> the mandibular first primary molar was the tooth most frequently affected by ankylosis in the present study. Since this tooth usually shows only slight and rarely moderate infraocclusion, and typically exfoliates on schedule, the diagnosis of ankylosis may be missed. Consequently, it is not surprising that the mandibular second molar, which is usually in more severe infraocclusion, has been considered to be the tooth most frequently affected by ankylosis.<sup>4,13,14</sup> In the present study, maxillary molars were affected less frequently than mandibular molars, and the maxillary second molar least of all, confirming the observations of many other surveys on this aspect of ankylosis.<sup>4,12-15</sup>

The present study appears to be one of very few examining the time of diagnosis of ankylosis.<sup>15,16</sup> Since a criterion for inclusion of the dentition in the study was the presence of at least one tooth already ankylosed, the actual onset of the condition for these teeth cannot be determined. Also, the diagnostic criteria are applicable only after the tooth has begun to manifest the condition clinically, and presumably the cellular changes occur considerably in advance of the clinical picture. Nevertheless, the approximations made in the present study serve to show that the four different primary molars are prone to ankylose at various times and that these are usually quite typical for each molar.

Maxillary primary molars tended to ankylose early, either before the eruption of the maxillary first permanent molar (as was shown by most of the second primary molars studied) or at approximately the same time as the maxillary first permanent molar erupted (as seen for most of the maxillary first primary molars studied). Mandibular primary molars tended to ankylose later than maxillary molars, the mean age of diagnosis for mandibular first molars being 7.1 years and 8.0 years for mandibular second molars. The majority of the mandibular first molars became ankylosed soon after the eruption of the first permanent molar in the same quadrant, but this was unusual among mandibular second molars. Ankylosis of mandibular first molars did not appear to occur

subsequent to ankylosis of the mandibular second molar in the same dentition, but there was a high incidence of ankylosis of the latter tooth subsequent to involvement of the former. Owen<sup>1</sup> has observed that ankylosis of maxillary molars usually occurs coincident with involvement of opposing mandibular molars, and this is supported by the present observations where 30 of the 37 ankylosed maxillary molars were present in dentitions which also showed mandibular involvement. However, it is not an invariable finding as there were seven instances of affected maxillary molars where no mandibular molar was involved either initially, or on longitudinal study.

The present study indicates that individual molars tend to show a somewhat typical pattern of severity. In comparison with mandibular molars, maxillary molars tend to show severe, early involvement and the relative severity may be partially reflecting a spurt of alveolar bone growth coincident with the eruption of the maxillary first permanent molars. The relative slightness of the typical infraocclusion of the affected mandibular first primary molar may reflect, in part, a lessened increment in vertical alveolar bone growth occurring in the cuspid-first molar region prior to the exfoliation time of the first primary molar.

The decided tendencies seen toward multiple occurrences, contralaterally affected teeth, and lack of predilection for the side of the arch first affected, confirm previous studies.<sup>4,14,19</sup> In the present study, only 35 of the 107 dentitions (33%) in the four-year study showed ankylosis limited to a single molar, and the remaining 72 dentitions (67%) each contained two or more ankylosed molars totaling 228 affected teeth. The teeth were distributed in three distinct clinical patterns which serve to indicate where a contralateral occurrence of the condition is likely to occur, and provide a basis for treatment recommendations, as described below. Contralateral occurrences are more likely in the mandibular arch than in the maxillary, and single occurrences are more likely to occur in the maxillary than in the mandibular arch.

### Characteristics of Succedaneous Bicuspid

The present study indicates that the presence of a preceding ankylosed primary molar is not likely to affect coronal morphology or to initiate coronal hypoplasia and/or hypomineralization of the succeeding bicuspid. This lends support to the opinion of Kollar (1972)<sup>30</sup> that the morphological template of the crown is established very early in embryological development and is not readily altered. For the majority of the ankylosed teeth studied in the present report, the crowns of the succedaneous bicuspid were already fully formed at the time described as the first clinical diagnosis of the condition. Presumably the



cellular changes involved in the process of ankylosis had no effect on the coronal tissues of the forming succedaneous tooth. The lack of an increased prevalence of enamel surface defects in the succeeding bicuspid is in contrast to the findings of Rule, Zacherl and Pfefferle (1972).<sup>31</sup> In a sample of 262 bicuspid succeeding ankylosed primary molars, these workers described a statistically significant increase in the number of enamel surface defects over those seen in control bicuspid and speculated on a correlation between ankylosis and the coronal abnormalities. The present study examined a larger sample of children with ankylosed teeth, and also identified that 40% of the dentitions demonstrated very mild fluorosis. This could have masked additional enamel defects of a non-fluorotic origin.

No clear association was found in the present study between apical flexion of the roots of succeeding bicuspid and "V"-shaped notches in the root peripheries, and ankylosis of the preceding molars. Notching of the root outline on a radiograph is an equivocal finding since the appearance of the root outline is largely dependent upon the radiographic technique employed. These observations support the conclusion of Steigman, Koyoumdjisky-Kaye and Matrai (1974), that ankylosed teeth usually have no causative influence on the rate of development of their successors.<sup>32</sup>

Examination of the occlusion of the succedaneous bicuspid suggests that those preceded by an ankylosed primary molar are more likely to demonstrate inadequate mesiodistal space and to show coronal rotation. Although these differences were demonstrated to be significant statistically, it cannot be concluded to be more than a trend since the entire occlusion of the affected dentitions was not evaluated. In addition, the bicuspid used for comparison were located in the same dentitions which showed ankylosed teeth, thereby introducing a bias into the statistical treatment of the data.

Bicuspid succeeding ankylosed primary molars appear more likely to exhibit periodontal pathology (and particularly if the molar was overretained or required extraction) than bicuspid succeeding non-ankylosed molars. The lack of vertical alveolar bone height coupled with periodontal pocket formation is thought to be due to a failure of alveolar bone development which normally occurs with exfoliation of the primary tooth and eruption of the permanent tooth. An ankylosed primary molar is retained at its vertical position by the ankylosing tissue while adjacent teeth continue to move occlusally with appositional alveolar bone growth. The impedance of primary tooth movement serves to restrict vertical alveolar bone deposition, hence there may be a reduced amount of bone surrounding the bicuspid.

## Prognosis and Treatment Recommendations

The present investigation did not seek to evaluate comparatively the efficacy of several treatment regimens for ankylosed molars. Instead, the study sought to observe the consequences of the three treatment approaches (observation; extraction; restoration to occlusion) utilized by the attending dentists. The literature reveals widely divergent opinions on the treatment of ankylosed primary molars. Hovell (1966)<sup>33</sup> stated that most cases require no treatment other than observation, while others recommend surgical extraction as the usual treatment on the basis that ankylosed teeth neither exfoliate nor allow the eruption of the succeeding permanent teeth.<sup>9,34-35</sup> Andlaw (1974)<sup>11</sup> has developed a more conservative series of treatment recommendations based upon the extent of infraocclusion of the affected tooth. The present study adds to those recommendations by taking into consideration also the three clinical patterns of ankylosis described and the recognized ankylosis characteristics for each type of primary molar.

The findings of the present study suggest that the majority of ankylosed mandibular first primary molars can be expected to become involved after the eruption of the mandibular first permanent molar, and that the condition is likely to become bilateral. Ankylosis of other primary molars in the dentition is likely, especially of the mandibular second primary molars. The first primary molar is likely to demonstrate only slight, progressing but occasionally to moderate, infraocclusion and can be expected to loosen and exfoliate on schedule. This expectation confirms the observations of Steigman *et al.*<sup>15</sup> on the ankylosis characteristics of the mandibular first primary molar. For these teeth, it is assumed that during the normal process of exfoliation, the ankylosing tissue is resorbed, allowing the tooth to become mobile and exfoliate.<sup>10</sup> Rarely is extraction or exfoliation of this tooth followed by residual root fragments. Therefore, the clinician is recommended to monitor dentitions with ankylosed mandibular first molars by employing study models and space measurements, and to extract these teeth only if they are severely infraoccluded and space loss is imminent. If supraeruption of opposing teeth appears imminent, restoration of the occlusal surface to full vertical dimension could be considered.

The ankylosed mandibular second primary molar is likely to be affected bilaterally, and onset is likely to occur later than that of the mandibular first primary molar. With time, mandibular second molars tend to become progressively more severely infraoccluded than mandibular first molars. Mesial tipping of the adjacent first permanent molar over the occlusal surface of the affected tooth may occur, resulting in loss of arch length. Failure to monitor these teeth

can result in overretention of the molar and a localized lack of vertical alveolar bone. Ankylosed mandibular second molars should be kept under close observation with study models and arch length measurements. Extraction should be performed if the tooth becomes moderately infraoccluded and/or mesial tipping of the mandibular first permanent molar is imminent, or if the molar fails to exfoliate on schedule for that dentition. A passive lower lingual arch is a useful space maintainer in the former situation. Following either extraction or exfoliation of the mandibular second molar, the area should be examined closely for root fragments as these may occur following the typically uneven resorption of the mesial and distal roots.

Restoration of singly affected mandibular molars showing only slight infraocclusion with built-up restorations or stainless steel crowns appears to be a useful interim treatment during the mixed dentition period. There must be a permanent successor present and both the vertical and mesiodistal dimensions of the crown of the ankylosed tooth need to be maintained adequately. Active vertical alveolar bone growth related to the adjacent unaffected teeth is likely to necessitate the periodic replacement of the restoration. If however, the primary molar is in moderate or severe infraocclusion, the vertical alveolar bone growth may be hindered and lead to a poor periodontal prognosis for the succeeding bicuspid. For such teeth, extraction and appropriate space maintenance is recommended.

In instances where the primary molar is ankylosed and the permanent molar is congenitally absent, early orthodontic and prosthodontic consultations should be sought concerning the long-term treatment of the dentition. While the vertical and mesiodistal dimensions of the ankylosed molar can be maintained with restorations throughout the mixed dentition, such restorations can only be considered of interim nature. Also, after the permanent dentition is established, the steady remodelling throughout life of alveolar bone supporting adjacent teeth is likely to require periodic replacement of such built-up restorations. Biederman (1968)<sup>2</sup> has observed that because of cessation of alveolar bone growth in the immediate area of the ankylosed tooth, the roots of adjacent teeth may become denuded of bone and the tooth lost. Such long-term restorative and periodontal consequences suggest that early consideration be given to extraction of the ankylosed tooth and space closure instituted in conjunction with orthodontic treatment of the dentition.

The findings of the present study suggest similar approaches to treatment for both maxillary first and second primary molars. Maxillary second primary molars tend to show a relatively fast progression towards

severe infraocclusion, with an onset which may precede the eruption of the adjacent first permanent molar. Maxillary first primary molars also tend to increasingly severe infraocclusion and the onset may occur close to the time of eruption of the first permanent molar. Additional ankylosed molars in the mandibular arch are likely to follow. The obvious severity of the ankylosis of the maxillary primary molars in the present long-term study clearly indicated the need for early extraction. It is likely that failure to extract these teeth would have resulted in tipping of adjacent non-ankylosed teeth and consequent loss of arch length and inadequate vertical alveolar bone growth leading to compromised periodontal support for the succeeding bicuspid. Regardless of the severity of the infraocclusion, it is recommended that ankylosed and immobile maxillary molars be extracted as early as appears feasible. Since such extractions frequently require a surgical removal of the tooth on a child aged seven years or under, appropriate consideration should be given to the behavior management of the child. In our experience, a distal shoe space maintainer is a useful appliance in the situation where an ankylosed maxillary second primary molar requires extraction prior to the eruption of the adjacent first permanent molar.

It is recommended that the treatment of dentitions with multiple ankylosed teeth be treated by employing a combination of the approaches recommended above for individual molars. Siblings in the family should also be monitored, since a familial tendency for the condition has been reported.<sup>5,12</sup>

#### Acknowledgments

The assistance of Drs. David McKibben and John Hinding in the initial clinical phases of this study is gratefully acknowledged. This study was supported in part by a Biomedical Research Support Grant from the National Institutes of Health.

---

#### References

1. Owen, T. L.: "Ankylosis of Teeth," *J Mich State Dent Assoc*, 47:347-350, 1965.
2. Biederman, W.: "The Problem of the Ankylosed Tooth," *Dent Clin North Am*, July, 409-424, 1968.
3. Darling, A. I. and Levers, B. G. H.: "Submerged Human Deciduous Molars and Ankylosis," *Arch Oral Biol*, 18: 1021-2040, 1973.
4. Biederman, W.: "Etiology and Treatment of Tooth Ankylosis," *Am J Orthod*, 48:670-684, 1962.
5. Via, W. F.: "Submerged Deciduous Molars: Familial Tendencies," *J Am Dent Assoc*, 69:127-129, 1964.
6. Adamson, K. T.: "The Problem of Impacted Teeth in Orthodontics," *Aust J Dent*, 56:74-84, 1952.
7. Atrizadeh, F., Kennedy, J., and Zander, H.: "Ankylosis of Teeth Following Thermal Injury," *J Periodont Res*, 6:159-167, 1971.

8. Finn, S. B.: *Clinical Pedodontics*, 4th Ed., Philadelphia: W. B. Saunders Co., 1973, p. 259.
9. Boyle, P. E., ed.: *Histopathology of the Teeth and Their Surrounding Structures*, 4th Ed., Philadelphia: Lea and Febiger, 1955, p. 276.
10. Henderson, H. Z.: "Ankylosis of Primary Molars: A Clinical, Radiographic, and Histologic Study," *J Dent Child*, 46:117-122, 1979.
11. Andlaw, R. J.: "Submerged Deciduous Molars: A Review, With Special Reference to the Rationale of Treatment," *Int Assoc Dent Child*, 5:59-66, 1974.
12. Brearley, L. J. and McKibben, D. H.: "Ankylosis of Primary Molar Teeth, I Prevalence and Characteristics; II Longitudinal Study," *J Dent Child*, 40:54-63, 1973.
13. Dixon, D. A.: "Observations on Submerged Deciduous Molars," *Dent Pract Dent Rec*, 13:303-316, 1963.
14. Lamb, K. A. and Reed, M. W.: "Measurement of Space Loss Resulting From Tooth Ankylosis," *J Dent Child*, 35:483-486, 1968.
15. Steigman, S., Koyoumdjisky-Kaye, E., and Matrai, Y.: "Submerged Deciduous Molars in Preschool Children: An Epidemiologic Survey," *J Dent Res*, 52:322-326, 1973.
16. Krakowiak, F. J.: "Ankylosed Primary Molars," *J Dent Child*, 45:288-292, 1978.
17. Brearley, L. J. and McKibben, D. H.: "A Longitudinal Study of Ankylosed Primary Molar Teeth," *IADR Abstr*, No. 678, 1972.
18. Noyes, F. B.: "Submerging Deciduous Molars," *Angle Orthod*, 2:77-87, 1932.
19. Thornton, M. and Zimmermann, E. R.: "Ankylosis of Primary Teeth," *J Dent Child*, 31:120-126, 1964.
20. Eichenbaum, I. W.: "Tooth Eruption and Ankylosis," *J Prev Dent*, 4:39-45, 1977.
21. Konstat, M. M. and White, G. W.: "Ankylosed Teeth: A Review of the Literature," *J Mass Dent Soc*, 24:74-78, 1975.
22. Gorelick, L. and Geiger, A. M.: "Direct Bonding in the Management of an Ankylosed Second Deciduous Molar," *J Am Dent Assoc*, 95:307-309, 1977.
23. Bonin, M.: "Simplified and Rapid Treatment of Ankylosed Primary Molars With an Amalgam and Composite Resin," *J Dent Child*, 43:159-162, 1976.
24. Logan, W. H. G. and Kronfeld, R.: "Development of the Human Jaws and Surrounding Structures From Birth to the Age of Fifteen Years," *J Am Dent Assoc*, 20:397-427, 1933.
25. Wheeler, R. C.: *Dental Anatomy, Physiology and Occlusion*, 5th Ed., Philadelphia: W. B. Saunders Co., 1974, pp. 195-236.
26. Sicher, H., ed.: *Orban's Oral Histology and Embryology*, 5th Ed., St. Louis: C. V. Mosby Co., 1962, pp. 100-102.
27. Russell, W. L.: "The Differential Diagnosis of Fluoride and Nonfluoride Enamel Opacities," *J Public Health Dent*, 21:143-146, 1961.
28. Goldman, H. M. and Cohen, D. W., eds.: *Periodontal Therapy*, 5th Ed., St. Louis: C. V. Mosby Co., 1973, pp. 319-321.
29. Freund, J. E.: *Modern Elementary Statistics*, New York, Prentice-Hall, 1952, pp. 198-219.
30. Kollar, E. J.: "Histogenetic Aspects of Dermal-Epidermal Interactions," in Slavkin, H. C., and Baretta, L. A., eds: *Developmental Aspects of Oral Biology*, New York: Academic Press, 1972, pp. 125-149.
31. Rule, J. T., Zacherl, W. A., and Pfefferle, A. M.: "The Relationship Between Ankylosed Primary Molars and Multiple Enamel Defects," *J Dent Child*, 39:29-35, 1972.
32. Steigman, S., Koyoumdjisky-Kaye, E., and Matrai, Y.: "Relationship of Submerged Deciduous Molars to Root Resorption and Development of Permanent Successors," *J Dent Res*, 53:88-93, 1974.
33. Howell, J. H.: In Walther, D. P. ed.: *Current Orthodontics*, Bristol: Wright, 1966, p. 203.
34. Shafer, W. G., Hine, M. K., and Levy, B. M.: *A Textbook of Oral Pathology*, 3rd Ed., Philadelphia: W. B. Saunders Co., 1974, p. 66.
35. Schour, I. and Massler, M.: In Brauer, J. C.: *Dentistry for Children*, New York: McGraw-Hill, 1964, p. 117.

---

DRS. MESSER and CLINE are affiliated with the Department of Pediatric Dentistry, University of Minnesota, Minneapolis, Minnesota.

Requests for reprints may be sent to Dr. Louise Brearley Messer, Department of Pediatric Dentistry, University of Minnesota, Minneapolis, MN 55455.