

Surgical exposure and orthodontic positioning of an unerupted maxillary canine: case report

Jane Mermigos, DDS Clemens A. Full, BS, DDS, MS

Abstract

This report describes the surgical and orthodontic management of a patient with a palatally impacted permanent maxillary canine. Following surgical exposure, orthodontic traction was applied to reposition the canine with resultant proper functioning, excellent esthetics, and good periodontal health.

Due to the prevalence of impacted permanent canines, it is likely that pediatric dentists will confront such a situation in the course of their practices. This report describes the surgical exposure and orthodontic repositioning of a palatally impacted permanent maxillary canine in a 14-year-old female. Not only were the esthetic results pleasing, but a properly functioning occlusion with excellent periodontal health was achieved.

Literature Review

Excluding the maxillary and mandibular third molars, the most commonly impacted or unerupted tooth is the permanent maxillary canine. Palatal impaction is much more common than labial impaction, although the rate has been reported to vary from 2:1 by Gaulis and Joho (1978) to 12:1 by Jacoby (1979). While there have been numerous hypotheses developed regarding the etiology of canine impaction, the issue remains controversial. Most authors state that impaction is due primarily to arch length deficiency. Since the canine is usually the last tooth to erupt anterior to the first molar in the maxillary arch, shortage of space may result in ectopic eruption or impaction of this tooth. Contrary to this popular belief, Jacoby (1983) found that 85% of the palatally impacted canines in his study had adequate space for eruption. He speculated that the presence of extra space in the maxillary bone may result in the lingual positioning of the canine and that the excess space may be the result of: (1) excessive growth in the base of the maxillary bone; (2) congenitally missing or peg-shaped lateral incisor; or (3) stimulated eruption of

the lateral incisor or first premolar. Other factors frequently reported to contribute to canine impaction include: (1) the rate of root resorption of primary teeth; (2) trauma to the primary tooth bud; (3) disturbances in the sequence of tooth eruption; (4) rotation of tooth buds; (5) premature root closure; and (6) localized pathologic lesions (Moyers 1963; Bishara 1976).

Due to the potential for adverse sequelae of impacted canines, including resorption of adjacent roots, referred pain, infection, dentigerous cyst formation which may lead to ameloblastoma, and resorption of the affected tooth (Shafer et al. 1963), treatment of these teeth is indicated. Whenever possible, treatment should involve exposure and repositioning of the impacted tooth in order to maintain the integrity of the maxillary arch.

Treatment in most cases first requires orthodontic preparation of the maxillary arch in order to create adequate space between the lateral incisor and first premolar prior to surgical exposure. The techniques involved in the surgical and repositioning stages have been described and modified extensively (Strock 1938; Clark 1971; Gensior et al. 1974; von der Heydt 1975; Levine et al. 1979).

The purpose of this paper was to describe a technique for the surgical exposure and orthodontic positioning of an impacted maxillary canine.

Case Report

A 14-year-old white female presented to the Department of Pediatric Dentistry, University of Iowa, for routine preventive and restorative dental care. Clinical and radiographic examination revealed palatal impaction of the maxillary left permanent canine (Figs 1, 1a). The patient presented with Class I molar relationship with normal overbite and overjet. The only apparent space discrepancy was in the immediate area of the impacted canine. Therefore, a cephalometric and dentition analysis did not appear to be necessary. A fixed appliance was placed only in the maxillary arch. Ade-

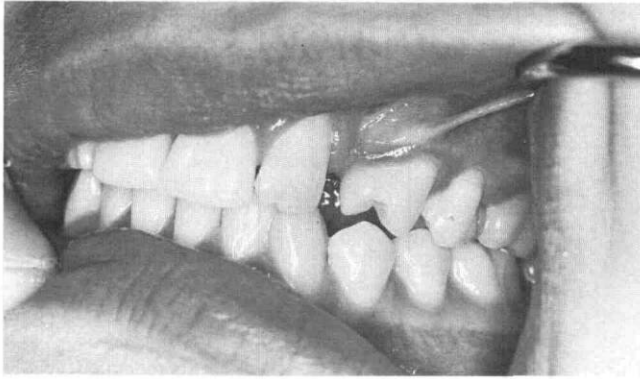


FIG 1. Initial evaluation of the patient revealed rotated first premolar and inadequate space for impacted canine.

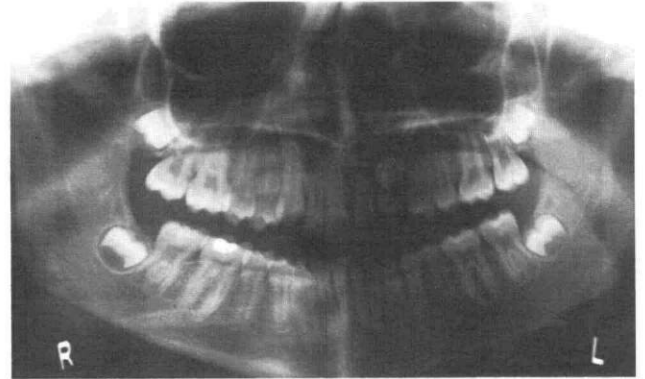


FIG 1a. Position of impacted canine at initial evaluation of the patient.

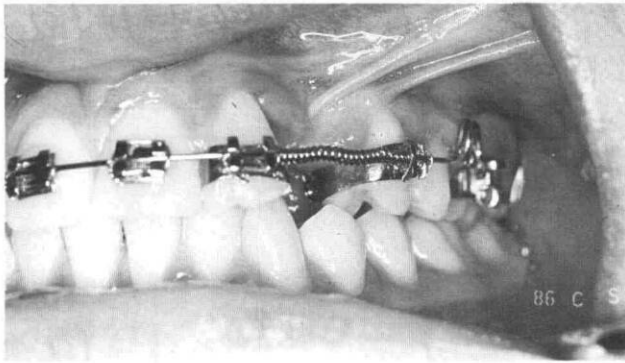

FIG 2. Arch preparation with open coil spring to create space in maxillary arch for impacted canine.

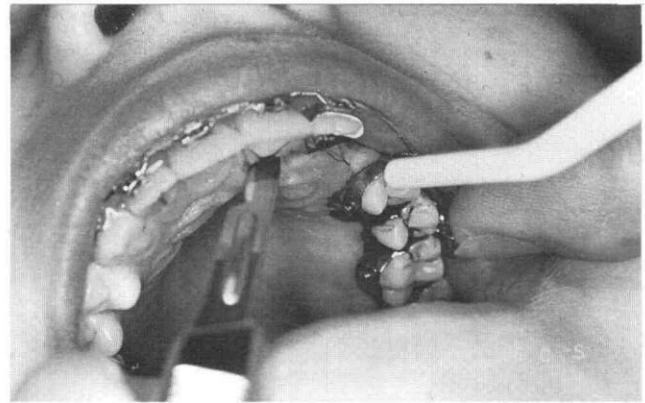


FIG 3. Palatal sulcular incision.

quate space for the canine was gained using a .018 round stainless steel wire with open coil spring and derotation of first premolar (Fig 2). The arch was stabilized and quadrants secured with .017 x .025 stainless steel arch wire. The arch was now ready for surgery. Arch preparations took approximately 7 months.

After adequate anesthesia was obtained using block and infiltration injection of 2% lidocaine with 1:100,000 epinephrine, a full-thickness mucoperiosteal flap was established. A palatal sulcular incision was made which extended from the mesial aspect of the left central incisor to the mesial aspect of the second premolar (Fig 3). The flap was elevated and retracted, and bone overlying the crown of the canine was removed using a surgical bur and copious irrigation with normal saline (Fig 4). Once adequate clinical crown was exposed, hemostasis was achieved by applying direct pressure with sterile gauze and cotton pellets.

Once hemorrhage was controlled, the tooth surface was isolated, etched with 50% phosphoric acid, rinsed with water, and dried. The appliance used to apply traction to the canine consisted of an orthodontic bracket, Pletcher spring loop, and ligature wire (Fig 5, page 74). The assembled appliance then was directly

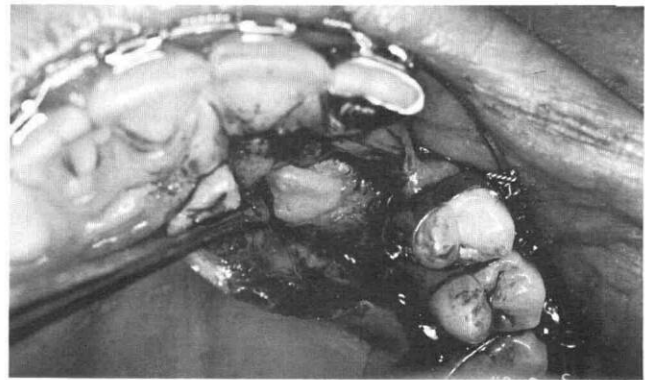


FIG 4. Retracted mucoperiosteal flap and exposure of the canine crown.

bonded to the etched tooth surface, having been oriented such that traction would be applied in a distal and facial direction. The appliance was tied onto the arch wire via the ligature tie, and the flap repositioned and closed primarily with interrupted sutures (Fig 6, page 74). Postoperative instructions were given to the patient and parent.

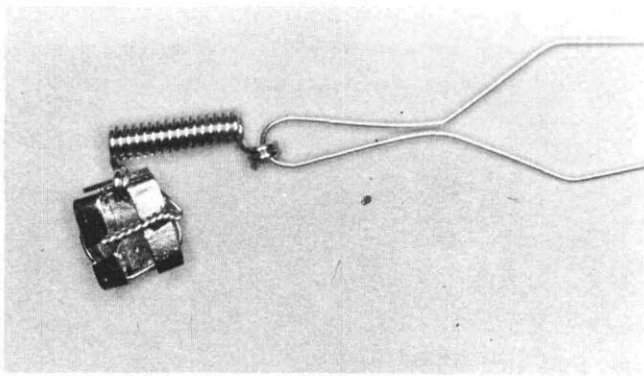


FIG 5. Assembled traction appliance ready for bonding to etched surface of canine.

The sutures were removed 7 days postsurgically, with excellent wound healing. At 1-month intervals, the Pletcher spring was activated by tightening the ligature tie. Movement of the canine was followed radiographically and clinically by observing the amount of spring visible (Fig 7). Within 6 months, the canine was clinically visible and conventional orthodontic mechanics were used to extrude, rotate, and align the canine in the maxillary arch. The duration of postsurgical active treatment was 14 months.

After removal of the fixed maxillary appliance, a Hawley retainer was placed (Fig 8). Evaluation revealed bilateral Angle Class I molar and canine relationships. The treated canine was in excellent position and alignment in the maxillary arch (Fig 8a). Periodontal assessment revealed healthy supporting tissues with normal soft tissue color and texture; sulcus depths of the canine and adjacent teeth ranged from 0 to 2 mm.

Discussion

Impacted permanent maxillary canines are detected quite regularly in the clinical and radiographic examination of a young dental patient.

The first step in treatment requires both clinical and radiographic assessment in order to determine accurately the location and position of the impacted tooth. The patient in this report demonstrated a palatally impacted canine. Through surgical exposure and direct bonding of an appliance which contained a Pletcher spring that could be activated at regular intervals, the canine was brought into proper position in the arch. The total active treatment time was 21 months — 7 months to prepare the arch and create space and 14 months postoperatively to reposition the canine, align, level, and rotate. The results of treatment included an intact, properly functioning occlusion, pleasing esthetics, as well as healthy periodontal supporting tissues.

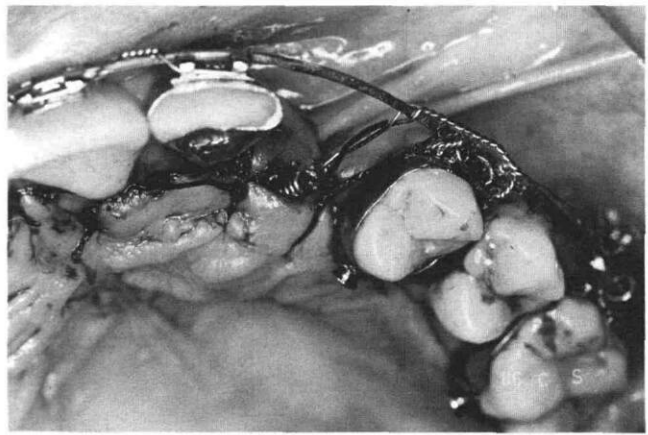


FIG 6. Wound closure and attachment of appliance to maxillary arch wire.

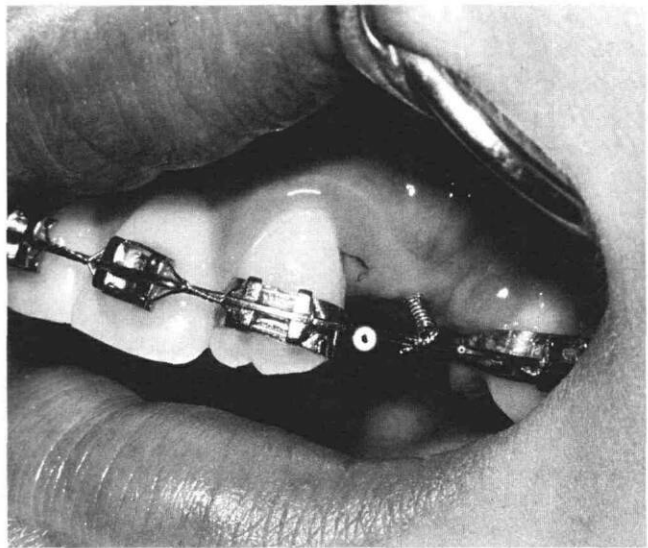


FIG 7. Clinical view of appliance with Pletcher spring clearly visible.

Dr. Full is a professor and at the time of the study Dr. Mermigos was a resident, pediatric dentistry, University of Iowa. Currently, Dr. Mermigos is an assistant professor, pediatric dentistry, The Ohio State University. Reprint requests should be sent to: Dr. Clemens A. Full, S-201 Dental Science Bldg., Dept. of Pediatric Dentistry, The University of Iowa, Iowa City, IA 52242.

Bishara SE, Kommer DD, McNeil MH, Montagano LN, Oesterle LJ, Youngquist HW: Management of impacted canines. *Am J Orthod* 69:371-87, 1976.

Clark D: The management of impacted canines: free physiologic eruption. *J Am Dent Assoc* 82:836-40, 1971.

Gaulis R, Joho JP: Parodonte marginal de canines superieures incluses: evaluation suite a differentes methodes d'accès chirurgical et de systeme orthodontique. *Rev Mens Suisse d'odontostomatol* 88:1249-61, 1978.

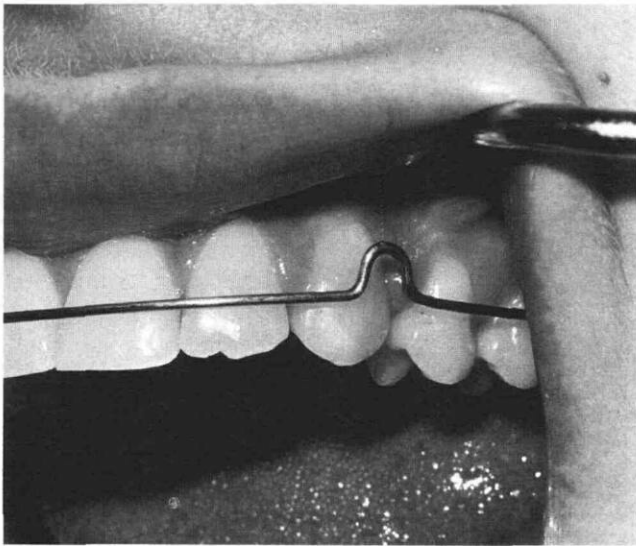


FIG 8. Completed treatment; maxillary left canine in good arch alignment.

Gensior AM, Strauss RE: The direct bonding technique applied to management of the maxillary impacted canine. *J Am Dent Assoc* 89:1332-37, 1974.

Jacoby H: The etiology of maxillary canine impactions. *Am J Orthod* 84:125-32, 1983.

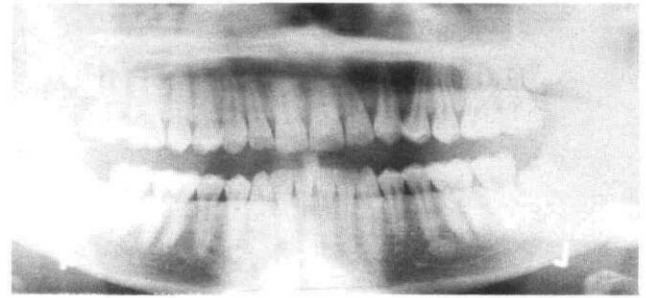


FIG 8a. Completed treatment; position of canine in place.

Jacoby H: The "ballista spring" system for impacted teeth. *Am J Orthod* 75:143-51, 1979.

Levine B, Skope L: Direct bonding of unerupted teeth for orthodontic movement. *J Am Dent Assoc* 98:55-57, 1979.

Moyers RE: *Handbook of Orthodontics*, 2nd ed. Chicago; YearBook Medical Publishers Inc, 1963 pp 83-88.

Shafer WG, Hine MK, Levy BM: *A Textbook of Oral Pathology*, 2nd ed. Philadelphia; WB Saunders Co, 1983 p 68.

Strock MS: A new approach to the unerupted tooth by surgery and orthodontics. *Am J Orthod* 24:626-34, 1938.

von der Heydt K: The surgical uncovering and orthodontic positioning of unerupted maxillary canines. *Am J Orthod* 68:256-76, 1975.

So you want to be an actuary

The Jobs Rated Almanac ranks 250 best and worst occupations. Rankings are based on salary, stress, work environment, outlook, job security, and physical demands.

Dentists ranked 68, compared with baseball players, who placed 222 on the list. Those who work with statistics and analysis are considered to have the best jobs, hence the number one rating for actuaries. The next best jobs are computer programmers and computer systems analysts.

Dentists fared better than other health care occupations. Dental lab technicians came in at number 90, dental hygienists at 94, physicians at 131, and surgeons 143.