

A very delayed developing premolar: clinical report

John E. Memmott, BS, DDS Curtis G. Kuster, BS, DDS, MS
Robert E. Sullivan, DDS, MSD

Abstract

This clinical report describes the delayed development of a maxillary second premolar. The premolar developed when the patient was between the ages of 12 and 16 years. The development of the tooth was discovered from a panoramic radiograph taken when the patient was 17 years, 1 month of age. Previous to this discovery, the tooth had been diagnosed as congenitally missing.

The transition from the primary dentition to the permanent dentition can be complicated by an aberrant second premolar, either congenitally absent or delayed in development. The prevalence of some missing permanent teeth (hypodontia) is a common developmental anomaly. A less frequent situation is apparent hypodontia due to delayed tooth development, leading to a possible misdiagnosis as congenital absence of the tooth. This clinical report will describe a patient who developed a maxillary second premolar sometime between the ages of 12 and 16 years, after the patient had been diagnosed as having a congenitally missing premolar.

Literature Review

Hypodontia is not an uncommon finding.¹⁻³ In a review of the literature, Silverman and Ackerman reported a summary of the results of various studies.⁴ The prevalence of missing teeth in the permanent dentition, with the exception of third molars is reported to be from 2.3 to 10.2%. One or more third molars are reported to be missing in approximately 25% of the population. The teeth most commonly missing, excluding third molars, are mandibular second premolars, maxillary lateral incisors, and maxillary second premolars, in that order.

Maxillary second premolars should begin hard tis-

sue formation at 2-2¼ years of age, with enamel formation completed at age 6-7 according to Logan and Krönfeld.⁵ Massler et al.⁶ reported that mineralization of premolars begins at age 2-2½.

Based upon several other studies,⁷⁻⁹ Jorgenson formulated a table listing ages at which teeth can be expected to be visible on radiographs² (Table 1). The maxillary second premolars should be visible by age 3.

Ravn and Nielsen¹⁰ reported findings of a longitudinal radiographic study of the mineralization of second premolars. They state that odontogenesis of the second premolar begins by age 3-3½ and a tentative diagnosis of aplasia can be made if there is no radiographic evidence of the tooth by age 6. They further state, however, that the second premolar can be very late in developing and that the chance of this occurring is greater in the maxilla than in the mandible.

Based upon these previous studies, the dentist who finds no evidence of second premolars developing in a child older than age 6 may develop a treatment plan that would assume aplasia of this tooth.¹¹

TABLE 1. Approximate Ages at Which Teeth Can Be Expected To Be Visible on Radiographs⁷⁻⁹

Deciduous Teeth			Permanent Teeth		
	Maxillary	Mandibular		Maxillary	Mandibular
I ₁	Birth	Birth	I ₁	6 months	6 months
I ₂	Birth	Birth	I ₂	1 year	9 months
C	Birth	Birth	C	6 months	6 months
M ₁	Birth	Birth	P ₁	2 years	2 years
M ₂	Birth	Birth	P ₂	3 years	3 years
			M ₁	Birth	Birth
			M ₂	4 years	4 years
			M ₃	9 years	9 years

This assumption should be guarded, however, because there are several reports in the literature of an apparent initial lack of radiographic evidence of developing premolars; but at age 8, 10, or even 13, subsequent radiographs revealed development of these teeth, or even supernumerary premolars.^{3,11-15}

Patient Presentation

CJ, a 17-year-old black female, had received dental treatment at the University of Nebraska Medical Center, College of Dentistry for 11 years. The patient's medical history was noncontributory, with no history of facial trauma or premature birth. The patient's dental history was also noncontributory, other than evidence of an apparently congenitally missing maxillary left second premolar and maxillary right lateral incisor. These apparent anomalies were discovered at age 7 years, 11 months during the patient's first dental examination (Fig 1).

At this initial dental examination, the maxillary left primary second molar was diagnosed as carious and a stainless steel crown restoration was scheduled. Because of the apparent absence of a permanent successor, the primary second molar was restored to approximate the mesiodistal dimension of a maxillary second premolar.

The next panoramic radiograph was taken at a routine dental examination when the patient was age 11 years, 11 months (Fig 2). The stainless steel crown restoration of the maxillary left primary second molar appeared to be satisfactory. The patient received restorative dental treatment and was scheduled for routine recall dental examinations.

At age 17 years, 1 month, during a recall dental examination, the patient complained of intermittent discomfort in her posterior mandible. A panoramic radiograph was taken to evaluate her third molars for possible surgical extraction. Upon examination of the radiograph, the maxillary second premolar was found to be developing (Fig 3).

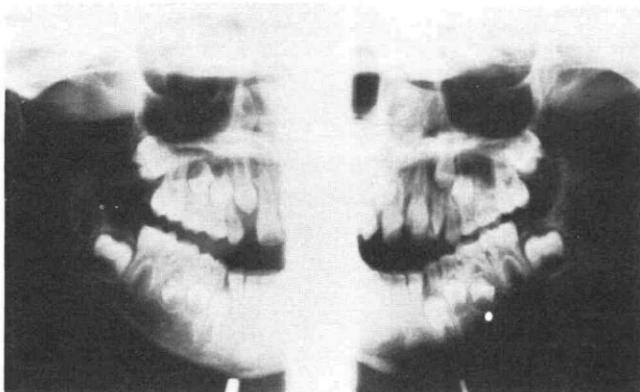


FIG 1. Panoramic radiograph at 7 years, 11 months.

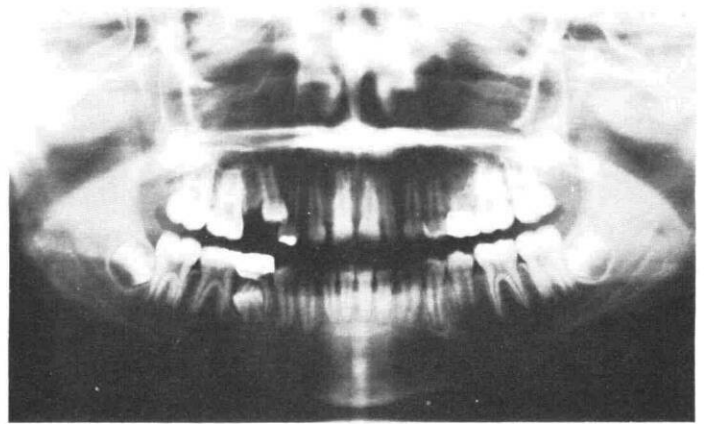

FIG 2. Panoramic radiograph at 11 years, 11 months.

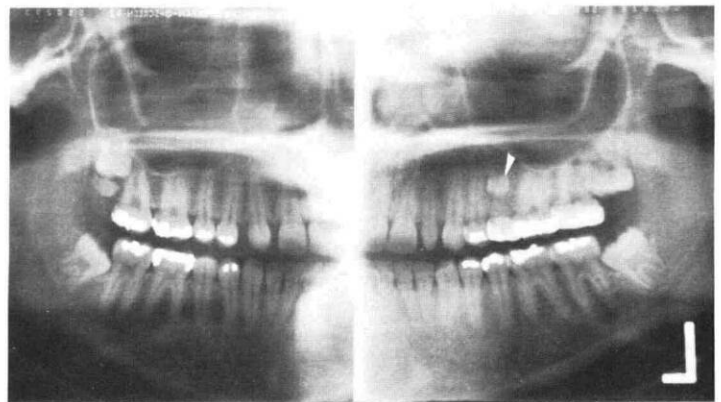


FIG 3. Panoramic radiograph at 17 years, 1 month.

An investigation of the patient's family was conducted. No other family member had knowledge of congenitally missing or delayed eruption of any teeth. Currently, the patient is being followed for routine dental care and to follow the eruption of her maxillary second premolar.

Discussion

The unilateral aplasia of a maxillary second bicuspid is not uncommon.^{2,4} From the reports of Jorgenson,² and Ravn and Nielsen,¹⁰ the dentist should expect to see radiographic evidence of the maxillary second bicuspid by age 3 and could make a tentative diagnosis of aplasia by age 6. The clinician must be aware, however, of the possibility of very delayed development of this tooth as occurred in this patient.

Awareness of the possibility of very delayed development of second premolars could influence the treatment plan for a patient with apparent aplasia. This awareness is especially important when the treatment may consist of prosthetic replacement or orthodontic repositioning if the primary second molar is lost.

Dr. Memmott is a research fellow, Dr. Kuster is an associate professor, and Dr. Sullivan is a professor and chairman, Department of Pedodontics, University of Nebraska Medical Center, College of Dentistry, Lincoln, NE 68583-0740. Reprint requests should be sent to Dr. Memmott.

1. Fass EN: Aberrant second premolars. *J Dent Child* 37:494-98, 1970.
2. Jorgenson RJ: Clinician's view of hypodontia. *JADA* 101:283-86, 1980.
3. Coupland MA: Apparent hypodontia. *Br Dent J* 152:388, 1982.
4. Silverman NE, Ackerman JL: Oligodontia: a study of its prevalence and variation in 4032 children. *J Dent Child* 46:470-77, 1979.
5. Logan WHG, Krönfeld R: Development of the human jaws and surrounding structures from birth to the age of fifteen years. *JADA* 20:379-427, 1933.
6. Massler M, Schour I, Poncher HG: Developmental pattern of the child as reflected in the calcification pattern of the teeth. *Am J Dis Child* 62:33-67, 1941.
7. Wheeler RC: *An Atlas of Dental Anatomy and Physiology*, 3rd ed. Philadelphia; WB Saunders Co, 1958 p 29.
8. Moorrees CF, Fanning EA, Hunt EE: Age variation of formation stage for ten permanent teeth. *J Dent Res* 42:1490-1502, 1963.
9. Garn SM, Lewis AB, Polacheck DL: Variability of tooth formation. *J Dent Res* 38:135-48, 1959.
10. Ravn JJ, Nielsen HG: A longitudinal radiographic study of the mineralization of second premolars. *Scand J Dent Res* 85:232-36, 1977.
11. Cunat JJ, Collord J: Late developing premolars: a report of two cases. *JADA* 87:183-85, 1973.
12. Torres JS: Late development of second premolar. *Oral Surg* 34:350, 1972.
13. Lieberman MA, Gazit E: Late supernumerary premolar formation. *J NJ Dent Assoc* 46:37-38, 1975.
14. Shapira Y, Haskell BS: Late developing supernumerary premolar. *J Clin Orthod* 15:571, 1981.
15. Ranta R, Ylipaavaliemi P: Developmental course of supernumerary premolars in childhood: report of two cases. *J Dent Child* 48:385-88, 1981.
16. Dolder E: Deficient dentition. *Dent Rec* 57:142-43, 1937.
17. Werther R, Rothenberg F: Anodontia: a review of its etiology with presentation of a case. *Am J Orthod* 25:61-81, 1939.
18. Byrd ED: Incidence of supernumerary and congenitally missing teeth. *J Dent Child* 10:84-86, 1943.
19. Clayton JM: Congenital dental anomalies occurring in 3557 children. *J Dent Child* 23:206-8, 1956.
20. Grahnen H: Hypodontia in the permanent dentition. *Odontol Revy* 7:5-100, 1956.
21. Brown R: The patterns and frequency of congenital absence of teeth. *Iowa Dent J* 43:60-61, 1957.
22. Glenn FB: Incidence of congenitally missing permanent teeth in a private pedodontic practice. *J Dent Child* 28:317-20, 1961.
23. Glenn FB: A consecutive six-year study of the prevalence of congenitally missing teeth in private practice of two geographically separated areas. *J Dent Child* 31:264-70, 1964.
24. Gimnes H: Congenital absence of teeth in Oslo school children. *Dent Abstr* 9:236-37, 1964.
25. Castaldi CR, Bodnarchuk A, MacRae PO: Incidence of congenital anomalies in permanent teeth of a group of Canadian children aged 6 to 9. *Can Dent Assoc J* 32:154-59, 1966.
26. Rose JS: A survey of congenitally missing teeth, excluding third molars in 6000 orthodontic patients. *Dent Pract (Bristol)* 17:107-14, 1966.
27. Horowitz JM: Aplasia and malocclusion: a survey and appraisal. *Am J Orthod* 52:440-53, 1966.
28. Blayney JD, Hill IN: Fluorine and dental caries. *JADA* 74:223-302, 1967.
29. Muller TP, Hill IN, Peterson AC: A survey of congenitally missing permanent teeth. *JADA* 81:101-7, 1970.
30. McKibben DR, Brearley LJ: Radiographic determination of the prevalence of selected dental anomalies in children. *J Dent Child* 38:390-98, 1971.
31. Haavikko K: Hypodontia of permanent teeth: an orthopantomographic study. *Suom Hammaslaak Toim* 67:219-25, 1971.
32. Boruchov MJ, Green LJ: Hypodontia in human twins and families. *Am J Orthod* 60:165-74, 1971.
33. Ferguson NC, Worth HM, Dillabaugh GH: An investigation of the occurrence of diastemata and supernumerary teeth. *JADA* 87:1409-10, 1973.
34. Hundstadbraten K: Hypodontia in the permanent dentition. *J Dent Child* 40:115-17, 1973.

Moving? Changing Your Name?

Name _____

Address _____

City _____

State _____ Zip _____

Members Only: Social Security Number:

To ensure prompt delivery of *Pediatric Dentistry* complete this form. Be sure to affix mailing label (if available) in the space provided.

If you are moving to a foreign country ADD \$4 per issue for each remaining issue on your current subscription. Make checks or money orders payable to: American Academy of Pediatric Dentistry. Allow 10 weeks for the change to become effective.

Members: Mail your change of name/address to: American Academy of Pediatric Dentistry, 211 E. Chicago Ave., Suite 1036, Chicago, IL 60611. Nonmembers: Mail your change of name/address to: American Academy of Pedodontics Editorial Office, 1411 Hollywood Blvd., Iowa City, Iowa 52240.