



# Identification of *Candida dubliniensis* in a study of HIV-Seropositive pediatric dental patients

Diana M. Brown, DDS Mary Ann Jabra-Rizk, BS, PhD William A. Falkler, Jr., PhD A. A.M.A. Baqui, MD, PhD  
Timothy F. Meiller, DDS, PhD

*Dr. Brown is a resident, Department of Pediatric Dentistry; Dr. Jabra-Rizk is a post-doctoral fellow and Dr. Falkler is a professor, Department of Oral and Craniofacial Biological Sciences; Dr. Baqui is a post-doctoral fellow and Dr. Meiller is a professor, Department of Oral Medicine and Diagnostic Sciences, they are all at the University of Maryland Dental School, Baltimore, MD. Correspond with Dr. Meiller at tfm001@umaryland.edu*

## Abstract

**Purpose:** The combination of an immature immune system and suppressed cellular immunity in children with HIV infections provides optimal conditions for rapid disease progression. As a result, pediatric AIDS has become a major epidemiological challenge. Oral fungal colonization remains one of the most common opportunistic infections observed in both adult and pediatric HIV infected patients. Although *Candida albicans* is the most frequently isolated opportunistic fungal species, a recently characterized *Candida* species, *C. dubliniensis*, has gained considerable attention due to its almost exclusive association with HIV-seropositive individuals. The purpose of this study was to prospectively screen for the presence of *C. dubliniensis* among pediatric HIV+ patients.

**Methods:** Oral samples taken from twenty-seven children were cultured for the presence of yeast. All positive yeast isolates obtained were screened for the presence of *C. dubliniensis* by use of tests for germ tube and chlamydospore production, detection of inability to grow at 45°C, by colony color on CHROMagar *Candida* medium, coaggregation with *Fusobacterium nucleatum* ATCC 49256 and by the results of sugar assimilation testing with the API 20C AUX yeast identification system.

**Results:** Among the 27 patients tested, 3 patients were found to harbor *C. dubliniensis*, one of which also grew *C. glabrata*; 12 patients were colonized with *C. albicans*, while the remaining 12 patients were negative for yeast. Identification of the three *C. dubliniensis* isolates was genetically confirmed by electrophoretic karyotyping. All three *C. dubliniensis* isolates were found to be susceptible to fluconazole (MIC ≤ 0.25 µg/ml).

**Conclusions:** These results confirm the presence of this novel species in a dental pediatric HIV seropositive population and support the need for further investigation into the prevalence and pathogenesis of *C. dubliniensis*. (*Pediatr Dent* 22:234-238, 2000)

Pediatric AIDS has become a major epidemiological challenge, as the scope of the disease continues to increase in magnitude. Among the various manifestations of AIDS in this immunologically immature and compromised population, the relentless onslaught of diverse opportunistic infections remains the most devastating. Although normal healthy children experience oral candidiasis to some degree<sup>23</sup>,

in HIV-infected populations, oral candidiasis ranks high in terms of incidence, with its prevalence comparable in both children and adult HIV-infected populations. In recent years, interest has shifted from *C. albicans*, the species long considered most pathogenic among the opportunistic fungi, to several of the less commonly isolated pathogenic species, namely *C. krusei*, *C. glabrata* and *C. dubliniensis*.<sup>1-3</sup> Since its initial characterization in 1995, *C. dubliniensis*, in particular, has attracted considerable attention as a newly emerging pathogen, mainly because it has been isolated almost exclusively from HIV-positive and AIDS individuals.<sup>3, 4-10, 29</sup>

Although extremely similar to *C. albicans* in many of its phenotypic characteristics such as germ tube formation and chlamydospore production, *C. dubliniensis* can be differentiated from *C. albicans* by its inability to grow at 45°C, production of characteristic colony color on chromogenic media and by typical sugar assimilation profiles. Despite the close resemblance between *C. dubliniensis* and *C. albicans*, ongoing characterization of *C. dubliniensis* revealing differences that may allow this novel species to be potentially more pathogenic than its closest relative.<sup>13</sup> In addition, unlike *C. albicans*, *C. dubliniensis* was found to rapidly develop stable resistance to fluconazole *in vitro*<sup>11,12</sup> and to have significantly higher levels of proteinase activity,<sup>6</sup> a property considered a virulence factor in fungi.

Recent studies comparing the interactive ability of the two *Candida* species with other oral microorganisms, showed that *C. dubliniensis* was able to coaggregate *in vitro*, with the anaerobic oral bacteria *Fusobacterium nucleatum*, when grown at 37°C, whereas *C. albicans* failed to do so when grown at the same temperature.<sup>13</sup> This intergeneric coaggregation between *C. dubliniensis* and *F. nucleatum* may give this species a greater ecological advantage in allowing enhanced colonization of the oral cavity besides allowing a rapid means of clinical identification.

To date, no studies have evaluated the presence of this species in the pediatric HIV-infected population. The following study aimed to screen for the presence of *C. dubliniensis* in the oral cavities of pediatric HIV-seropositive dental patients.

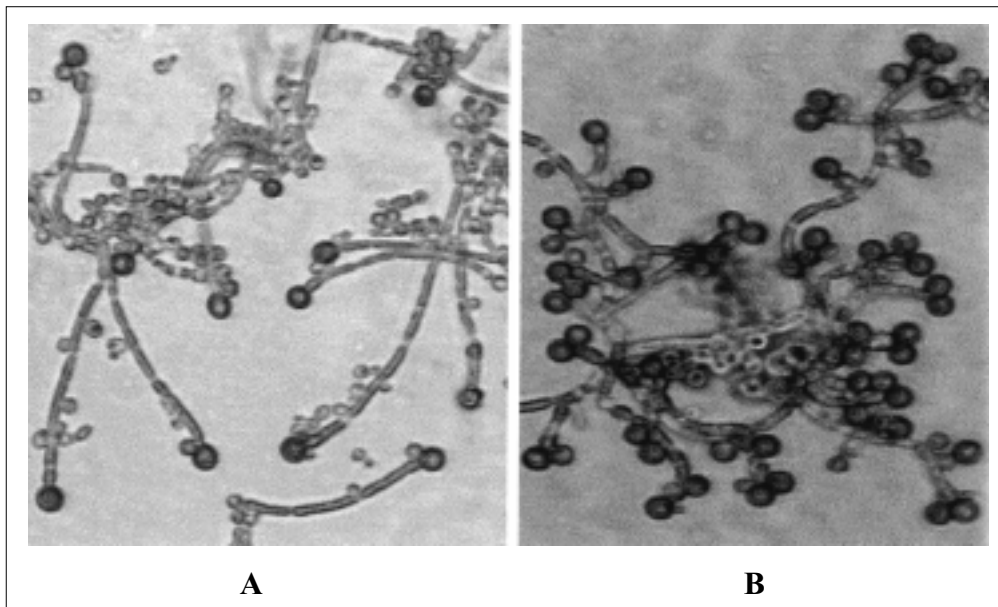


Fig 1. Phase-contrast micrographs showing chlamydospore production on TOC agar plates incubated at 25°C for 48 hours. (A) Chlamydospores and pseudohyphae produced by *C. albicans* ATCC 18804; (B) typical production of abundant chlamydospores by the *C. dubliniensis* isolates in our study; the terminal pairs arrangement is shown. Magnifications, X320.

## Materials and methods

### Patient population

Twenty-seven pediatric HIV-seropositive patients managed at the University of Maryland Dental School, were evaluated for the presence of *C. dubliniensis*. Although culturing for potential fungal colonization maybe part of normal dental care, informed consent was obtained from the parents or legal guardians of each child participating in this study. Of those pediatric patients sampled, 68% were females and 32% were males, with an age range of 26 months to 13 years. For isolation of *Candida* species oral samples were obtained from the mid-dorsum of the tongue with a sterile swab, streaked on Sabouraud dextrose agar (SDA; Difco Laboratories, Detroit, MI) plates and incubated at 37°C for 48 to 72 h. Colonies growing on original cultures were tested for germ tube formation, chlamydospore production and ability to grow at 45°C.

### Yeast identification

Isolated yeast colonies were streaked on TOC agar (Tween 80-oxgall-cafeic acid; REMEL, Lenexa, KS), and plates were incubated at 37°C for 3 h for evaluation of germ tube formation, followed by incubation at room temperature for 2 to 3 days in the dark, to promote the production of chlamydospores, hyphae and pseudohyphae. Germ tube and chlamydospore production was observed using phase contrast light microscopy.

Isolates that met these initial criteria were then plated on a chromogenic differential medium and incubated at 37°C for 48 h. The isolates were further characterized for substrate assimilation profiles using the API 20C system (bioMerieux Vitek, Inc., Hazelwood, MO).

### CoAg Assay

Isolates were grown at 37°C for 24 h on SDA and 10% yeast suspensions were prepared in CoAg buffer as described previ-

ously.<sup>13</sup> The CoAg ability of the 3 *C. dubliniensis* isolates with the anaerobic oral bacteria *F. nucleatum* ATCC 49256 was tested by mixing aliquot of yeast suspension with bacterial suspension and checked visually for coaggregation. *Candida dubliniensis* type strain CD36 and *C. albicans* ATCC 18804 were used as positive and negative controls, respectively.

### Electrophoretic Karyotyping (EK)

All isolates meeting the phenotypic criteria of *C. dubliniensis*, along with *C. albicans* ATCC 18804 and *C. dubliniensis* CD36 as controls, were subjected to electrophoretic karyotyping of intact chromosomal DNA using pulsed-field gel electrophoresis. Intact yeast DNA was prepared according to the method of King et al.<sup>14</sup> as described previously.<sup>10</sup>

### Fluconazole susceptibility testing

A broth macrodilution susceptibility assay was carried out according to the method outlined in The National Committee for Clinical Laboratory Standards (NCCLS) M27-A reference method.<sup>15</sup> The MIC value at 48 h was used to determine resistance or susceptibility. Interpretation of results was performed according to the guidelines of Rex et al.,<sup>16</sup> as follows: an MIC at 48 h of <8 ug/ml = susceptible, an MIC of 16-32 ug/ml, dose-dependent susceptible; and an MIC >64 ug/ml, resistant.<sup>15-17</sup>

## Results

### Phenotypic characterization

Of the 27 yeast isolates from HIV-seropositive pediatric patients obtained by culture of clinical specimens, 3 isolates grew well at 37°C but failed to grow at 45°C on SDA whereas *C. albicans* ATCC 18804 grew equally well at both temperatures. These 3 isolates were confirmed to be germ tube positive and to produce abundant chlamydospores with the characteristic

triplet or pair arrangement at the end of short, hyperbranching hyphae. The *C. albicans* reference strains also produced germ tubes but fewer, single chlamydo spores on longer hyphae (see Fig 1 for typical patterns for patient isolates compared to *C. albicans* strain). The color of the colonies from the three patient isolates grown on CHROMagar Candida medium was comparable to the characteristic dark green of *C. dubliniensis* type strain CD36, unlike the blue-green colonies formed by *C. albicans* ATCC 18804 colonies, used as a control. The sugar-assimilation profiles obtained for the three isolates with the API 20C AUX yeast identification systems were typical of *C. dubliniensis*.

#### CoAg Assay

Visual coaggregation was observed with the three presumptive *C. dubliniensis* (37°C-grown) patient isolates showing a 4+ reaction with *F. nucleatum*, whereas no coaggregation occurred with the 37°C-grown *C. albicans* ATCC strain.<sup>13</sup>

#### Electrophoretic karyotype analysis

Eight to nine DNA bands ranging from ~1.9 Mb to <1 Mb were separated by the pulsed-field gel electrophoresis procedure applied to the three isolates of presumptive *C. dubliniensis* and reference strain CD36. Electrophoretic karyotyping patterns for all of the three suspected *C. dubliniensis* isolates revealed the presence of a chromosome-sized band of size <1 Mb.<sup>10</sup> This band was not seen in the seven bands (>1 Mb) observed with the ATCC *C. albicans* reference strain.

#### Fluconazole susceptibility testing

The results of fluconazole susceptibility testing for the three isolates presumptively identified as *C. dubliniensis* showed that all three isolates were sensitive with MIC <0.25 µg/ml.

#### Characteristics of the patients positive for *C. dubliniensis*.

As part of the normal protocol for initial evaluation of HIV+ pediatric patients entering the dental program at the University of Maryland Dental School 27 consecutive patients were evaluated with fungal surveillance cultures. Of these 27 patients, 3 patients were found to be harboring *Candida dubliniensis*.

Case #1 was a 5-year 2-month old female positive with HIV since soon after birth. Her current CDC classification was C3 with severe immunosuppression. While the viral load was greater than 10,000 at the time of the oral surveillance culture, CD4 count was within the range of normal at approximately 1,000 cells. No history or record of candidiasis was noted in the patient's medical work up. The mother was a previous intravenous drug abuser and was deceased soon after the child's birth. The child was born with signs of addiction. The patient was currently on a nucleoside analog, a protease inhibitor and a nonnucleoside analog. The mother had had a previous history of oropharyngeal candidiasis and had been treated with fluconazole although the child never had a documented episode.

Case #2 is a 10-year 5-month old female with a positive diagnosis of HIV at approximately 9 months of age. One brother also had a positive history of HIV. The patient was also CDC class C3 with severe immunosuppression. Viral load

was in the undetectable range and the CD4 count was currently 646. The patient was on triple drug combination therapy including a protease inhibitor, nucleoside analog and a nonnucleoside drug. The brother with whom the child lived had been diagnosed with oropharyngeal candidiasis and was treated routinely with fluconazole. The patient had no current or past history of fungal colonization. The mother was deceased and the child was living in a foster home with her brother.

Case #3 is a 6-year 6-month old male diagnosed soon after birth as being HIV+. Current CDC classification was C3 with severe immunosuppression. Viral load was greater than 250,000. CD4 count was 115. The patient was currently on antibiotics including dapsone and anti-retrovirals including 2 nucleoside analogs, 2 nonnucleoside analogs and a protease inhibitor. In addition the patient was on prednisone and clotrimazole for treatment of chronic oral and esophageal fungal infections, as evidenced by patchy pseudomembranous and erythematous oral lesions. The patient had previously been treated in 1995 and 1996 with fluconazole and was considered to be a chronic carrier of fungus. The mother was deceased and the child was living in foster care.

#### Discussion

In this study, the presence of *Candida* species with characteristics consistent with those of *C. dubliniensis* was observed in three HIV-seropositive pediatric dental patients with various manifestations of AIDS. Overall oral health status of these patients was poor. Cultures from the 3 patients varied in amount of fungal growth, from light to medium pure growth of *C. dubliniensis* to mixed heavy growth of *C. dubliniensis* with other *Candida* species. In this investigation, *C. dubliniensis* was identified by cultural methods, germ tube and chlamydo spore production, lack of growth at 45°C and CoAg assay. In addition, the API 20C sugar assimilation profiles were consistent with *C. dubliniensis* and finally the EK, with a small molecular weight chromosome, provided a profile consistent with the *C. dubliniensis* reference strain. Although the three patient isolates were found to be susceptible to fluconazole, studies showed that fluconazole resistance occurs in *C. dubliniensis* clinical isolates and that *C. dubliniensis* is capable of rapidly developing stable fluconazole resistance *in vitro*.<sup>11,12</sup> It could be postulated, therefore, that *C. dubliniensis* may emerge as a resistant organism when *C. albicans* is treated successfully with fluconazole.

Among the many manifestations of AIDS, oral candidiasis often remains the initial clinical marker of the disease and a predictor of further opportunistic infections.<sup>18</sup> Similarly in children, oral candidiasis has been strongly associated with decreasing CD4 counts and hence is considered an AIDS defining illness, prognostic of short term survival.<sup>19-21</sup> Children with HIV, however, present an unfortunate situation that predisposes them to a variety of opportunistic infectious diseases that often take on a more rapid and progressive form.<sup>22</sup> Reports have estimated that 2% of HIV-infected individuals in the United States and 15-20% of the cases in developing countries, are children under the age of 15,<sup>23</sup> with fungal colonization ranging from 26% to 72% in prevalence.<sup>23-25</sup> Although most children experience oral candidiasis to some degree during the first six months after birth, in HIV-infected children, candidiasis is more persistent, more severe and more difficult to treat with occurrences well past infancy.<sup>23,26</sup>

Oral candidiasis takes on many forms such as, acute pseudomembranous, chronic atrophic or hypertrophic, erythematous, hyperplastic or angular cheilitis. Although the gross appearance of pseudomembranous candidiasis is readily identifiable by the white plaques, it is often difficult to differentiate some of the other oral lesions that may resemble any number of conditions.

In addition, pharyngeal candidiasis, a more serious condition, may not be readily visible or accessible and may be overlooked upon clinical examination. Recently, a case report implicated *C. dubliniensis* as a pathogen in linear gingival erythema in a pediatric HIV-seropositive individual, while another report clinically documented two cases of *C. dubliniensis* candidemia in two pediatric patients with chemotherapy-induced neutropenia and bone marrow transplantation.<sup>27,28</sup> Since confirmation of the diagnosis of candidiasis requires at least cytologic testing, it is suspected that the prevalence of candidiasis in children may be considerably under reported. Due to the importance of candidiasis in defining AIDS, it is imperative to look carefully for indications of the presence of candidal infection and research into which forms of candidiasis are more often encountered in HIV+ children is warranted.

The future is uncertain for HIV+ individuals. Advances in understanding candidiasis can provide some understanding of the pathogenesis and virulence in immunocompromised population and the effect of antifungal therapy. As HIV-infected children benefit from advances in antiviral therapy, so too may they benefit from reduction in the prevalence of candidiasis.

These 3 cases raise several questions regarding the presence of *Candida dubliniensis* in HIV+ pediatric patients. Although all of these patients were C3 AIDS classification based on history, only one presented at the time of culturing with the classical picture of advancing AIDS, that is, high viral load and low CD4 count. One other had high viral load only while the third had low viral burden and normal CD4 levels. This correlates well with the incidence of fungal infection in adults as previously reported.<sup>29,30</sup> One of the 3 children had been on fluconazole in the past yet still had persistent candidiasis even though he remained on clotrimazole on an as needed basis. Also, this was the only child who demonstrated clinical evidence of oral yeast infection involving the tongue and mucosa with white plaques and broad erythema. This finding indicated that *C. dubliniensis* can present as an asymptomatic oral inhabitant as part of the flora, as well as with clinical signs and symptoms.

Overall, however, this complex picture of level of immunocompromise and AIDS in children is typical and likely reflects various responses to antiviral drugs and other yet unidentified factors. As more patients are evaluated in our cohort, contrasts between patients colonized or infected with *C. dubliniensis* with non-colonized patients may be more valid relative to trends in CDC classification, viral load and CD4 counts.

With *C. dubliniensis* recently added to the growing list of opportunistic infections, questions regarding its role in oral diseases, the factors that encourage its growth and the involvement of its interaction with *F. nucleatum* and other oral microorganisms in the infectious processes in the oral cavity, remain to be answered.

## Conclusion

The results from this study confirm the presence of *C. dubliniensis* among pediatric HIV-seropositive patients.

We would like to thank Seth Meiller and Jackie Kelley for their assistance in the preparation of this manuscript.

## References

1. Wingard JR, Merz WG, Rinaldi G, Johnson TR, Karp JE, Saral R: Increase in *Candida krusei* infection among patients with bone marrow transplantation and neutropenia treated prophylactically with fluconazole. *N Engl J Med* 18:1274-1277, 1991.
2. Vazquez JA, Dembry MA, Sanchez V, Vazquez MA, Sobel JD, Dmuchowski C, Zervos MJ: Nosocomial *Candida glabrata* colonization: an epidemiologic study. *J Clin Microbiol* 36:421-426, 1998.
3. Sullivan DT, Westermemg T, Haynes KA, Bennett D, Coleman D: *Candida dubliniensis* sp. nov. = phenotypic and molecular characterization of a novel species associated with oral candidiasis in HIV-infected individuals. *Microbiol* 141:1507-1521, 1995.
4. Boerlin P, Loerlin-Petzold F, Durussel C, Addo M, Pagani J-L, Cjave J-P, Bille J: Cluster of oral atypical *Candida albicans* isolates in a group of human immunodeficiency virus-positive drug users. *J Clin Microbiol* 33:1129-1135, 1995.
5. Coleman DC, Sullivan DJ, Bennett DE, Moran GP, Barry HJ, Shanky DB: Candidiasis: the emergence of a novel species, *Candida dubliniensis*. *AIDS* 11:557-567, 1997.
6. McCullough MB, Ross B, Reade P: Characterization of genetically distinct subgroup of *Candida albicans* strains isolated from oral cavities of patients infected with human immunodeficiency virus. *J Clin Microbiol* 33:696-700, 1995.
7. Sullivan D, Haynes K, Bille J: Widespread geographic distribution of oral *Candida dubliniensis* strains in human immunodeficiency virus-infected individuals. *J Clin Microbiol* 35:960-964, 1997.
8. Sullivan D, Coleman D: *Candida dubliniensis*: characteristics and identification. *J Clin Microbiol* 36:329-334, 1998.
9. Sullivan D, Moran G, Donnelly S, Gee S, Pinjon E, McCartan B, Shanley DB, Coleman DC: *Candida dubliniensis*. An update. *Rev Iberoam Micol* 16:72-76, 1999.
10. Jabra-Rizk MA, Baqui AAMA, Kelley JJ, Falkler Jr. WA, Merz WG, Meiller TF: Identification of *Candida dubliniensis* in a prospective study of patients in the United States. *J Clin Microbiol* 37:321-326, 1999.
11. Moran GP, Sullivan DJ, Henman MC, McCreary CE, Harrington BJ, Shanley DB, Coleman DC: Antifungal drug susceptibilities of oral *Candida dubliniensis* isolates from human immunodeficiency virus (HIV)-infected and non-HIV-infected subjects and generation of stable fluconazole-resistant derivatives in vitro. *Antimicrob Agents Chemother* 41:617-623, 1997.
12. Moran GP, Sanglard D, Donnelly SM, Shanley DB, Sullivan DJ, Coleman DC: Identification and expression of multidrug transporters responsible for fluconazole resistance in *Candida dubliniensis*. *Antimicrob Agents Chemother* 42:1818-1830, 1998.

13. Jabra-Rizk MA, Falkler WA, Jr., Merz WG, Kelley JI, Baqui AAMA, Meiller TM: Coaggregation of *Candida dubliniensis* with *Fusobacterium nucleatum*. *J Clin Microbiol* 37:1464-1468,1999.
14. King D, Rhine-Chalberg J, Pfaller MA, Moser SA, Merz WG: Comparison of four DNA-based methods for strain delineation of *Candida lusitanae*. *J Clin Microbiol* 33:1467-1470,1995.
15. National Committee for Clinical Laboratory Standards. Reference method for broth dilution antifungal susceptibility testing of yeasts: approved standard. Document M27-A. National Committee for Clinical Laboratory Standards, Wayne, Pa., 1997.
16. Rex JH, Pfaller MA, Galgiani JN, Barlett MS, Espinel-Ingroff A, Ghannoum MA, Lancaster M, Odds FC, Rinaldi MG, Walsh TJ, Barry AL: Development of interpretative breakpoints for antifungal susceptibility testing: conceptual framework and analysis of in vitro-in vivo correlation data for fluconazole, itraconazole and *Candida* infections. *Clin Infect Dis* 24: 235-247,1997.
17. Isenberg HD. (ed). *In vitro antifungal susceptibility testing of yeasts*. Vol. I. Washington: ASM,1992.
18. Klein RS, Harris CA, Small CB, Moll B, Lesser M, Friedland GH.: Oral candidiasis in high-risk patients as the initial manifestation of the acquired immunodeficiency syndrome. *N Engl J Med* 311:354-358,1984.
19. Moniaci D, Greco D, Flecchia G, Raiteri R, Sinnico A: Epidemiology, clinical features and prognostic of HIV-1 related oral lesions. *J Oral Pathol Med* 9:477-481,1990.
20. Scott GB, Hutto C, Makuch RW, Mastrucci MT, O'Connor T, Mitchell CD, Trapido EJ, Parks WP: Survival in children with perinatally acquired human immunodeficiency virus type 1 infection. *N Engl J Med* 321:1791-1796,1989.
21. Rubinstein A, Calvelli C. Acquired immunodeficiency in children. *Pediatr Rev* 10:165-169, 1988.
22. Rosenberg ZF, Fauci AS. Immunopathology and pathogenesis of HIV infection In: *Pediatric AIDS: The challenge of HIV infection in infants, children and adolescents*, 2<sup>nd</sup> edition: 115-127. Pizzo AP, Wilfert CM, editors. Baltimore: Williams and Wilkins, 1994.
23. Russell C, Lay KM. Natural history of candida species and yeasts in the oral cavities of infants. *Arch Oral Biol* 18:957-962,1973.
24. Ketchum L, Berkowitz RJ, McIlveen L, Forrester D, Rakusan T: Oral findings in seropositive children. *Pediatric Dentistry* 12:143-146,1990.
25. Katz MH, Matrucci MT, Leggott PJ, Westenhous H, Greenspan JS, Scott GB.: Prognostic significance of oral lesions in children with perinatally acquired human immunodeficiency virus infection. *Am J Dis Child* 147:45-48,1993.
26. Samaranayake LP. Oral mycoses in HIV infection. *Oral Surg Oral Med Oral Path* 73:171-180,1993.
27. Velegraki A, Nicolatou O, Theodoridou M, Mostrou G, Legakis NJ: Paediatric AIDS—related linear gingival erythema: a form of erythematous candidiasis? *J Oral Pathol Med* 28:178-182,1999.
28. Meis JF, Ruhnke M, DePauw BE, Odds FC, Siegert W, Verweij PE: *Candida dubliniensis* candidemia in patients with chemotherapy-induced neutropenia and bone marrow transplantation. *Emerg Inf Dis* 5:Dispatches, Article #3, 1999.
29. Meiller TF, Jabra-Rizk MA, Baqui AAMA, Kelley JI, Meeks VI, Merz WG, Falkler Jr. WA: Oral *Candida dubliniensis* as a clinically important species in HIV-seropositive patients in the United States. *Oral Surg, Oral Med, Oral Pathol* 88:573-580, 1999.
30. Baqui AAMA, Meiller TF, Jabra-Rizk MA, Zhang M, Kelley JI, Falkler Jr. WA: Association of HIV viral load with oral diseases. *Oral Diseases* 5:294-298, 1999.

## ABSTRACT OF THE SCIENTIFIC LITERATURE



### CEPHALOMETRIC EVALUATION OF THE TWIN-BLOCK APPLIANCE

The purpose of this study was to compare an experimental group of patients who were treated with the Twin-block appliance to a matched group of control subjects using cephalometric data. There were 30 experimental subjects (14 males and 16 females). Their class II division I malocclusion was treated with the following 3 phases. 1) semi-rapid maxillary expansion and alignment of the maxillary arch, 2) correction of the class II relationship with the Twin-block appliance, 3) retention with a maxillary removable appliance with a "very steep anterior bite plane". Each treatment case was individually matched to a control subject in regards to age, sex, and observation time. The author emphasized that the results were "compared to twice the method error to see if the treatment change was clinically significant". The following cephalometric measurements showed both statistically significant differences and also showed twice the method error. There was a significant reduction in overjet. The ANB angle was significantly reduced which was mainly the result of an increase in the SNB angle. "The upper incisor angulation was significantly reduced with the interincisal angle correspondingly increased".

**Comments:** There appears to be more variables in the treatment protocol than just the use of the Twin-block appliance. The author also used "semi-rapid maxillary expansion and alignment of the upper arch" and retention with "an upper removable appliance with a very steep anterior bite plane" when treating these patients. **JEP**

**Reprint Information:** M.J. Trenouth, BSc, BDS, MDS, PhD, FDS, DDO, DOrth, Royal Preston Hospital, Sharoe Green Lane, Preston PR2 9HT, England

**Cephalometric evaluation of the Twin-block appliance in the treatment of Class II Division I malocclusion with matched normative growth data.** Trenouth MJ. *Am. J of Ortho. and Dentofacial Orthopedics*, Vol.117-1:54-59, 2000. 35 references