

## Comparing treatment options for occlusal surfaces utilizing an invasive index

Carole McKnight-Hanes, DMD David R. Myers, DDS, MS  
Fouad S. Salama, BDS, MS William O. Thompson, PhD  
James T. Barenie, DDS, MS

### Abstract

*The purpose of this project was to develop an invasive index to: 1) compare the treatments recommended by dentists for the occlusal surfaces of molars; 2) compare the invasive index score of each tooth with the extent of the carious lesion as determined by electrical resistance and histological examination; and 3) compare the relative extent of the total crown destruction resulting from the carious lesion and the cavity preparation.*

*Twenty dentists examined 19 extracted permanent molar teeth using a #23 explorer and selected the most appropriate treatment from the following options: no treatment (score 0), occlusal sealant (score 1), preventive resin (score 2), occlusal amalgam (score 3). The invasive index scores determined for each dentist and each tooth were compared using an analysis of variance. The electrical conductivity of each tooth was measured with an electronic caries detector (Vanguard™). Electrical resistance scores were compared to the invasive index scores and to a histological examination.*

*The results demonstrate that the invasive index is a useful means to compare treatments recommended by different dentists. The invasive index suggests there is considerable variation among dentists in the treatment they recommend for occlusal surfaces. Electrical resistance testing did not provide helpful information for treatment planning of questionably carious occlusal surfaces.*

### Introduction

The clinical diagnosis of early pit and fissure caries along with the development of new materials has created a dilemma for dentists who treat children. The occlusal surfaces of the permanent molars are the surfaces most likely to become carious in children 5–17 years of age (Miller et al. 1981). Since these teeth must last for the patient's lifetime, an early accurate diagnosis followed by appropriate treatment has important ramifications for the patient's long-term dental health. New

developments in diagnostic instruments and restorative materials have implications for the management of occlusal carious lesions.

A recent study (Weerheijm et al. 1989) suggests that due to the changing picture of occlusal caries, the clinical diagnosis of pit and fissure caries has become even more difficult. The traditional use of visual assessment of the appearance of the enamel and tactile evaluation with an explorer (Radike 1972) remain imprecise at best (Rock 1987; Weerheijm et al. 1989). The size and shape of the explorer, the force applied and the judgment of the examiner all influence the diagnosis (Haupt et al. 1985). An additional diagnostic tool, based on the fact that electrical conductivity increases in demineralized enamel, is currently available (Vanguard™, Massachusetts Mfg. Corp: Cambridge, MA, 1984; White et al. 1978). Clinical studies suggest that the Electronic Caries Detector (Vanguard) is superior to the explorer based on the three criteria of sensitivity, specificity and consistency (White et al. 1981). An in vitro correlation has been demonstrated between the electrical resistance and the extent of the carious lesion. Radiographs provide minimal diagnostic information in the detection of occlusal caries (Flaitz et al. 1986). However, bite-wing radiographs may be of some benefit in the individual clinical examination (Weerheijm et al. 1989). The use of slides of the occlusal surfaces to aid in the diagnosis of questionably carious teeth also has been advocated (Weerheijm et al. 1989). Transillumination for caries detection appears more helpful for proximal rather than occlusal surfaces (Rock 1987). Another approach to caries diagnosis currently under investigation is the use of lasers (Bjelklagen et al. 1982). At the present time at the clinical level, in spite of technological experimentation, the diagnosis of pit and fissure caries is most frequently made on the basis of a mirror, light, and explorer examination.

The traditional options for managing occlusal carious lesions include either providing no treatment or placing an occlusal amalgam restoration. Providing no treatment increases the risk of allowing a carious lesion to progress to the point of extensive destruction of the tooth. Placing an amalgam restoration is invasive and requires cutting sound as well as diseased tooth structure to establish proper resistance and retention, while eliminating the caries susceptible pits and fissures (Meiers and Jensen 1984). Removal of sound tooth structure may increase the long-term possibility of pulp damage or cusp fracture (Haupt et al. 1986).

Acid etch resin bonding procedures, including occlusal sealants and composite resin/sealant restorations, have expanded the options available for treating occlusal carious lesions. Sealants have been shown to be effective in preventing carious lesions in sound pits and fissures (Mertz-Fairhurst et al. 1984). Sealants also may be of value in treating questionable and even carious occlusal surfaces without mechanical invasion of sound tooth structure (Handelman et al. 1986; Mertz-Fairhurst et al. 1986). Composite resin/sealant restorations require minimal tooth preparation and therefore are less invasive than traditional occlusal amalgam restorations. Composite resin/sealant restorations have been employed successfully to treat occlusal lesions (Simonsen 1980).

Despite the fact that dentists have an additional diagnostic instrument and a range of treatment procedures of varying invasiveness available, there is little information as to how dentists might employ these options to manage occlusal carious lesions. The purpose of this project was to develop and use an invasive index to:

1. Compare the treatments recommended by a group of dentists for the occlusal surfaces of molar teeth
2. Compare the invasive index score of each tooth with the extent of the carious lesion as determined by electrical resistance and histological examination
3. Compare the relative amount of crown destruction resulting from the combination of the carious lesion and the cavity preparation required for various types of restorative procedures.

## Method

Nineteen extracted permanent molar teeth were selected to provide a typical clinical spectrum of occlusal conditions ranging from apparently sound to extensive occlusal caries. The teeth were assigned random numbers and mounted on a board to simplify handling. Twenty dentists examined each of the extracted teeth using a #23 explorer. The dentists included recent graduates, dentists with several years experience, gen-

eral dentists and pediatric dentists. All the dentists treated children and employed the treatment options included in the study in their practice. The dentists were to assume each tooth was a first permanent molar in a 7-year-old patient. The instructions to the dentists were to recommend treatment for the occlusal surface of each tooth from the following options:

1. No treatment (score = 0)
2. Occlusal sealant (score = 1)
3. Preventive resin restoration (score = 2)
4. Occlusal amalgam restoration (score = 3).

By calculating the mean of the scores an invasive index was determined for each dentist and for each of the 19 teeth. Comparisons were made of the invasive indices of the dentists and of the teeth using an analysis of variance.

The electrical conductivity of each tooth was measured with an electronic caries detector (Vanguard) essentially as described by Flaitz et al. (1986). Three examiners independently scored each of the teeth with the electronic caries detector. The mean of the three electrical resistance scores was calculated for each tooth and compared to the mean invasive index score.

Finally each tooth was sectioned through the apparently carious area and examined under a dissecting microscope at 2x magnification. Each tooth was scored as follows:

1. No caries (score = 0; Group A)
2. Enamel caries short of the DEJ or discoloration of the dentin without obvious enamel lesion, (score = 1; Group B)
3. Enamel and dentinal caries (score = 2; Group C).

## Results

The mean invasive index scores for each dentist based on the treatments recommended for the 19 teeth ranged from 1.2 to 2.3. The invasive index of each dentist is shown in Fig 1 (see next page).

The standard deviation for the treatments recommended by the examining dentists was used as a measure of treatment variability and is shown in Fig 2 (see next page). The standard deviation ranged from 0.6 to 1.35.

Table 1 (see next page) reports the mean invasive index and the standard deviation of the teeth by histological group. The means ranged from 0.875 for the teeth with no evidence of caries (Group A); 1.660 for those teeth with enamel caries short of the DEJ, or with discoloration of the dentin without obvious enamel lesions (Group B), to 2.531 for the teeth with enamel and dentinal caries (Group C). The differences between the mean invasive indices of the histological groups was significant ( $P < .001$ ) as determined by a Mann-Whitney rank

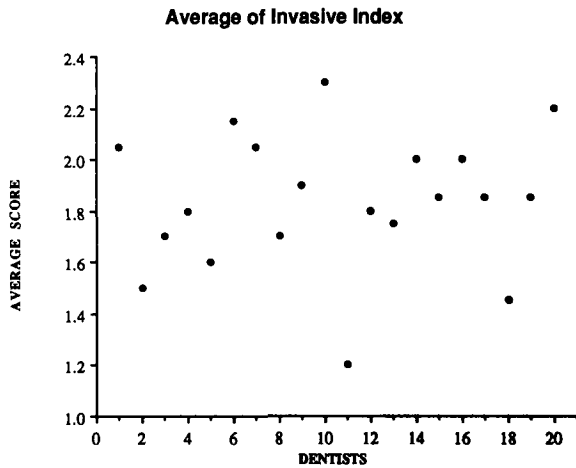


Fig 1. The mean invasive index score for each of the 20 dentists.

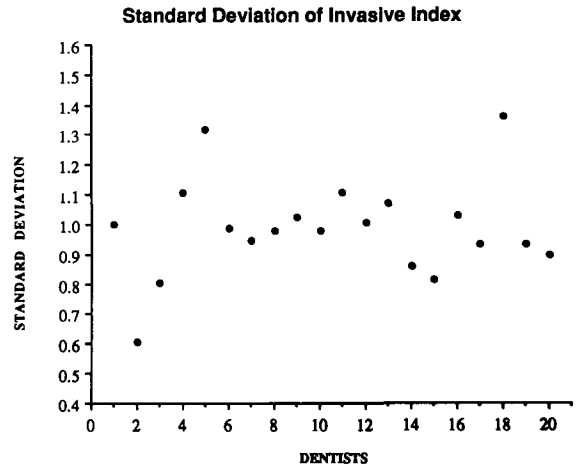


Fig 2. The standard deviation of the mean invasive index for each dentist.

TABLE 1. Invasive Index by Histology Group

Group	N	Average	Standard Deviation
A	6	0.875	0.108
B	5	1.660	0.479
C	8	2.531	0.614

sum test. This statistical test was used rather than a traditional analysis of variance because of the unequal variances in the histology groups.

The electrical resistance score for each group is shown in Table 2. The mean electrical resistance ranged from 0.611 for the sound teeth (Group A) to 3.200 for the teeth with enamel caries or discolored dentin (Group B) to 8.583 for the teeth with enamel and dentin caries (Group C).

The association between the electrical resistance and the invasive index is shown in Fig 3. The electrical resistance scores obtained by each tooth are plotted by histological group in Fig 4 (see next page).

## Discussion

The invasive index scores of the individual dentists ranged from 1.2 to 2.3, indicating that there was considerable variation in the treatment recommended for the occlusal surfaces of the teeth. The standard deviation of the invasive indices provides insight regarding the variation of treatments recommended by each dentist.

TABLE 2. Electric Resistance by Histology Group

Group	N	Average	Standard Deviation
A	6	0.611	0.772
B	5	3.200	2.193
C	8	8.583	0.850

A low standard deviation indicates that a dentist recommended a limited range of treatment (i.e., tends to use one treatment) whereby a larger standard deviation indicates that a dentist recommended a broader range of treatment options. The two-way analysis of variance demonstrates a highly significant difference ( $P < .0001$ ) in the invasiveness of the treatments recommended by the dentists. Therefore, some dentists limited themselves to one or two treatment options (i.e., no treatment or an occlusal amalgam), while others employed the entire spectrum including sealants and preventive resins.

Examination of the cross sections of each tooth under a dissecting microscope confirmed that the electrical

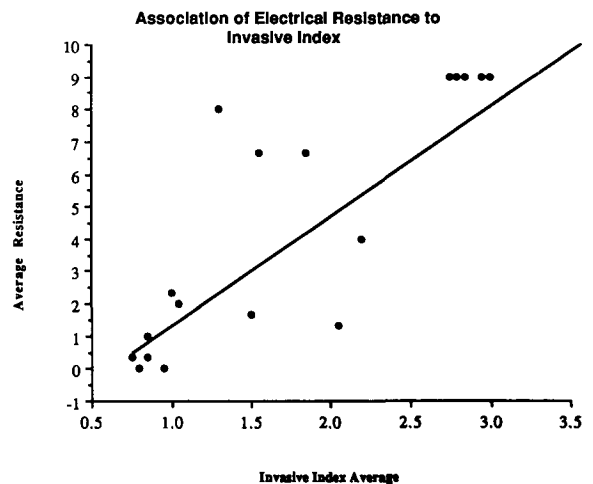


Fig 3. The association between the electrical resistance scores and the invasive index.



Electrical resistance testing did not provide helpful information for treatment planning for questionably carious occlusal surfaces.

Dr. McKnight-Hanes is associate professor; Dr. Myers is dean and Merritt Professor; Dr. Salama is senior resident; and Dr. Barenie is professor and acting chairman; all are in the department of pediatric dentistry at the School of Dentistry, Medical College of Georgia, Augusta, GA. Dr. Thompson is director of Research Computing and Statistics at the college.

Bjelklagen H, Sundstrom F, Angmar-Mansson B, Ryden H: Early detection of enamel caries by the luminescence excited by visible laser light. *Swed Dent J* 6:1-7, 1982.

Flaitz CM, Hicks MJ, Silverstone LM: Radiographic, histologic, and electronic comparison of occlusal caries: An in vitro study. *Pediatr Dent* 8:24-28, 1986.

Handelman SL, Leverett DH, Espeland MA, Curzon JA: Clinical radiographic evaluation of sealed carious and sound tooth surfaces. *J Am Dent Assoc* 113:751-54, 1986.

Haupt M, Eidelman E, Shey Z, Fuks A, Chosek A, Shapira A: The composite/sealant restoration. Five year results. *J Prosthet Dent* 55:164-68, 1986.

Haupt M, Fuks AB, Eidelman E: Measuring the stickiness of pits and fissures in enamel. *Clin Prev Dent* 7:28-30, 1985.

Massachusetts Manufacturing Corp: Instruction Manual, Vanguard Electronic Caries Detector. Cambridge, MA, 1984.

Meiers JC, Jensen ME: Management of the questionable carious fissure: Invasive vs non-invasive techniques. *J Am Dent Assoc* 108:64-68, 1984.

Mertz-Fairhurst EJ, Fairhurst CW, Williams JE, Della-Guistina VE, Brooks JD: A comparative clinical study of two pit and fissure sealants. Seven year results in Augusta, GA. *J Am Dent Assoc* 109:252-55, 1984.

Mertz-Fairhurst EJ, Schuster GS, Fairhurst CW: Arresting caries by sealants: Results of a clinical study. *J Am Dent Assoc* 112:194-97, 1986.

Miller AM, Brunelle JA, Carlos JP, Scott DB: The prevalence of dental caries in United States children, 1979-1980. U.S. Department of Health and Human Services, NIH pub. no 82-2246, 1981.

Radike AW: Criteria for diagnosis of dental caries in Proceedings of the Conference on the Clinical Testing of Cariostatic Agents. October 14-16, 1968. Chicago: American Dental Association, pp 87-88, 1972.

Rock WP: The diagnosis of early carious lesions—a review. *J Paediatr Dent* 3:1-6, 1987.

Simonsen RJ: Preventive resin restorations: Three-year results. *J Am Dent Assoc* 100:535-39, 1980.

Weerheijm KL, Van Amerongen WE, Eggink CO: The clinical diagnosis of occlusal caries: problem. *J Dent Child* 56:196-200, 1989.

White GE, Tsamtsouris A, Williams DL: Early detection of occlusal caries by measuring the electrical resistance of the tooth. *J Dent Res* 57:195-200, 1978.

White GE, Tsamtsouris A, Williams DL: A longitudinal study of electronic caries detection of occlusal caries. *J Pedod* 5:91-101, 1981.

## Patient turnoffs

It's easy to establish good will with your patients, but just as easy to break down the positive relationship you've established. *Dynamic Dental Strategies*, an ADA marketing newsletter, lists eight common patient turnoffs:

1. Talking about, not to, the patient. Especially true of children, but affecting adults as well, this tendency on the part of the dental team makes the most important person—the patient—feel left out.
2. Ignoring the patient at the reception desk. The patient should be greeted by the receptionist on the way in, as well as on the way out. Furthermore, the patient should not have to wait to pay or schedule the next appointment.
3. Forgetting that the patient can see and hear practically everything happening in the dental office. If you need to discuss practice management problems with the staff, hold these discussions in private, not in the operatory.
4. Gossiping in front of the patient. Don't talk about other patients—or other staff members—in front of patients. They'll wonder what you say about them when they leave!
5. Not answering the phone promptly. Patients expect you to be organized and ready to receive phone calls.
6. Forgetting the patient's name—or misspelling it.
7. Failing to inform before you perform. A considerable amount of anxiety on the patient's part can be avoided if he or she understands the next step before it happens.
8. Sending mixed signals on fees and payment options. If the back office and the front office send the patient different messages, the entire office lacks credibility.