



# Nutritional rickets in a 2-year-old child: case report

Dónal McDonnell, BDS, FFD, MSc, FRCD(C) Gary Derkson, DMD  
Lewei Zhang, BDS, PhD, FRCD(C) Jean Hlady, MD, FRCP(C)

**O**steomalacia is a disorder of the adult skeleton in which mineralization of newly formed bone is defective. In children, the disease is manifested as rickets. Bone mineralization requires normal plasma concentrations of calcium, phosphate, and vitamin D. A deficiency of these factors results in impaired cartilage calcification, widening of the ends of long bones, abnormal mineralization of bone matrix, and skeletal deformities.

Vitamin D is a fat-soluble vitamin that acts very much like a hormone in the control of calcium and phosphorus homeostasis. In general, vitamin D is responsible for calcium uptake from the intestine, bone calcium mobilization, and renal calcium reabsorption. In vitamin D deficiency, the accumulation of osteoid and the lack of mineralization result in a soft skeleton, deformity, or fracture.

Rickets usually is classified according to the underlying cause. Hutchison and Bell<sup>1</sup> indicate that the most common cause of vitamin D deficiency in the United States is intestinal malabsorption associated with diseases of the small intestine, hepatobiliary tree, and pancreas. Nutritional deficiency and sunlight deprivation are uncommon causes, and with the addition of vitamin D as a food additive, nutritional rickets is now rare in North America.<sup>1,2</sup> However osteomalacia has been reported in immigrant populations in the United Kingdom and is attributed to ethnic traditions such as traditional clothing, women staying indoors, and dietary patterns.<sup>3-5</sup>

This report illustrates a case of nutritional rickets in a 2.5-year-old child born in Canada who had dental radiographic evidence of rickets affecting the jaws. The medical, hematological, and radiological investigations, and histopathological findings of the extracted teeth are reported. A successful response to treatment is illustrated with changes in the radiological appearances of the jaws.

## Case report

### Chief complaint and history of present illness

A female, aged 2 years and 6 months, was referred by her general dentist to British Columbia's Children's Hospital dental department with facial pain and swelling. Oral antibiotics had been prescribed and the symp-

toms were improving when the child was first seen. The child was born in Canada to non-English speaking Vietnamese parents. Clinical examination was difficult due to lack of cooperation, but did reveal many grossly carious teeth. Arrangements were made for examination and treatment under general anesthesia.

### Physical examination

The patient weighed 19.2 kg (> 95th percentile) and was 87 cm tall (25th percentile). Preoperative assessment by the pediatrician revealed a waddling gait, and a hip radiograph (not shown) showed normal acetabular angles, metaphyseal lucency, and medial beaking. Hemoglobin was within normal limits.

### Oral examination

Under general anesthesia in the operating room, clinical examination confirmed a complete primary dentition and a discharging sinus in the buccal sulcus associated with the carious maxillary right primary first molar. Carious lesions were noted in the following teeth: all maxillary primary incisors, all primary first molars, and the mandibular primary central incisors.

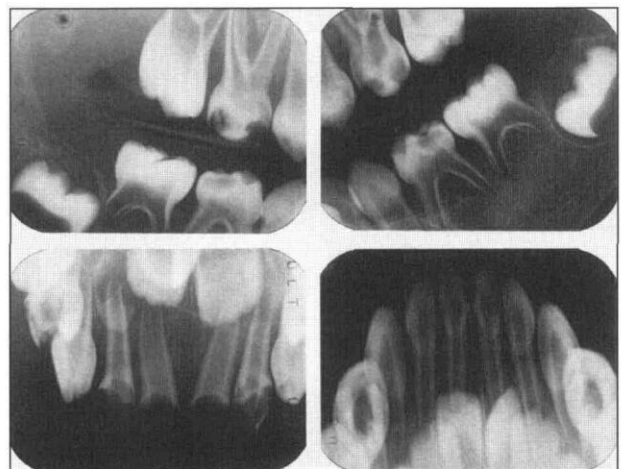
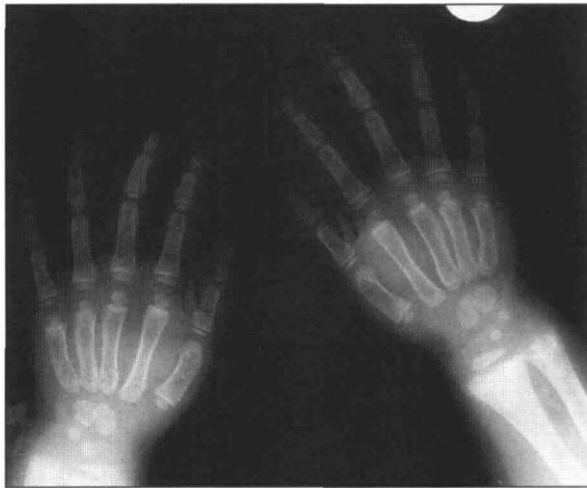


Fig 1. Intraoral radiographs showing the grossly carious teeth, the size of the pulp chambers, the crypts of the developing teeth, the outline of which is attenuated (as is the lamina dura). The trabecular pattern is sparse, and the inferior cortex on the left side appears thinned. The endotracheal tube accounts for the radiopacity in the incisor region.



**Fig 2. Hand radiographs showing widening of the growth plates and generalized demineralization.**

Intraoral dental radiographs (Fig 1) illustrate the extent of the carious lesions and the large size of the pulp chambers with pulpal horn extension close to the dentoenamel junction, especially in the mandibular primary first molars. Hypoplasia was not evident in the unerupted teeth. The bone trabeculation in the anterior mandible and maxilla was very sparse. The lamina dura and the crypts of the developing teeth were present, but attenuated. On the left side, the cortices of the inferior alveolar canal were evident and the inferior cortex of the mandible appeared thinned, but the other side was not available for comparison.

### Dental treatment

The maxillary primary central and lateral incisor teeth and the maxillary primary first molar teeth were extracted and submitted for histopathological examination. Hemorrhage was controlled easily by local pressure and postoperative recovery was uneventful.

### Supplemental testing

Further hematological and radiological investigations were carried out. The alkaline phosphatase level was 2264 U/L, approximately seven times the upper level of the normal range, and both serum calcium and phosphorus levels were reduced (Table 1). Hand (Fig 2) and knee radiographs (not shown) showed sparse trabeculation with generalized demineralization and a lack of cortical outline. Some growth plates were widened and showed findings consistent with rickets. Dietary analysis revealed a diet of rice and various types of Vietnamese foods that were low in calcium but high in calories. About 1 L of soya milk (not vitamin D-fortified) was consumed per day, with no cow's milk.

### Histological examination

When extracted teeth were examined microscopically, all were found to be severely carious with a thick layer of dental plaque directly abutting the carious dentin. The dentinal tubules seemed unremarkable in the crowns but decreased markedly in the roots. The

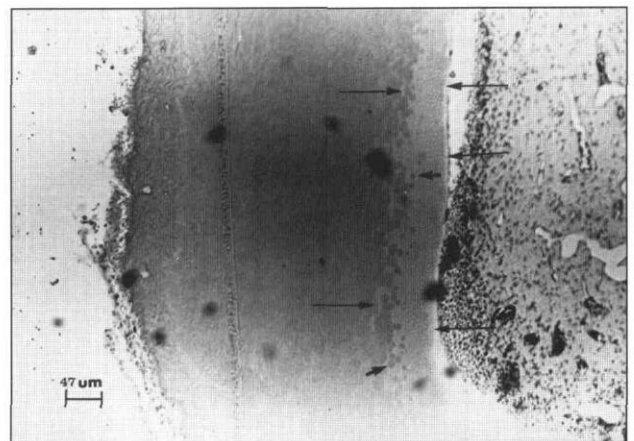
**TABLE. NORMAL, BASELINE AND POST-TREATMENT CALCIUM, PHOSPHORUS AND ALKALINE (Alk) PHOSPHATASE**

	Calcium mmol/L	Phosphorus mmol/L	Alk Phosphatase U/L
Normal	2.17-2.45	1.32-2.10	145-320
Baseline	2.14	0.79	2264
Completion	2.39	1.56	26

width of the predentin layer in the crowns seemed normal, but was three to four times wider than normal in the molar roots and two to three times wider than normal in the incisor roots (Fig 3). Irregularity of the dentin-predentin border, interglobular dentin, and focal areas of external root resorption were noted in all teeth. In areas with no root resorption, the thickness of cementum varied from normal to hardly identifiable. Bone trabeculae present were primarily immature woven bone and showed widened osteoid seams.

### Medical management

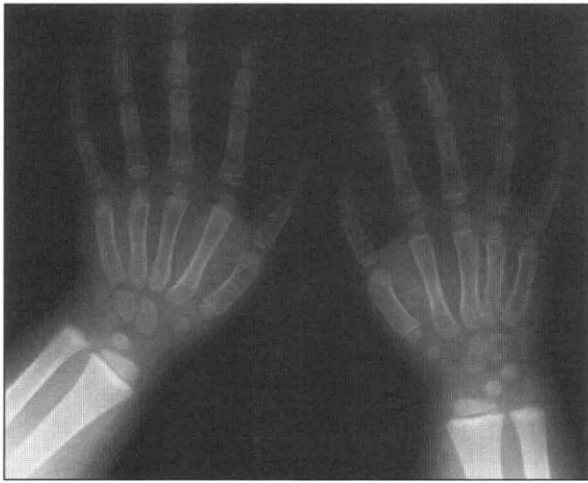The clinical, biochemical, and radiographic evidence confirmed the diagnosis of rickets. Oral vitamin D and Calcium Sandoz (Sandoz Canada Inc., Dorval, QB) were prescribed. An initial drop in the serum calcium level was easily corrected by adjusting the medication. The child was discharged after 10 days and reviewed on an outpatient basis. With treatment and a change in diet to include cow's milk, the alkaline phosphatase,



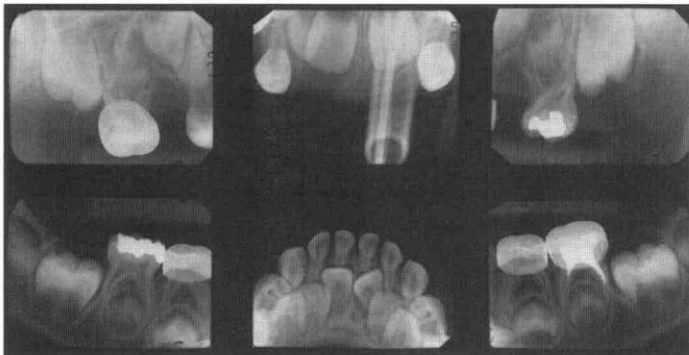
**Fig 3. Photomicrographs showing markedly widened predentin (long arrows) in the presence of interglobular dentin (short arrows) in the root of an incisor tooth.**

calcium, and phosphorous returned to normal levels, thus confirming a nutritional cause of the rickets and excluding other causes. Follow-up radiographs of the hands (Fig 4) and knees (not shown), showed evidence of healing. Walking had improved and the waddling gait had disappeared. The child's weight was still above the 95th percentile and her height had increased to the 80th percentile. After 8 months, the patient was discharged to the care of her family physician.

The patient was lost to dental follow-up for 2 years. On further review, the remaining carious teeth were



**Fig 4.** Post-treatment radiographs showing improvement in the appearance of the growth plates, which are more sharply defined and better mineralized than in Fig 2.



**Fig 5.** Intraoral radiographs dated 2 years after beginning treatment, illustrating better outlining of the lamina dura, the inferior cortex of the mandible, and increase in the trabecular pattern within the mandible. All permanent second premolars suggest hypoplasia of the crowns. The endotracheal tube is visible in the upper incisor region.

restored and radiographs showed a normal trabecular pattern, an improvement in the outline of the crypt cortices around the unerupted teeth, and a denser inferior cortex of the mandible (Fig 5). This pattern of improvement was similar to the changes seen in the other bones.

## Discussion

Nutritional rickets is rare in North America, and this report illustrates the investigation and medical management of a patient who initially presented with facial cellulitis coincidental to the diagnosis of rickets. The diagnosis of rickets based on dental radiographic changes alone may be difficult as there may be no specific features evident.<sup>6-8</sup> Poyton and Pharoah<sup>7</sup> report the following radiographic features may be seen: osteoporosis, the crypts of the unerupted teeth and lamina dura may be attenuated, and hypoplasia of enamel may occur. Goaz and White<sup>9</sup> and Gibilisco<sup>10</sup> report thinning of the inferior cortex of the mandible and

state that radiographic defects in the jaws in nutritional rickets are uncommon.

The large pulp chambers and pulp horns, at the expense of dentin, combined with the extent of dental caries present are perhaps more suggestive of vitamin D resistant rickets.<sup>6, 11, 12</sup> Osteoporosis and hypophosphatasia may give a similar appearance, which cannot be differentiated from rickets on the radiographic features alone.

Some studies indicate that clinical evidence of enamel hypoplasia is found in a high percentage of rachitic children,<sup>13, 14</sup> although others found no correlation between enamel hypoplasia and rickets.<sup>15</sup> Opinion is divided on the susceptibility of hypoplastic teeth to caries.<sup>16-18</sup> However, there is general agreement that once caries has started in the hypoplastic tooth, it spreads more rapidly than in a nonhypoplastic tooth. Vitamin D deficient children have been found to have retarded eruption.<sup>19</sup> Few studies have reported the histopathological changes in dentin or cementum of vitamin D deficient patients. Recent studies are rare due to the rarity of rickets.

The general goals of medical treatment of rickets have been well described by Hutchison and Bell.<sup>1</sup> Vitamin D is the drug of choice and calcium supplements are also frequently used. Calcium absorption is usually low in patients with rickets; increasing calcium intake reduces the dose of vitamin D related compounds required for treatment. Diet analysis and investigation to exclude causes other than nutrition should be undertaken. Treatment continues until there is radiographic evidence of healing and a return to normal plasma concentrations of calcium, phosphorus, and alkaline phosphatase. The long-term prognosis should be good.

Nutritional rickets is a rare occurrence in North America, but with changing patterns of immigration and dietary habits associated with such populations, its occurrence may increase. The radiographic features suggestive of rickets in this patient at presentation showed changes in appearance following treatment, namely improvement in crypt outline, increase in trabeculation, and increase in density of the mandibular cortex. This case is reported because it illustrates some radiographic evidence of rickets in the jaw bones, which changed in appearance in response to appropriate medical treatment.

Dr. McDonnell is assistant professor and Dr. Zhang is associate professor, Department of Oral Medical and Surgical Sciences, University of British Columbia, Vancouver. Dr. Derkson is associate professor and head, Department of Dentistry and Dr. Hlady is a clinical professor, Department of Pediatrics, both at British Columbia's Children's Hospital, Vancouver. Mr. Harold Traeger photographed the illustrations.

1. Hutchison FN, Bell NH: Osteomalacia and rickets. *Semin Nephrol* 12:127-45, 1992.
2. Manolagas SC, Olefsky JM: *Metabolic Bone and Mineral Disorders*. New York: Churchill Livingstone, 1988, pp 103-92.

3. Stamp TCB, Exton-Smith AN, Richens A: Classical rickets and osteomalacia in Britain. *Lancet* 2:308, 1976. [Letter]
4. Holmes AM, Enoch BA, Taylor JL, Jones ME: Occult rickets and osteomalacia amongst the Asian immigrant population. *Q J Med* 42:125-49, 1973.
5. Pietrek J, Preece MA, Windo J, O'Riordan JLH, Dunnigan MG, McIntosh WB, Ford JA: Prevention of Vitamin D deficiency in Asians. *Lancet* 1:1145-48, 1976.
6. Worth H: Principles and Practice of Radiographic Interpretation. Chicago: CV Mosby Co, 1963, pp 341-43.
7. Poyton HG, Pharoah MJ: Oral Radiology, 2nd ed. Philadelphia: BC Decker Inc. 1989, 258-61.
8. Miles DA, Van Dis M, Kaugars GE, Lovas JGL: Oral and Maxillofacial Radiology: Radiologic/Pathologic Correlations. Philadelphia: WB Saunders Co. 1991, p 244.
9. Goaz PW, White SC: Oral Radiology: Principles and Interpretation, 2nd ed. St Louis: CV Mosby Co. 1987, pp 643-45.
10. Gibilisco JA, Ed. Stafne's Oral Radiographic Diagnosis, 5th ed. WB Saunders Co. 1985, pp 277-78.
11. Farman AG, Nortjé CJ, Wood RE: Oral and Maxillofacial Diagnostic Imaging. St Louis: Mosby-Year Book Inc. 1993, pp 338-42.
12. Langlais RP, Langland OE, Nortjé CJ: Diagnostic Imaging of the Jaws. Baltimore: Williams & Wilkins. 1995, pp 454-57
13. Dick JL: The teeth in rickets. *Proc R Soc Med* 9:83-91, 1916.
14. Grahén H, Selander P: The effect of rickets and spasmophilia on the permanent dentition. *Odontol Revy* 5:7-26, 1954.
15. Marshall-Day CD: Nutritional deficiencies and dental caries in Northern India. *Brit Dent J* 76:115-22, 143-47, 1944.
16. Anderson PG, Williams CHM, Halderson H, Summerfeldt C, Agnew RS: The influence of vitamin D in the prevention of dental caries. *Am Den Ass J* 21:1349-66, 1934.
17. Bibby BG: The relationship between microscopic hypoplasia and dental caries. *J Dent Res* 22:218, 1943. [Abstr #60]
18. Shelling DH, Anderson GM: Relation of rickets and vitamin D to the incidence of dental caries, enamel hypoplasia and malocclusion in children. *Am Den Assoc J* 23:840-46, 1936.
19. Speidel TD, Stearns G: Relation of vitamin D intake to age of infant at time of eruption of first deciduous incisor. *J Pediatr* 17:506-11, 1940

## The Newest Revelation from Kinder Crowns

# IncisalLock



**IncisalLock is an Exclusive Feature From Kinder Crowns**

- **Save Operatory Time**
- **Get Consistent Results**

### *Ask About our Crown Shortening Service!*

If you find that the stainless steel crowns are too long, right out of the box, we can trim them for you before we put the facing on; saving you valuable time.

**KinderCrowns**  
BY MAYCLIN®

**"The Aesthetic Alternative"**

**CALL OR FAX TODAY FOR MORE INFO OR TO TRY OUR RISK-FREE INTRO KIT!**

The new Kinder Crowns combine the best of the original with some revolutionary new ideas in pediatric restorations. A new hybrid composite which has a natural translucency mimics childrens teeth even better than before.

The most exciting concept in the new crowns is what we call **IncisalLock**. We use mechanical retention at the incisal area, the weakest point of ANY of these types of crowns. Our findings show in the majority of cases the incisal portion of the crown is filled with cement. We have utilized that to our advantage. The internal composite also helps strengthen the bond of the crown to the tooth.

Kinder Crowns are available in two shades, Pedo 1 and Pedo 2, and we specialize in kustomizing the crowns to your individual specifications. But perhaps the best reason to use Kinder Crowns is that they look like teeth. We don't do Chiclets! Call today!

MAYCLIN DENTAL STUDIOS, INC.  
2629 LOUISIANA AVE. SOUTH • MINNEAPOLIS, MN 55426

**1-800-522-7883**

(612) 926-1809, FAX (612) 926-6331