



Microcanals of dentin associated with maxillary primary anterior teeth

Su-Chieh Liu, DDS, MS Sally J. Marshall, PhD Scott L. Tomar, DMD, DrPH Grayson W. Marshall, DDS, MPH, PhD

Dr. Liu is currently in private pediatric dental practice in San Francisco, California; Dr. G. Marshall is professor and chair, Division of Biomaterials and Bioengineering, Department of Preventive and Restorative Dental Sciences, University of California, San Francisco; Dr. Tomar was previously with the Department of Dental Public Health and Hygiene and is currently with the Centers for Disease Control and Prevention, Atlanta, Georgia; and Dr. Sally Marshall is professor and vice-chair for Research, Department of Preventive and Restorative Dental Sciences, University of California, San Francisco, CA. Correspond with Dr. Grayson Marshall at graymar@itsa.ucsf.edu

Abstract

Purpose: This study was performed to estimate the prevalence of giant dentin tubules or microcanals in primary maxillary anterior teeth.

Methods: One hundred sixty eight extracted or exfoliated primary maxillary anterior teeth were sectioned and examined by optical microscopy and image analysis. Differences in the proportion of teeth with microcanals among tooth types were tested by using the Pearson chi-square test.

Results: Microcanals, having the appearance of enlarged dentin tubules, were found in approximately 20% of primary central and lateral incisors, but were significantly less prevalent (3%) in primary cuspids. Microcanals occurred in a mesial distal axial plane and ran between the DEJ and the pulp chamber. When present they numbered between 1 and 43, with mean numbers of 20 and 16 in central and lateral incisors, respectively. The microcanals ranged in size between 5 and 70 μm , compared to normal dentin tubule diameters of approximately 1 μm .

Conclusions: Microcanals are relatively common in primary maxillary incisors, but uncommon in primary cuspids. Additional work is needed to establish their prevalence in various teeth of both primary and permanent dentition. (*Pediatr Dent* 22:318-320, 2000)

Giant dentin tubules were first described by Tronstad¹ as a series of round holes or slits across the middle of dentin in permanent incisors. Miller² found similar holes using microradiography in an unerupted primary incisor. Giant tubules or microcanals³ are not rare, and have been found regularly in human, red deer,⁴⁻⁷ bovine,⁸⁻¹⁰ and rat teeth.⁷ These features have an appearance similar to normal dentin tubules¹¹ but are significantly larger having lumens of 5-40 μm diameter, as compared to normal dentin tubule diameters of approximately 1 μm , and are often surrounded by a thick cuff of mineral similar to peritubular dentin.⁴ The microcanals are usually found in mesiodistal axial plane, extend from the DEJ to the pulp chamber, and typically range in number from 0-30. In a recent study of anterior primary dentin, 4 of 20 maxillary anterior teeth contained such microcanals, but no microcanals were found in primary cuspids.¹² Since there is little information on the prevalence of these features, and there may be significant differences in the prevalence of microcanals with

tooth type, this study examined differences in prevalence and number of microcanals in maxillary anterior primary teeth among a larger sample of teeth.

Methods

One hundred sixty-eight extracted or exfoliated primary maxillary anterior teeth were included in the study. Teeth were excluded from the study if they had pulp exposures or severe caries. The teeth were collected from the pediatric dental clinics at UCSF, Children's Hospital Oakland, and local pediatric dental offices in the San Francisco area. All teeth were collected according to a protocol which was approved by the UCSF Institutional Committee on Human Research. The reasons for extraction included severe caries, trauma, esthetic concerns, occlusal discrepancies, or normal exfoliation. Following collection of all teeth, 7 teeth were excluded following sectioning, based on the presence of severe caries. Teeth with severe caries were excluded from the study because the caries could have destroyed evidence of the presence of microcanals. The teeth were stored in 10% buffered formalin and sterilized by gamma radiation. The teeth were identified and labeled with the universal alphabetical system (C-H) and the caries status of each tooth was recorded. A slow speed water cooled diamond saw (Buehler Isomet Model 11-1180 Saw, Buehler Ltd., Lake Bluff, IL) was used to make a 2.3 mm section of each tooth by mak-

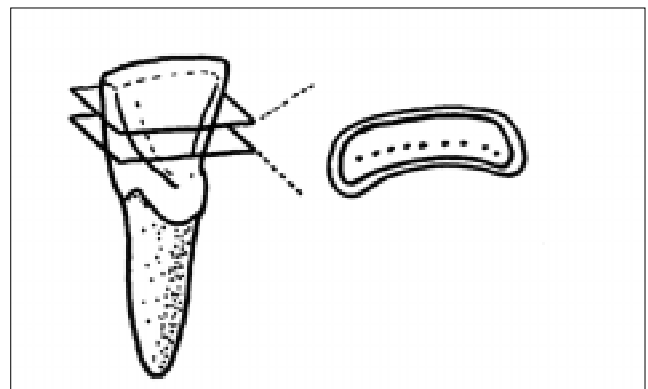


Fig 1. Schematic diagram of tooth sectioning for observation of microcanals.

Table 1. Microcanal Prevalence in Maxillary Anterior Primary Teeth

Tooth Group	Number of Teeth			Prevalence %
	N	Present	Absent	
C	11	0	11	0
D	23	7	16	30
E	46	6	40	13
F	43	13	30	30
G	20	2	18	10
H	25	1	24	4
Tooth Type				
Central Incisors	89	19	70	21
Lateral Incisors	43	9	34	21
Cuspids	36	1	35	3*
Total	168	29	139	17

*Cuspids had a significantly lower prevalence compared to primary lateral or central incisors by χ^2 test of association ($P < 0.05$).

ing two saw cuts parallel to the incisal edge with the first cut 2 mm below the incisal edge, as shown in Fig 1. Each section was embedded and polished using water cooled abrasive strips from 600 through 1200 grit and then using aqueous alumina polishing slurries of 6.0 through 0.3 μm on felt polishing cloth.

The polished section from each tooth was studied by a single observer on a reflected light microscope equipped with photo and video image system (Olympus BX 50 Microscope System, Olympus Optical Co., Ltd., Tokyo, Japan), and some samples were examined by adding a Nomarski DIC lens for improving focus at higher magnification. The images were digitized and transferred to the computer, the number of microcanals were counted and the lumina were measured using an image analysis system (BioQuant/TCW Image Measurement System for Windows, R & M Biometrics, Inc., Nashville, TN). Since the lumina were often irregular in shape, the maximum dimension was used as a measure of the microcanal size. The data were keyed twice into the computer to assure accuracy of the data entry, and statistically analyzed. No errors in data entry were detected. The prevalence and number of microcanals were calculated separately by tooth group and type. Differences in the proportion of teeth with microcanals among tooth types were tested using the χ^2 test.

Results

Fig 2 shows a transverse section from a primary maxillary central incisor showing the line of 43 microcanals in dentin. In all teeth containing microcanals, the microcanals were in the mesial distal axial plane. The prevalence of microcanals is shown in Table 1. There were more lateral and central incisors containing microcanals as compared with cuspids. (χ^2 test of association, $P < 0.05$). There were also significant differences based on the right or left side between central and lateral incisors, but this probably reflects sample size rather than biological differences. Overall, approximately 20% of the incisors contained microcanals while less than 3% of cuspids contained

such features. The number of microcanals in a given tooth also varied widely, as shown in Table 2. One of the 36 cuspids studied contained 2 microcanals, while the number of microcanals in lateral and central incisors ranged from 1 to 43, with an average of about 20 in central incisors and 16 in lateral incisors. Initial examination also suggested that in teeth with multiple microcanals, the size of the canals might decrease systematically from the central to mesial or distal region (see Fig 2). The size of the microcanals varied from 5-70 μm in maximum dimension and the size was plotted versus position for each tooth. However, no pattern of size relative to particular location could be discerned in this sample of teeth.

Discussion

Although microcanals or giant tubules have been reported previously, they have largely been ignored by clinicians, since their size is still too small to attract attention by the unaided eye or low-magnification operating lenses. However, this study shows that the prevalence and number of microcanals depends on tooth type and that they are much more likely to occur and be in much larger numbers in maxillary incisors as compared to cuspids. Because maxillary primary incisors are

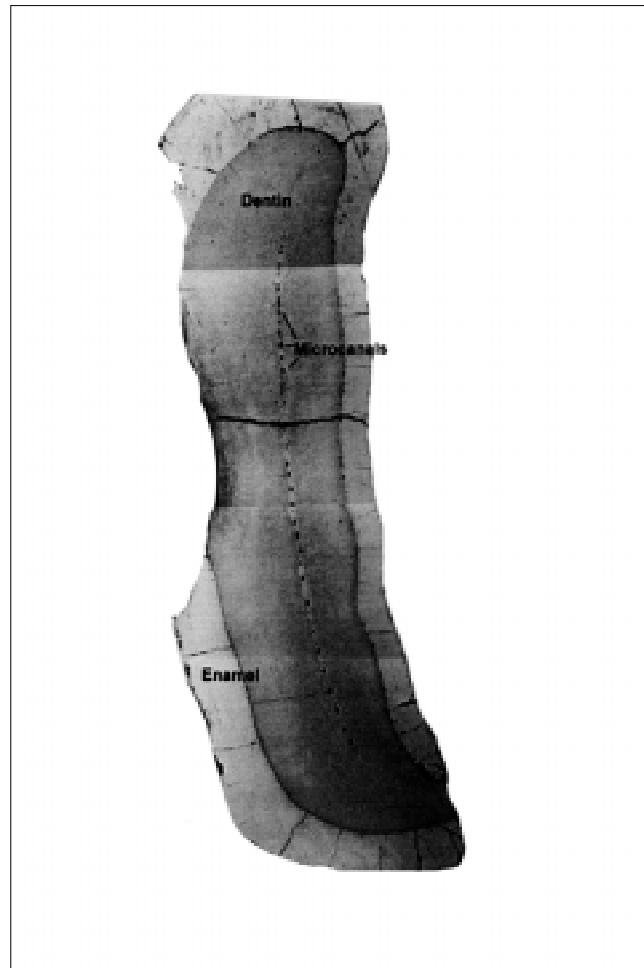


Fig 2. Optical micrograph of a polished section of a primary central incisor showing the mesial-distal arrangement of numerous microcanals—43 microcanals were identified in this sample, the maximum number seen in a single tooth. Original magnification 50X.

frequent candidates for restorative treatment the presence of microcanals could make treatment more difficult.¹² This suggests that a more thorough study aimed at determining other epidemiologic factors associated with the prevalence of microcanals is warranted.

Two theories have been suggested for the origin of microcanals. Earlier workers believed that the giant tubules resulted from crowding of the odontoblasts during dentinogenesis.¹⁻³ However, contradictory evidence has been presented indicating that dentinal tubules circumvent the microcanal origins, few dentin tubules enter the microcanals, a blood vessel loop is often seen in the pulpal portion, cellular components are similar to pulp tissue, and the luminal caliber is approximately constant along the course of the microcanal.¹³ Dyngeland and Kvinnsland¹⁰ presented the vessel retraction hypothesis to account for these features. In this theory, blood vessels and associated cellular material lag behind the odontoblastic layer that forms the dentin, and therefore the microcanals are the result of the pathway of vessel retraction during tooth formation. This theory seems to explain most features of the microcanals, although it does not address the question of why particular tooth types should show differences in prevalence.

In summary, this work suggests that microcanals are a relatively common feature associated with primary maxillary anterior teeth, but the prevalence and number are much higher in primary incisors than in primary cuspids. If the hypothesis suggested as a result of this work, that microcanal occurrence systematically varies with tooth type is further demonstrated, then theories regarding their histogenesis should help to explain such differences. Information on prevalence of microcanals in other teeth and primary and permanent dentition are needed to determine if these developmental anomalies are important in dental health.

This work is based in part on a thesis submitted in partial fulfillment of the requirements for the MS degree at UCSF. This work was supported in part through NIH/NIDCR Grant P01 DE 09859.

References

1. Tronstad L: Optical and radiographic appearance of intact and normal human coronal dentine. *Arch Oral Biol* 17:847-58, 1972.
2. Miller J: Large tubules in dentin. *J Dent Child* 48: 269-71, 1981.
3. Agematsu H, Watanabe H, Yamamoto H, Fukayama M, Kanazawa T, Miake K: Scanning electron microscopic observations of microcanals and continuous zones of interglobular dentin in human deciduous incisal dentin. *Bull Tokyo Dent Coll* 31:163-73, 1990.

Table 2. Number and Range of Microcanals Present in Primary Maxillary Anterior Teeth

	Teeth Containing Microcanals			
	N	Minimum	Maximum	Mean (SD)
Tooth group				
C	0	0	0	0
D	7	9	39	19 (12)
E	6	2	40	20 (12)
F	13	2	43	20 (12)
G	2	1	13	7 (8)
H	1	2	2	2 (0)
Tooth type				
Central incisors	19	2	43	20 (12)
Lateral incisors	9	1	39	16 (12)
Cuspids	1	2	2	2 (0)
Total	29	1	43	18 (12)

4. Hals E: Observations on giant tubules in human coronal dentin by light microscopy and microradiography. *Scand J Dent Res* 91:1-7, 1983.
5. Hals E: Polarized light study of giant tubules in human and red deer coronal dentin. *Scand J Dent Res* 91:105-11, 1983.
6. Hals E, Cato Olsen H: Scanning electron and incident light microscopy of giant tubules in red deer dentin. *Scand J Dent Res* 92:269-74, 1984.
7. Hals E, Dyngeland T: Column-like structures following the course of dentinal tubules in bovine, red deer, and rat teeth. *Scand J Dent Res* 96:489-99, 1988.
8. Dyngeland T, Fosse G, Justesen B: Histochemical study of giant tubule content in dentin of unerupted cow incisors. *Scand J Dent Res* 92:177-82, 1984.
9. Dyngeland T, Fosse G: Light microscopic study of giant tubules in bovine dentin. *Scand J Dent Res* 94:381-93, 1986.
10. Dyngeland T, Kvinnsland S: In vitro study of the giant tubule collagen formation in bovine dentin by [³H]-proline incorporation. *Scand J Dent Res* 96:317-23, 1988.
11. Marshall GW, Marshall SJ, Kinney JH, Balooch M: The dentin substrate: structure and properties related to bonding. *J Dent* 25:441-458, 1997.
12. Sumikawa DA, Marshall GW, Gee L, Marshall SJ: Microstructure of primary dentin. *Pediatr Dent* 21:439-444, 1999.
13. Dyngeland T: Transmission electron microscopic study of giant tubules in bovine dentin. *Scand J Dent Res* 96:293-303, 1988.