

## Calcific metamorphosis/ internal resorption: a case report

Curtis G. Kuster, DDS, MS

### Abstract

*A commonly observed occurrence in pediatric dentistry is that of pulp chamber and root canal obliteration secondary to trauma. This report describes a case of calcific metamorphosis in a primary incisor reversing and undergoing internal resorption.*

### Introduction

A frequently observed, but infrequently reported phenomenon is that of complete or partial pulp chamber and root canal obliteration secondary to trauma. Microscopically, this calcific metamorphosis is characterized by multifocal, dystrophic calcifications usually composed of ill-defined secondary dentin.<sup>1,2</sup>

There are conflicting views regarding the treatment of pulpal obliteration in permanent teeth when no periapical radiographic change or pulp test response is manifested. Some state that no treatment is necessary.<sup>1,3,4</sup> They interpret calcification of the pulp chamber and root canal as being nature's root canal filling. Others view the calcification of the pulp chamber and root canal as a pathologic deterioration of the normal pulp.<sup>5,8</sup>

Primary teeth demonstrating calcific metamorphosis will generally be maintained in an apparently healthy state and will ultimately evidence normal root resorption. The number of these teeth which show subsequent radiographic changes or clinical symptoms is so small that management of calcific metamorphosis in primary teeth is generally limited to periodic observation.<sup>1,4,8,8</sup>

Cases have been reported of permanent teeth undergoing internal resorption and then reversing to a more normal state.<sup>9,10</sup> This report describes a case of calcific metamorphosis in a primary incisor reversing and undergoing internal resorption.

### Case Report

A white female, four years and one month of age was seen for her initial dental examination. A

complete oral and radiographic examination was performed.

The clinical examination revealed two maxillary primary central incisors which were slightly out of alignment with the remainder of the arch. All other clinical findings were within normal limits. The radiographic examination revealed that the maxillary right primary central incisor was undergoing calcific degeneration. The pulp chamber and root canal were approximately one-half the width of the maxillary left primary central incisor (Figure 1).

The patient's medical history was non-contributory. The dental history, taken from the mother, revealed that the patient had fallen approximately one year previously and had "bumped" the front teeth. The mother reported that the teeth were slightly mobile for several days, but they then seemed to tighten and she did not think any more about the incident. The patient did not complain of any discomfort during this time.

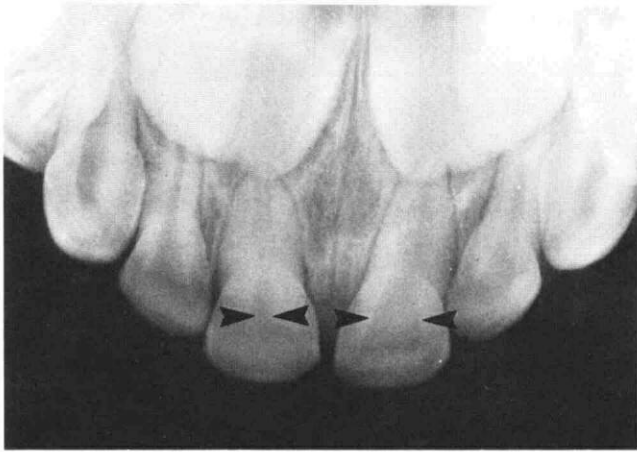
The mother was advised of the radiographic findings during the consultation and informed that the tooth would be observed closely at subsequent recall appointments. The child and parent were dismissed to be seen again for a yearly recall examination.

Ten months after this initial examination, the patient was seen on an emergency basis because of pain in the maxillary right primary central incisor while biting.

The clinical examination revealed a rather high degree of mobility of the affected tooth. The radiographic examination revealed a large area of internal resorption in the middle one-third of the tooth (Figure 2).

It was determined that the affected incisor was not restorable, thus the tooth was extracted. A prosthetic replacement was provided at subsequent appointments. The histologic evaluation of the tooth was consistent with the radiographic diagnosis of internal resorption.

Accepted: January 10, 1981



**Figure 1.** Maxillary right primary central incisor with pulp chamber and root canal one-half the width of the maxillary left primary central incisor.

## Discussion

After primary or permanent teeth have been traumatized, two common pathologic pulpal sequelae are either calcific metamorphosis or internal resorption.

Calcific metamorphosis is probably initiated by a stimulation of odontoblastic activity.<sup>2</sup> Internal resorption is probably initiated by stimulation of odontoclastic activity.<sup>7</sup> Generally, if one of these processes begins and is left untreated, the course of events will continue. In this particular case, a complete reversal occurred.

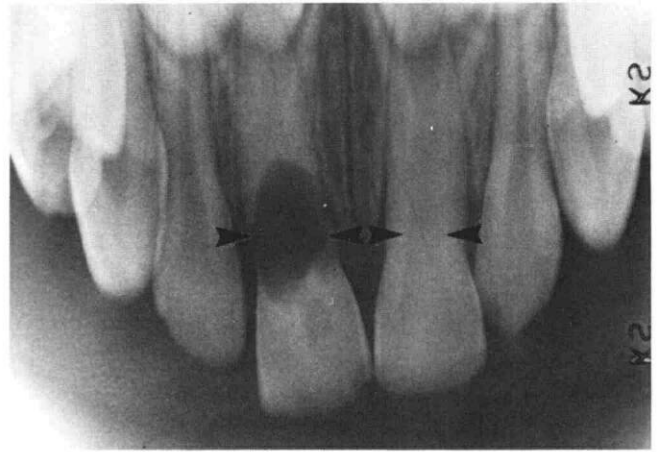
The cause of this reversal is not clearly understood. One possibility is that since the parent cells for odontoblasts and odontoclasts may be from the same undifferentiated mesenchymal stock, the odontoblasts idiopathically develop into odontoclasts.

Another possibility is that subsequent to the initial trauma which caused the calcific metamorphosis, the patient retraumatized the tooth which then stimulated odontoclastic activity.

## Conclusion

A case of a primary incisor exhibiting calcific metamorphosis reversing and undergoing internal resorption is presented. The primary tooth was diagnosed as undergoing calcific metamorphosis secondary to a traumatic injury. Ten months later the tooth had internally resorbed to such a degree that it was unrestorable.

This case demonstrates that a primary tooth evidencing pulpal obliteration can reverse and undergo internal resorption. However, in the vast majority of



**Figure 2.** Large area of internal resorption in middle one-third of maxillary right primary central incisor.

cases of calcific metamorphosis, the pulp chambers and root canals remain obliterated and the tooth is maintained in an apparently healthy state until it is exfoliated. Hence, the routine treatment of calcific metamorphosis in primary teeth remains limited to close observation. Routine pulpal treatment of these teeth does not seem warranted.

---

Dr. Kuster is assistant professor, department of pedodontics, University of Nebraska, College of Dentistry, Lincoln, Nebraska 68583. Requests for reprints should be sent to Dr. Kuster.

## References

1. Eversole, L. R.: *Clinical Outline of Oral Pathology: Diagnosis and Treatment*, Philadelphia: Lea and Febiger, 1978, pp 273-274.
2. Johnson, P. L. and Bevelander, G.: Histogenesis and histochemistry of pulpal calcification, *J Dent Res*, 35:714-722, 1956.
3. Morse, D. R.: *Clinical Endodontology: A Comprehensive Guide to Diagnosis, Treatment and Prevention*, Springfield, Ill.: Charles C. Thomas, 1974, p 150.
4. Stafne, E. C. and Gibilisco, J. A.: *Oral Roentgenographic Diagnosis*, Philadelphia: W. B. Saunders Co., 1975, pp 65-66.
5. Patterson, S. S. and Mitchell, D. F.: Calcific metamorphosis of the dental pulp, *Oral Surg, Oral Med, Oral Path*, 20:94-101, 1965.
6. Brauer, J. C.: *Dentistry for Children*, New York: McGraw Hill Book Co., 1958, pp 452-53.
7. McDonald, R. E. and Avery, D. R.: *Dentistry for the Child and Adolescent*, St. Louis: C. V. Mosby Co., 1978, pp 316-17.
8. Wuehrmann, A. H. and Manson-Hing, L. R.: *Dental Radiology*, St. Louis: C. V. Mosby Co., 1973, pp 317-21.
9. Weisman, M. I. and Rackley, R. H.: A rare case: Recalcification of internal resorption, *J Ga Dent Assoc*, 41:15, 1968.
10. Hartness, J. D.: Fractured root with internal resorption, repair, and formation of callus, *J Endo*, 1:73-75, 1975.