



Clinical guidelines for treatment of impalement injuries of the oropharynx in children

Ari Kupietzky, DMD, MSc

Dr. Kupietzky is in private practice, Jerusalem, Israel, and a Diplomate of The American Board of Pediatric Dentistry.

Orodental injury in children is a cause of much concern and anxiety for the patient and parent. Most pediatric dentists are well-acquainted and capable of treatment of trauma to the teeth and their supporting structures. However, the anatomical area posterior to the hard palate is less familiar to the pediatric dentist. The active toddler and young child are likely to turn first to their familiar dentist if and when they experience an impalement injury. The pediatric dentist needs to be in a position to provide proper emergency treatment and reassurance in such cases.

The objectives of the present report are to describe an impalement injury in a 6-year old, review the relevant anatomy, modes of treatment, and possible sequela associated with such injuries.

Mini review of terminology, prevalence and etiology

Impalement injuries of the oropharynx and particularly of the soft palate are relatively common in children.¹⁻⁵ Impalement injuries of the soft palate have been reported in patients of all ages, ranging from the newborn to geriatric patients. However, young children, particularly toddlers, are most involved in these types of injuries. Children frequently run around with objects in their mouths. Left unsupervised, they may fall and suffer minor oropharyngeal trauma.²

Age and Sex

The mean age of patients presenting with impalement injuries has been reported as being under 4 years of age.^{1,2,5} Males are two to three times more likely to be involved than females.

Site

Injuries of the soft palate and oropharynx may include the following areas: posterior pharyngeal wall, the tonsillar region, uvula, the midline, and the left and right soft palate superior to the tonsils (Fig 1). The most common site is the left supra-tonsillar area.^{1,2} The higher incidence of left sided injuries may reflect predominant right-handedness among patients.¹ Lesions are predominately in the soft and hard palate without perforation. Linear and superficial wounds are frequent. A typical injury is the flat-, u-, or v-shaped with the apex directed anteriorly.⁵

Etiology

The most common objects causing impalement injuries in children are sticks, pens/pencils, cylindrical toys, and straws. Sticks were implicated in 25% to 30% of the cases reviewed. Even toothbrushes have been reported to be the cause of injury in young children.^{2,3,5,7} Young children often place objects

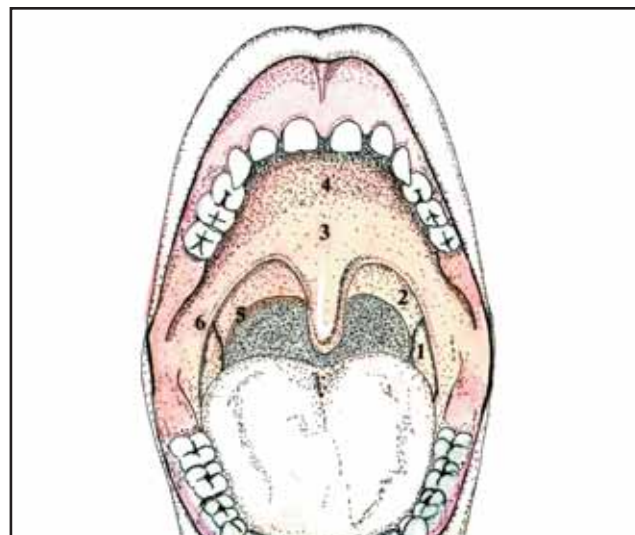


Fig 1. Landmark anatomy of oropharynx and soft palate region: 1. Palatine tonsil. 2. Supratonsillar fossa. 3. Mid soft palate. 4. Hard palate. 5. Palatopharyngeal arch. 6. Interior pillar. The clinician should be able to describe the area of injury.

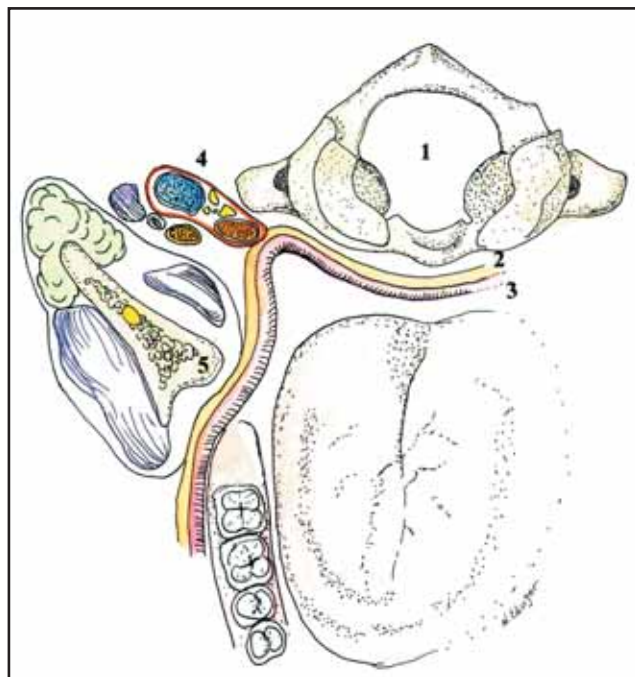


Fig 2. Cross-section passing through the mouth and pharynx. 1. Cervical vertebrae. 2. Retropharyngeal space. 3. Superior Constrictor muscle. 4. Carotid sheath 5. Mandibular Ramus. Note close proximity of carotid sheath to the peritonsillar and palatal tissues. Compression of the artery between the penetrating object and the transverse process of the cervical vertebrae may lead to thrombus and future coma.

Received June 22, 1999 Revision Accepted September 8, 1999

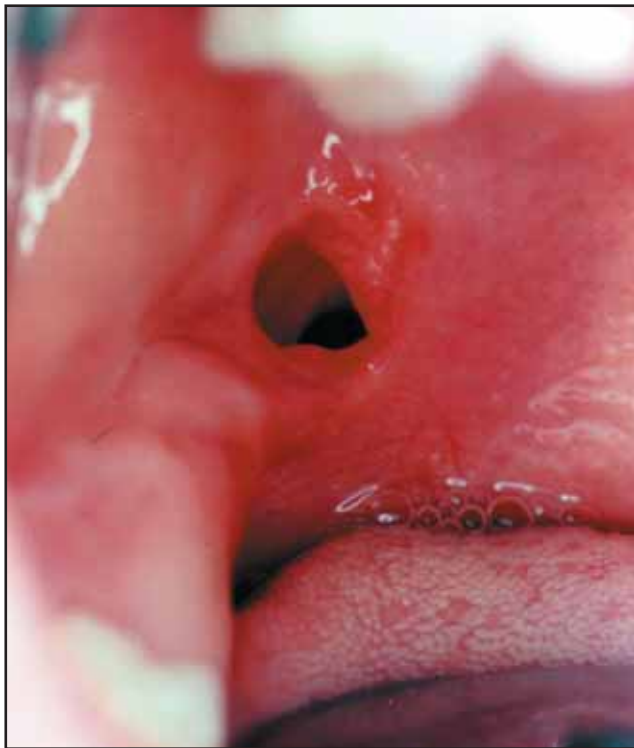

Fig 3. Impalement injury in a 5-year old male. The patient presented at a private practice two to three days following a fall with a pencil-like object in his mouth. No bleeding was observed by parent and the patient did not alert parent until present time. Prophylactic antibiotic therapy was initiated and parent was given detailed instructions.

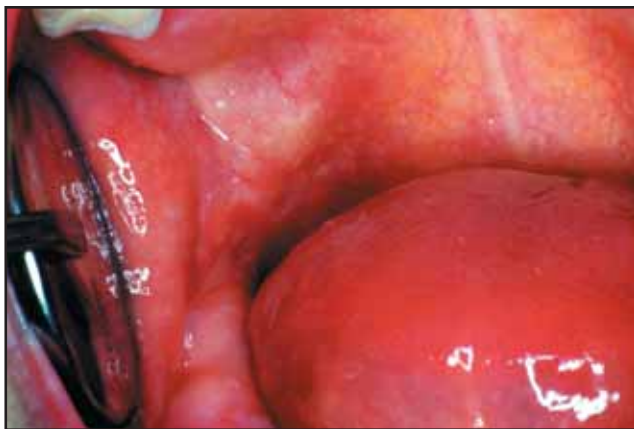

Fig 4. Spontaneous healing of wound in Fig 3, six weeks after injury. Note light color of healing site.

in their mouths. The child may then fall on the object or receive a direct force on the object which then perforates the soft palate tissue.

Treatment

Conservative treatment is recommended. Primary healing is usually uneventful. The majority of soft palate and oropharyngeal impalement injuries can be managed on an outpatient basis. Most palate injuries heal without direct intervention.¹ Even gaping through-and-through wounds of the hard palate have been reported to heal spontaneously.^{1,2,3,5} The oropha-

Table 1. Facts for the Clinician—Impalement Injuries of the Oropharynx

Age:	most common under 4 years of age
Sex:	males>females
Location:	most common site is left side of soft palate in supratonsillar area
Etiology:	most common causes in decreasing order: ^{1,5} falling on object carried in mouth; direct force applied to an object held in mouth; falling into a stationary object with the mouth open

ryngeal area has a very high potential of healing capacity. However, cases of a large avulsion flap, through-and-through wounds, or the need to explore the wound for a foreign object should be referred to the oral surgeon for possible surgical intervention. Studies^{5,6} have suggested that suture placement is contraindicated in most situations. The use of sutures may cause further damage and delay healing. However, prophylactic antibiotic therapy should be prescribed immediately to prevent the possible complication of facial cellulitis. Healing of the wound should be complete by three weeks with minimal scarring.

Complications

Neurologic sequelae secondary to carotid artery injury are rare but have been reported.¹ Most were reported as lateral soft palate injuries. However, neither the mechanism of injury nor the degree of injury correlates with the potential for neurovascular sequelae.² The carotid artery in its sheath is susceptible to injury due to its anatomic proximity to the lateral peritonsillar and palatal tissues of the oropharynx (Fig 2). Compression of the artery between the penetrating object and the transverse process of the cervical vertebrae may lead to disruption of the intima of the artery and may result in the formation of a mural thrombus. This may cause future formation of a stroke. Fortunately, most individuals have adequate collateral circulation and can tolerate acute occlusion of one internal carotid artery. Onset of symptoms may occur several weeks or even months after the initial injury to the artery,² therefore, admission to hospital for early observation would not necessarily detect potential neurologic injury. No diagnostic measures prior to the development of neurologic symptoms appear to alter the final outcome of these injuries. Therefore, outpatient management with parental counseling (see Table 2) and close follow up is recommended versus admission to hospital. However, reports of any neurologic signs would warrant immediate referral to an oral surgeon, ENT specialist, or neurologist. More extensive evaluation with angiography and other tests would then be initiated. A recent report⁷ illustrates the need to instruct parents and perform follow-up visits. A 2-year old child fell on a toothbrush, sustaining a pharyngeal injury. Eighteen hours later, localizing symptoms of a cerebrovascular accident became evident. Magnetic resonance angiography showed occlusion of the internal carotid artery and a cerebral infarction. She was treated with anticoagulation and made a complete recovery.

Table 2. Clinical Guidelines for Treatment of Impalement Injuries of the Oropharynx

A neurologic assessment of the patient can be achieved in a short time (see screening as described by Croll⁸). If neurologic damage is suspected, immediate medical referral is indicated.

Most palatal injuries will heal spontaneously without intervention,⁵ even perforating lesions of the hard palate.⁴

A brief episode of intraoral bleeding which stops spontaneously is common.³ Profuse bleeding which is life threatening is usually not a problem with these injuries.⁵

Avoid the impulse to suture the wound.^{4,6} Surgical intervention should be reserved for the rare case of a large avulsion flap or need to explore for foreign objects.⁵

Prophylactic antibiotic therapy^{5,9} (penicillin) may be prescribed to prevent infection, especially in wounds greater than 1 cm in greatest dimension.

Instructions similar to those given for minor head trauma should be explained to parents (see Table 3).

Soft diet should be recommended for a few days.

Close follow-up examinations are recommended.

Table 3. Parental Instructions Following an Impalement Injury

Eating, speaking, and talking may be difficult for a few days.

Soft diet for five days.

Observe child closely for 48-72 hours.

Most children do not develop problems, but if parent notices any of the symptoms listed below, contact the dentist immediately:

1. Decreased level of consciousness.
2. Irritability.
3. Vomiting.
4. Weakness of either arm or leg.
5. Headache, blurred vision, or convulsions.
6. Neck swelling or bleeding from the mouth.

The author thanks N. Edinger for the anatomical drawings.

References

1. Hellmann JR, Shott SR, Gootee MJ: Impalement injuries of the palate in children: review of 131 cases. *Intl J Pediatr Otorhinolaryngology* 26:157-163, 1993.
2. Schoem SR, Choi SS, Zazal GH, Grundfast KM: Management of oropharyngeal trauma in children. *Arch Otolaryngol Head Neck Surg* 123:1267-70, 1997.
3. Radowski D, McGill TJ, Healy GB, Jones DT: Penetrating trauma of the oropharynx in children. *Laryngoscope* 103:991-94, 1993.
4. Domarus HV, Poeschel W: Impalement injuries of the palate. *Plastic and Reconstructive Surgery* 72:656-58, 1983.
5. Takenoshita Y, Sasaki M, Horinouchi Y, Ikebe T, Kawano Y: Impalement injuries of the oral cavity in children. *J Dent Child* 63:181-84, 1996.
6. Crawford BS: The management of perforating wounds of the palate. *Brit J Plast Surg* 23:262, 1970.
7. Moriarty KP, Harris BH, Benitez-Marchand K: Carotid artery thrombosis and stroke after blunt pharyngeal injury. *J Trauma* 42:541-43, 1997.
8. Croll TP, Brooks EB, Schut L, Laurent JP: Rapid neurologic assessment and initial management for the patient with traumatic dental injuries. *J Am Dent Assoc* 100:530-34, 1980.
9. Altieri M, Brasch L: Antibiotic prophylaxis in intraoral wounds. *Am J Emerg Med* 4: 507-10, 1986.

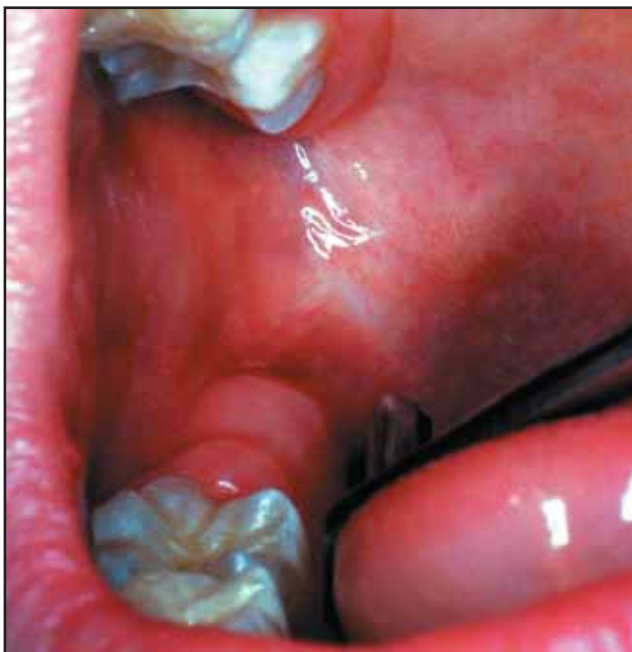

Fig 5. Ten months following injury, healing tissue has been replaced by healthy, normal-looking tissue.