



# Condyloma Acuminatum and Human Papilloma Virus Infection in the Oral Mucosa of Children

Liu Lai Kui, PhD He Zhi Xiu, MD Li Yi Ning, DDS

*Dr. Kui is assistant professor, Dr. Xiu is professor, and Dr. Ning is assistant professor, Department of Oral Pathology, West China College of Stomatology, Sichuan University, Chengdu, Sichuan, The People's Republic of China.*

*Correspond with Dr. Kui at laikui@china.com*

## Abstract

**Purpose:** The purpose of this study was to investigate the clinicopathological features of oral condylomas in children and condylomatous lesions of their mothers. Moreover, the authors sought to determine the mode of transmission of this disease and to find the genotype of human papilloma virus (HPV) in the children's oral condyloma.

**Methods:** Nine instances of oral condyloma acuminatum in children and lesions in their mothers were reviewed. Their HPV genotypes were evaluated by in situ hybridization (ISH).

**Results:** This study revealed that the lesions appeared during 3 years of age and the most common location was the hard and soft palate. Seven of the 9 mothers had experienced vulva and/or oral cavity condylomata during pregnancy. Social evaluation confirmed sexual abuse in 1 girl, and probable sexual abuse in another girl. The results of ISH demonstrated HPV 16/18 DNA being positive in 5 of the 9 cases, and HPV 6 and HPV 11, HPV 6 and HPV 16/18, HPV 6, and HPV 11 DNA being positive, respectively, in 1 case. HPV DNA types in mother-child pairs were not concordant.

**Conclusions:** Oral condyloma acuminatum in children is probably induced by HPV 16/18. The mode of transmission by sexual abuse is the most likely route. Prenatal transmission of HPV to children is rare. This study provides further confirmation of possible different genotype and transmission in oral CA of children and adults. (*Pediatr Dent.* 2003;25:149-153)

**KEYWORDS:** CHILDREN, ORAL MUCOSA, CONDYLOMA ACUMINATUM, HUMAN PAPILLOMA VIRUS

*Received May 13, 2002 Revision Accepted November 14, 2002*

Condyloma acuminatum (CA) is a benign papillary lesion that is commonly found on anogenital tract skin and mucosa.<sup>1,2</sup> These benign epithelial lesions are associated with human papilloma virus (HPV), the majority being types 6 and 11.<sup>3</sup> Oral condyloma acuminatum has been reported to be resulted from genital-oral sexual transmission or hand-to-mouth autoinoculation in adults.<sup>4,5</sup> Some authors believe that the presence of condylomata in children may be due to sexual abuse.<sup>6-8</sup> However, an earlier study of children with anogenital CA and their parents provides further confirmation of possible nonsexual transmission through prenatal infection, digital inoculation or autoinoculation, fomites, and casual social contact.<sup>9,10</sup> Oral condyloma has also been reported in association with HIV status in children.<sup>11</sup> As currently known, the frequency of childhood condylomata is steadily increasing<sup>9,12</sup>

and appears to be related to an increase of condylomata in adults.<sup>13</sup> However, there is little data concerning oral mucosa condylomata in children. In this paper, the clinicopathological features of 9 instances of oral condylomas in children have been studied and their HPV genotypes have been evaluated by in situ hybridization.

## Methods

### Case selection

Nine cases of children's oral condyloma acuminatum were reviewed in the department of oral pathology, West China College of Stomatology, Sichuan University, Sichuan, China. Differentiation from the more common squamous papilloma was made employing criteria specified for anogenital condylomata.<sup>14</sup> All cases in this study exhibited

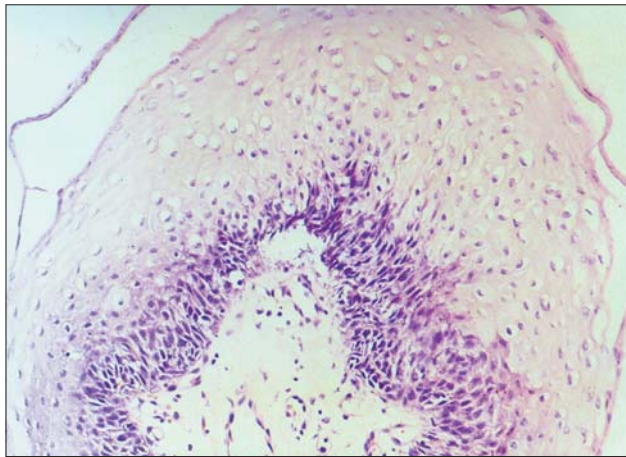


Figure 1. Children's oral condyloma acuminatum—cytopathic changes in the superficial cells of condyloma acuminatum showing numerous koilocytes and slight hyperparakeratosis (H and E  $\times 200$ ).

papillomatosis with a tendency for a sessile rather than predunculated architecture. Clinically, the surface of condylomas appears as a cauliflower-like lesion that is the result of multiple, small white or pink nodules that coalesce to produce a soft, nodular mass. Histologically, invaginations of these parakeratinized cells are often present, along with marked acathosis. Koilocytes (vacuolated cells) are common in the upper spinous and corneal layers (Figure 1). All children received an environmental risk assessment for sexual abuse.

Nine volunteer mothers whose children presented with oral condyloma acuminatum accepted histological examination of the lesions from the oral cavity or anogenital regions. The authors were unable to obtain adequate data on the conditions of the children's fathers. All children had surgical excision of the lesions, but 1 case recurred 10 months later.

Table 1. Clinical Data of Oral Condyloma in Children and Lesions in Their Mothers

Case no.	Age at onset	Sex	Site of lesion	Sexual abuse	Lesions in their mothers		
					Site of lesion	Diagnosis	During pregnancy
1	2 y, 1 mo	F	Palate	No	Vulva	CA*	Yes
2	6 y	F	Commissure	Suspicion	No lesion	No	No
3	2 y, 6 mo	F	Palate	No	Vulva	CA	Yes
4	4 y	F	Palate	Yes	Vulva	CA	No
5	1 y, 6 mo	M	Palate	No	Vulva and cavity	CA	Yes
6	4 y, 6 mo	F	Commissure	No	Vulva	CA	Yes
7	3 y	M	Palate	No	Vulva	CA	Yes
8	4 y	F	Palate	No	Vulva	CA	Yes
9	1 y, 4 mo	M	Palate	No	No lesion	No	No
9 (recurred)	2 y, 2 mo	M	Palate and lower lip	No	No lesion	No	No

\*Condyloma acuminatum.

### DNA in situ hybridization

In situ hybridization was performed with HPV 6, 11, and 16/18 probes from a viral-type in situ hybridization kit according to the manufacturer's directions. Each specimen was cut 4 to 6  $\mu\text{m}$  thick and placed on a glass slide treated with 3-aminopropyltriethoxysilane, then allowed to adhere at 60°C overnight. Sections were dewaxed in xylene and dehydrated in pure ethanol. The slides were then air dried and incubated with digestion reagent (37°C for 15 minutes). Digoxin probes for HPV 6, 11, and 16/18 were applied to the sections and denatured (100°C for 5 minutes) in a water bath. The sections were then removed from the water bath and placed in a 37°C incubator overnight to allow for DNA hybridization between tissue and probes. Posthybridization washes were incubated with rabbit anti-Digoxin and biotinylated goat antirabbit at 37°C for 30 minutes.<sup>15-17</sup>

### Controls

Two genital condylomata were used as positive controls. Negative controls consisted of normal oral tissues.

### Results

Clinical data of oral condyloma in children and lesions in their mothers is presented in Table 1. The lesions appeared in children between 1 year, 4 months to 6 years of age. Six of the 9 children were girls, and 1 of them recurred 10 month after treatment. The most common location was the palate, with only 2 cases in the commissure. The recurred lesions located in the palate, and also in the lower lip. Seven of the 9 mothers suffered from vulva or/and oral cavity condylomata during pregnancy.

Social evaluation confirmed sexual abuse in 1 girl, and probable sexual abuse in another girl.

The results of HPV DNA in situ hybridization are presented in Table 2. The specific hybridization signal was

localized in the nuclei of superficial spinous layer cells (Figure 2). The majority of positive cells exhibited koilocytotic alterations. In most instances, the distribution of positive signal was focal. The results of ISH demonstrated HPV16/18 being positive in 5 of the 9 cases: one case positive for both HPV 6 and 11; another case positive for both HPV 6 and 16/18; one case positive for HPV 6 and one case positive for HPV 11.

All positive control samples were color reactive. The negative control samples were nonreactive (Figure 3).

## Discussion

Condyloma acuminatum has been reported to occur in the oral cavity, however, most published instances are adults.<sup>18-20</sup> In this study, 9 instances of CA have been found in the oral cavity of children. The lesion appeared at about 3 years of age. The common location of children's oral CA, which is located in the palate, is different from those of adults that are often located in the lower lip and tongue.<sup>17,21</sup>

Data indicate that the primary means of transmission of adult's condylomata is by sexual contact with a person infected with HPV.<sup>22-24</sup> Most publications concerning pediatric anogenital warts authored by clinicians who work with child protection services have concluded that the majority of children whose lesions were recognized after infancy had been sexually abused.<sup>25</sup> Oral lesions due to HPV have been reported in children, several of whom had been sexually abused.<sup>26,27</sup> In this study, sexual abuse was confirmed in 1 girl, and there was a suspicion of sexual abuse in another girl. But children are difficult to assess for sexual abuse because of preverbal or limited verbal abilities. A child who has not been evaluated for abuse cannot be assumed to be nonabused<sup>28,29</sup> so the mode of transmission by sexual abuse must be considered.

Perinatal transmission of HPV to infants and toddlers is possible in theory. Most experts agree that HPV lesions seen on any part of the body of a child younger than 1 year of age can be the result of vertical transmission from an infected mother.<sup>25</sup> In this study, the lesion had appeared at about 3 years of age, so vertical transmission is considered to be unlikely. On the other hand, although mothers of 7 of the 9 children suffered from vulva or oral condyloma acuminatum during pregnancy, the unexpected finding showed some discordance between the HPV type in CA of children and mothers. This finding is supported by most experts, which suggests that vertical transmission of HPV to children is rare. In addition, the authors were unable to obtain adequate data to demonstrate if the children's HPV types were concordant with their contact. Atraumatic and

casual transmission of lesions to the oral cavity in children remains, therefore, conjectural.

In this investigation, the authors demonstrate that HPV 16/18 is the most common HPV type (6 out of 9 cases). In contrast, some studies report a high percentage of HPV 6 and HPV 11 oral mucosa infections in adults with CA.<sup>17</sup> The relative lower incidence of HPV 6 and HPV 11 may represent a lower diffusion of these viruses within the oral cavity of children with CA, or

an underestimation due to the sample size. Mixed infections were revealed in 2 of 9 instances, corresponding to findings reported for anogenital region lesions.<sup>30</sup> HPV 6 DNA was presented in both of the mixed infections. It is still unclear whether oral mucosa in children is vulnerable to infection by HPV 16/18, and whether the presence of HPV 6 predisposes to infection by other HPV types. Further analysis is, therefore, necessary to confirm this hypothesis.

HPV 16/18 is still positive in 1 recurred case. This is supported by previous studies that childhood CA caused by low-risk HPV 6 and HPV 11 may have been spontaneously resolved, while chronic HPV infection may have been correlated with the high-risk types HPV 16/18.<sup>31</sup> These types are also highly associated with mucosal carcinoma in

**Table 2. HPV Distribution in Children and their Mothers as Demonstrated by In Situ Hybridization**

Case no.	HPV genotypes	In situ hybridization
	Children	Mother
1	16/18	6
2	16/18	Negative
3	6, 11	6, 11
4	6, 16/18	6
5	6	16/18
6	11	11
7	16/18	6
8	16/18	6
9	16/18	Negative
9 (recurred)	16/18	Negative
Positive controls	Positive	
Negative controls	Negative	

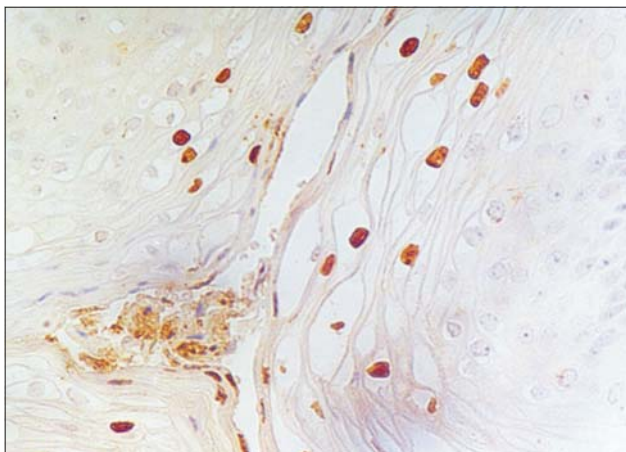


Figure 2. HPV DNA in koilocytes of children's oral condylomata (in situ hybridization  $\times 200$ ).

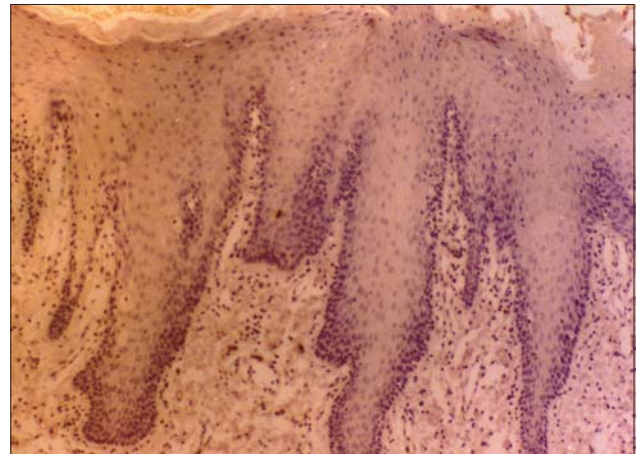


Figure 3. This photograph shows nonreactive HPV DNA negative control samples (in situ hybridization  $\times 100$ ).

adults.<sup>32,33</sup> Hence, a prolonged follow-up is necessary for HPV 16/18 infection in children.

### Conclusions

The majority of incidences of oral condyloma acuminatum in children are caused by HPV 16/18. Sexual abuse is the most common mode of transmission. Prenatal transmission of HPV to children is less common. HPV infection of the oral mucosa in children has not been studied as intensively as those of the genital infection. The authors' data revealed that the genotype, lesion location, and mode of transmission of oral CA in children was different from those of the adults. Therefore, research is necessary to confirm this difference.

### Acknowledgments

The authors wish to express their appreciation to Mr. Yang for his technical assistance.

### References

1. Della Torre G, Pilotti S, De Palo G, Rike F. Viral particle in condylomatous lesions. *Tumori*. 1978;64:549-555.
2. Sehgal VN, Koranne RV, Srivastava SB. Genital warts. Current status. *Int J Dermatol*. 1989;28:75-78.
3. Padel AF, Venning VA, Evans MF, Quantrill AM, Fleming KA. Human papilloma virus in anogenital warts in children: typing by in situ hybridization. *Br Med J*. 1990;300:1491-1494.
4. Choukas NC, Toto PD. Condyloma acuminatum of the oral cavity. *Oral Surg Oral Med Oral Pathol*. 1985;54:480-485.
5. Butler S, Molinari JA, Plezia RA, Chandrasekar P, Venkat H. Condyloma acuminatum in the oral cavity: four cases and a review. *Rev Infect Dis*. 1988;10:544-550.
6. Hanson RM, Glasson M, McCrossin I, Rogers M, Rose B, Thompson C. Anogenital warts in childhood. *Child Abuse Negl*. 1989;13:225-233.
7. Davis AJ, Emans SJ. Human papilloma virus infection in the pediatric and adolescent patient. *J Pediatr*. 1989;115:1-9.
8. Guman LT, Claire K, Herman-Giddens PA, Johnston WW, Phelps WC. Evaluation of sexually abused and nonabused girls for intravaginal human papilloma virus infection. *Am J Dis Child*. 1992;146:694-699.
9. Obalek S, Jablonska S, Favre M, et al. Condylomata acuminata in children: frequent association with human papilloma viruses responsible for cutaneous warts. *J Am Acad Dermatol*. 1990;23:205-213.
10. Obalek S, Misiewicz J, Jablonska S, Favre M, Orth G. Childhood condylomata acuminatum: association with genital and cutaneous human papilloma viruses. *Pediatr Dermatol*. 1993;10:101-106.
11. Magalhaes MG, Bueno DF, Serra E, Goncalves R. Oral manifestations of HIV positive children. *J Clin Pediatr Dent*. 2001;25:103-106.
12. Lacey CHJN. Genital warts in children. *Papillomavirus Report*. 1991;2:31-32.
13. Koutsky LA, Galloway DN, Holmes KK. Epidemiology of genital human papilloma virus infection. *Epidemiol Rev*. 1988;10:122-162.
14. Lever WF, Schaumburg-Lever G. *Histopathology of the Skin*. Philadelphia, Pa: JB Lippincott; 1975:352-360.
15. Gissman L, Wolnik L, Ikenberg H, Koldovsky U, Schnurch HG, Zu Hausen H. Human papilloma virus types 6 and 11 DNA sequences in genital and laryngeal papilloma virus and in some cervical cancers. *Proc Natl Acad Sci USA*. 1983;80:560.
16. Brigati DJ, Myerson D, Leary JJ, et al. Detection of viral genomes in cultured cells and paraffin-embedded tissue sections using biotin-labelled hybridization probes. *Virology*. 1983;126:32.
17. Eversole LR, Laipis PJ, Merrell P, Choi E. Demonstration of human papilloma virus DNA in oral condyloma acuminatum. *J Oral Pathol*. 1987;16:266-272.
18. Shaffer EL, Reimann BE, Gysland WB. Oral condyloma acuminatum; a case report with light microscopic and ultrastructural feature. *J Oral Pathol*. 1980;9:163.
19. Jensen AB, Lancaster WD, Hartmann DP, Shafer Jr EL. Frequency and distribution of papillomavirus structural antigens in verrucae, multiple papillomas, and condylomata of the oral cavity. *Am J Pathol*. 1982;107:212.
20. Jin, Toto Y-T. Detection of human papilloma virus antigen in oral papillary lesion. *Oral Surg Oral Med Oral Pathol*. 1984;58:702.
21. Zeuss MS, Miller CS, White DK. In situ hybridization analysis of human papilloma virus DNA in oral mucosal lesions. *Oral Surg Oral Med Oral Pathol*. 1991;71:714-719.
22. Schneider A, Kirchmayr R, Devilliers E-M, Gissmann L. Subclinical human papilloma virus infections in male sexual partners of female carriers. *J Urol*. 1988;140:1431-1434.
23. Ley C, Bauer HM, Reingold A, et al. Determinants of genital human papilloma virus infection in young women. *J Natl Cancer Inst*. 1991;83:997-1003.
24. Schiffman MH. Recent progress in defining the epidemiology of human papilloma virus infection and cervical neoplasia. *J Natl Cancer Inst*. 1992;84:394-398.
25. Gutman LT, Herman-Giddens PA, Marcia E, Phelps WC. Transmission of human genital papilloma virus disease: comparison of data from adults and children. *J Pediatr*. 1993;91:31-38.
26. Franger AL. Condyloma acuminatum in prepubescent females. *Adolescent and Pediatric Gynecology*. 1990;3:38-41.
27. Ashiru JO, Ogunbanjo BO, Rotowa HA, Adeyemi-Doro FBA, Osoba AO. Intraoral condyloma acuminatum: a case report. *Br J Vener Dis*. 1983;59:325-326.

28. Russell DEH. The incidence and prevalence of intrafamilial and extrafamilial sexual abuse of female children. *Child Abuse Negl.* 1983;7:133-146.
29. Siegel JM, Sorenson SB, Golding JM, Burnam MA, Stein JA. The prevalence of childhood sexual assault: the Los Angeles epidemiologic catchment area project. *Am J Epidemiol.* 1987;126:1141-1153.
30. Miller CS, White DK, Royse DD. In situ hybridization analysis of human papilloma virus in oralfacial lesions using a consensus biotinylated probe. *Am J Dermatopathol.* 1993;15:256-259.
31. Angel L, Allen et al. The natural history of condyloma in children. *J Am Acad Dermatol.* 1998;39:951-995.
32. Ho GYF, Burk RD, Klein S, et al. Persistent genital human papilloma virus infection as a risk factor for persistent cervical dysplasia. *J Natl Cancer Inst.* 1995;87:1365-1371.
33. Koutsky IA, Holmes KK, Critchlow CW, et al. A cohort study of the risk of cervical intraepithelial neoplasia grade 2 or 3 in relation to papillomavirus infection. *N Engl J Med.* 1992;327:1272-1278.

## ABSTRACT OF THE SCIENTIFIC LITERATURE



### EFFECTS OF WATER STORAGE ON EXPANSION AND BOND STRENGTH OF 4 RESIN COMPOSITES

The authors of this study wanted to test the hypothesis that resinous materials with relatively large water absorption will show reduced gap sizes around fillings in cavities as well as reduced mechanical strength. Therefore, the aim of their study was to test and compare the hygroscopic expansion in dentin cavities of a compomer (Dyract AP), an ormocer (Definite), an ion-releasing resin composite (Ariston pHc), and a traditional resin composite (Spectrum TPH), and to measure changes in mechanical properties of the materials due to extended water storage. Cavity preparations were made on flattened dentinal surfaces of extracted human teeth of approximately 3.1 mm in diameter with a depth of 1.5 mm. The preparations were slightly overfilled and cured using no dentin pretreatment and stored at 37°C in water. Microscopic examination of the maximal gap at the cavity margin between dentin and polymerized material was measured after 1 hour, 1 day, 7 days, 30 days, 90 days, and 180 days in water storage with the excess material removed immediately before inspection. Those that were examined after 1 hour were put back into water storage and examined again after 1, 7, 30, 90 and 180 days. Flexural strength was also measured at all time points, and the results were compared. The authors found that, in all cases, extended water storage caused a significant reduction in the sizes of the marginal gaps and, with 2 of the materials (DYR and ARI), a very small or absence of marginal gaps was apparent after 180 days in water storage. Flexural strengths for each material did not differ significantly from 1 to 180 days. The authors concluded that the gap sizes were reduced but the mechanical properties were either unaltered or increased in the range of 1 to 180 days of water immersion.

**Comments:** Although this in vitro test using a cylindrical cavity preparation does not equate to their use in vivo, it does allow for direct comparisons of various composite resin materials. **DARB**

*Address correspondence to Erik Christian Munksgaard, Department of Dental Materials, School of Dentistry, University of Copenhagen, 20 Norre Alle, DK-2200 Copenhagen N, Denmark. ecm@odont.ku.dk*

Munksgaard EC. Changes in expansion and mechanical strength during water storage of a traditional and three modified resin composites. *Acta Odontol Scand.* 2002;60:203-297.

20 references