

Submucous cleft palate: review and two clinical reports

Michael C. Kinnebrew, DDS, MD Dennis J. McTigue, DDS, MS

Abstract

Early and appropriate management of submucous cleft palate greatly can enhance the afflicted child's potential for optimum speech and hearing. The pediatric dentist, through his familiarity with oropharyngeal aberrancies and access to this patient population, is in a unique position to diagnose this condition. This report describes historical and clinical markers which identify submucous cleft palate and briefly discusses surgical management of two patients. Overt, occult, and residual submucous clefts are discussed, including the common anatomic points among these subtypes which may predispose toward speech and hearing difficulties.

The responsible position of the pediatric dentist on the cleft palate team is well established, involving preventive, restorative, orthopedic and orthodontic aspects of dentistry in concert with other team efforts. Outside the team atmosphere, a less recognized but equally important unique role that the pediatric dentist can assume involves the early diagnosis of other occult congenital deformities, including submucous cleft palate. This clinical entity can have far-reaching implications for the child's speech and hearing, and for the clinician as he interfaces with other health professionals in patient management.

The purpose of this paper is to review submucous cleft palate, describe its embryogenesis and clinical characteristics, and to detail the management of two patients. Further, the existence of another entity within the orofacial cleft population, the residual submucous cleft, is reported.

Diagnosis of Submucous Cleft Palate: Historical and Clinical Factors

Submucous clefts have been reported to be the most common form of cleft in the posterior palate, with an

incidence of one in 1,200 normal children.¹ Given the increasing disclosure of minimally expressed congenital anomalies, however, an even greater incidence may be anticipated. These clefts are manifested in both overt² and occult forms. The latter, described by Kaplan in 1975,³ is less distinct. However, they share some abnormalities of the intrinsic and extrinsic palatal musculature which are not unlike those seen in a fully expressed cleft and often preclude proper velopharyngeal activity, predisposing toward:

1. Hypernasality, nasal emission, and faulty speech
2. Chronic otitis media with associated low-frequency hearing loss
3. Nasal regurgitation (especially in infancy).

Overt submucous clefts: This diagnosis is confirmed by clinical examination. The classic triad describing it includes:

1. Bifid uvula
2. Translucent palatal raphe area (zona pellucida)
3. Palpable notch in the midline of the posterior hard palate.

Additionally, a fourth finding is seen; two triangular tissue folds diverge from the clefted posterior nasal hemispines when the palate is lifted on phonation (Figure 1). This is in contrast to the subuvular, transverse crease or "levator dimpling" seen with normal palatal elevation (Figure 2).

The embryogenesis of the submucous cleft palate involves ectodermal fusion when the embryonic palatal processes abut; however, the mesenchyme fails to intermingle properly across the midline.⁴ Instead, it differentiates unilaterally, with the result that the palatal muscles and vestigial palatine aponeurosis converge onto the posterior border of the hard palate and nasal hemispines on either side.⁵ Figure 3a demonstrates the normal muscular anatomy of the soft

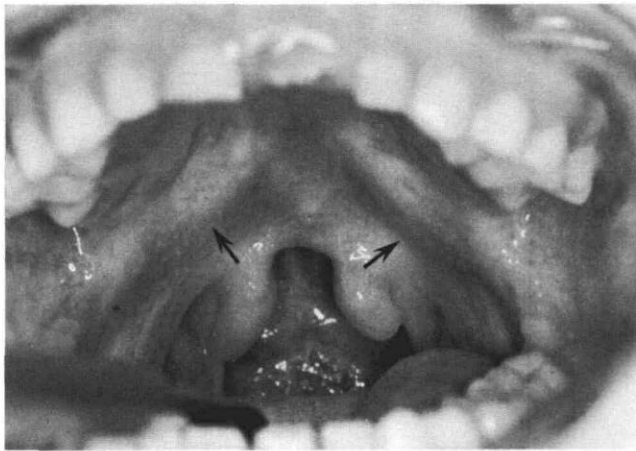


FIGURE 1. An overt submucous cleft palate demonstrating the "classic triad" of bifid uvula, midline translucency, and notching at the posterior border of the hard palate. A fourth finding, triangular muscle ridging on palatal elevation, also is seen (arrows).

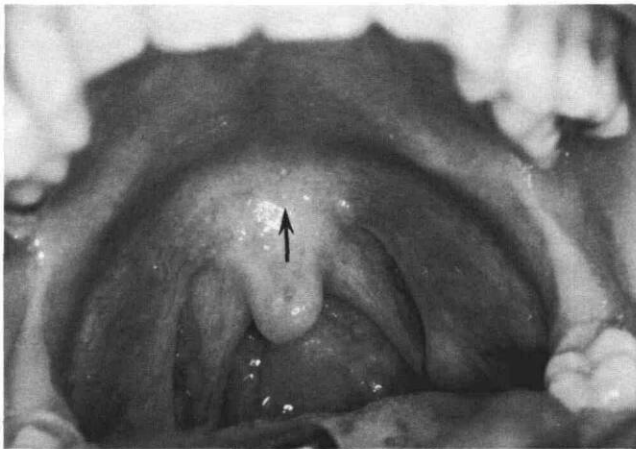


FIGURE 2. A normal palate in elevation, demonstrating the subvular creasing which signifies normal muscular position and activity (arrow).

palate, which may be compared to Figure 3b, depict-

ing a clefted secondary palate with the muscular components inserting on the posterior palatal border and nasal hemispines. The lack of sagittal continuity of the muscles places them at a disadvantage for lifting the palate and for "clearing" the ears through eustachian tube openings and equilibration of ambient and middle ear pressures. The anatomical result is a clinically short palate, due not only to the atrophy of isotonic muscles made to act isometrically, but also to the lack of trophic stimulation or muscular pull which culminates in growth lag.⁶ This is not as pronounced as in the fully expressed cleft palate but common mechanisms are nonetheless operative.

Occult submucous clefts: These clefts present similar diagnostic findings but to a more subtle degree. Rather than a widely notched uvula one may see only a fine fissure. The hard palatal notch may be minimal and the midline translucency and muscular triangulation obscure if present at all (Figure 4). Here muscular development has proceeded along more normal lines but often has stopped short of the normal function needed for speech and middle ear respiration. Not uncommonly there will be muscular decussation, but at indiscrete levels with the *musculus uvulae* atretic or absent entirely. This leads to a central gap in the soft palate through which orally impounded air pressure escapes. Increased nasality and speech distortion results.

Summarizing, the following historical and clinical markers will alert the pediatric dentist to the possible presence of submucous cleft palate.^{7,8}

1. Nasal regurgitation
2. Chronic otitis media
3. Hypernasal speech with misarticulations
4. Bifid or grooved uvula
5. Translucent palatal raphe (variable)
6. Hard palate with a palpable notch in the posterior midline
7. Muscular triangulation upon palatal elevation (variable).

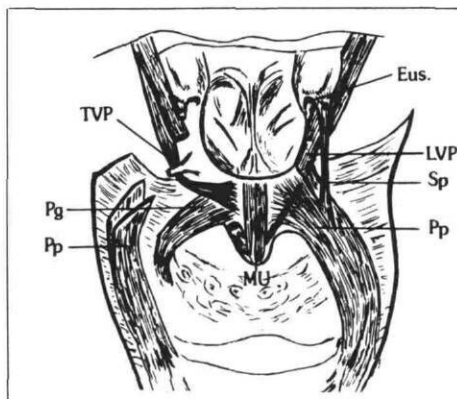
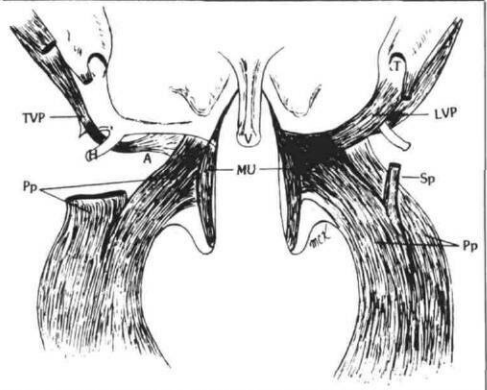


FIGURE 3a. (left) The normal muscular anatomy of the velum.

FIGURE 3b. (right) The abnormal anatomy of a clefted secondary palate. Note the cleft muscular components insertion onto the posterior palatal borders and nasal hemispines.



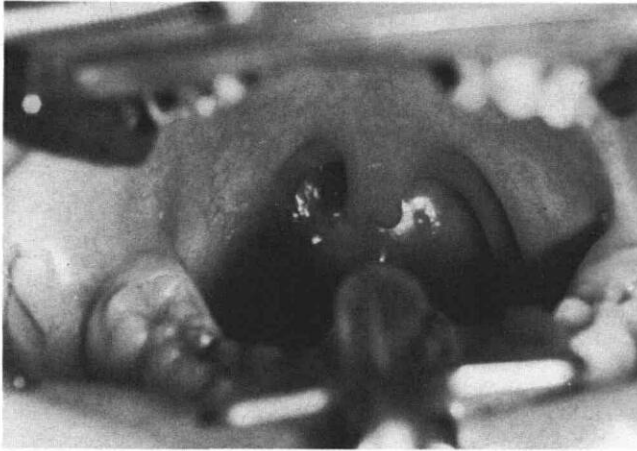


FIGURE 4. The grooved uvula of occult submucous cleft palate. Zona pellucida is absent, minimal hard palatal notching is palpable.

The symptoms and signs of submucous clefting may become obvious in infancy (regurgitation), and later when the child begins to talk. This is quite variable; frequently the condition manifests itself only after adenoidectomy performed to correct chronic otitis media. The child's limited velopharyngeal closure, formerly compensated by the presence of the adenoids, then becomes clinically apparent with persistent hypernasal speech. Otitis media occurs frequently in the pediatric age group; surgical remediation by adenoidectomy and combined myringotomy with possible placement of pneumatic equilibration (PE) tubes is appropriate for otherwise normal children.^{9,10} However, in children with these "microform" palatal clefts adenoidectomy may be deleterious for speech and the otologic intervention not definitive for middle ear dysfunction unless the palatal musculature is reoriented.^{11,12}

The adenoids play a major role in velopharyngeal competency; they provide a pad against which the soft palate and pharyngeal walls are abutted as the portal is "stopped down" in production of most consonants (except *M*, *N*, and *NG*) and nonnasal vowels.¹³ As a child grows older, the adenoids regress in size, thus causing a developmental increase in the nasopharyngeal dimensions. Normally the soft palate undergoes adaptation in posture and length to maintain proper portal size, through the process of "velar stretch."¹⁴ Muscular activity plays a pivotal role in this phenomenon in that it "pulls" the palate and thereby supports growth. This adaptation also explains the transient nature of the hypernasal resonance which may follow any adenoidectomy. With submucous cleft palate, and in such other conditions as congenitally short palate or even bulbar palsy, abnormal palatal and pharyngeal muscular activity may prohibit compensation.

It is realized fully that recurrent upper respiratory infections, with accompanying otitis media, may necessitate adenoidectomy in any of these children. In that event selective adenoidectomy is employed by the otologist to remove only the lymphoid tissue encroaching upon the eustachian tube orifices. Middle ear respiration is thereby facilitated and bulk retained in the strategic areas of velopharyngeal closure. In the cleft palate, proper orientation of the muscles, prominently the tensor veli palantini, further may support middle ear respiration. As these muscles are joined across the midline, they can act toward opening the eustachian tubes.

The following clinical reports will develop further the foregoing comments and describe surgical correction of submucous cleft palates.

Patient 1

This otherwise normal eight-year-old female was referred jointly by her otologist and speech therapist for surgical correction of an obvious submucous cleft palate.

The child had experienced multiple episodes of otitis media prompting placement of PE tubes. Speech therapy had been postponed pending surgical management of the submucous cleft palate. In the child's early years she had exhibited hypernasal speech along with articulation errors and speech substitutions which limited conversational intelligibility. There was also a history of nasal regurgitation with fluid ingestion.

There was no history of submucous cleft palate in this child's family, although heavy ethanol intake (maternal) in the first trimester was highly suspect.

Clinical findings are illustrated in Figure 1. Lateral phonating cephalograms showed apparent velopharyngeal closure; however, fiberoptic nasopharyngoscopy defined a central triangular gap of 8 mm in the velopharyngeal portal (absence of the musculus uvulae). Figure 5 depicts the nasopharyngoscopic view of normal (a & b) and submucous cleft palate (c & d) velopharyngeal portals. The portals on the left are at repose while those on the right are closed as during speech production. Note that the portals differ in the presence of the musculus uvulae (a). The central triangular gap which allows escape of orally impounded air pressure during functions clearly is seen (d).

Surgical repair involved a V-Y palatal pushback and simultaneous transposition of a superiorly based pharyngeal flap.^{15,16} The palatal muscles were detached from the hard palatal border, dissected into components, and retrodisplaced and anastomosed across the midline. A free buccal mucosal graft was placed on the nasal surface of the soft palate to decrease scar contracture and subsequent relapse of the palatal lengthening. The lateral velopharyngeal por-

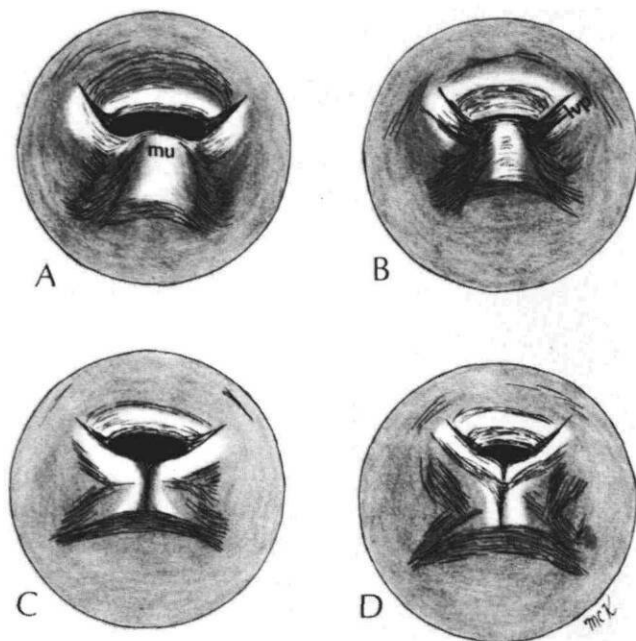


FIGURE 5. Nasopharyngoscopic schemata of normal (top) and submucous cleft palate (bottom) velopharyngeal portals.

tals formed by attachment of the pharyngeal flap were stented by rubber catheters threaded through these air passages on either side. The catheters were removed in seven days, having completed their role of adapting and maintaining lateral portal size and patency.¹⁷

Healing was uneventful and the patient returned for speech therapy within three weeks. The hypernasality was eradicated although articulation errors remained which were to be the subject of speech retraining.

Patient 2

This six-year-old male was referred by a pediatric dentist for surgical management of an occult submucous cleft palate.

This child had a history similar to that of the previous patient. However, speech pathology was less involved and was limited to mild hypernasality and an articulation disorder.

Clinical findings were as shown in Figure 4, including a grooved uvula and suggestions of triangular muscle ridging upon palatal elevation. A minimal cleft of the hard palate was palpated. Once again, lateral phonating radiography (videofluoroscopy) showed apparent velopharyngeal closure. However, nasopharyngoscopy exhibited a triangular notch with a 3 mm sagittal discrepancy. The velar eminence, which is formed by "inch-worm" contraction of the musculus uvulae, was notably absent (Figure 5c).

Surgical management was similar to that of the preceding patient. In contrast, however, the muscular discontinuity was limited to the area anterior to an intact palatopharyngeal ring and was managed with retropositioned anastomosis of the levator veli palatini and palatine aponeurosis (tensors) accordingly. Because the velopharyngeal defect was mild, it was elected merely to lengthen the palate and provide a midline bulge by rotation of the uvula halves onto the nasal surface. Following discharge, speech therapy rapidly improved the mild residual articulation problems; no hypernasality remained.

Discussion

Two instances of submucous palatal clefting have been presented. The first was an older child with an overt submucous cleft. This patient had developed speech substitutions which could have been overcome with considerably less difficulty had the palatal surgery occurred earlier in life — before neuromuscular programming of the aberrant soft palate and pharyngeal musculature had been established in compensation for the anatomic abnormalities. Similarly, the chronic otitis media may have been decreased by normalization of the palatal muscles with less threat of irreversible changes in the middle ear. A similar problem, though less involved, was presented by the occult submucous cleft of the second patient. Without a systematic pediatric dental evaluation the existence of this condition might have remained undisclosed.

The interrelated problems of chronic otitis media and faulty speech production may be diminished by functional reorientation of the palatal muscles and simultaneous revision of the velopharyngeal portal, as noted in the patient presentations. However, given the absence of absolute bulk in the velum, there may remain problems of excessive nasality. Where the individual is unable to decrease the portal size to 20 mm² during connected speech, pharyngoplastic procedures offer assistance toward competency.¹⁸ The most commonly used is the pharyngeal flap, either inferiorly or superiorly based, as discussed for Patient 1. These flaps act primarily as baffles which bridge the open aperture. They rely upon lateral pharyngeal wall movement to close the portal and allow impoundment of oral air pressure, which diminishes nasal resonance, and produces normal speech.¹⁹ Other procedures include laterally based flaps from the pharyngeal walls or the posterior tonsillar pillars which provide dynamic sphincteric activity.^{20,21} All flap procedures find greatest efficacy in wide velopharyngeal gaps. For milder discrepancies — for example a linear 5 mm gap between the pharyngeal wall and velum — simple augmentation of the posterior pharyngeal

wall with alloplastic material,^a lypholized cartilage, or musculomucosal flaps elevated and transposed totally within the posterior pharyngeal wall may suffice.²²⁻²⁴ Whatever mode is chosen, be it a velopharyngeal baffle (flap) or "padding" of the posterior wall, palatal lengthening by "push-back" and certainly muscular reorientation may be a necessary accompaniment.

Both of these cases underscore the role of the pediatric dentist in detecting submucous clefts of the palate. No health care professional has greater expertise in evaluating the oropharyngeal structures of a child; indeed, the small proportions of an infant or the prospect of a bitten finger in the young child often rule against close scrutiny. Additionally, few others have equivalent opportunity for thorough examination, whether it be in chairside evaluation or under general anesthesia induced for restorative purposes.

Genetic predisposition to orofacial clefting is obtained through the family history; recurrent clefting should arouse suspicion, as should the mother's first trimester ingestion of any teratogen, including ethanol or anti-nausea medications.²⁵ The presence of a congenital anomaly, be it an isolated cleft lip, limb, heart, or renal malformation, also warrants a close inspection of the palate. Regarding the personal history, persistent nasal regurgitation, delayed speech, or recurrent episodes of otitis media are important historical markers.

The clinical signs of submucous cleft palate are often difficult to ascertain due to the young child's resistance to examination and reluctance to say "ah" to lift his palate. Visual inspection obviously is hampered, even more so where salivary adsorption and surface tension hold the clefted uvula halves into such close apposition as to escape detection. Where suspected, the uvulae must be separated physically with a mirror for example, for substantiation (Figures 6a & b).

Residual Submucous Cleft

To this point discussion has centered around a previously undetected submucous palatal cleft. There exists another related entity which merits mention, the residual submucous cleft.²⁶ This represents sub-

mucous cleft muscular anatomy left after simple edge-to-edge closure of a complete palatal cleft. In this instance functional muscular dissection and reorientation is not achieved in the primary repair. The residual problems of deficient palatal growth, velopharyngeal incompetency, hypernasality and speech misarticulations, and persistent otitis media,^{27,28} then are superimposed upon similar problems which may be ascribed to the pediatric population in general (speech delays and otitis media) and the cleft population in particular (speech delays associated with hypernasality and otitis media). Just because a palate has been repaired, it does not follow that functional repair has been achieved.

Where the condition is suspected, mere observation of the palate in maximal lift may be diagnostic. Normal creasing in the subuvular zone is replaced by triangular ridging or more anterior dimpling, in the velum (Figure 7a), which indicates clinically that muscular decussation is yet lacking (Figure 7b). Further investigation, such as still or dynamic phonating cephalography, or nasopharyngoscopy, should be arranged in that situation. Lateral, still phonating cephalography and nasopharyngoscopy has been illustrated previously; Figures 8a & b demonstrate dynamic, phonating cephalography performed upon another patient with anterior displacement of the velar eminence compatible with residual submucous clefting. With residual abnormality confirmed, revisional surgery such as presented in the clinical reports is indicated. It is not uncommon that ongoing speech therapy will achieve remarkable progress once the remaining deformity is eradicated and the anatomic basis for normal function achieved.

Conclusion

The pediatric dentist is in a unique position to diagnose submucous cleft palate and to refer the child for early or, in the case of residual clefting, revisional treatment. Such intervention can help assure optimal speech and hearing development for the child.

Historical and clinical markers which should alert the pediatric dentist to the possible presence of submucous cleft palate include:

^a E.g., Proplast—Vitek Corp.; Houston, TX.

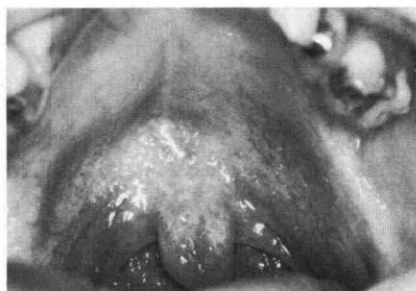
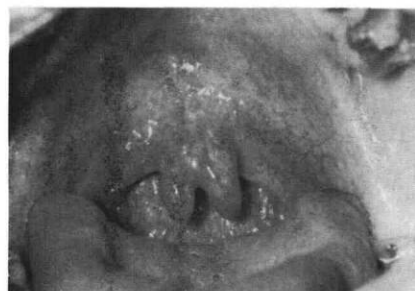
FIGURE 6a. (left) Demonstrating the changing characteristics of the bifid uvula. Here surface tension from saliva holds the uvula in apposition.

FIGURE 6b. (right) After physical separation of the uvular halves. Note the suggestion of muscular triangulation on these views of palatal elevation.



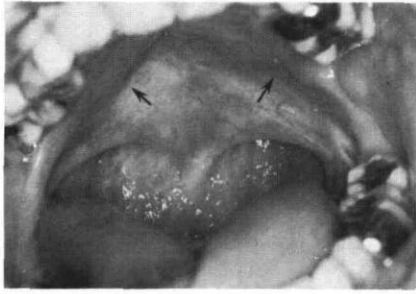


FIGURE 7a. (left) A residual submucous cleft palate in this patient who had undergone multiple procedures, including an inferiorly based pharyngeal flap for velopharyngeal incompetency. Triangular muscular ridging is seen on attempted palatal elevation (arrows).

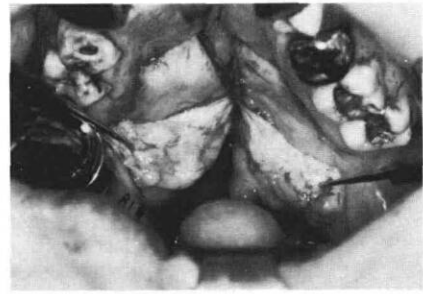

FIGURE 7b. (right) Midline fibrofatty tissue noted upon surgical division of the palate denotes lack of muscular continuity; instead, the muscles retained their "cleft" orientation.

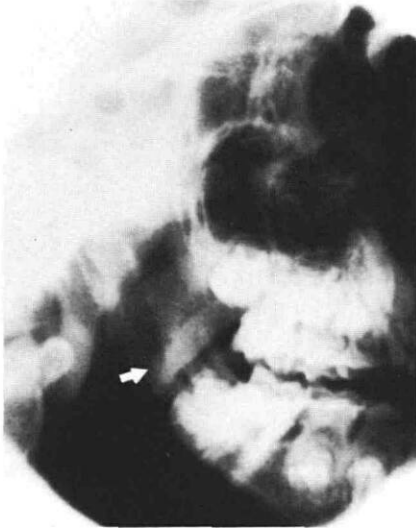


FIGURE 8a. (left) Videofluoroscopic view of an orofacial cleft patient with velum at repose (arrow).



FIGURE 8b. (right) Maximal palatal elevation in this dynamic study is inadequate, and shows flexing activity near the hard palatal velar attachments (arrow). This pattern strongly suggests residual submucous clefting (confirmed at revisional surgery).

1. A family history of orofacial clefting
2. Maternal ingestion of teratogens during the first trimester of pregnancy
3. Other congenital anomalies
4. Recurrent episodes of otitis media
5. Persistent nasal regurgitation
6. Delayed speech acquisition
7. Hypernasality, nasal emission, and faulty speech production
8. Bifid or grooved uvula
9. Translucent palatal raphe
10. Palpable notch in the midline of the posterior hard palate
11. Muscular triangulation upon palatal elevation
12. A history of a repaired palatal cleft with speech problems and findings of muscular triangulation (residual submucous cleft).

Clinical evaluation may be hampered by a resistant child or by a throat pack in the anesthetized patient. Nevertheless, a thorough examination is indicated for any patient presenting with these clinical and historical markers.

Dr. Kinnebrew is an associate professor, oral and maxillofacial surgery and communication disorders, and is coordinator, oral facial anomalies group, Louisiana State University Medical Center, New Orleans, LA. Dr. McTigue is a professor and chairman, pedodontics, The Ohio State University, College of Dentistry, 305 W. 12th Ave., Columbus, OH 43210. Reprint requests should be sent to Dr. McTigue.

1. Weatherly-White RCA, Sakura CY, Brenner LD, Stewart JM, Ott JE: Submucous cleft palate — its incidence, natural history, and indications for treatment. *Plast Reconstr Surg* 49:297-304, 1972.
2. Calnan J: Submucous cleft palate. *Br J Plast Surg* 6:264-82, 1954.
3. Kaplan EN: The occult submucous cleft palate. *Cleft Palate J* 12:356-68, 1975.
4. Poswillo D: The pathogenesis of submucous cleft palate. *Scand J Plast Reconstr Surg* 8:34-41, 1974.
5. Latham RA, Long RE, Latham EA: Cleft palate velopharyngeal musculature in a five-month-old infant: a three-dimensional histological reconstruction. *Cleft Palate J* 17:1-16, 1980.
6. Kriens OB: Anatomy of the velopharyngeal area in cleft palate. *Clin Plast Surg* 2:261-83, 1975.
7. Sphrintzen RJ, Schwartz R, Daniller A, Hoch L: The morphologic significance of bifid uvula: Is it a marker for submucous cleft palate? Abstract, 40th Annual Session of American Cleft Palate Association, Indianapolis, 1983.

8. Witzel A, Rich RH, Margar-Bacal F, Cox C: Velopharyngeal insufficiency after adenoidectomy: an eight-year review. Abstract, 40th Annual Session of American Cleft Palate Association, Indianapolis, 1983.
9. Yamaguchi T, Somekawa Y, Ara H, Kataura A: Indications for the use of ventilating tubes for secretory otitis media. *Int J Pediatr Otorhinolaryngol* 4:29-38, 1982.
10. Virtanen H: Eustachian tube function in children with secretory otitis media. *Int J Pediatr Otorhinolaryngol* 5:11-17, 1983.
11. Morgan RF, Dellon AL, Hoopes JE: Evaluation of levator retractor displacement upon conductive hearing loss in the cleft palate patient. Abstract, 39th Annual Session of American Cleft Palate Association, Denver, 1982.
12. Too-Chung MA: The assessment of middle ear function and hearing by tympanometry in children before and after early cleft palate repair. *Br J Plast Surg* 36:295-99, 1983.
13. Subtelny JD, Baker HK: The significance of adenoid tissue in velopharyngeal function. *Plast Reconstr Surg* 17:235-50, 1956.
14. Pruzansky S, Mason RM: The "stretch factor" in soft palate function. *J Dent Res* 48:972, 1969.
15. Kilner TP: Cleft lip and palate repair technique. *St Thomas Hosp Rep* 2:127-40, 1937.
16. Wardill WEM: The technique of operation for cleft palate. *Br J Surg* 25:117-30, 1937.
17. Hogan VM: A clarification of the surgical goals in cleft palate speech and the introduction of the lateral port control (LPC) pharyngeal flap. *Cleft Palate J* 10:331-45, 1973.
18. Warren DW: Velopharyngeal orifice size and upper pharyngeal pressure flow patterns in normal speech. *Plast Reconstr Surg* 33:148-62, 1964.
19. Owsley JC, Blackfield HM: The technique and complications of pharyngeal flap surgery. *Plast Reconstr Surg* 35:531-39, 1965.
20. Kapetansky DI: Transverse pharyngeal flaps: a dynamic repair for velopharyngeal insufficiency. *Cleft Palate J* 12:44-50, 1975.
21. Reichert H: The lateral velopharyngoplasty: a new method for the correction of open nasality. *J Maxillofac Surg* 2:95-101, 1974.
22. Wolford LM: Proplast pharyngeal wall implants to correct VPI: long-term results. Abstract, 40th Annual Session of American Cleft Palate Association, Indianapolis, 1983.
23. Hynes W: Pharyngoplasty by muscle transplantation. *Br J Plast Surg* 3:128-35, 1950.
24. Wardill WEM: Results of operation for cleft palate. *Br J Surg* 16:127-48, 1928.
25. Burdi AR: Cleft lip and palate research. An updated state of the art. I Epidemiology, etiology, and pathogenesis of cleft lip and palate. *Cleft Palate J* 14:261-69, 1977.
26. Kinnebrew MC: The "residual submucous cleft," in VPI — Velopharyngeal Incompetency, a Practical Guide for Evaluation and Management, Rampp DL, Pannbacker MD, Kinnebrew MC. Tulsa, OK; Modern Educational Corp, 1984 pp 57.
27. Stool SE, Randall P: Unexpected ear disease in infants with cleft palate. *Cleft Palate J* 4:99-103, 1967.
28. Bluestone CD: Eustachean tube obstruction in the infant with cleft palate. *Ann Oto Rhinol Laryngol* 80:1-30, 1971.

Quotable quote: you are what you don't eat

Oregon researchers are unruffled by waves of criticism that hit them this week when they released findings suggesting a link between hypertension and diets deficient in calcium, potassium, vitamins A and C, and — most controversial — salt.

David McCarron, Cynthia Morris, and others at Oregon Health Sciences University in Portland analyzed 1977 data from the National Center for Health Statistics' Health and Nutrition Examination Survey (HANES 1). They looked for relationships between high blood pressure (estimated to afflict 37 million Americans) and 17 nutrients in 10,372 people ages 18-74.

"Significant decreases in the consumption of calcium, potassium, vitamin A . . . and C were the nutritional factors that distinguished hypertensives from normotensive subjects," says the report published in the June 22 *Science*. Lower calcium intake was the most significant factor among hypertensives. They also found a weak correlation between hypertension and low salt in the diet. No causation is claimed, but the group urges more studies on nutrition links to high blood pressure, even if it bucks "common wisdom" of dietary excesses, rather than deficiencies, as leading to increased systolic pressure, Morris says.

Prior studies have suggested ties among calcium and potassium, and hypertension, but this is the first to correlate vitamin deficiencies, Morris told *Science News*. Lower vitamin intake among hypertensives may reflect the close diet association of vitamin A with calcium, and C with potassium, she adds. Because dairy foods are a major source of calcium and potassium, the Oregon report says lower dairy food consumption is "most closely related" to high blood pressure. Not everyone agrees.

American Heart Association President Antonio Gotto says salt intake must be cut, and no one should increase dairy foods based on the "unverified hypothesis" of this report. Morris says, "As for controversy . . . anyone can replicate our analysis." No dairy council money was used for this specific study, she adds.

Rowand A: You are what you don't eat.
Science News, June 30, 1984.