

A laboratory fabricated fixed appliance for extruding anterior teeth with subgingival fractures

Nigel M. King, MSc, BDS, LDSRCS Lisa So, BDS

Abstract

Traumatized anterior teeth with subgingival fractures of the crown and root can be restored successfully after orthodontic extrusion. A technique is described which involves the use of a localized fixed appliance made of rectangular wire. The appliance is fabricated in the laboratory prior to bonding to the teeth with composite resin. The simple design of the appliance makes it easy to manage and esthetically acceptable to patients.

If a tooth is to be saved, which as a result of trauma has a subgingival fracture involving the crown and root, it requires treatment of a multidisciplinary nature including endodontics, orthodontics, periodontics, and restorative dentistry.

Since Heithersay (1973) reported a combined endodontic-orthodontic technique for the extrusion of a traumatized tooth, various methods have been described in order to adequately expose sound tooth substance for the finishing of the margins of the final coronal restoration (Heithersay and Moule 1982). These techniques require endodontic therapy to have been performed previously. In addition, it is recommended that the fractured segment of the crown be removed to facilitate fixation of an intra-radicular device for the attachment of the active component which is responsible for applying the extrusive force to the tooth. Removal of the fractured portion of the crown generally results in hemorrhage of the gingival tissues which were attached to that part of the tooth, hence, obstructing the operating field and preventing adequate isolation of the root canal. This problem can be overcome if the fractured coronal fragment is left in situ. This can be achieved by using pins plus composite resin (Spasser 1977) or composite resin alone (Mader 1987). The recently introduced dentin bonding agents also can be used (Ludolow and LaTurno 1985).

When the active component is a spring (Fournies 1981) or even a magnet (McCord and Harvie 1984), they require a removable appliance to be fitted. Localized appliances (Simon et al. 1987) and full-arch fixed appli-

ances (Wolfson and Seiden 1975) incorporate an elastic band or an elastic ligature. Removable appliances are bulky and require considerable patient cooperation which is not always available, especially in young children. These problems can be overcome by the use of a fixed appliance. However, considerable chairside time and specialized materials are required to fabricate and fit a fixed appliance.

A simple fixed appliance is described that can be fabricated easily in the laboratory and fitted to the crown of the fractured tooth utilizing materials routinely available in the dental office.

Method

The following technique using a laboratory fabricated fixed appliance for extruding anterior teeth has been used to successfully treat teeth with subgingival fractures of differing severity.

Following bonding of the crown fragments of the fractured tooth, endodontic therapy can be performed more easily (Fig 1). Alginate impressions of the maxillary and mandibular arches are taken to fabricate stone casts. The appliance is designed and completed in the laboratory by the technician. The appliance consists of a heavy gauge rectangular wire (0.017 x 0.022") with a metal gauze pad welded to each end. Two hooks for attachment of the active component are

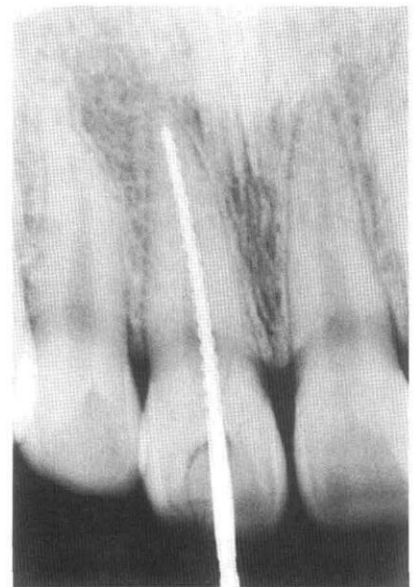

FIG 1. A radiograph of a traumatized maxillary right central incisor with a subgingival fracture (arrow) during endodontic therapy.

made of the same rectangular wire, as are the "stops" which overlap the incisal edges of the adjacent incisor teeth. All of these components are welded and then soldered onto the arch wire. An orthodontic bracket, hook, or button then is selected for bonding onto the fractured tooth to which the active component can be attached (Fig 2).

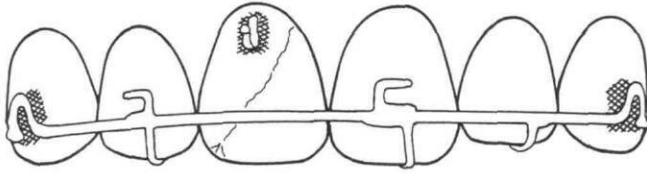


FIG 2. Fixed appliance.

After the enamel on the labial surfaces of the canines and the fractured tooth have been cleaned with a pumice slurry and etched with phosphoric acid, the gauze pads at the ends of the arch wire are bonded onto the canines with composite resin. The orthodontic bracket or hook then is bonded to the traumatized tooth; it must be located sufficiently close to the gingival margin of the tooth so as to provide an adequate vertical distance through which the tooth can be extruded. Gingival retraction cord provides good gingival retraction and enhances moisture control in this region during the bonding of the button. After waiting at least 5 min for the composite to set, intraoral latex elastics exerting 80 g of force then are placed over the hooks (Fig 3). These elastics need to be changed daily by the patient. Weekly

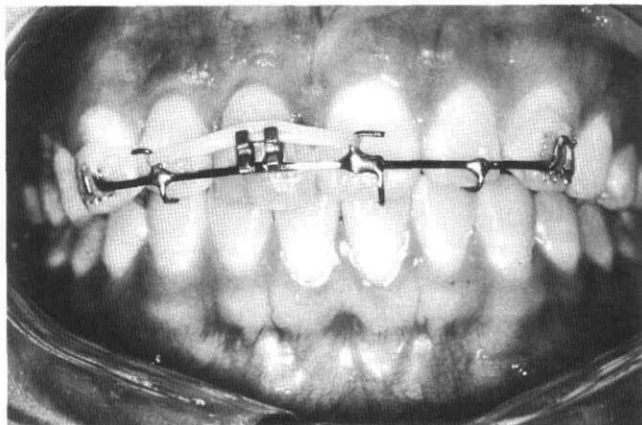


FIG 3. The appliance at the commencement of the extrusion phase using a latex elastic as the active component.

reviews are necessary because the extrusion process is quite rapid, the rate of extrusion being approximately 1 mm/week. The height of the clinical crown of the extruded tooth as well as the palatal cingulum may need to be adjusted according to the length of the adjacent teeth if the esthetics are to be maintained, and to make any minor occlusal adjustments (Fig 4).

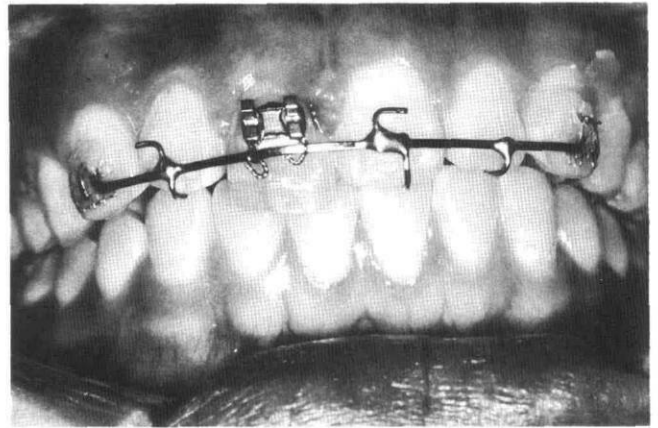


FIG 4. A maxillary right central incisor which was extruded until the bracket was in contact with the arch wire. A ligature wire was placed to retain the tooth in this position. The length of the clinical crown and the position of the gingival margin need to be adjusted to match the adjacent tooth.

When the tooth has reached the desired position, which can be assessed clinically and radiographically (Fig 5), it should be stabilized by a ligature wire attached to the bracket and the arch wire (Fig 4). Circumferential supracrestal fibrotomy is recommended to improve the tooth's stability. If the procedure is not performed, the tooth may undergo a reactionary intrusion when the retaining ligature is removed. The period of retention is calculated using the formula of 1 month of retention per millimeter of extrusion (Lemon 1982). Following the appropriate period of retention, gingival recontouring frequently is required after which the tooth can be prepared and have the final coronal restoration.

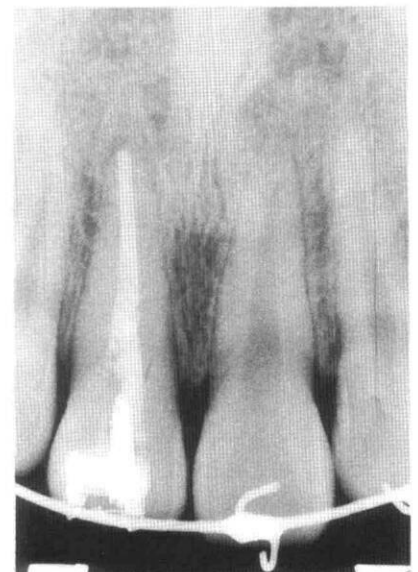


FIG 5. A radiograph of a maxillary right central incisor indicating the extent of the extrusion.

Discussion

Unlike removable appliances, this fixed appliance requires only minimal patient cooperation for changing the latex elastics. If even this degree of cooperation is in doubt, or the patient lacks the manual dexterity, Power TubeTM ^a or Zing[®] String^b can be utilized and changed by the operator each week.

^a Ormco — Sybron Corp; Glendora, CA.

^b TP Laboratories Inc; LaPorte, IN.

Because this appliance is less bulky than a removable type, it is more easily tolerated, especially by an older patient. When compared to full arch fixed appliances, this localized fixed type of appliance allows the patient to maintain a high standard of oral hygiene easily.

The use of rectangular wire makes it easy for the technician to align the hooks and stops for welding and soldering. In addition, the heavy gauge rectangular wire is rigid enough to resist distortion during the extrusion process. Surface contacts between the passive rectangular wire and the labial surfaces of adjacent teeth prevent untoward secondary torsional effects, such as tipping or rotation of the adjacent teeth. Anchorage is provided by the canines and the adjacent teeth via the bonds and stops. Hence, there is minimal risk of the adjacent teeth being intruded with this appliance.

By retaining the natural crown of the tooth throughout the extrusion process, there is neither loss of arch length nor over-eruption of the opposing tooth. If the fractured fragment has been lost the traumatized tooth can be restored with composite resin or even with a temporary crown prior to extruding the tooth with this appliance. As no intra-radicular fixture is required with this appliance, it also can be used for fractured teeth with immature roots which usually present problems with retention of temporary posts (Cooke and Scheer 1980).

Long-term studies of teeth with fractures involving the crown and root are limited (Andreasen 1985). Hence, data on the histology of human teeth that have been extruded are not available. However, it has been shown that occlusal movement of the alveolar bone housing of an extruded tooth is followed by bone deposition at the alveolar crest in dogs (Simon and Torabinejad 1980). This being the case, in humans the tooth can be expected to become stable after a period of retention during which the supporting bone can reorganize.

As the gingival margin of an extruded tooth tends to be at a different level than that of a normal tooth, pericision and minor localized gingivectomy to recontour the gingivae may be required prior to the final restoration. This procedure is far less difficult for the child patient than would be the osseous recontouring technique (Langdon 1968) if the traumatized tooth had not been extruded.

The authors thank the Dental Illustration Unit of the Prince Philip Dental Hospital for the illustrations.

Dr. King is a senior lecturer and Dr. So is a postgraduate dental officer, children's dentistry and orthodontics, University of Hong Kong. Reprint requests should be sent to: Dr. Nigel M. King, Dept. of Children's Dentistry and Orthodontics, University of Hong Kong, The Prince Philip Dental Hospital, 34 Hospital Rd., Hong Kong.

Andreasen JO: Challenges in clinical dental traumatology. *Endod Dent Traumatol* 1:45-55, 1985.

Cooke MS, Scheer B: Extrusion of fractured teeth. *Br Dent J* 149:50-53, 1980.

Fournies A: Orthodontic management of subgingivally fractured teeth. *J Clin Orthod* 15:502-3, 1981.

Heithersay GS: Combined endodontic-orthodontic treatment of transverse root fractures in the region of the alveolar crest. *Oral Surg* 36:404-15, 1973.

Heithersay GS, Moule AJ: Anterior subgingival fractures: a review of treatment alternatives. *Aust Dent J* 27:368-76, 1982.

Langdon JD: Treatment of oblique fractures of incisors involving the epithelial attachment. A case report. *Br Dent J* 125:72-74, 1968.

Lemon RR: Simplified esthetic root extrusion techniques. *Oral Surg* 54:93-99, 1982.

Ludlow JB, LaTurno SAL: Traumatic fracture — one-visit endodontic treatment and dentinal bonding reattachment of coronal fragment: report of case. *J Am Dent Assoc* 110:341-42, 1985.

Mader C: Restoration of a fractured anterior tooth. *J Am Dent Assoc* 96:113-15, 1978.

McCord JF, Harvie H: An alternative treatment of anterior teeth fractured beneath the gingival margin. *Br Dent J* 157:320-22, 1984.

Simon JHS, Torabinejad M: Clinical and histologic evaluation of extruded endodontically treated teeth in dogs. *Oral Surg* 50:361-71, 1980.

Simon JHS et al: Extrusion of endodontically treated teeth. *J Am Dent Assoc* 97:17-23, 1978.

Spasser HF: Repair and restoration of a fractured pulpally involved anterior tooth: report of a case. *J Am Dent Assoc* 94:519-20, 1977.

Wolfson E, Seiden L: Combined endodontic-orthodontic treatment of subgingivally fractured teeth. *J Can Dent Assoc* 11:621-24, 1975.