

Clinical Evaluation of a Compomer and an Amalgam in Primary Teeth Class II Restorations: A 2-year Comparative Study

Katerina Kavvadia, DDS, MDentSc, Dr Odont Afrodite Kakaboura, DDS, Dr Odont
 Apostole P. Vanderas, DDS, JD, MPH, MDS, Dr Odont Liza Papagiannoulis, DDS, MSc, Dr Odont
*Dr. Kavvadia is a lecturer, Dr. Vanderas is assistant professor, and Dr. Papagiannoulis is professor and chairman, Department of Pediatric Dentistry; and Dr. Kakaboura is associate professor, Department of Restorative Dentistry, University of Athens, Greece.
 Correspond with Dr. Kavvadia at kavad@dent.uoa.gr*

Abstract

Purpose: This study was performed to compare the clinical performance between the compomer F2000 and amalgam Dispersalloy in Class II restorations in primary molars over a 2-year period.

Methods: Seventy-five amalgam and 75 compomer restorations were placed in 75 children based on a split-mouth design. The restorations were evaluated after 1 week and after 6, 12, 18, and 24 months of oral function. The evaluation consisted of a clinical assessment according to modified Ryge criteria, a radiographic examination using bite-wing radiographs, and an observation of epoxy casts under scanning electron microscopy.

Results: The results showed statistically significant differences in the marginal adaptation and anatomic form between amalgam and compomer restorations. A higher number of compomer restorations were rated as Bravo, while a higher number of amalgam restorations were rated as Alpha at 24 months. Significant differences in the failure of the restoration and development of secondary caries were not found between the materials.

Conclusions: The use of compomer F2000 in Class II restorations in primary molars, although it presents a significantly higher number of restorations rated as Bravo regarding the marginal adaptation and anatomic form vs the amalgam, does not increase the risks of developing secondary caries and failure of the restoration over a period of 2 years. (*Pediatr Dent.* 2004;26:245-250)

KEYWORDS: COMPOMER, AMALGAM, CLASS II RESTORATIONS, PRIMARY MOLARS

Received June 5, 2003 Revision Accepted January 2, 2004

The increasing demand for esthetic restorations and the public concern over the harmful effects of mercury on health and the environment led to the development of alternatives to amalgam restorative materials such as polyacid-modified resin composites, also called compomers. Compomers have been recommended for the restoration of cervical lesions in permanent teeth¹ and for Class I and II lesions in primary teeth.^{2,3} The fluoride-release potential, bonding capacity with enamel and dentin, and easy handling of compomers are considered their main advantages.²

Clinical studies⁴⁻¹⁵ evaluating compomers in Class II restorations of primary teeth showed a wide distribution of failure rates, ranging from 4% to 22% for up to 2 years of clinical service. These studies, however, evaluated the first developed, commercially available product (Dyract,

DeTrey/Dentsply, Konstanz, Germany), while the newer developed compomer (F2000 3M ESPE, St. Paul, Minn) has not yet been tested. In spite of the restricted use of amalgam as a restorative material in lesions of posterior primary teeth, amalgam is still considered the reference filling material of choice for these restorations.

The aim of the present study was to compare the clinical performance between the compomer F2000 and amalgam Dispersalloy in Class II restorations in primary molars over a 2-year period.

Methods

Sample size

The sample population consisted of 75 children ages 6 to 9 years old (mean age=7±1.2) from 2 pediatric dentistry

private practices. The purpose and clinical procedures of the study were fully explained to the parents, and consent forms were completed and signed. The children were under a regular preventive program, including recalls every 6 months for oral hygiene instructions and topical fluoride application. One hundred and fifty teeth, 2 primary first or second molars per patient, distributed to contralateral quadrants were selected using clinical and radiographic criteria to ensure the vitality of the teeth and existence of proximal caries extending into dentin but not involving the pulp. Prior to this study, a pilot study was performed for interoperator calibration regarding case selection, cavity preparation and filling procedure.

Clinical procedure

In each pair of molars, one was filled by the compomer F2000, (3M ESPE, St. Paul, Minn) and the other one was filled by the amalgam Dispersalloy (DeTrey/Dentsply, Konstanz, Germany). The restorative material per tooth was assigned by computer-generated random number tables. Restorations were placed in the same type of contralateral teeth—first or second primary molars. The opposing teeth of the restored teeth were either intact or filled with amalgam or resin composite. The restorations were placed by 2 qualified and experienced pediatric dentists using a rubber dam. The decayed tissues were removed and a conservative Class II cavity was prepared according to the one suggested by project Tapp.¹⁶ A resin-modified glass ionomer liner (Vitrebond, 3M ESPE, St. Paul, Minn) was applied only close to the pulp areas of the excavated cavities. Metal matrix bands and wooden wedges were used in the application of both materials in Class II cavities.

For compomer restorations, a self-etching adhesive (Clicker, 3M ESPE, St. Paul, Minn) was applied according to the manufacturer's instructions and the filling material was inserted. The compomer was placed in 2 incremental layers: the first layer was placed in the proximal box and the second in the rest of the cavity. Each layer was photopolymerized for 40 seconds using a light-curing unit (Elipar II, 3M ESPE, St. Paul, Minn) emitting 650 mW/cm² intensity as measured by a curing radiometer (Demetron, Model 100, Demetron Research Corp, Danbury, Conn). The buccal and gingival margins of the proximal box were subjected to an additional photopolymerization after matrix removal for 40 seconds. For amalgam restorations, the material was placed according to the customary procedure. The compomer restorations were finished immediately after photopolymerization with 12- and 24-fluted carbide burs (Jet Beavers, Morrisburg, Canada) and polished with the series of Soflex discs (3M ESPE, St. Paul, Minn), whereas the amalgam was finished and polished after 1 week with finishing burs and rubber cups (Kendal polishers, Kendal AG, Lichtenstein).

Evaluation of the restorations

The evaluation of the restorations was performed by clinical and radiographic examinations as well as by observation

of epoxy replicas from randomly selected restorations, under scanning electron microscope (SEM). Restorations were examined at baseline (1 week post insertion) and after 6, 12, 18, and 24 months, by 2 independently calibrated evaluators. When disagreement occurred between the 2 evaluators, a consensus was obtained with a third evaluator who was also a pediatric dentist.

The clinical examination was performed according to modified Ryge criteria¹⁷ as follows:

1. retention, bulk fracture, and secondary caries were ranked as Yes (presence) or No (absence);
2. surface texture, marginal adaptation, marginal discoloration, contact area, and anatomic form were ranked as Alpha (A=clinically ideal condition), Bravo (B=clinically acceptable condition), or Charlie (C=unacceptable condition).

Restorations were considered failures if restoration replacement was needed due to loss of retention or material fracture or secondary caries.

At the radiographic examination, bite-wing radiographs were taken at baseline, 12-, and 24-month examinations, and the incidence of secondary caries and defects presented at the cervical margin of the restorations were recorded.

Replicas were taken with polysiloxane impression material (Reprosil HF, DeTrey/Dentsply, Konstanz, Germany) from 16 randomly selected restorations (8 amalgam and 8 compomer) at baseline. The same restorations were followed at the 12- and 24-month examinations. Casts were then produced with an epoxy resin (Araldit, Ciba/Geigy, Basel, Switzerland) and examined under a SEM (515 Phillips, Eindhoven, The Netherlands).

Statistical methods

The data were subjected to a Mann-Whitney test to detect differences between the materials for each criterion, and a Kruskal-Wallis test ($\alpha=0.05$) to define differences for each material separately between recalls.

Results

From a total of 150 restorations placed, 114 (76%) were evaluated at the 24-month recall. The number of restorations examined and the exfoliated teeth, at each recall, are presented in Table 1.

Clinical evaluation

Table 2 shows the results of the assessment of the clinical performance of the amalgam and compomer restorations regarding retention, bulk fracture, and secondary caries at each examination. One amalgam restoration was lost and 1 compomer restoration presented secondary caries at the cervical margin after 24 months. No bulk fracture was recorded in any of the restorations.

Table 3 presents the results of the assessment of the clinical performance of amalgam and compomer restorations related to surface texture, marginal adaptation, contact area, marginal discoloration, and anatomic form. None of the restorations was graded as Charlie (C) up to 24 months. A statistically significant higher number of amalgam than

compomer restorations were rated as Bravo (B) in surface texture at 6- and 12-month examinations, whereas no statistically significant differences were detected at the 18- and 24-month evaluation times. Also, statistically significant dif-

ferences were found in the marginal adaptation between the 2 groups of restorations at 12, 18, and 24 months. A higher number of compomer restorations were assessed as Bravo. No differences were detected between the 2 materials for the proximal contact area for up to 24 months of oral function. Moreover, statistically significant differences were found in anatomic form between the compomer and amalgam restorations at 18 and 24 months. A higher number of compomer restorations were assessed as Bravo. Regarding the marginal discoloration, which was assessed only for F2000, significant differences were found between the 12- and 24-month examinations. More restorations were rated as Bravo at 24 months.

Table 1. Number of Restorations Evaluated at Each Examination

Examinations	Compomer	Exfoliated teeth	Amalgam	Exfoliated teeth
Baseline	75		75	
6 months	69	-	69	-
12 months	67	1	68	-
18 months	59	4	58	5
24 months	57	6	57	6

Table 2. Clinical Assessment of Retention, Bulk Fracture and Secondary Caries in Amalgam Dispersalloy (D) and Compomer F2000 (F) Restorations

Examinations		Baseline (%)		6 months (%)		12 months (%)		18 months (%)		24 months (%)	
		Ranking									
Criteria*		YES	NO	YES	NO	YES	NO	YES	NO	YES	NO
Retention	D	100	0	100	0	100	0	100	0	98	2
	F	100	0	100	0	100	0	100	0	100	0
Bulk Fracture	D	0	100	0	100	0	100	0	100	0	100
	F	0	100	0	100	0	100	0	100	0	100
Secondary Caries	D	0	100	0	100	0	100	0	100	0	100
	F	0	100	0	100	0	100	0	100	2	98

*The criteria were ranked as YES (presence) or NO (absence).

Table 3. Clinical Assessment of the Surface Texture, Marginal Adaptation, Contact Area, Marginal Discoloration, and Anatomic Form in Amalgam Dispersalloy (D) and Compomer F2000 (F) Restorations

Examinations		Baseline (%)		6 months (%)		12 months (%)		18 months (%)		24 months (%)	
		Ranking*									
Criteria		A	B	A	B	A	B	A	B	A	B
Surface texture	D	92	8	70	30	72	28	62	38	62	38
	F	96	4	87	13	84	16	70	30	59	41
Marginal adaptation	D	96	4	68	32	75	25	67	33	61	39
	F	100	0	77	23	64	36	54	46	53	47
Contact Area	D	99	1	99	1	96	4	81	19	79	21
	F	99	1	87	3	95	5	84	16	81	19
Marginal discoloration	D	NA†	NA†	NA†	NA†	NA†	NA†	NA†	NA†	NA†	NA†
	F	100	0	96	4	93	7	80	20	77	23
Anatomic form	D	100	0	91	9	90	10	74	26	76	24
	F	100	0	94	6	91	9	66	34	54	46

*There were no restorations ranked as C.

†NA=not applicable.

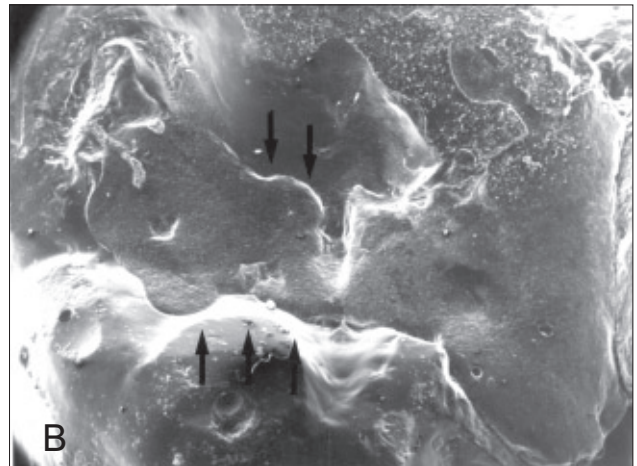
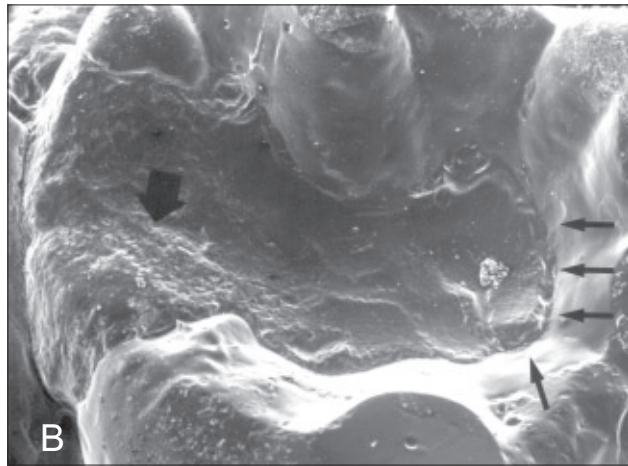

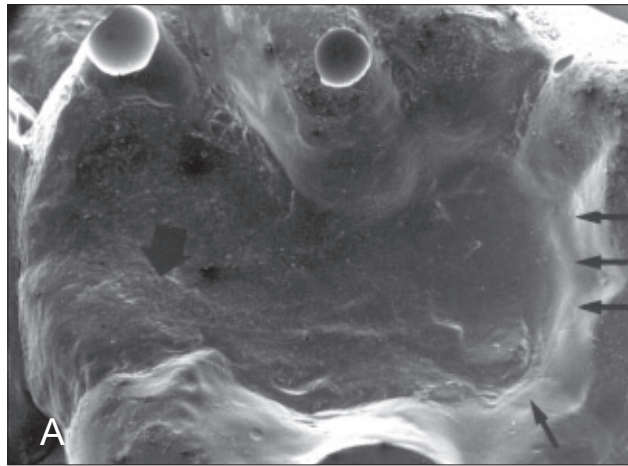


Figure 1. An amalgam restoration at 12- (A) and 24-month (B) examinations $\times 20$. Marginal microfractures, loss of anatomic form and inferior surface texture are more obvious at 24- compared to 12-month examination.

Figure 2. A compomer restoration at 12- (A) and 24-month (B) examinations (SEI, $\times 20$). Loss of anatomic form, marginal adaptation, and surface smoothness are noted vs time of oral function.

Amalgam and compomer restorations provided statistically significant lower numbers of Alpha (A) rates in all clinical criteria at the 24-month period compared to the baseline. There were no failures within the first 18 months. At the 24-month examination, the failure rate reached to 2% for both restoratives tested.

Radiographic evaluation

Radiographic evaluation at baseline showed cervical defects in 5 amalgam and 4 compomer restorations. The defects observed were overhangs and porous formation at the outer gingival margins of the amalgam and compomer restorations, respectively. After 24 months in service, these defects had not progressed. The secondary caries detected in 1 compomer restoration by clinical examination was also observed by the bite-wing radiographs.

SEM evaluation

Figures 1 and 2 show representative images from amalgam and compomer restorations after 12 and 24 months of clinical service. Under SEM observation, amalgam restorations demonstrated marginal microfractures of the material, lead-

ing to marginal ditching as the most frequent finding. Furthermore, progressive amalgam deterioration over time led to loss of anatomic form (Figure 1). The compomer restorations exhibited generalized wear of the material with sequential loss of anatomic form and exposure of the cavity walls along the occlusal margins (Figure 2). No evidence of marginal microfractures was determined. Despite the loss in marginal integrity, no marginal gaps were observed.

Discussion

The present study investigated differences in the clinical performance between the compomer F2000 and Dispersalloy amalgam restorations in primary molars. The split-mouth design followed in this study limits the patient-effect, and the 2 groups of restorations are more comparable. Additionally, although the adhesive type of cavities are suggested for the compomers, conservative cavities were used in the present study, as suggested by project Tapp,¹⁶ to ensure a more accurate comparison of the clinical performance between the experimental (compomer) and control materials (amalgam). Finally, this is the first study to investigate

the clinical performance of the compomer F2000 in Class II restorations of primary molars.

The results of the present investigation showed that the failure rate of the restorations as measured by retention, bulk fracture, and development of secondary caries was very low (Table 2). Other studies found that, when other compomer materials such as Dyract were used, the failure rate ranged from 4%¹⁵ to 22%.⁵ The high retention rate found in this study for both materials tested may be attributed to the mechanical retention provided by the conservative preparations used and to the bonding efficiency of the self-etching adhesive agent Clicker, which accompanies the compomer F2000. It has been reported that this agent provides a high quality of enamel etching and formation of a homogenous, continuous, and uniformly distributed hybrid layer with dentin.¹⁸

No bulk fracture was found in any of the restorative materials tested. This finding implies that the fracture resistance was the same for amalgam and compomer F2000 restorations. In a clinical study⁸ conducted under similar experimental conditions using Dyract, bulk fracture occurred at 3% of the restorations. Comparing this finding with the results of the present investigation, it may be suggested that the clinical performance of compomer F2000 regarding the fracture rate is better than that of Dyract material.

With respect to the development of dental caries, no statistically significant differences were found between the amalgam and compomer F2000 restorations. In fact, dental caries did not develop around amalgam restorations, while the caries rate for the compomer was 1.7% (Table 2). Other studies reported that dental caries occurred at a rate of 3% to 9% around amalgam restorations,^{9,18} while the corresponding values for other compomer materials ranged from 5% to 6%.^{5,8,11}

Recurrent caries is mostly associated with the existence of marginal and interfacial microgaps.²⁰ The absence of gaps detected by the SEM observations implies sufficient adaptation of F2000 along the gingival walls, which resulted in low incidence of recurrent caries. In addition, although 4 compomer restorations exhibited porous formation at the outer cervical margin at baseline, new cervical defects were not revealed by bite-wing radiographs in any of the restorations up to 24 months. This finding may show that the interfacial adaptation of the compomer F2000 to the cavity walls withstands satisfactorily the loading and the degradation subjected to this material. Finally, other possible factors which contributed to the low frequency of secondary caries are the preventive program applied to the children, fluoride release by the compomer F2000,²¹ and experience of the 2 pediatric dentists who placed the restorations.

Statistically significant differences in the marginal adaptation were found between amalgam and compomer F2000 restorations at 12-, 18-, and 24-month examinations. This finding implies that, as the lifetime of the restoration increases, the wear of the compomer is greater than that of the amalgam, resulting in inferior marginal

adaptation. It should be pointed out, however, that amalgam restorations maintained better marginal adaptation, but this criterion was clinically acceptable also for the compomer restorations.

An interesting observation was that a higher number of amalgam restorations was rated as Bravo at 6 months than at 12 months (Table 3) regarding the same criterion. This finding can be explained mainly by the presence of amalgam microfractures during the first examination period, while the improvement of the marginal adaptation at the 12-month examination should be attributed to the smoothing effect on the sharp margins of the restorations of the enamel wear occurring at the occlusal surface of primary teeth. With respect to compomer F2000, a continuous increase of the number of restorations rated as Bravo in marginal adaptation was recorded over the period of the study. It is likely that the compomer F2000 wear exceeds the tooth wear, resulting in deterioration of the marginal adaptation. In another study conducted under similar experimental conditions using Dyract, the pattern of marginal adaptation loss was similar and Bravo rates occurred at a similar rate.⁸

The performance of the restorations with respect to surface texture and contact area was clinically acceptable for both materials over the period of the study, although a statistically significant higher number of amalgam restorations showed deterioration in the surface texture at the 6- and 12-month examinations.

Furthermore, statistically significant differences in the anatomic form were found between amalgam and compomer F2000 restorations at the 18- and 24-month examinations. A higher number of compomer F2000 restorations were rated as Bravo. Again, this finding implies that, as the lifetime of the restoration increases, the wear of the compomer is greater than that of the amalgam, resulting in inferior anatomic form. It is likely that the material fatigue during the first year of oral function of the restoration accelerates the wear of the compomer, consequently deteriorating anatomic form after the first year. Loss of anatomic form after 24 months (46%) in this study was comparable with that recorded in another study (39% Bravo),⁸ applying the same cavity design, but using another compomer material, Dyract. Loss of anatomic form, however, was greater than in other studies (1-15%) that applied more conservative cavity designs of the adhesive type and using other compomer materials such as Dyract⁵ and Compoglass.¹¹

A statistically significant increase in the number of compomer F2000 restorations showing marginal staining was found between the 12- and 24-month examinations. This finding can be attributed to the increased number of compomer F2000 restorations with exposed enamel margins due to the generalized wear of the material at the occlusal surfaces. Finally, the cervical defects detected by bite-wing radiographs should be attributed to material placement technique. In the present study, the operator factor accounts for the overhangs observed in amalgam restorations, while the inclusions of air bubbles in the

compomer due to the material viscosity can explain the formation of pores.

It should be mentioned that the data recorded are based on qualitative evaluation of the restorations by 3 observers using clinical criteria. Although the examiners are experienced pediatric dentists, the subjective assessment may be a limitation of this study, as it occurs in all clinical trials. Restorations were evaluated up to 24 months. Longer evaluation periods, however, are needed to define the long-term clinical performance of the materials tested. Another limitation of this study may be that there was no caries risk assessment of the patients during the study, and this might have influenced the occurrence of secondary caries. However, since both of the restorative materials tested were placed in each patient, their clinical performance was assessed under the same oral conditions.

The results of the present investigation showed that the compomer F2000 and amalgam Dispersalloy in Class II restorations of primary molars do not differ significantly in the retention, bulk fracture, secondary caries, surface texture, and contact area. Meanwhile, the compomer presents significant deterioration, rated as Bravo, in marginal adaptation and anatomic form over a period of 2 years.

Conclusions

On the basis of the results of this study, it can be concluded that the use of compomer F2000 in Class II restorations in primary molars—although it presents a significantly higher number of restorations rated as Bravo regarding the marginal adaptation and anatomic form vs the amalgam—does not increase the risks of developing secondary caries and failure of the restorations over a period of 2 years.

Acknowledgments

This study was partially supported by 3M ESPE.

References

1. Abdalla AI, Alhadainy HA, García-Godoy F. Clinical evaluation of glass ionomers and compomers in Class V carious lesions. *Am J Dent.* 1997;10:18-20.
2. García-Godoy F. Resin based composites and compomers in primary molars. *Dent Clin North Am.* 2000;44:541-569.
3. Burke FG, Fleming GJ, Owen FJ, Watson DJ. Materials for restoration of primary teeth: Glass ionomer derivatives and compomers. *Dent Update.* 2002;29:10-14,16-17.
4. Peters TCRB, Roeters JJM, Frankenmolen FWA. Clinical evaluation of Dyract in primary molars: One-year results. *Am J Dent.* 1996;9:83-87.
5. Anderson-Wenckert IE, Folkesson UH, Van Dijken JWV. Durability of a polyacid-modified composite resin (compomer) in primary molars. A multicenter study. *Acta Odontol Scand.* 1997;55:255-260.
6. Hse KM, Wei SH. Clinical evaluation of compomer in primary teeth: One-year results. *J Am Dent Assoc.* 1997;128:1088-1096.

7. Roeters J, Frankenmolen F, Burgersdijk R, Peters T. Clinical evaluation of Dyract in primary molars: Three-year results. *Am J Dent.* 1998;11:143-148.
8. Papagiannoulis L, Kakaboura A, Pantaleon F, Kavvadia K. Clinical evaluation of a polyacid-modified resin composite (compomer) in Class II restorations of primary teeth: A two-year follow up study. *Pediatr Dent.* 1999;21:231-234.
9. Marks LAM, Weerheijm KL, Van Amerongen WE, Groen HJ, Martens LC. Dyract vs Tytin Class II restorations in primary molars, 36 months evaluation. *Caries Res.* 1999;33:387-392.
10. Wellbury RR, Shaw AJ, Murray JJ, Gordan PH, McCabe JF. Clinical evaluation of paired compomer and glass ionomer restorations in primary molars: Final results after 42 months. *Br Dent J.* 2000;189:93-97.
11. Attin T, Opatowski A, Meyer C, Zingg-Meyer B, Monting J. Class II restorations with a polyacid-modified composite resin in primary molars placed in a dental practice: Results of a two-year clinical evaluation. *Oper Dent.* 2000;25:259-264.
12. Marks LAM, Van Amerongen WE, Borgmeijer P, Groen HJ, Martens LC. Ketac molar vs Dyract class II restorations in primary molars: 12-month clinical results. *J Dent Child.* 2000;22:37-40.
13. Attin T, Opatowski A, Meyer C, Zingg-Meyer B, Buchalla W, Monting J. Three-year follow up assessment of Class II restorations in primary molars with a polyacid-modified composite resin and a hybrid composite. *Am J Dent.* 2001;14:148-152.
14. Gross L, Griffen A, Cassamassimo P. Compomers as Class II restorations in primary molars. *Pediatr Dent.* 2001;23 24-27.
15. Duggal MS, Toumba KJ, Sharma NK. Clinical performance of a compomer and amalgam for the interproximal restoration of primary molars: A 24-month evaluation. *Br Dent J.* 2002;193:339-342.
16. Houpt M. Project TAPP, Task Analysis of Procedures in Pedodontics, United States Public Health Service Final Report. (litho), 1975.
17. Ryge G. Clinical criteria. *Int Dent J.* 1980;30:347-358.
18. Breschi L, Gobbi P, Falconi M, Ciavarelli L, Teti G, Mazzati G. Evaluation of the F2000 bonding procedure: A high resolution SEM study. *J Dent.* 2001;29:499-507.
19. Muller U, Kiebassa A, Schulle-Monting J, Hellwig E. Fluoride release from light-curing restorative materials. *Am J Dent.* 2000;13:301-304.
20. Barr-Agholme M, Odén A, Dahllöf G, Modeér T. A two-year clinical study of light-cured composite and amalgam restorations in primary molars. *Dent Mater.* 1991;7:230-233.
21. Ozer L, Thylstrup A. What is known about caries in relation to restorations as a reason for replacement? A review. *Adv Dent Res.* 1995;9:394-402.