



# The Complete Endodontic Obturation of an Avulsed Immature Permanent Incisor With Mineral Trioxide Aggregate: A Case Report

Jeffrey Karp DMD, MS<sup>1</sup> Jennifer Bryk DDS, MS<sup>2</sup> Eric Menke DDS MS<sup>3</sup> Dennis McTigue DDS, MS<sup>4</sup>

## Abstract

The use of mineral trioxide aggregate (MTA) for complete endodontic obturation of an immature maxillary central incisor is reported. The injured tooth of a 9-year-old male was avulsed secondary to a sports-related traumatic event. Early attempts at pulpal revascularization of the replanted tooth proved unsuccessful, as evidenced by radiographic signs of external inflammatory root resorption in the middle to cervical thirds of the root. Calcium hydroxide apexification over a 1-year period promoted cessation of the resorptive process, but was unable to adequately form an apical root canal barrier. Due to the extent of external resorption and the lack of an apical stop, a novel endodontic treatment using mineral trioxide aggregate was utilized. At 865 days post-injury, the tooth remained asymptomatic with clinical and radiographic evidence of periodontal health. (*Pediatr Dent* 2006;28:273-278)

**KEYWORDS:** MINERAL TRIOXIDE AGGREGATE, AVULSION, APEXIFICATION, IMMATURE TOOTH, DENTAL TRAUMA

Received October 5, 2005 Revision Accepted January 17, 2006

Management of dental trauma in the pediatric population requires not only emergent surgical care but also a structured, long-term follow-up regimen. Avulsion injuries or a complete disarticulation of the tooth from the surrounding alveolar socket are particularly complex to manage in patients with immature teeth. Tooth avulsions encompass structural and cellular damage to the tooth and its pulpal blood supply and innervation, the periodontal ligament cells, and the alveolar bone comprising the tooth socket. Emergent management of avulsions is based on the rapid return of the disarticulated tooth to its respective socket, nonrigid splinting of the tooth to nontraumatized adjacent teeth, and antimicrobial therapy for prevention of infection and prolonged healing.<sup>1-5</sup> Once the avulsed tooth is replanted and stabilized for a 7- to 14-day period, an assessment of pulp status must be recorded.<sup>6</sup>

The most devastating early complication of tooth avulsion is external inflammatory root resorption. This resorptive process is exacerbated by necrotic pulpal tissue. After avulsion of mature teeth with closed apices, prophylactic pulpectomy is recommended by the American

Association of Endodontists and the International Association of Dental Traumatology to prevent root destruction. Avulsed immature teeth with thin root dentinal walls and incomplete apices, however, require different management strategies. Pulpal revascularization has been shown to occur subsequent to avulsive injuries in immature teeth if the teeth are replanted after a short extraoral period.<sup>7,8</sup> Teeth receiving pulpectomy prior to complete root development remain immature, causing difficulties in the completion of endodontic therapy, restoration of the coronal anatomy, and long-term periodontal stability of the tooth. Therefore, pulpectomy of these teeth is not recommended until clinical or radiographic signs of tooth pathology (ie, necrosis, inflammatory root resorption, swelling, pain) are evident.

The necrosis of immature avulsed teeth leaves the root apex open and blunderbuss in structure. Conventional root canal therapy is not feasible, due to the inadequacy of the apical stop. Traditionally, management of the immature apex utilizes calcium hydroxide powder to encourage an apical barrier through the process of apexification. Although apexification has been shown to be effective, this therapeutic regimen requires long-term management with periodic replacement of the calcium hydroxide filling. Studies have shown that prolonged calcium hydroxide apexification structurally weakens the tooth, making it more susceptible to root fracture.<sup>9</sup> Recently, a new material—mineral trioxide aggregate (ProRoot MTA, tooth-colored formula, Dentsply, Tulsa, Okla) has been advocated for creation of an apical barrier in these immature teeth in one treatment session.<sup>10-12</sup>

<sup>1</sup>Dr. Karp is assistant professor, Division of Pediatric Dentistry, Eastman Department of Dentistry, University of Rochester School of Medicine and Dentistry, Rochester, NY; <sup>2</sup>Dr. Bryk is a pediatric dentist in private practice, Aurora, Ohio; <sup>3</sup>Dr. Menke is an endodontist in private practice, Worthington, Ohio; and <sup>4</sup>Dr. McTigue is professor, Section of Pediatric Dentistry, College of Dentistry, The Ohio State University, Columbus, Ohio.  
Correspond with Dr. Karp at [jeff\\_karp@urmc.rochester.edu](mailto:jeff_karp@urmc.rochester.edu)

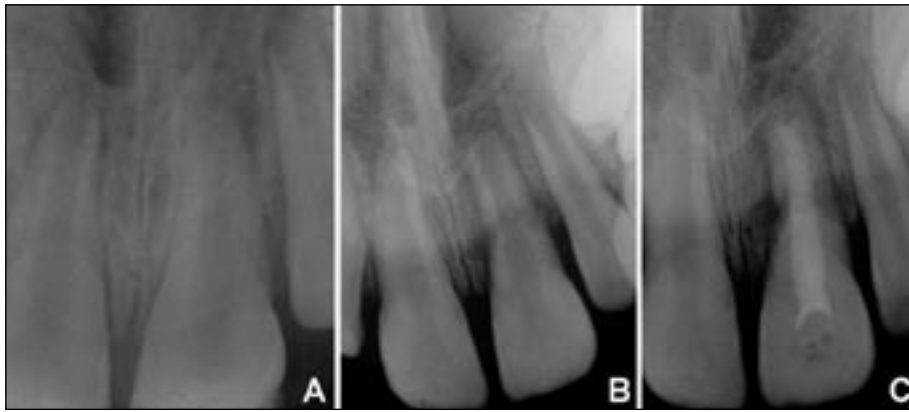

Figure 1a. Left maxillary central incisor replanted after an avulsion injury and stabilized with a fishing line splint. This periapical radiograph was taken 1½ hours after the injury was sustained.

Figure 1b. External inflammatory root resorption involving the middle to cervical thirds of the root at 47 days post-injury.

Figure 1c. At 75 days post-injury, continued external inflammatory resorption was seen despite pulpal extirpation and initiation of apexification with calcium and barium hydroxide paste 28 days earlier.

To date, mineral trioxide aggregate (MTA) has only been used to create an apical plug prior to final obturation with laterally condensed gutta-percha, thermoplasticized gutta-percha, or composite resin.

The purpose of this paper was to report the use of mineral trioxide aggregate for complete endodontic obturation.

### Case description

A 9-year-old male with no reported medical health problems and a current list of immunizations presented to the Emergency Department of the Columbus Children's Hospital in Columbus, Ohio. The patient had suffered several dental injuries subsequent to being struck in the mouth at close range by a hit golf ball. The clinical examination revealed no detectable neurologic or craniofacial dysfunction. No fractures of the maxillofacial complex were noted. Intraorally, superficial lacerations were present in the maxillary attached gingiva around the left central incisor. The lacerations were free of debris and well approximated. A stable, reproducible occlusion was present. The parents reported that the left central incisor had been avulsed intact at the time of the injury. The tooth was placed in water for 10 minutes, followed by immersion in cold milk for 10 minutes, before being returned to the socket by the family.

The patient presented to the Emergency Department with the tooth replanted and held in place by his occlusion. A periapical film taken of the maxillary anterior sextant displayed immature incisors with open apices. After local anesthesia was obtained, the left central incisor was properly repositioned and a 50-lb monofilament fishing line splint was stabilized by composite resin (TPH, Caulk Dentsply, Milford, Del). (Figure 1a). Penicillin V and a 0.12% chlorhexidine gluconate mouthrinse were prescribed. The patient was scheduled for a follow-up visit at the Department of Dentistry, Columbus Children's Hos-

pital, Columbus, Ohio, for splint removal and further evaluation.

At 12 days post-injury, the patient was re-evaluated clinically and radiographically. The left central incisor was stable with good gingival healing and physiologic mobility. The maxillary incisors revealed a normal response to percussion testing, and the periapical film displayed no evidence of pathology. Being an immature tooth with a chance of revascularization, sustained vitality, and continued development of root length and thickness, pulp therapy was deferred for the left central incisor due to a lack of clinical or radiographic evidence of pathology. The splint was removed, and the patient was reappointed for an additional fol-

low-up visit in 1 month.

The patient returned to the dental clinic 47 days post-injury and reported no history of pain or symptoms. A clinical examination revealed that the maxillary central incisors maintained normal color, mobility, and response to palpation and percussion. A periapical radiograph revealed external inflammatory root resorption encompassing the root structure of the middle to cervical thirds of the left central incisor. (Figure 1b) This radiographic finding refuted the potential for revascularization and necessitated pulp extirpation. The apexification process was carried out under local anesthesia using a 3:1 ratio of calcium hydroxide powder (Henry Schein Inc, Melville, NY) and barium hydroxide powder (Mallinckrodt, Inc, Science Products Division, Paris, Ky) by weight in a 2% lidocaine with 1:100,000 epinephrine (Sterling Winthrop Inc, New York, NY) vehicle to form a viscous paste.

The mixture was introduced to the root canal space using a 25-mm lentulo spiral (Dentsply Maillefer, Johnson City, Tenn) attachment in a slow-speed handpiece. The paste was condensed from the blunderbuss root apex to the tooth's cemento-enamel junction. A dry cotton pellet was placed in the coronal pulp chamber, and the endodontic access was closed with a flowable composite resin (Revolution Formula 2, Kerr Corporation, Orange, Calif) following the manufacturer's instructions. The child was reappointed for further evaluation in 1 month.

The patients returned asymptomatic once again 75 days post-injury. Clinical examination continued to reveal maxillary central incisors with normal color, mobility, and response to palpation and percussion. Radiographic evaluation of the left central incisor revealed further external resorption of the middle to cervical root structure. (Figure 1c) In 2 dimensions, the areas of resorption appeared to encroach upon the root canal space. The left central inci-

tor was given a hopeless prognosis, the family was informed, and a conversation outlining a long-term treatment planning and follow-up regimen was undertaken.

At 166 days post-injury, the asymptomatic maxillary central incisors remained clinically normal in response to palpation and percussion, mobility, and color. A periapical radiograph was taken and found to display cessation of the resorptive process. (Figure 2a) Although the root surface defects remained, a well-defined periodontal ligament space was evident along with osseous regeneration in the areas of previous inflammation. The family was notified of the radiographic signs of periodontal healing, and a mutual decision was made to continue with the apexification process. The calcium hydroxide paste was changed, and the patient was reappointed for re-evaluation in 3 months.

At 257 days post-injury, the patient returned asymptomatic for continuation of the apexification process. A periapical radiograph revealed that an apical stop had not yet formed. (Figure 2b) The calcium hydroxide interim filling was changed for the last time. The patient was reappointed for a 3-month follow-up.

At 347 days post-injury, the patient reported no present pain or problems. A thorough clinical and radiographic examination revealed no evidence of replacement resorption or periodontal pathology. Notably, the maxillary left lateral incisor had undergone pulp canal obliteration radiographically, although no clinical evidence was present. The apex of the avulsed central incisor remained blunderbuss (Figure 2c). With the family's consent, the patient was referred to an endodontist for evaluation and obturation of the tooth.

At 422 days post-injury, the referred endodontist recommended complete obturation of the tooth from the apex to the cemento-enamel junction using MTA. A local anesthetic was administered and rubber dam isolation was obtained. The temporary restoration on the lingual surface of the left central incisor was removed and access was gained to the canal. The existing calcium hydroxide paste was removed with K-files (SybronEndo, Glendale, Calif) and multiple rinses of sodium hypochlorite. The canal was instrumented to a size 100 K-file at a working length of 22.5 mm. The canal was dried and obturated with MTA. The MTA was mixed with sterile water following the manufacturer's instructions. The MTA was placed in the canal with a large amalgam carrier and condensed with a 9/11 double-ended plugger. A stopper was placed on the plugger at 22.5 mm.

Condensation was checked radiographically and the canal was filled slightly below the cemento-enamel junction (Figure 3a). A damp cotton pellet was placed in the pulp chamber overlying the condensed MTA and Cavit G (3M

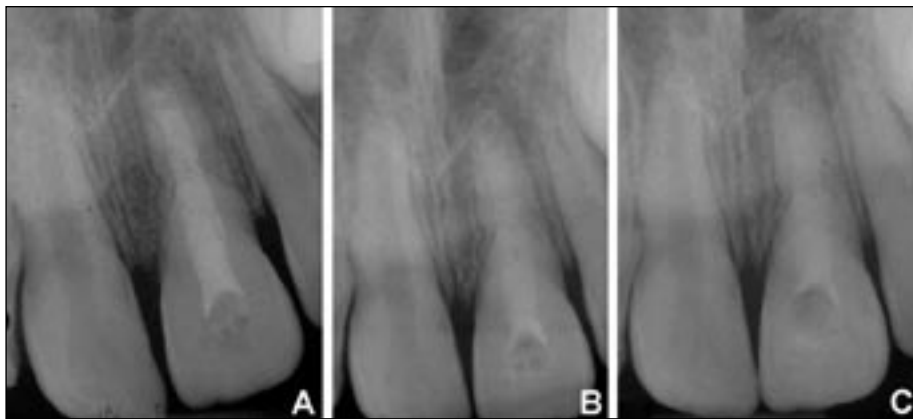


Figure 2a. Cessation of root resorption and return of the periodontal ligament space at 166 days post-injury.

Figure 2b. Calcium hydroxide apexification at 257 days post-injury.

Figure 2c. Lack of an apical stop at 347 days post-injury.

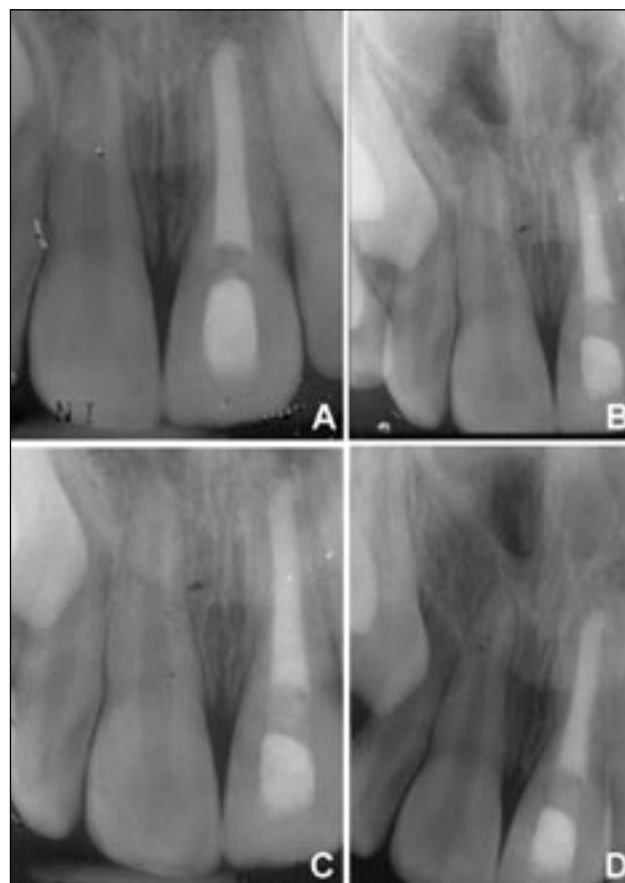


Figure 3a. Complete endodontic obturation with MTA 422 days post-injury.

Figure 3b. MTA follow up after 5 months.

Figure 3c. MTA follow up at 8 months, 625 post-injury.

Figure 3d. MTA follow-up at 16 months, 865 post-injury.

ESPE, Norristown, Pa) was placed in the access opening to close the tooth. The patient was referred back to the Columbus Children's Hospital for final restoration of the lingual access with composite resin (TPH, Caulk Dentsply,

Milford, Del) after a 2-week period to allow for complete setting of the MTA.

The child continued to receive routine preventive dental care from his private general dentist. Five-, 8-, 12-, and 16-month (Figure 3b, 3c, 3d) clinical and radiographic re-evaluations of the MTA obturation were completed by the endodontist. At the time this case report was written, the patient had avoided additional dental trauma and remained symptom free. At 865 days post-injury, the left maxillary central incisor displayed normal mobility with no clinical or radiographic evidence of replacement resorption or pathology.

## Discussion

MTA has gained clinical popularity since its approval by the Food and Drug Administration in 1998 for human usage.<sup>13</sup> MTA is a powder consisting mainly of lime, silica, and bismuth oxides that transitions from a gel of pH 12.5 to a rigid mass when exposed to moisture and allowed to set for approximately 4 hours.<sup>14-16</sup> MTA has been advocated as a root-end-filling material for endodontic therapy.<sup>15,17</sup> Several studies have reported that MTA displays minimal cytotoxicity when compared to other retrofilling materials<sup>18,19</sup> with minor degrees of inflammation,<sup>20</sup> promotion of hard tissue induction in the periodontal tissues,<sup>17,20-22</sup> stimulation of dentin bridge formation adjacent to the dental pulp,<sup>15,23</sup> and superior sealing capabilities through enhanced marginal adaptation.<sup>24-27</sup> These properties have extended the use of MTA for:

1. repair of root canal perforations;
2. direct pulp capping;
3. barriers during internal bleaching of root canal treated teeth; and
4. apexification.<sup>10-12,28</sup>

Apexification using MTA as an apical plug usually requires obturation of the radicular pulp with laterally condensed gutta-percha, thermoplasticized gutta-percha, or composite resin. These procedures are then followed by restoration of the missing coronal tooth structure with the appropriate restorative material. Although appropriate for obturation of the root canal system, these aforementioned materials display minimal beneficial effects on the periodontal complex.

In this case, the extensive nature of the external root resorption compromised the structural integrity of the middle and into the cervical root. MTA's hard tissue inductive effects were believed to be useful in not only the tooth's apical regions, but also in the areas of previous external resorption. Previous studies have suggested that MTA displays a high level of marginal adaptation and reduced degree of bacterial microleakage.<sup>24,27</sup> Several apexification procedures using calcium hydroxide paste were believed to have further weakened the remaining root structure. Andreasen et al demonstrated that apexification therapy for 1 year with calcium hydroxide reduces the fracture resistance of the immature pulpectomized tooth by 50%.<sup>9</sup> Additional studies have suggested the use of composite

resin as a coronal root canal obturant in teeth susceptible to cervical root fractures.<sup>29-32</sup> Composite resin was found to significantly increase the root fracture resistance of immature pulpectomized teeth *in vitro*.<sup>29,30</sup>

In this case, the health of the periodontal complex and asepsis of the root canal system were believed to be the highest priority. The amount of root destruction mediated by the inflammatory process conceivably perforated the barrier that normally exists between the periodontal complex and the root canal system. The introduction of oral bacteria into the pulpal system through the gingival sulcus and periodontal ligament are more likely to occur in root perforations in the middle to cervical thirds of the root.<sup>33</sup> Composite resin as a root canal obturant does not display beneficial inductive effects on the periodontal complex and, in fact, has been suggested to be cytotoxic to periodontal ligament cells.<sup>34</sup> Therefore, the authors found that complete MTA obturation was indicated vs composite resin because the importance of periodontal complex healing and maintenance of an aseptic root canal system outweighed the complications of cervical root fracture.

Long-term maintenance of a nonpathologic root, despite cervical root fracture or replacement resorption, remains the greatest priority in this case. Contemporary literature has yet to describe the feasibility of discretely removing set MTA from the complete root canal system. As MTA is classically used for forming an apical plug in immature teeth,<sup>15</sup> the authors speculate that infection of these teeth would probably be managed by apicoectomy of the MTA-containing root structure and endodontic retreatment of the tooth.

In this case report, the authors believe the chance of infection after 865 days to be minimal. Tooth extraction, however, would be the probable treatment if infection develops. In most cases of cervical root fracture, post and core placement would be indicated to restore coronal tooth structure needed for retention of an esthetic crown. In this case, the previously discussed rationale for obturating the tooth with MTA and the increased chance of root perforation or vertical root fracture makes MTA removal and post-placement an ill-advised procedure. Decoronation is reported to maintain optimal alveolar bone height and width for future implant placement.<sup>35-37</sup> As such, the occurrence of cervical root fracture or replacement resorption with associated infraocclusion in this case would be managed by decoronation and interim placement of either an acrylic removable partial denture or a resin-bonded bridge.<sup>38</sup> This treatment plan would allow the patient to maintain optimal esthetics and function until growth cessation occurs and implant placement is indicated.

Teeth with guarded or hopeless prognoses secondary to dental trauma utilize the full armamentarium of the pediatric specialist. Practitioners treating these injuries must consider the social, emotional, psychological, and financial characteristics of their patients and family members when making treatment recommendations. Extraction of these teeth always remains an option, but the practitioner must consider the patient's esthetic, functional, and future restorative needs.

In this case report, the patient and family remained highly motivated and compliant with the treatment recommendations and follow-up regimen set forth by the authors. Routine evaluation will continue with this patient to ensure that long-term sequelae—such as replacement resorption, cervical root fracture, or infection—are managed appropriately. The authors were satisfied with the patient's clinical outcome thus far, as the restorative process proved to be atraumatic while allowing for full maintenance of oral function and esthetics.

## References

- Andreasen JO. Effect of extra-alveolar period and storage media upon periodontal and pulpal healing after replantation of mature permanent incisors in monkeys. *Int J Oral Surg* 1981;10:43-53.
- Hammarstrom L, Blomlof L, Feiglin B, Andersson L, Lindskog S. Replantation of teeth and antibiotic treatment. *Endod Dent Traumatol* 1986;2:51-57.
- Sae-Lim V, Wang CY, Trope M. Effect of systemic tetracycline and amoxicillin on inflammatory root resorption of replanted dogs' teeth. *Endod Dent Traumatol* 1998;14:216-220.
- Keller DC, Carano A. Tetracycline effect on osteoclastic and osteoblastic activity. *Gen Dent* 1995;43:60-63.
- Oikarinen K, Andreasen JO, Andreasen FM. Rigidity of various fixation methods used as dental splints. *Endod Dent Traumatol* 1992;8:113-119.
- Ram D, Cohenca N. Therapeutic protocols for avulsed permanent teeth: Review and clinical update. *Pediatr Dent* 2004;26:251-255.
- Andreasen JO, Borum MK, Jacobsen HL, Andreasen FM. Replantation of 400 avulsed permanent incisors. 2. Factors related to pulpal healing. *Endod Dent Traumatol* 1995;11:59-68.
- Strobl H, Gojer G, Norer B, Emshoff R. Assessing revascularization of avulsed permanent maxillary incisors by laser Doppler flowmetry. *J Am Dent Assoc* 2003;134:1597-1603.
- Andreasen JO, Farik B, Munksgaard EC. Long-term calcium hydroxide as a root canal dressing may increase risk of root fracture. *Dent Traumatol* 2002;18:134-137.
- Giuliani V, Baccetti T, Pace R, Pagavino G. The use of MTA in teeth with necrotic pulps and open apices. *Dent Traumatol* 2002;18:217-221.
- Hayashi M, Shimizu A, Ebisu S. MTA for obturation of mandibular central incisors with open apices: Case report. *J Endod* 2004;30:120-122.
- Maroto M, Barberia E, Planells P, Vera V. Treatment of a nonvital immature incisor with mineral trioxide aggregate (MTA). *Dent Traumatol* 2003;19:165-169.
- Schwartz RS, Mauger M, Clement DJ, Walker WA, III. Mineral trioxide aggregate: A new material for endodontics. *J Am Dent Assoc* 1999;130:967-975.
- Asgary S, Parirokh M, Eghbal MJ, Brink F. Chemical differences between white and gray mineral trioxide aggregate. *J Endod* 2005;31:101-103.
- Torabinejad M, Chivian N. Clinical applications of mineral trioxide aggregate. *J Endod* 1999;25:197-205.
- Torabinejad M, Hong CU, McDonald F, Pitt Ford TR. Physical and chemical properties of a new root-end filling material. *J Endod* 1995;21:349-353.
- Apaydin ES, Shabahang S, Torabinejad M. Hard-tissue healing after application of fresh or set MTA as root-end-filling material. *J Endod* 2004;30:21-24.
- Keiser K, Johnson CC, Tipton DA. Cytotoxicity of mineral trioxide aggregate using human periodontal ligament fibroblasts. *J Endod* 2000;26:288-291.
- Osorio RM, Hefti A, Vertucci FJ, Shawley AL. Cytotoxicity of endodontic materials. *J Endod* 1998;24:91-96.
- Baek SH, Plenk H, Jr, Kim S. Periapical tissue responses and cementum regeneration with amalgam, SuperEBA, and MTA as root-end filling materials. *J Endod* 2005;31:444-449.
- Koh ET, McDonald F, Pitt Ford TR, Torabinejad M. Cellular response to mineral trioxide aggregate. *J Endod* 1998;24:543-547.
- Yaltirik M, Ozbas H, Bilgic B, Issever H. Reactions of connective tissue to mineral trioxide aggregate and amalgam. *J Endod* 2004;30:95-99.
- Ford TR, Torabinejad M, Abedi HR, Bakland LK, Kariyawasam SP. Using mineral trioxide aggregate as a pulp-capping material. *J Am Dent Assoc* 1996;127:1491-1494.
- Al-Kahtani A, Shostad S, Schifferle R, Bhambhani S. In-vitro evaluation of microleakage of an orthograde apical plug of mineral trioxide aggregate in permanent teeth with simulated immature apices. *J Endod* 2005;31:117-119.
- Gondim E, Jr, Kim S, de Souza-Filho FJ. An investigation of microleakage from root-end fillings in ultrasonic retrograde cavities with or without finishing: a quantitative analysis. *Oral Surg Oral Med Oral Pathol Oral Radiol Endod* 2005;99:755-760.
- Shipper G, Grossman ES, Botha AJ, Cleaton-Jones PE. Marginal adaptation of mineral trioxide aggregate (MTA) compared with amalgam as a root-end filling material: A low-vacuum (LV) vs high-vacuum (HV) SEM study. *Int Endod J* 2004;37:325-336.
- Tselnik M, Baumgartner JC, Marshall JG. Bacterial leakage with mineral trioxide aggregate or a resin-modified glass ionomer used as a coronal barrier. *J Endod* 2004;30:782-784.
- Schmitt D, Lee J, Bogen G. Multifaceted use of Pro-Root MTA root canal repair material. *Pediatr Dent* 2001;23:326-330.
- Carvalho CA, Valera MC, Oliveira LD, Camargo CH. Structural resistance in immature teeth using root reinforcements in vitro. *Dent Traumatol* 2005;21:155-159.

30. Katebzadeh N, Dalton BC, Trope M. Strengthening immature teeth during and after apexification. *J Endod* 1998;24:256-259.
31. Rabie G, Trope M, Garcia C, Tronstad L. Strengthening and restoration of immature teeth with an acid-etch resin technique. *Endod Dent Traumatol* 1985;1:246-256.
32. Rabie G, Trope M, Tronstad L. Strengthening of immature teeth during long-term endodontic therapy. *Endod Dent Traumatol* 1986;2:43-47.
33. Main C, Mirzayan N, Shabahang S, Torabinejad M. Repair of root perforations using mineral trioxide aggregate: A long-term study. *J Endod* 2004;30:80-83.
34. Tai KW, Chang YC. Cytotoxicity evaluation of perforation repair materials on human periodontal ligament cells in vitro. *J Endod* 2000;26:395-397.
35. Filippi A, Pohl Y, von Arx T. Decoronation of an ankylosed tooth for preservation of alveolar bone prior to implant placement. *Dent Traumatol* 2001;17:93-95.
36. Malmgren B. Decoronation: How, why, and when? *J Calif Dent Assoc* 2000;28:846-854.
37. Schwartz-Arad D, Levin L, Ashkenazi M. Treatment options of untreatable traumatized anterior maxillary teeth for future use of dental implantation. *Implant Dent* 2004;13:120-128.
38. Chafaie A, Portier R. Anterior fiber-reinforced composite resin bridge: A case report. *Pediatr Dent* 2004;26:530-534.

## Abstract of the Scientific Literature



### Traumatic Injuries in Young Individuals With Cerebral Palsy

The purpose of this study was to assess the characteristics of dental trauma in individuals with cerebral palsy. The study group consisted of 68 individuals (36 boys and 32 girls) who daily visited a school dedicated for children with cerebral palsy. Their ages ranged between 7 and 21 years, with a mean age of 12.6 years. The majority (74%) required a wheelchair for mobility, 13% used a walker, and the others were able to walk with crutches or without aid. The parents were asked to complete a questionnaire regarding their child's age, gender, medical history, and dental trauma history. The teeth were evaluated clinically for evidence of past tooth injuries, enamel defects in the permanent incisors, scars on the chin, and overjet size. Thirty-nine individuals (57%) had signs of trauma to the permanent teeth. Sixty-eight teeth, mostly the maxillary central incisors, were injured. Boys were slightly less affected than girls—56% (20/36) and 59% (19/32), respectively. Fracture of enamel and dentin was the most common type of injury (62%). Chin scars were detected in 28% of the individuals, but only one had fractures of the molar (primary) teeth. The overjet ranged between -3.0 and +14 mm, but no correlation could be found between the size of the overjet and tendency to injure the teeth. Localized enamel defects were detected on the labial surface of 13 teeth in 9 individuals, probably due to luxation injuries to the primary incisors. The prevalence of dental injuries in a group of cerebral palsy subjects was found to be much higher than that of healthy populations, despite the fact that cerebral palsy sufferers do not take part in sport activities as violent as healthy children do.

**Comments:** This is a good study that alerts the need for more studies dealing with traumatic injuries in special-needs populations. This study alerts caregivers to carry out a profound investigation of the events that result in dental injuries in special needs individuals and suggests methods to reduce this type of morbidity and preventive measures such as mouthguards, padding hard objects which have the potential of harming the teeth, and safe transportation of the children in wheelchairs. **FSS**

*Address correspondence to Gideon Holan, Department of Pediatric Dentistry, The Hebrew University—Hadassah School of Dental Medicine, P.O. Box 12272 Jerusalem 91120.*

**Holan G, Peretz B, Efrat J, Shapira Y. Traumatic injuries to the teeth in young individuals with cerebral palsy. *Dent Traumatol* 2005;21:65-69.**

18 references.