



## Management of a Fused Central Incisor in Association With a Macrodont Lateral Incisor: A Case Report

Seniz Karacay, DDS, PhD<sup>1</sup> Günseli Guven, DDS, PhD<sup>2</sup> Ramazan Koymen, DDS, PhD<sup>3</sup>

### Abstract

Fusion is developmental anomaly of the dental hard tissue and is defined as the joining of 2 developing tooth germs resulting in a single large tooth structure. Different treatment methods can be used according to the requirements of the situation. The purpose of this case report was to present the multidisciplinary treatment of a patient who had a permanent maxillary left central tooth fused with a supernumerary incisor and a macrodont permanent maxillary right lateral incisor. In the radiographic evaluation, it was determined that the fused tooth had 2 separate roots. The supernumerary tooth was extracted after hemisection, and endodontic treatment was performed on the remaining portion. The distal side of the macrodont lateral incisor was recontoured, and the right central incisor was reshaped with a strip crown to provide aesthetic appearance and to gain space for the alignment of teeth. Following the restoration of the incisors, orthodontic treatment was provided. (*Pediatr Dent* 2006;28:336-340)

**KEYWORDS:** FUSION, MACRODONT, GEMINATION, TWINNING, HEMISECTION, ENDODONTIC TREATMENT, ORTHODONTIC TREATMENT

*Received November 16, 2005 Revision Accepted February 17, 2006*

Teeth may be maldeveloped in shape, size, and structure during developmental stages. Fusion and gemination are developmental anomalies of the dental hard tissue. It is not yet known if fusion and gemination are part of the same developmental disturbance, or if they may be considered as pathological events leading to formation of supernumerary elements.<sup>1,2</sup>

Fusion is the embryologic union of normally discrete structures. If it occurs early, 2 developing teeth will unite to form a single tooth of almost normal size. If it occurs very late, however, one tooth almost twice the normal size will develop.<sup>3</sup> The teeth may be permanent or primary, and sometimes one of them may be a supernumerary tooth.<sup>4</sup> A fused tooth is clinically broad and shows either a bifid crown, a groove delineating 2 crowns or an incisal notch. The groove may continue onto the root if they are also conjoined, but maxillary fused teeth often show 2 roots.<sup>5</sup> Fusion may be: (1) partial (incomplete), including only the tooth crowns; or (2) total (complete), involving tooth crowns and roots.<sup>6,7</sup> Fused tooth may involve: (1) 1 pulp chamber dividing into 2 root canals; or (2) 2 independent endodontic systems.<sup>5</sup>

Gemination is an abortive attempt by a single tooth bud to divide and is due to the invagination of the developing dental organ. It occurs when 1 tooth bud attempts to split into 2, resulting in a single tooth with a bifid crown and a single root structure with an enlarged pulp canal.<sup>8,9</sup> Some authors include geminated teeth among cases of fusion in which union occurred to a supernumerary element.<sup>1,2</sup>

Knezevic et al<sup>10</sup> investigated fusion and gemination and reported the prevalence of both anomalies as less than 1%; 57% of the anomalies were fused, and 43% were geminated. From the view of location (maxillary or mandibular) or gender, similar results were determined. In relation to race, however, differences have been reported. The prevalence of fusion and gemination is lower among Caucasians.<sup>11</sup> A lower prevalence has also been reported in the permanent dentition.<sup>12</sup>

In the same dentition, geminated or fused teeth at one site may be accompanied by macrodont teeth at the other. These kinds of developmental anomalies create not only esthetic problems, but also cause malalignment and malocclusion.<sup>13</sup>

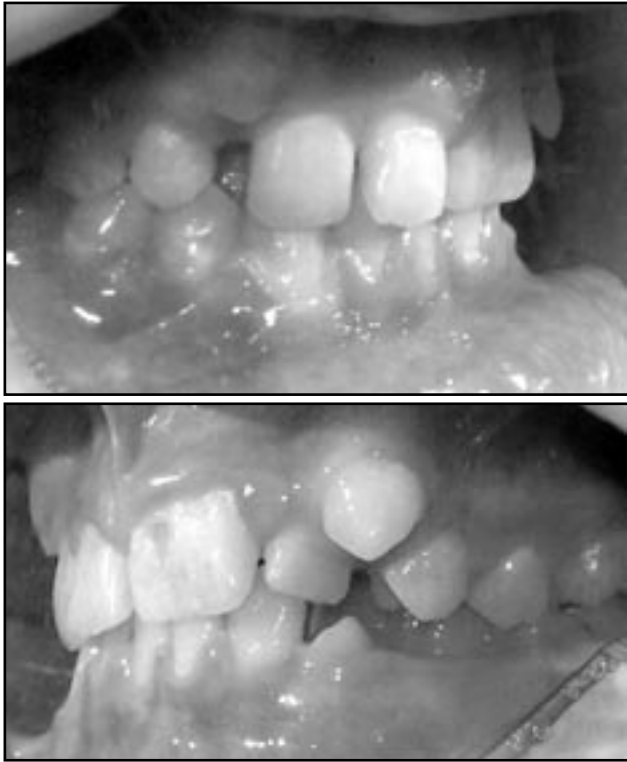Disproportionate sizes of the upper and lower teeth create interarch tooth size discrepancies. For good occlusion, the teeth must be proportional in size. An interarch tooth size discrepancy of less than 1.5 mm is rarely significant, but larger discrepancies create treatment problems. If the large upper teeth are combined with small lower teeth, an ideal occlusion cannot be achieved. Therefore, normal oc-

<sup>1</sup>Dr. Karacay is assistant professor, Department of Orthodontics,

<sup>2</sup>Dr. Guven is assistant professor, Department of Pedodontics, and

<sup>3</sup>Dr. Koymen is assistant professor, Department of Maxillofacial Surgery, all at Gulhane Military Academy Center of Dental Sciences, Ankara, Turkey.

Correspond with Dr. Karacay at senkaracay@yahoo.com



Figures 1a and 1b. Pretreatment photographs of a patient with a fused maxillary left central incisor, macrodont maxillary right lateral incisor, and crowding.

clusion is impossible in the presence of geminated, fused, or macrodont teeth.<sup>14</sup>

In the dental literature, various treatment considerations have been recommended to achieve ideal esthetic and occlusion and they usually require a multidisciplinary approach.<sup>7-9,15</sup> This case report presents the combined treatment of a patient who had severe tooth size/arch size deficiency due to tooth size abnormalities created by a fused central incisor and a macrodont lateral incisor. The treatment alternatives of fused teeth are also discussed.

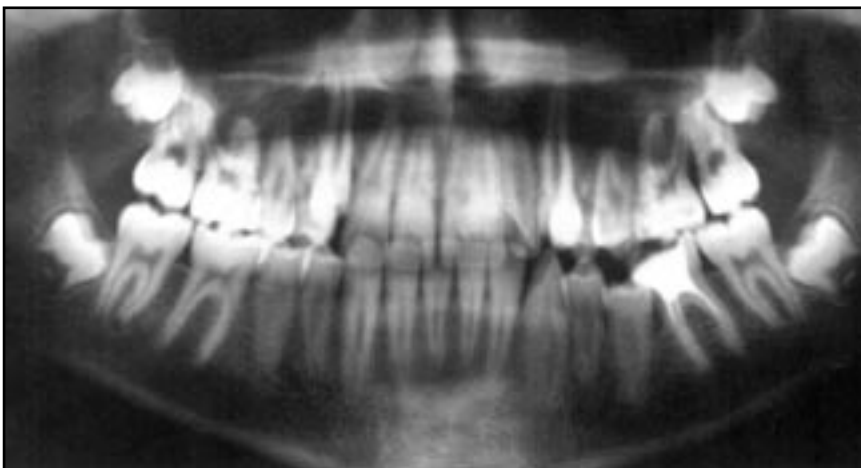


Figure 2a. Pretreatment panoramic film demonstrating a macrodont maxillary right lateral incisor and fusion of a maxillary left central incisor with a supernumerary tooth.

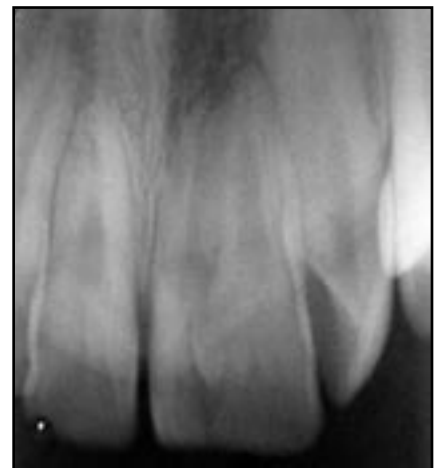

Figure 2b. Pretreatment periapical film of the central incisor fused to a supernumerary tooth.

## Case report

A 13-year-old male patient was referred to the Department of Orthodontics, Gulhane Military Academy Center of Dental Sciences, Ankara, Turkey, for the treatment of his teeth. His chief complaint was the unesthetic appearance of his anterior teeth. Intraoral examination revealed that a permanent maxillary left central incisor was fused with a supernumerary tooth. Enamel hypoplasia was also observed. The permanent maxillary right central and lateral incisors also had tooth size anomalies. The central incisor was narrow, while the lateral incisor was larger than normal. There was a diastema of 1 mm between the central incisors. Because of the space deficiency, the maxillary left lateral incisor was malaligned and slightly rotated. The maxillary left canine was in buccoversion and insufficient space was available for the eruption of this tooth (Figures 1a and 1b). Panoramic and occlusal radiographs showed that the fused tooth had a single crown with a single pulp chamber, but 2 separate roots (Figures 2a and 2b).

## Treatment plan

Hemisection and endodontic treatment of the fused maxillary left central incisor and extraction of the conjoined supernumerary tooth was planned to provide aesthetic appearance and to gain space in the maxillary arch. The patient initially refused the treatment when the surgical procedures were explained to him and his parents. A few months later, however, he consented to the proposed treatment.

### Hemisection of the fused tooth

The surgical procedure was carried out under local anesthesia. A mucoperiosteal flap was raised, and the fused tooth was separated with a diamond bur under irrigation. The tooth's mesial (supernumerary) portion was extracted (Figure 3).

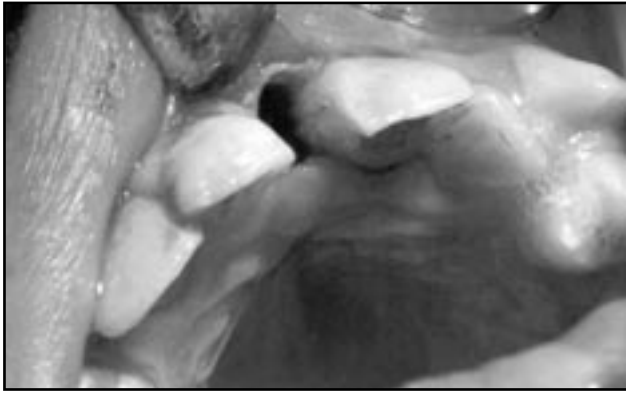


Figure 3. Hemisection and extraction of the supernumerary tooth.

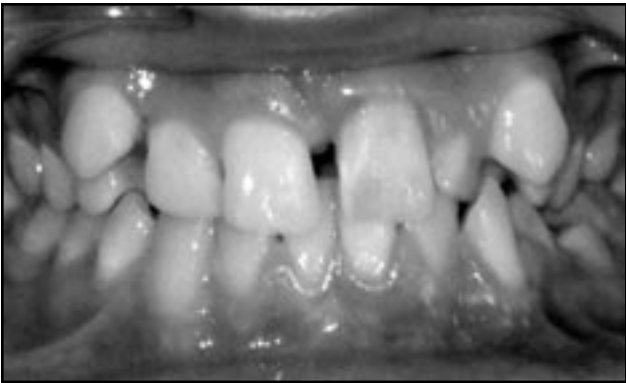

Figure 4. Maxillary teeth after surgical and restorative treatment.

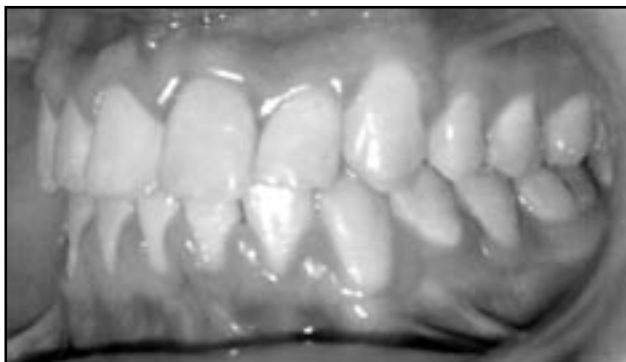
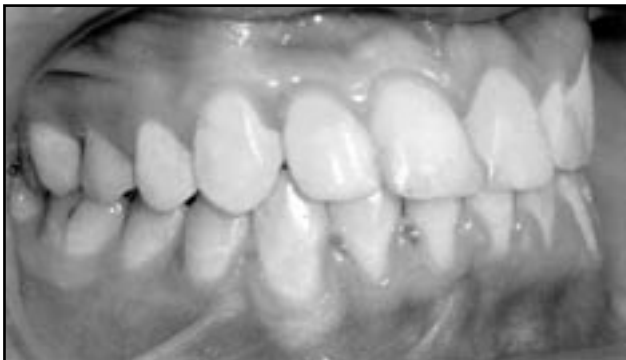
Figure 5. Appearance of the dentition following orthodontic treatment.

### Endodontic treatment of fused tooth

Endodontic treatment of the maxillary left central incisor was performed immediately following the surgical procedure. A lingual cavity was prepared, and the pulp canal was instrumented using the crown-down technique to a size 40 master apical file. The site was copiously irrigated with sodium hypochlorite solution during preparation. The canal was obturated with gutta percha points. Zinc-oxide eugenol sealer was used for cold lateral condensation. Final reconstruction was completed with a light cured composite resin.

### Reshaping of the right central and lateral incisors

Reshaping of the maxillary right incisors was performed after the surrounding periodontal tissues healed. The right central incisor was narrow, while the lateral incisor was wider than normal. The mesiodistal dimension of the maxillary right central incisor was broadened with light cured composite resin using a strip crown. The distal surface of the macrodont lateral incisor was reduced with a high-speed turbine and extra-long diamond bur to provide space for the alignment of the permanent maxillary right canine. Finally, fluoride was applied to the crown's distal surface. Figure 4 illustrates the symmetrical appearance of the central incisors prior to instituting orthodontic treatment.

### Orthodontic treatment

Following the restorative procedures, the patient had a diastema between the maxillary central incisors. His canines were in buccoversion, and the left lateral incisor was in crossbite and slightly rotated behind the hemisected central incisor.

Pretorqued Roth brackets were attached to the maxillary teeth, and a 0.016-inch nitinol arch wire was used for initial leveling of the maxillary dental arch. After the extrusion of the canines, an open coil spring was placed between the left canine and left central incisor to create space for the alignment of the rotated lateral incisor. When adequate space was obtained, a posterior mandibular bite-plate was placed to prevent the left lateral incisor from being locked behind the lower incisors. The left lateral incisor was aligned in 6 weeks. Brackets and a 0.016-inch nitinol arch wire were then attached to the mandibular teeth. Class I occlusion was attained by using intraoral elastics. Following the active orthodontic treatment, a Hawley retainer was used for stability and retention. The patient's final occlusion and improvement in his teeth's appearance is presented in Figure 5. No periapical pathology or root resorption was observed on the panoramic radiograph.

### Discussion

Abnormalities in tooth size and shape result from disturbances during the morphodifferentiation stage of development, perhaps with some carryover from the histodifferentiation stage. Occasionally, tooth buds may fuse or geminate during their development.<sup>14</sup> Clinically, it may be difficult to dif-

ferentiate between fusion and gemination, especially when a supernumerary tooth is fused with a permanent tooth. To differentiate these 2 developmental anomalies, Levitas<sup>5</sup> suggested counting the teeth present on the dental arch. He noted that fusion diminished the number of teeth, while the gemination did not. This method is not always reliable, however, because of the possible existence of supernumerary teeth or congenitally missing teeth.<sup>16</sup> Morphology and pulpal anatomy are the more valuable diagnostic criteria for distinguishing fusion from gemination.<sup>17</sup>

In the present case, the maxillary left central incisor was broad with a triangular groove on the crown's face. Radiographic evaluation revealed 2 distinct roots and 2 separate pulp chambers. Morphology and pulpal anatomy were consistent with fusion rather than gemination. The permanent maxillary left central incisor was fused with a supernumerary tooth and fusion was partial (incomplete), as only the crowns were involved.<sup>5-7,18,19</sup>

Fusion of teeth usually appears in the anterior region and causes esthetic problems, including: (1) diastema; (2) crowding; or (3) protrusion. If 2 normal teeth fuse, the resulting conjoined tooth may occupy less space than 2 single teeth. If a normal tooth fuses with a supernumerary tooth, however, severe crowding and malalignment may occur because of insufficient arch length.<sup>20-23</sup> In the present case, the central incisor was fused with a supernumerary tooth so that the resultant tooth caused crowding. Several authors have reported that in the same dentition, conjoined teeth at one site may be accompanied by macrodont at the contralateral site.<sup>13</sup> In the present case, the patient's right lateral incisor was wider than normal. The fused central incisor and the wide lateral incisor created an unesthetic appearance and severe malalignment of the upper anterior teeth.

The choice of treatment for a fused tooth should be determined by the patient's orthodontic, periodontal, esthetic, and functional requirements. Usually a multidisciplinary approach is needed due to the: (1) abnormal crown shape; (2) root formation; (3) endodontic considerations; (4) malalignment; and (5) esthetics. The most common treatment alternatives are:

1. extraction of the fused tooth;
2. separation of the conjoined tooth into 2 single teeth;
3. hemisection and extraction of one tooth half; or
4. reshaping of the crown.<sup>16,22-24</sup>

In the present case, because the fused tooth had 2 separate roots, it was surgically separated and the supernumerary tooth was extracted to gain space in the dental arch for alignment of the rotated left lateral incisor. In some previous cases treated with hemisection, the remaining tooth's vitality was maintained because there was no communication between the 2 coronal pulps.<sup>25</sup> In the present case, the fused tooth had independent radicular pulps but a single coronal pulp, thus necessitating endodontic treatment.

## References

1. Carrol MK. Fusion and gemination in alternate dentitions. *Oral Surg* 1990;69:655.
2. Gersh RP, Isler S. Bilateral connotation of primary molars: Report of case. *J Dent Child* 1973;40:39-41.
3. Shaw L. *Pediatric Dentistry*. 3<sup>rd</sup> ed. Spain, Pa: Mosby-Wolfe; 1995:97, 126, 149.
4. Neves AA, Neves LA, Farinhas JA. Bilateral connotation of permanent mandibular incisors: A case report. *Int J Paediatr Dent* 2002;12:61-65.
5. Levitas TC. Gemination, fusion, twinning, and concrescence. *J Dent Child* 1965;32:93-100.
6. Hernandez-Guisado JM, Torres-Lagares D, Infante-Cossio P, Gutierrez-Perrez JL. Dental gemination: Report of a case. *Med Oral* 2002;7:231-237.
7. Budd CS, Reid DE, Kulild JC, Weller RN. Endodontic treatment of an unusual case of a fusion. *J Endod* 1992;18:133-140.
8. Terezhalmay GT, Riley CK. Gemination/fusion. *Quintessence Int* 1999;30:437.
9. Aryanpour S, Bercy P, Van Nieuwenhuysen JP. Endodontic and periodontal treatment of a geminated mandibular first premolar. *Int Endod J* 2002;35:209-214.
10. Knezevic A, Travan S, Tarle Z, et al. Double tooth. *Coll Antropol* 2002;26:667-672.
11. Aguilo L, Gandia JL, Ciprian R, Catala M. Primary double teeth. A retrospective clinical study of their morphological characteristics and associated anomalies. *Int J Paediatr Dent* 1999;9:175-183.
12. Pilo R, Kaffe I, Amir E, Sarnat H. Diagnosis of developmental dental anomalies using panoramic radiographs. *J Dent Child* 1987;54:267-272.
13. De Oliveria Mattos-Graner R, Rottani RMP, Duarte Gavião MG. Anomalies of tooth form and number in the permanent dentition. *J Dent Child* 1997;64:298-302.
14. Proffit WR, Fields HW Jr. Diagnosis and treatment planning. In: *Contemporary Orthodontics*. 3<sup>rd</sup> ed. St. Louis, Mo: Mosby Inc; 2000:145-195.
15. Karacay S, Gurton AU, Olmez H, Koymen G. Multidisciplinary treatment of twinned teeth: Case report. *J Dent Child* 2004;71:80-86.
16. Brook AH, Winter GB. Double teeth. A retrospective study of geminated and fused teeth in children. *Br Dent J* 1970;129:123-130.
17. Schuur AHB, van Loveren C. Double teeth: Review of the literature. 2000;67:313-325.
18. De Siqueira VC, Braga TL, Martins MA, Raitz R, Martins MD. Dental fusion and dens evaginatus in the permanent dentition: Literature review and clinical case report with conservative treatment. *J Dent Child* 2004;71:69-72.
19. Oncag O, Candan U, Arikan F. Comprehensive therapy of a fusion between a mandibular incisor and a supernumerary tooth. *Int Dent J* 2005;55:213-216.

20. Hashim HA. Orthodontic treatment of fused and geminated central incisors: A case report. *J Contemp Dent Pract* 2004;5:136-144.
21. Tannenbaum KA, Alling EE. Case reports of gemination and twinning. *Oral Surg* 1963;16: 883-887.
22. Weiss JK. The double tooth. *J Clin Orthod* 1980;14:780-787.
23. Melnik AK. Orthodontic movement of a supplemental incisor through the midpalatal suture area. *Am J Orthod Dentofacial Orthop* 1993;104:85-90.
24. Oliván-Rosas G, López-Jiménez J, Giménez-Prats MJ, Piqueras-Hernández M. Considerations and differences in the treatment of a fused tooth. *Med Oral* 2004;3:224-228.
25. Hülsmann M, Bahr R, Grohmann U. Hemisection and vital treatment of a fused tooth-literature review and case report. *Endod Dent Traumatol* 1997;13:253-258.

## Abstract of the Scientific Literature



### Sedation Research in Pediatric Dentistry: Serious Questions About Quality

Anxiety about dental treatment may be a barrier to its uptake in children. Sedation can be used to relieve anxiety and manage behavior. Unfortunately, it is difficult to determine from published research which agents, dosages, and techniques are effective.

The purpose of this study was to evaluate the relative efficacy of the various conscious sedation techniques and dosages for behavior management in pediatric dentistry. MEDLINE, PubMed, EMBASE, Cochrane Central Register of Controlled Trials, dissertation abstracts, SIGLE, the World Wide Web (Google), and the Community of Science Database were searched for relevant trials and references. Searches were carried out for MEDLINE and EMBASE up to June 2003 and for the remaining databases up to December 2002. Reference lists from relevant articles were scanned, and the authors were contacted to identify trials and obtain additional information. There were no language restrictions. Trials predating 1966 were not searched.

Studies were selected if they met the following criteria: randomized controlled trials of conscious sedation comparing 2 or more drugs/techniques/placebo undertaken by the dentist or a dental team member in anxious children up to 16 years of age. Information regarding methods, participants, interventions, and outcome measures and results were independently extracted, in duplicate, by 2 authors. Specialist advice was asked to categorize interventions. Authors of trials were contacted for details about randomization and withdrawals, and a quality assessment was conducted without using any formal scoring system. The Cochrane Oral Health Group statistical guidelines were followed.

Fifty-three studies were included with 2,345 total subjects. The overall quality of the studies was found to be disappointing, with poor reporting often the main problem. Data reported could not be easily aggregated into groups to facilitate description of the results. Meta-analysis of the available data was also not possible for the same reason. The variety of differing drug regimens compared made it difficult to isolate groups of studies that were sufficiently similar in design to allow sensible comparison. When groups of studies could be isolated, the differing outcome measures used made their meta-analysis impossible.

The authors were not able to reach any definitive conclusion on which was the most effective drug or sedation method used for anxious children. A list of the proposed areas of study was described.

**Comments:** While the conclusions of this Cochrane review are disturbing and even controversial, pediatric dentists have recognized that better quality research is needed to support our sedation practices. Improvements in sedation research will occur when the training and education of pediatric dentists in sedation techniques improves. Academicians are resistant to a standardized sedation curriculum in pediatric postgraduate and graduate programs. This, in turn, directly impacts the quality of our sedation education, training, and research. But take heart: Those who regularly utilize sedation to assist in the provision of necessary dental treatment of children who are either anxious or difficult to manage know that our current sedation techniques are successful most of the time. Although the authors don't discuss this, I think what is missing is better dental sedation research to help us to choose the correct sedation technique for each situation and child. **ARM**

*Address correspondence to Dr. L.M. Matharu, Department of Paediatric Dentistry, Eastman Dental Institute, 256 Gray's Inn Rd, London, UK, WC1X 8LD.*

**Matharu LM, Ashley PF. Sedation of anxious children undergoing dental treatment. *Cochrane Database Syst Rev* 2005;2:CD003877.**

53 references