

Long-term Evaluation of Pulpotomy in Primary Molars Using Mineral Trioxide Aggregate or Formocresol

Gideon Holan, DMD¹ Eliezer Eidelman, Dr. Odont, MSD² Anna B. Fuks, CD³

Abstract

Purpose. The objective of this study was to assess the effect of mineral trioxide aggregate (MTA) as pulp dressing material following pulpotomy in primary molars with carious pulp exposure and compare them to those of formocresol (FC).

Methods. Of 33 children, primary molars treated via a conventional pulpotomy technique were randomly assigned to the MTA group (33 teeth) or FC group (29 teeth). Clinical and radiographic follow-up ranged between 4 and 74 months. The mean follow-up time was 38 months, with no difference between the groups. Twenty-nine teeth were followed until uneventful shedding (mean=33 months). Failures were detected after a mean period of 16 months (range=4 to 30).

Results. The success rate of pulpotomy was 97% for MTA (1 failure) and 83% for FC (5 failures). Eight teeth presented internal resorption. In 4 of them (2 of each group), progress of the resorption process stopped and the pulp tissue was replaced by a radioopaque calcified tissue. Pulp canal obliteration was observed in 58% of the MTA group and in 52% of the FC group (total=55%).

Conclusions. MTA showed a higher (though not statistically significant) long-term clinical and radiographic success rate than formocresol, and can be recommended as its replacement as, unlike FC, MTA does not induce undesirable responses. (*Pediatr Dent* 2005;27:129-136)

KEYWORDS: DENTAL PULP, FORMOCRESOL, PULPOTOMY, MINERAL TRIOXIDE AGGREGATE

Received August 18, 2004 Revision Accepted January 24, 2005

When the carious process advances deep into the dentin, the pulp reacts by producing an inflammation that is temporarily limited to the area close to the caries lesion. With the progression of the lesion, the inflammatory process spreads throughout the coronal pulp. When pulpotomy is performed, the complete coronal pulp is removed. The rationale for pulpotomy is based on the assumption that the inflammation is limited to the coronal pulp. As it is difficult, if not impossible, to determine clinically the histological status of the pulp, the operator has to rely on somewhat subjective criteria to determine whether the radicular pulp is or is not affected.

Thus, the bleeding time of the radicular stump after the amputation, color of the blood, and consistency of the tissue are all subjective criteria that might lead to diagnosis error. A chronically inflamed radicular pulp erroneously diagnosed as noninflamed and noninfected is one of the

major factors possibly causing pulpotomy failure in primary molars.¹

Formocresol (FC) has been a popular pulpotomy medicament in the primary dentition for the past 60 years, and is considered the most universally taught and preferred pulp therapy for primary teeth.^{2,3} Concerns have been raised about the toxicity and potential carcinogenicity of FC in humans,^{2,4-10} and alternatives have been proposed to maintain the radicular pulp's vitality. These include: (1) electrosurgery^{11,12}; (2) laser¹³; (3) glutaraldehyde¹⁴⁻¹⁷; (4) ferric sulfate¹⁸⁻²⁰; (5) freeze-dried bone^{21,22}; (6) bone morphogenetic protein^{23,24}; and (7) osteogenic protein.²⁵

In 1995, Torabinejad et al²⁶ described the physical and chemical properties of mineral trioxide aggregate (MTA)—a new root-end filling material. MTA is a powder composed of tricalcium silicate, bismuth oxide, dicalcium silicate, tricalcium aluminate, tetracalcium aluminoferrite, and calcium sulfate dihydrate. It sets via hydration to become a colloidal gel with a pH of 12.5, similar to that of calcium hydroxide.²⁷ The cement's setting time is 3 to 4 hours, and its compressive strength after setting is 70 Mpa—comparable to that of IRM.²⁸

^{1,2,3}Dr. Holan is senior lecturer, and Drs. Eidelman and Fuks are professors, Department of Pediatric Dentistry, The Hebrew University, Hadassah School of Dental Medicine, Jerusalem, Israel. Correspond with Dr. Holan at holan@cc.huji.ac.il

It has been demonstrated that MTA has the ability to stimulate cytokine release from bone cells, indicating that it actively promotes hard tissue formation.²⁹ It has also been shown that MTA has antimicrobial properties similar to zinc-oxide eugenol²⁶ and has no cytotoxic effect.³⁰ MTA has been proposed as a potential medicament for pulpotomy procedures, capping of pulps with reversible pulpitis, apexification, and root perforation repair.²⁸ The material is biocompatible and allows bone regeneration and overgrowth of cementum when used as a root-end filling material.³¹ Its sealing ability is better than that of amalgam or zinc oxide-eugenol.³²

MTA was tested in monkey teeth as a pulp-capping agent, and the favorable pulp responses observed in that experiment were found to be superior to those of calcium hydroxide.³³ Similar results were found when human intact third molars were used to compare the effect of pulp capping with MTA and calcium hydroxide.³⁴ MTA was found to maintain pulp integrity after pulp capping and pulpotomy in animal studies.^{35,36} It was also found to have a dentinogenic effect on the pulp, expressed by dentin bridge formation, where it contacts the pulp tissue.³⁶⁻³⁸

The objective of this study was to assess, clinically and radiographically, the effects of MTA as a pulp-dressing material following pulpotomy in human primary molars with carious pulp exposure and compare them to those of FC.

Methods

Study population

The procedure, possible discomfort or risks, as well as possible benefits were explained fully to parents of the children involved. The parents' informed consent, as approved by the Institutional Review Board of Human Subjects experiments was obtained prior to the investigation.

The study population consisted of exclusively healthy children attending the Pediatric Dentistry Clinic of the Hebrew University-Hadassah School of Dental Medicine in Jerusalem. Primary molars were treated via a conventional pulpotomy technique. The authors, who also performed the procedures, assessed the suitability of the teeth for pulpotomy. The authors were previously involved in several pulpotomy studies and used a standardized technique.

The criteria for selection of teeth to be included in the study were:

1. symptomless primary molars with a deep carious lesion;
2. exposure of a vital pulp by caries;
3. no clinical or radiographic evidence of pulp degeneration, such as excessive bleeding from the root canal, internal root resorption, inter-radicular and/or peri-apical bone destruction, swelling, or sinus tract;
4. the possibility of proper restoration of the teeth.

A total of 64 primary molars were pulpottedomized in 35 children (22 boys and 13 girls). Their age at time of treatment ranged between:

1. 4 years, 6 months and 10 years, with a mean age of 6 years, 7 months in the MTA group;
2. 4 years, 3 months and 12 years, with a mean age of 6 year 5 months in the FC group.

Technique

The teeth were randomly assigned via coin toss to either the MTA or FC group. In case a child had 2 molars needing pulpotomy, the second tooth was assigned to the alternative group.

If a child had a third tooth needing a pulpotomy, the dressing material was selected again by coin toss. All molars were treated with rubber dam isolation. After caries removal, coronal access was obtained with a no. 330 high-speed bur with water spray to expose the pulp chamber.

Following removal of the coronal pulp with a round bur and hemostasis, the pulp stumps in the experimental group were covered with an MTA paste, obtained by mixing MTA powder with sterile saline at a 3:1 powder/saline ratio followed by a layer of IRM. In the control group, a cotton pellet moistened with full-strength FC was placed for 5 minutes on the amputated pulp. The pulp stumps were then covered by zinc oxide-eugenol (ZOE) (The L.D. Caulk Division, Dentsply International Inc. Milford, Del) paste and a layer of IRM (Bayer-Leverkussen, Germany). ZOE was used directly over the pulp stumps to prevent possible deleterious effects of the resins in IRM on the amputated radicular pulp. The crown of all but 8 teeth was restored with a stainless steel crown. One tooth had a composite restoration, and 7 other teeth were restored with amalgam that was condensed after the IRM had set to avoid the MTA from being pushed into the root canals.

Follow-up

The children were asked to return for clinical and radiographic examination every 6 months. When a patient did not respond or broke an appointment, further attempts were made to call the parents and a follow-up examination was rescheduled. The children were then examined clinically by 1 of the 3 authors who were not blind to which treatment group the assessed tooth belonged. All 3 authors blindly evaluated the radiographs, however, and a consensus was reached. The follow-up period was defined as the time elapsed between treatment and one of the following:

1. detection of pulpotomy failure;
2. naturally exfoliated tooth;
3. patient's last visit for recall examination.

Teeth with less than 12 months follow-up time were excluded from the study, unless a failure was detected during the first postoperative year.

Evaluation

All 3 investigators independently evaluated the radiographs to detect signs of pathology. The authors were previously involved in several pulpotomy studies and used a standardized evaluation that regarded the treatment as

a failure when one or more of the following signs were present: (1) furcation radiolucency; (2) periapical bone destruction; and (3) swelling or sinus tract. Internal root resorption was regarded as a failure only if the process reached the root's outer surface, thereby inducing an inflammatory process in the periodontal ligament and the surrounding bone. Arrest of internal resorption with calcific metamorphosis of the pulp was not regarded as a failure, nor was pulp canal obliteration (PCO).³⁹

The data were analyzed to assess the treatment's success rates at the various follow-up periods. The differences were statistically analyzed using the chi-square test, Fisher exact test, *t* test, and Mann-Whitney U test.

Results

Of the 64 pulpotomized teeth, 62 teeth in 33 children (22 boys and 11 girls) were available for analysis of success/failure rate. Two molars in 2 patients, both of the FC group, were excluded from the study because the patients never returned for follow-up examination.

No difference was found between the MTA and FC groups regarding the children's age at the time of treatment (*t* test and Mann-Whitney U test). The girls' mean age at the time of treatment was 6 years, 1 month—8 months less than that of the boys (6 years, 9 months). The distribution of the assessed teeth is presented in Table 1. The dressing material used was MTA in 33 molars and FC in the other 29 molars.

Follow-up time

Follow-up time of all teeth in both the MTA and FC groups ranged between 4 and 74 months, with a mean of

38.2 months. Treatment failure was detected in 6 teeth after a mean period of 16 months (range=4 to 30 months). One tooth, in which failure was detected after 4 months, could not be excluded from the study despite the short follow-up, as it would distort the results. Table 2 presents the failures in a separate column. Twenty-nine teeth with successful treatment were followed until uneventful shedding, with a mean follow-up period of 33 months (range=13 to 59 months). The other 27 successfully treated teeth had a mean follow-up period of 49 months (range=21 to 74 months), with no difference between the experimental and control group (Table 2). The differences were statistically analyzed using the *t* test and Mann-Whitney U test.

Success rate

The success rate of the pulpotomies of all teeth in this study was 90%; MTA was successful in 97% (32/33) of the cases, and FC had an 83% (24/29) success rate, with no statistical difference between the 2 materials (*P*>.05). The follow-up evaluations revealed 6 failures (10%) of pulpotomy: 5 of them in teeth treated with FC and only 1 in which MTA was used as a dressing material. Four teeth were first primary molars, and 2 were second molars. All failures were observed in teeth restored with stainless steel crowns. Failures were detected after a mean follow-up period of 16 months (range=4 to 30 months).

Table 1. Distribution of Evaluated Pulpotomized Primary Molars

Material	Primary 1st molar		Primary 2nd molar		Total		Total
	Maxillary	Mandibular	Maxillary	Mandibular	Maxillary	Mandibular	
MTA	4	11	7	11	11	22	33
Formocresol	6	11	5	7	11	18	29
Total	10	22	12	18	22	40	62

Table 2. Distribution of Pulpotomized Teeth and Follow-up Times According to Longest Possible Follow-up Period

	Longest possible follow-up period (months)			
	Until uneventful shedding*	Until last examination*	Until detection of failure*	Total
MTA	N=14	N=18	N=1	N=33
Range	13-57	21-68		12-68
Mean	31.20	48.14	12	39.84
(±SD)	±14.3	±11.68		±15.88
Formocresol	N=15	N=9	N=5	N=29
Range	16-59	34-74	4-30	4-74
Mean	34.37	53	16.47	36.28
(±SD)	±14.5	±13.02	±10.21	±17.48
Total	N=29	N=27	N=6	N=62
Range	13-59	21-74	4-30	4-74
Mean	32.87	48.94	15.64	38.25
(±SD)	±14.3	±11.94	±9.36	±16.76

*Not significant (*t* test and Mann-Whitney U test) *P*>.05

Radiographic findings

When comparing the results of the 3 evaluators, a complete accordance was found, as all cases were clear-cut success or failure with no need to discuss any of the cases to achieve a consensus. In no case was MTA found to be pushed into the root canals.

Pulp canal obliteration

The most frequent radiographic finding was pulp canal obliteration (PCO), which developed in 55% (34/62) of all teeth. PCO was found in 58% of MTA group teeth (19/33) and in 52% (15/29) in FC group teeth, with no difference between the groups ($P>.5$). PCO was detected after a mean period of 22 months (range=7 to 46 months). In the MTA group, it was observed after a mean of 20.5 months (range=7 to 46), and in the FC group the mean was 24 months (range=10 to 43 months). This difference was not statistically significant (t test and Mann-Whitney U test).

Internal root resorption

Internal root resorption was observed in 8 teeth: 6 treated with FC and 2 with MTA. This finding was detected after 25 to 38 months in the MTA group and after 4 to 25

months in the FC group. In 4 teeth (2 of each group), internal root resorption was found to be arrested and the pulp tissue was replaced by calcified tissue (Figures 1 and 2), with the teeth being clinically asymptomatic. These teeth were not considered as failures.

In the other 4 teeth (the entire FC group), internal resorption was associated with periapical and/or inter-radicular radiolucent defects and external inflammatory root resorption leading to extraction of the teeth. At the 12-month recall examination, 2 other teeth (1 of each group) presented with periapical and inter-radicular radiolucent defects associated with clinical signs of an abscess.

Dentin bridge

One mandibular primary second molar presented a dentin bridge at the entrance of the mesial root canal just below the MTA.

Discussion

This report intended to examine the clinical and radiographic success rates of pulpotomies with MTA, a material with evidence-based success in many endodontic procedures. Several in vitro and in vivo studies have shown that

Table 3. Radiographic Appearance of the Pulp in Pulpotomized Primary Molars

	Normal appearance of the pulp (%)	Pulp canal obliteration (%)	Pathologic finding* (%)	Total (%)
MTA	13 (39)	19 (58)†	1 (3)	33 (100)
Formocresol	9 (31)	15 (52) †	5 (17)‡	29 (100)
Total	22 (34)	34 (55)	6 (11)	62 (100)

*Periapical and inter-radicular radiolucency, pathologic external root resorption, not including arrested internal resorption.

†Chi-square $P>.05$. Not significant.

‡Chi-square $P>.05$. Not significant.

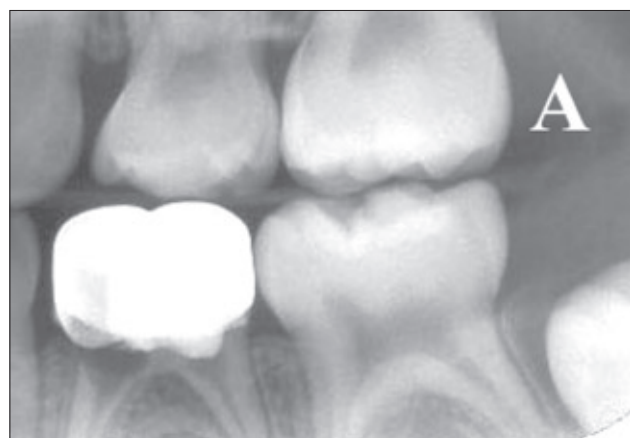

Figure 1A. Left bite-wing radiograph of a 5-year, 2-month-old girl. Primary mandibular first molar with internal resorption in the mesial root 7 months after performance of pulpotomy with formocresol.

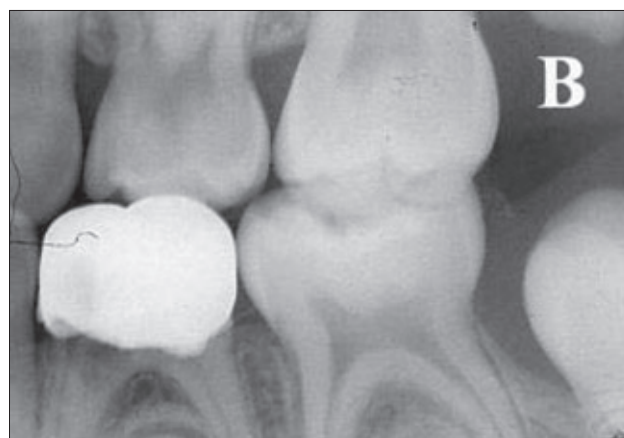


Figure 1B. Twenty-six months later. Notice the calcified tissue replacing the pulp tissue in the resorption area. As the internal resorption did not induce an inflammatory process in the periodontal ligament and the surrounding bone, the treatment was not considered a failure.

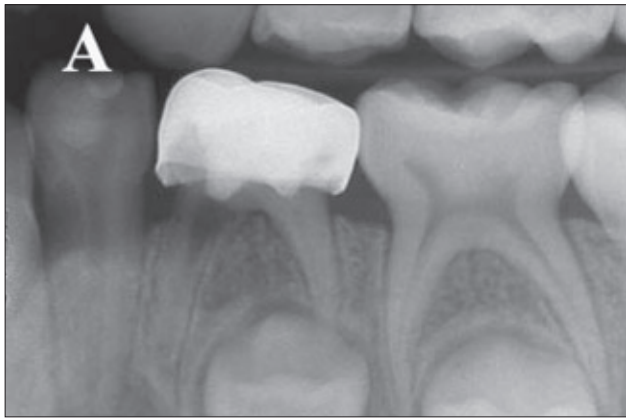

Figure 2A. Left bite-wing radiograph of an 8-year, 2-month-old girl. Primary mandibular first molar with internal resorption in the mesial root 38 months after performance of pulpotomy with MTA.

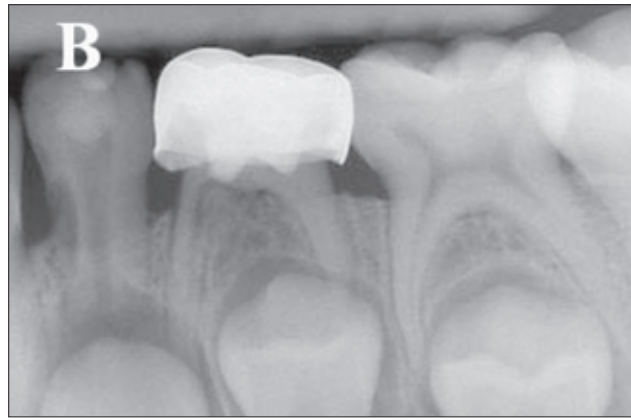


Figure 2B. Ten months later. Notice the calcified tissue replacing the pulp tissue in the resorption area. Similarly to Figure 1, internal resorption did not involve the surrounding tissues and was, therefore, not considered a failure.

MTA prevents microleakage, is biocompatible, and promotes regeneration of the original tissues when it is placed in contact with the dental pulp or periradicular tissues.²⁸

FC was selected as the control group, since it is still considered the gold standard in primary teeth pulp therapy, in spite of its reported toxic, mutagenic, and carcinogenic properties.^{4,7,10}

The high success rate of pulpotomy with MTA (97%) is impressive, especially considering the long-term follow-up period. Except for 1 failure detected at the 12-month recall examination, all molars treated with MTA presented a successful outcome. Some of these teeth were retained until uneventful shedding, and others had a mean follow-up of more than 4 years. While the success rate of FC decreased with time as expected,^{1,40,41} with the last failure being detected postoperatively at 30 months, MTA's success rate remained stable with no new failures observed after 12 months.

Pulpotomy failures in primary teeth with caries exposure can be attributed to misdiagnosis of inflammation in the radicular pulp prior to treatment¹ and/or pulp contamination due to microleakage of large multi-surface amalgam rather than stainless steel crowns.⁴² These arguments, however, cannot explain the difference in success rates between MTA and FC. As the teeth were randomly assigned to 1 of the groups via coin toss, it is not feasible that more teeth with undiagnosed, inflamed, radicular pulp were assigned to the FC group. Additionally, all failures were detected in teeth restored with stainless steel crowns, ruling out the possibility of contamination due to poor restoration seal.⁴³ It is, therefore, reasonable to assume that MTA can handle inflammation better than FC. Salako et al³⁶ radiographically and histologically compared the effect of several dressing materials, including MTA and FC, on the radicular pulp in pulpotomized rat molars. They found that, while FC showed zones of atrophy, inflammation, and fibrosis, MTA performed ideally as a pulpotomy agent, causing dentin bridge formation while simultaneously maintaining normal pulp architecture. Dentin bridges were also found under the MTA in a study on monkeys.³³ Based on

these studies, the authors would expect to find more than only 1 case of a dentin bridge in the present study.

One of this study's more interesting radiographic findings was the arrest of the progression of the internal resorption process with replacement of the radicular pulp tissue by calcified material. This was reported earlier by Smith et al³⁹ and Papagiannoulis⁴⁴ in primary molars pulpotomized with ferric sulfate.

Previous investigations of ZOE as a pulpotomy agent or as a base for pulpotomies suggest that ZOE can cause pulp inflammation,⁴⁵ with a risk for subsequent internal resorption. Smith et al³⁹ claimed that internal resorption is associated with eugenol. When used together with zinc oxide (as in a sub-base following pulpotomy), eugenol comes into direct contact with the vital tissue and causes a moderate to severe inflammatory response, resulting in chronic inflammation and necrosis. This, however, cannot explain the internal resorption observed in the present study. Though ZOE was used to fill the pulp chamber prior to coronal restoration, it has been placed over the MTA layer and not directly over the pulp stumps. Because MTA is an excellent sealer,⁴⁶ it is more likely that internal resorption was the result of undiagnosed chronic inflammation existing in the radicular pulp prior to pulpotomy than the result of exposure of the radicular pulp to eugenol. Cotes et al⁴⁷ claimed that, in pulpotomized rat teeth, if the pulp tissue is fixed by FC it will not be affected by eugenol. Smith et al also claimed that the fixed layer, caused by the application of FC on the pulp, serves as a barrier to eugenol.³⁹ In the present study, however, internal resorption was found also in FC-treated teeth.

Internal resorption, as an obvious pathologic process,⁴⁸ cannot be considered a sign of pulpotomy success as suggested by Smith et al.³⁹ Conversely, it is not necessarily an indication of failure, as shown in this study and previously by Smith et al³⁹ and Papagiannoulis.⁴⁴ This confusion leads to the need to re-evaluate the definitions of pulpotomy success and failure. Before doing so, it is imperative to define the purpose of performing pulpotomy in primary

teeth with carious exposure. The aim of pulpotomy, in the authors' opinion, is to retain a symptom-free, functional primary tooth until it reaches the age of its physiologic exfoliation. This definition allows the inclusion of any condition and process that is symptom-free and does not impair (or have the potential to impair) the tooth's function. Internal resorption fits this definition, as long as it is not associated with external inflammatory root resorption. Internal resorption can, therefore, be left for follow-up, expecting the arrest of the process and the development of calcific metamorphosis.

Pulp canal obliteration (PCO) (sometimes termed "calcific metamorphosis"³⁹) was the most common radiographic finding in both groups. PCO is the result of extensive activity of odontoblast-like cells, demonstrating that the tooth has retained some degree of vitality^{49,50} and, therefore, was not regarded as failure. PCO is a common radiographic finding in pulpotomized teeth, and a wide range of frequencies has been reported in teeth treated with FC,⁴⁹ diluted FC,^{19,39,51} and ferric sulfate.⁵² PCO was observed in both MTA and FC groups, with no significant difference (52% and 38%, respectively). This is in contrast to the findings of Fei et al,¹⁹ who reported a finding of 44% PCO after application of diluted FC in 27 human molars.

Another clinical advantage of MTA over FC is the fact that less time is needed for the procedure. While FC requires 3 to 5 minutes application before the cotton pellet is removed, with MTA the pulp chamber is filled with IRM immediately after application of the dressing material. In addition, as the moist cotton pellet in FC is usually squeezed to remove the excess of FC before placement over the pulp stumps, it sometimes adheres to the clot and bleeding reoccurs when the pellet is removed. This does not occur with MTA applied directly without a cotton pellet.

MTA is commercially available as Proroot MTA (Dentsply, Paris), but its price is very high. As the material cannot be kept once the envelope is opened, its clinical use in pediatric dentistry practice becomes almost prohibitive.⁵³ Recently, MTA was found to have a composition similar to conventional Portland cement used in the production of concrete. Holland et al⁵⁴ used MTA and Portland cement to cover the radicular pulp stumps of pulpotomized teeth in dogs. These authors found no difference in the healing process of the pulp in teeth treated with MTA or Portland cement.

The authors hope that these findings will lead to the development of a more affordable type of MTA compound. A recent study⁵⁵ found that gray MTA appears to be superior to white MTA and FC as a pulp dressing for pulpotomized primary teeth. No failures were observed with the gray MTA after a 12-month follow-up period. In the preliminary report of the present study,⁵⁶ the mean follow-up period was 13 months and 1 failure of a tooth treated with MTA was observed. It should be emphasized, however, that this was the only failure of MTA detected in the present study, with a mean follow-up of more than 38 months.

Conclusions

MTA showed a higher (though not statistically significant) long-term clinical and radiographic success rate than FC, and can be recommended as its replacement as, unlike FC, MTA does not induce undesirable responses.

Acknowledgement

The authors wish to thank Dr. Mahmoud Torabinejad, DMD, MSSD, PhD, Loma Linda University, Loma Linda, Calif, for providing the MTA material and for his suggestions to the research protocol.

References

1. Mejare I. Pulpotomy of primary molars with coronal or total pulpitis using formocresol technique. *Scand J Dent Res* 1979;87:208-216.
2. Primosch, RE, Glom TA, Jerrell RG. Primary tooth pulp therapy as taught in predoctoral pediatric dental programs in the United States. *Pediatr Dent* 1997;19:118-122.
3. Vij R, Coll JA, Shelton P, Farooq NS. Caries control and other variables associated with success of primary molar vital pulp therapy. *Pediatr Dent* 2004; 26:214-220.
4. Auerbach C, Moutschen-Damen M, Moutschen M. Genetic and cytogenetical effects of formaldehyde and related compounds. *Mutat Res* 1977;39:317-361.
5. Block RM, Lewis RD, Sheats JB, Fauley J. Cell-mediated immune response to dog pulp tissue altered by formocresol within the root canal. *J Endod* 1977;3:424-430.
6. Pruhs RJ, Olen GA, Sharma PS. Relationship between formocresol pulpotomies on primary teeth and enamel defects on their permanent successors. *J Am Dent Assoc* 1977;94:698-700.
7. Myers DR, Shoaf HK, Dirksen TR, Pashley DH, Whitford GM, Reynolds KE. Distribution of 14c-formaldehyde after pulpotomy with formocresol. *J Am Dent Assoc* 1978;96:805-813.
8. Block RM, Lewis RD, Sheats JB, Burke SG. Antibody formation to dog pulp tissue altered by formocresol within the root canal. *Oral Surg* 1978;45:282-292.
9. Judd PL, Kenny DJ. Formocresol concerns: A review. *J Can Dent Assoc* 1987;53:401-404.
10. Sun HW, Feigal RJ, Messer HH. Cytotoxicity of glutaraldehyde and formaldehyde in relation to time of exposure and concentration. *Pediatr Dent* 1990;12:303-307.
11. Shaw DW, Sheller B, Barras BD, Morton TH. Electrosurgical pulpotomy: A 6 months study in primates. *J Endod* 1987;13:500-505.
12. Ruemping DR, Morton TH Jr, Anderson MW. Electrosurgical pulpotomy in primates—A comparison with formocresol pulpotomy. *Pediatr Dent* 1983;5:14-18.

13. Shoji S, Nakamura M, Horiuchi H. Histopathological changes in dental pulps irradiated by CO₂ laser: A preliminary report on laser pulpotomy. *J Endod* 1985;11:379-384.
14. Lloyd MJ, Seale NS, Wilson CFG. The effects of various concentrations and lengths of application of glutaraldehyde on monkey pulp tissue. *Pediatr Dent* 1988;10:121-126.
15. García-Godoy F, Ranly DM. Clinical evaluation of pulpotomies with ZOE as the vehicle of glutaraldehyde. *Pediatr Dent* 1987;9:144-146.
16. Fuks AB, Bimstein E, Klein H, Guelmann M. Assessment of a 2% buffered glutaraldehyde solution in pulpotomized primary teeth of schoolchildren. *J Dent Child* 1990;57:371-375.
17. Fuks AB, Cleaton-Jones P, Michaeli Y, Bimstein E. Pulp response to collagen and glutaraldehyde in pulpotomized primary teeth of baboons. *Pediatr Dent* 1991;13:142-150.
18. Landau MJ, Johnsen DC. Pulpal response to ferric sulfate in monkeys [abstract no. 822]. *J Dent Res* 1988;67:215.
19. Fei AL, Udin RD, Johnson R. A clinical study of ferric sulfate as a pulpotomy agent in primary teeth. *Pediatr Dent* 1991;13:327-332.
20. Davis JM, Furtado LB. Ferric sulfate: A possible new medicament for pulpotomies in the primary dentition: the first year results from a four year study in Fortaleza, Brazil. Proceedings of the 13th Congress of the International Association of Dentistry for Children, Kyoto, Japan; 1991.
21. Fadavi S, Anderson AW, Punwani IC. Freeze-dried bone in pulpotomy procedures in monkeys. *J Pedod* 1989;13:108-122.
22. Fadavi S, Anderson AW. A comparison of the pulpal response to freeze-dried bone, calcium hydroxide, and zinc oxide-eugenol in primary teeth in two cynomolgus monkeys. *Pediatr Dent* 1996;18:52-56.
23. Nakashima M. The induction of reparative dentine in the amputated dental pulp of the dog by bone morphogenetic protein. *Arch Oral Biol* 1990;35:493-497.
24. Nakashima M. Induction of dentine formation on canine amputated pulp by recombinant human bone morphogenetic proteins (BMP)-2 and 4. *J Dent Res* 1994;73:1515-1522.
25. Rutherford RB, Wahle J, Tucker M, Roger D, Charette M. Induction of reparative dentine formation in monkeys by recombinant human osteogenic protein-1. *Arch Oral Biol* 1993;38:571-576.
26. Torabinejad M, Hong CU, McDonald F, Pitt Ford TR. Physical and chemical properties of a new root-end filling material. *J Endod* 1995;21:349-353.
27. Schwartz R, Mauger M, Clement D, Walker W. Mineral trioxide aggregate: A new material for endodontics. *J Am Dent Assoc* 1999;130:967-975.
28. Torabinejad M, Chivian N. Clinical applications of Mineral Trioxide Aggregate. *J Endod* 1999;25:197-205.
29. Koh ET, Pitt Ford TR, Torabinejad M, McDonald F. Mineral trioxide aggregate stimulates cytokine production in human osteoblasts. *J Bone Miner Res* 1995;10S:S406.
30. Osorio RM, Hefti A, Vertucci FJ, Shawley AL. Cytotoxicity of endodontic materials. *J Endod* 1998;24:91-96.
31. Torabinejad M, Pitt-Ford T, McKendry D, Abedi H, Miller D, Kariyawasam S. Histologic assessment of mineral trioxide aggregate as a root-end filling in monkeys. *J Endod* 1997;23:225-229.
32. Fogel HM, Peikoff MD. Microleakage of root-end filling materials. *J Endod* 2001;27:456-458.
33. Pitt Ford T, Torabinejad M, Abedi H, Bakland LK, Kariyawasam SP. Using mineral trioxide aggregate as a pulp capping material. *J Am Dent Assoc* 1996;127:1491-1494.
34. Aienehchi M, Eslami B, Ghanbariha M, Saffar AS. Mineral trioxide aggregate (MTA) and calcium hydroxide as pulp-capping agents in human teeth. A preliminary report. *Int Endod J* 2003;26:225-231.
35. Dominguez MS, Witherspoon DE, Gutmann JL, Opperman LA. Histological and scanning electron microscopy assessment of various vital pulp-therapy materials. *J Endod* 2003;29:324-333.
36. Salako N, Joseph B, Ritwik P, Salonen J, John P, Junaid TA. Comparison of bioactive glass, mineral trioxide aggregate, ferric sulfate, and formocresol as pulpotomy agents in rat molar. *Dent Traumatol* 2003;19:314-320.
37. Tziafas D, Pantelidou O, Alvanou A, Belibasakis G, Papadimitriou S. The dentinogenic effect of mineral trioxide aggregate (MTA) in short-term capping experiments. *Int Endod J* 2002;35:245-254.
38. Sakar NK, Saunderi B, Moiseyevai R, Berzins DW, Kawashima I. Interaction of mineral trioxide aggregate (MTA) with a synthetic tissue fluid [abstract no. 3155]. *J Dent Res* 81(special issue A):A-391.
39. Smith NL, Seale NS, Nunn ME. Ferric sulfate pulpotomy in primary molars: A retrospective study. *Pediatr Dent* 2000;22:192-199.
40. Rolling I, Thylstrup A. A 3-year clinical follow-up study of pulpotomized primary molars treated with the formocresol technique. *Scand J Dent Res* 1975;83:47-53.
41. Hicks MJ, Barr ES, Flaitz CM. Formocresol pulpotomies in primary molars. A radiographic study in a pediatric dentistry practice. *J Pedod* 1986;10:331-339.
42. Holan G, Fuks AB, Keltz N. Success rate of pulpotomized primary molars restored with stainless steel crown vs amalgam. *Pediatr Dent* 2002;24:212-216.
43. Randall RC. Prefabricated metal crowns for primary and permanent molar teeth: Review of the literature. *Pediatr Dent* 2002;24:489-500.
44. Papagiannoulis L. Clinical studies on ferric sulphate as a pulpotomy medicament in primary teeth. *Eur J Paediatr Dent* 2002;3:126-32.

45. Watts A, Paterson RC. Pulpal response to a zinc oxide-eugenol cement. *Int Endod J* 1987;20:82-86.
46. Andelin WE, Browning DF, Hsu GH, Roland DD, Torabinejad M. Microleakage of resected MTA. *J Endod* 2002;28:573-574.
47. Cotes O, Boj JR, Canalda C, Carreras M. Pulpal tissue reaction to formocresol vs ferric sulfate in pulpotomized rat teeth. *J Clin Pediatr Dent* 1997;21:247-253.
48. Mjor IA. *Reaction patterns in human teeth*. Boca Raton, Fla: CRC Press Inc; 1983:104-105.
49. Willard RM. Radiographic changes following formocresol pulpotomy in primary molars. *J Dent Child* 1976;43:414-415.
50. Tziafas D, Smith AJ, Lesot H. Designing new treatment strategies in vital pulp therapy. *J Dent* 2000;28:77-92.
51. Fuks AB, Bimstein E. Clinical evaluation of diluted formocresol pulpotomy in primary teeth of school children. *Pediatr Dent* 1981;3:321-324.
52. Fuks AB, Holan G, Davis JM, Eidelman E. Ferric sulfate versus diluted formocresol in pulpotomized primary molar: Long-term follow up. *Pediatr Dent* 1997;19:327-330.
53. Fuks AB. Current concepts in vital primary pulp therapy. *Eur J Paediatr Dent* 2002;3:115-120.
54. Holland R, de Souza V, Murata SS, Nevy MJ, Bernabe PF, Otoboni Filho JA, Dezan Junior E. Healing process of dog dental pulp after pulpotomy and pulp covering with mineral trioxide aggregate or Portland cement. *Braz Dent J* 2001;12:109-113.
55. Agamy HA, Bakry NS, Mounir MM, Avery DR. Comparison of mineral trioxide aggregate and formocresol as pulp-capping agents in pulpotomized primary teeth. *Pediatr Dent* 2004;26:302-309.
56. Eidelman E, Holan G, Fuks AB. Mineral trioxide aggregate vs formocresol in pulpotomized primary molars: A preliminary report. *Pediatr Dent* 2001;23:15-18.

ABSTRACT OF THE SCIENTIFIC LITERATURE



EFFECTS OF ARGON LASER AND FLUORIDE ON PRIMARY TOOTH CARIES

Dental caries is the most common chronic childhood disease, as documented by the U.S. Surgeon General in the report *Oral Health in America*. Recently, laser irradiation has been touted in the prevention of dental caries in permanent teeth by reducing enamel solubility and dissolution rates. The purpose of this study was to evaluate topical fluoride and low-fluence argon laser treatment effects on in vitro caries formation in primary tooth enamel.

Twenty primary molars with caries-free buccal and lingual surfaces were selected and divided into 4 groups. Group 1 served as the control with no treatment; group 2 had argon laser irradiation only; group 3 had an acidulated phosphate fluoride treatment (1.23% for 4 minutes) before laser treatment; and group 4 had laser then fluoride treatment. In all instances of laser treatment, exposure was limited to 10 seconds.

The teeth had an acid-resistant coating applied, leaving buccal and lingual windows exposed, and were immersed in an artificial caries medium. Following a 10-day exposure to this medium, teeth were sectioned longitudinally, and the in vitro lesions created were evaluated for depth.

The results showed that argon laser alone or a combination of a laser with fluoride in either order of application resulted in a significant reduction in lesion depth. The combination of fluoride and laser was more effective than the laser alone.

Comments: This procedure is relatively simple and noninvasive. Pediatric dentists need to explore and keep abreast of caries-preventive regimens and innovative techniques. With the incorporation of argon laser irradiation, a practice can exhibit “cutting-edge” technology and provide a major step toward creating “cavity-free” patients by imparting significant caries resistance to primary teeth.

Address correspondence to Dr. John Hicks, Department of Pathology, MCI-2261, Texas Children's Hospital, 6621 Fannin Street, Houston, TX 77030-2313.

Westerman GH, Hicks, MJ, Flaitz CM, Ellis RW, Powell, GL. Argon laser irradiation and fluoride treatment effects on caries-like enamel lesion formation in primary teeth: An in vitro study. *Am J Dent* 2004;17:241-244.

40 references