

# A comparison of pulpectomies using ZOE and KRI paste in primary molars: a retrospective study

Gideon Holan, DMD Anna B. Fuks, CD

## Abstract

Maintaining a successfully root-treated primary molar has the advantage of preserving the natural tooth—the best possible space maintainer. The purpose of this study was to compare the success of endodontic treatment of nonvital primary molars using ZOE with that of KRI paste. Of 78 necrotic primary molars, 34 were filled with ZOE and 44 with an iodoform-containing paste (KRI). The canals were prepared with files, rinsed with saline and filled with one of the resorbable pastes, using a spiral Lentulo on a low-speed handpiece. A radiograph was exposed immediately postoperatively to observe whether the root filling was flush, underfilled, or overfilled. The effect of length of fill on the treatment outcome also was evaluated. Teeth were examined periodically clinically and radiographically to assess success of the treatment. Follow-up interval varied from 12 to more than 48 months. Overall success rate for KRI paste was 84% versus 65% for ZOE, which was statistically significant ( $P < 0.05$ ). Overfilling with ZOE led to a failure rate of 59% as opposed to 21% for KRI ( $P < 0.02$ ). Conversely, underfilling led to similar results, with a failure rate of 17% for ZOE and 14% for KRI. These results support the clinical efficacy of root filling with KRI paste as a treatment option for nonvital primary molars. (*Pediatr Dent* 15:403–7, 1993)

## Introduction

Numerous articles describe indications, contra-indications, and techniques for root canal treatment of primary teeth with infected pulps.<sup>1-6</sup> Although root canal treatment of primary molars has been advocated for many years,<sup>7</sup> no consensus exists as to the preferred filling material. Rabinowitch,<sup>7</sup> in 1953, stated, "The history of the treatment of root canals is the discussion of medications used."

The optimal requirements of a root-filling material for primary teeth were listed by several authors:<sup>2, 8, 9</sup>

1. It should not irritate the periapical tissues, nor coagulate any organic remnants in the canal.
2. It should have a stable disinfecting power.
3. Surplus pressed beyond the apex should be resorbed easily.
4. It should be inserted easily into the root canal, and removed easily if necessary.
5. It should adhere to the walls of the canal and should not shrink.
6. It should not be soluble in water.
7. It should not discolor the tooth.
8. It should be radiopaque.
9. It should induce vital periapical tissue to seal the canal with calcified or connective tissue.
10. It should be harmless to the adjacent tooth germ.

11. It should not set to a hard mass, which could deflect an erupting succedaneous tooth.

The filling materials most commonly suggested as suitable pastes for obturation of the root canals are zinc oxide-eugenol (ZOE)<sup>10, 11</sup> sometimes mixed with formocresol (FC),<sup>12</sup> and Kri 1 (KRI) (2.025% parachlorophenol, 4.86% camphor, 1.215% menthol, and 80.8% iodoform).<sup>5, 13</sup> Table 1 summarizes reports of success rates of root canal fillings in primary molars using different filling materials.

Despite the high success rates, ZOE does not meet all criteria required from an ideal root canal filling material for primary teeth.<sup>2</sup> Although described as a resorbable material,<sup>3</sup> ZOE is retained after tooth exfoliation.<sup>1, 16, 17</sup> In addition, Erausquin and Muruzabal<sup>16</sup> demonstrated ZOE to be highly toxic to periapical tissues in rats, causing necrosis of the hard tissues it contacted. Jerrel and Ronk<sup>18</sup> reported a case of develop-

**Table 1. Reports of success rates in root canal filling in primary molars using different filling materials**

Investigator	Year	Followup (months)	Number of Teeth Examined	Filling Material	Success Rate (%)
Gould <sup>14</sup>	1972	7–26	29	ZOE	68.7
Rifkin <sup>2</sup>	1980	12	26	KRI	89.0
Coll et al. <sup>11</sup>	1985	6–36	33	ZOE	80.5
Coll et al. <sup>11</sup>	1985	60–82	29	ZOE	86.1
Garcia-Godoy <sup>5</sup>	1987	6–24	55	KRI	95.6
Reyes et al. <sup>15</sup>	1989	6–24	53	KRI + FC + Ca(OH) <sub>2</sub>	100.0
Barr et al. <sup>12</sup>	1991	12–74	62	ZOE + FC	82.3

mental arrest of a premolar following overfilling of the root canal of the second primary molar using a zinc oxide-eugenol/formocresol paste. They attributed this malformation to the toxic nature of the filling material.

KRI, basically an iodoform paste, was suggested initially by Wolkhoff<sup>19</sup> in 1928 as a resorbable paste suitable for root canal filling. According to Rifkin,<sup>13</sup> it meets all criteria required from an ideal root canal filling material for primary teeth. It was also found to have a long-lasting bactericidal potential.<sup>8</sup> The excess of paste extruded into periapical granulomatous tissue is removed rapidly from the apical region, and replaced by healthy connective tissue.<sup>8,20</sup> Since iodoform paste does not set to a hard mass, its removal for retreatment is very easy.<sup>5</sup>

In 1984, based on the reports in the literature and our experience of frequent retention of ZOE (particularly with primary anterior teeth) the principal investigator (GH) stopped using ZOE and chose KRI paste as the preferred root canal filling material. The criteria for pulpectomy, as well as the technique used remained identical, allowing comparison of the effectiveness of both filling materials.

The purpose of the present retrospective study was to assess the success rates of root canal treatment of nonvital primary molars using ZOE or KRI paste.

## Methods and materials

The data used in this study were collected from files of patients treated at the principal investigator's private practice between 1980 and 1990. Pulpectomy was performed on 139 primary molars, 86 with ZOE and 53 with KRI paste. Only cases having postoperative follow-up records of 6 months or more were included in the study. Teeth extracted less than 6 months post-treatment were listed as failures.

A one-visit pulpectomy procedure was performed in restorable primary molars with severely infected and/or nonvital pulp. Alveolar swelling, sinus tract (parulis), inter-radicular or periapical radiolucency and external resorption of less than one-third of the root length were not considered contraindications for pulpectomy.

## Technique

Broaches were used to remove necrotic pulp tissue, and the root canals were prepared with files up to #35, rinsed with hydrogen peroxide and saline and dried with paper points. Root length was determined from a preoperative radiograph. ZOE paste was used initially as the root filling material. Since traces of ZOE paste were observed in the tissue after resorption of the root and natural exfoliation of the endodontically treated primary teeth, particularly in the incisor region, its use was discontinued and KRI paste (Pharmachemie AG., CH-8053, Zurich, Switzerland) was employed instead. In both cases, the paste was introduced into the root

canal using a spiral Lentulo. A postoperative radiograph was exposed to ensure adequate obturation of the canals. When gross underfilling was observed, additional paste was condensed into the canal; in cases of overfilling an attempt was made to remove the excess by irrigation through the sinus tract, if present. The pulp chamber was filled temporarily with IRM and the tooth was restored with a stainless steel crown four weeks later. Prior to tooth crowning another radiograph was exposed in cases presenting bone loss in the postoperative radiograph and cases of retreatment due to over- or underfilling. For retreated teeth the 4-week postoperative radiograph was used as baseline. The teeth were checked clinically and radiographically at periodic recall examinations.

The clinical and radiographic findings at the pre- and postoperative examinations were recorded. These included the presence or absence of mobility, swelling, sensitivity to percussion, sinus tract, interradicular or periapical radiolucencies, and pathologic root resorption.

The treatment was judged to be successful when the following clinical and radiographic criteria were fulfilled:

### Clinical criteria:

1. No abnormal mobility
2. No sensitivity to percussion
3. Healthy soft tissue (no swelling, redness, or sinus tract).

### Radiographic criteria:

1. Preoperative pathologic inter-radicular and/or periapical radiolucencies resolved, and no new postoperative pathologic radiolucencies developed
2. Pathologic external root resorption arrested.

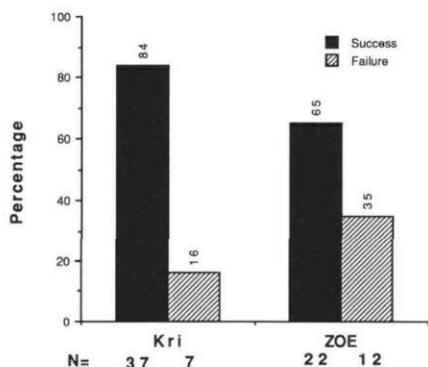
The overall success rates of root canal fillings with KRI vs. ZOE were compared. In addition, possible differences between maxillary and mandibular molars, first and second molars, and the filling quality (i.e., overfilling, underfilling, or flush) were assessed. The chi-square test was used for statistical analysis.

**Table 2. Distribution of pulpectomized primary molars according to type and filling material**

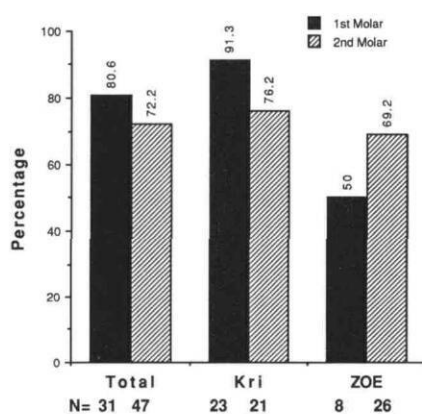
	KRI	ZOE	Total
<b>Maxillary</b>			
1st molar	5	1	6
2nd molar	5	6	11
<b>Mandibular</b>			
1st molar	18	7	25
2nd molar	16	20	36
<b>Total</b>	<b>44</b>	<b>34</b>	<b>78</b>

**Table 3. Maximum follow-up time in months of the root-treated teeth**

Filling Material	Post-Treatment Examination Period (Months)					Total
	6-12	12-24	24-36	36-48	> 48	
ZOE	7	4	8	11	4	34
KRI	13	7	14	7	3	44
<b>Total</b>	20	11	22	18	7	78



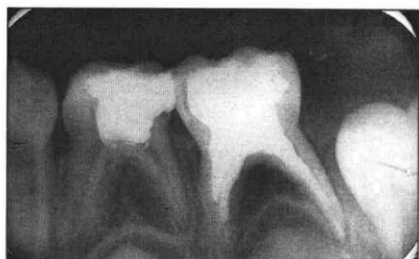**Fig 1. Success rates of root canal fillings with KRI vs. ZOE.**



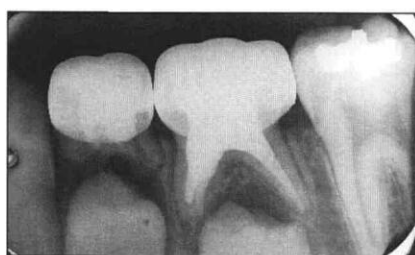**Fig 2. Success rates of root canal fillings in first vs. second primary molars.**

## Results

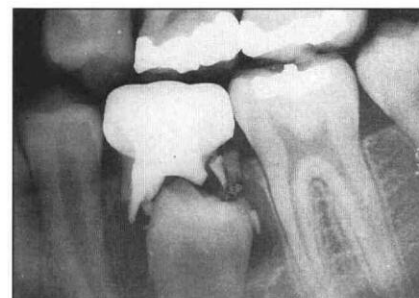From a total of 139 primary molars root treated at the principal investigator's private practice, 62 were excluded either for lack of sufficient data or were not available for more than 6-month follow-up examination. The remaining 78 primary molars (34 filled with ZOE and 44 with KRI) were evaluated. The mean age of patients with pulpectomy of the 1st and 2nd primary molars was 5 years 7 months and 5 years 11 months. The distribution of teeth according to tooth type and filling material is presented in Table 2. Follow-up period extended between 6 and 84 months (Table 3). The results of root treatment with ZOE and KRI paste are summarized in Figs 1 and 2. Three teeth were extracted during the first six months following pulpectomy due to failure of the endodontic treatment.



**Fig 4a. Mandibular second primary molar just after completion of the root filling with ZOE. Underfilling of the mesial canals and an inter-radicular radiolucency are evident.**



**Fig 4b. The same tooth 5 years later. Notice new bone filling the pathologic area.**



**Fig 4c. Radiograph of the tooth prior to exfoliation (7 years post treatment)**

The overall success rate for KRI paste was 84% and for ZOE 65%. (Fig 1). This difference was statistically significant ( $P < 0.05$ ). The difference between success rates of first (80.6%) vs. second (72.2%) primary molars was not statistically significant (Fig 2). However, when the first molars were observed separately, it was found that success rates were higher when KRI paste was used (91.3%) than ZOE (50%) ( $P < 0.02$ ).

Maxillary and mandibular molars led to similar success rates, 70.6% and 77%, respectively. Although the success rate of teeth treated with KRI was slightly higher than when ZOE was used in mandibular molars, this difference was not statistically significant. However, the success rate of KRI paste for maxillary molars was significantly higher than that for ZOE ( $P < 0.02$ ).

Fig 3 is a graphic representation of the success rates as related to the quality of the filling. All the teeth filled flush to the apex with KRI paste and 89% of those filled with ZOE were successful. This difference had no statistical significance. Similarly, no difference was observed when the teeth were underfilled with both materials. However, overfilling resulted in a much higher success rate of KRI (79%) than ZOE (41%). This difference had statistical significance ( $P < 0.02$ ).

Figs 4a, 4b, and 4c are radiographs of a mandibular second primary molar successfully treated with ZOE. Notice that despite the apparently normal exfoliation process, some remnants of ZOE can be detected around the bud of the second premolar. This, however was a

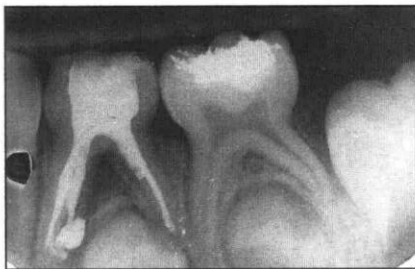


Fig 5a. Mandibular first primary molar extensively overfilled with KRI paste. A pathologic radiolucent area also can be observed.

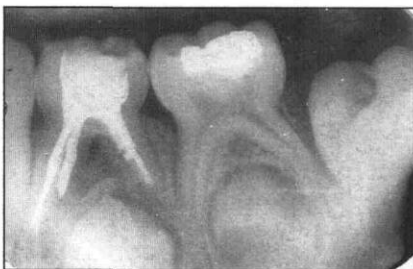

Fig 5b. The same tooth 6 weeks after completion of the root filling. The excess of material has been resorbed but the lesion is still present.

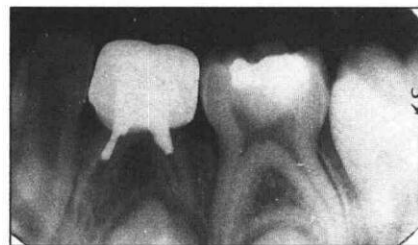

Fig 5c. Extensive resorption of the KRI paste 18 months after treatment. The bone lesion appears almost healed.

rare finding in the study sample. In Figs 5a, 5b, and 5c, the followup of a mandibular first primary molar root treated with KRI paste is presented. It is important to emphasize that despite the initial overfill, the material is resorbed promptly and excessively. This however, did not prevent healing of the bone lesion.

## Discussion

Developmental, morphological, and physiological differences between primary and permanent teeth lead to differences in the rationale for endodontic treatment. While carious pulp exposures in adults frequently are treated by complete endodontic therapy, pulpotomy is the treatment of choice for vital primary teeth with pulp exposure. Pulpotomy is indicated for teeth that have evidence of chronic inflammation or necrosis in the radicular pulp, but is contraindicated in teeth with gross loss of root structure, advanced internal or external resorption, or periapical infection involving the crypt of the succedaneous tooth.<sup>21</sup> The goal of pulpectomy is to maintain primary teeth that would otherwise be lost. This rationale has been questioned by Yacobi et al.<sup>22</sup> who propose pulpectomies for vital primary teeth to eliminate the need for aldehyde-containing compounds currently utilized in pulpotomy techniques. These authors report a success rate of 84% 12 months postoperatively for posterior teeth. These figures are similar to those observed in our study for nonvital primary molars utilizing KRI paste after a more extensive follow-up time.

There is still disagreement among clinicians—although to a lesser extent than in the past—regarding the utility of pulpectomy in primary teeth. Reasons like the variable morphology of primary root canals leading to difficulty in their preparation and the uncertainty relative to the effects of instrumentation, medication, and filling materials on the developing succedaneous teeth dissuade some professionals from using this technique.<sup>23</sup> Behavior management problems, sometimes occurring in pediatric patients, have added to the reluctance among dentists to perform root canal treatments in primary teeth.<sup>24</sup> Despite these problems, most pediatric dentists prefer pulpectomies over ex-

traction and space maintenance. Kopel,<sup>25</sup> in 1985, stated that successful root canal filling of primary teeth is not only highly recommended, but was being successfully accomplished by thousands of dentists. Success rates of ZOE root fillings range from 68.7 to 86.1% (Table 1). These differences may be related more to the pathologic condition of the tooth prior to treatment than to the filling technique per se. The results observed in the present study for ZOE (65% success) resemble those described by Gould<sup>14</sup> (68.7%); the criteria for selection of cases in both studies were similar. A significantly higher success rate (84%) was observed in the present report when teeth with similar pathologic conditions were filled with KRI paste, which resembles that described by Rifkin<sup>2</sup> in 1980 (89%). The superiority of KRI paste might be due to its bactericidal action and its capability of penetrating the tissues, controlling infection in the dentinal walls.<sup>2</sup>

The overall success rates of first and second primary molars were similar for both materials (Fig 2). However, a significantly higher success rate was observed

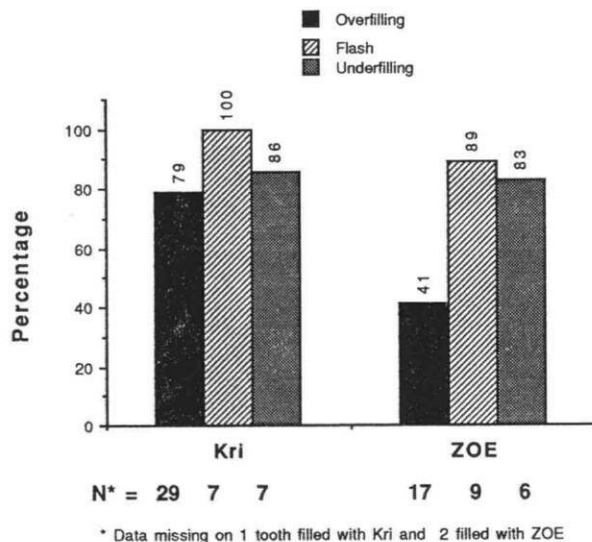


Fig 3. Success rates of root canal fillings according to filling quality.

in first molars filled with KRI paste. As the root morphology of first primary molars is more variable and irregular than that of second molars,<sup>26</sup> filling the canals with a thicker paste as ZOE might be more difficult than with KRI, a softer and smoother paste. Similarly, a significantly higher success rate was seen in maxillary primary molars filled with KRI, when compared to ZOE; this difference is probably due to the same characteristics.

The success rates for both materials were similar in underfilled teeth, and slightly higher for KRI paste when the fillings were flush to the apex (Fig 3). These differences however, were not significant and conflict with those reported by Yacobi et al.<sup>22</sup> for ZOE fillings. These authors indicated that proportionally more underfilled teeth failed than those that were completely filled.

Overfilling with KRI paste led to similar results (79%) to underfilling (86%) with this material (Fig 3). However, overfilling with ZOE resulted in a much lower success rate (41%), and is in agreement with the results of Yacobi et al.<sup>22</sup> They believe that the side effects of extrusion of ZOE beyond the root apex might initiate a foreign body reaction because of the material's irritating effect. Erausquin and Muruzabal<sup>16</sup> observed bone and cementum necrosis that was in contact with extruded ZOE from overfilled canals. They claimed that the excessive material was quickly resorbed however, and the necrotic tissues healed within two weeks.

## Conclusions

Resorption of hardened ZOE may be delayed and cause deflection of the succedaneous tooth.<sup>5, 14, 17</sup> ZOE retention did not occur in the present study; these findings are in agreement with those described by Yacobi et al.<sup>22</sup>

In this study KRI paste presented a higher overall success rate than ZOE. Pulpectomies of first molars, maxillary molars, and cases of overfilling presented a significantly higher success rate when KRI paste was used compared to ZOE. Based on these findings it seems justifiable to recommend KRI paste as a root-filling material for nonvital primary molars.

Dr. Holan is lecturer and Dr. Fuks is professor, Department of Pediatric Dentistry, The Hebrew University—Hadassah Faculty of Dental Medicine. Founded by the Alpha Omega Fraternity, Jerusalem, Israel.

1. Allen KR: Endodontic treatment of primary teeth. *Aust Dent J* 24:347-51, 1979.
2. Rifkin A: A simple, effective, safe technique for the root canal treatment of abscessed primary teeth. *ASDC J Dent Child* 47:435-41, 1980.
3. Goerig AC, Camp JH: Root canal treatment in primary teeth: a

- review. *Pediatr Dent* 5:33-37, 1983.
4. Cullen CL: Endodontic therapy of deciduous teeth. *Compend Contin Educ Dent* 4:302-6, 308, 1983.
5. Garcia-Godoy F: Evaluation of an iodoform paste in root canal therapy for infected primary teeth. *ASDC J Dent Child* 54:30-34, 1987.
6. Duggal MS, Curzon ME: Restoration of the broken down primary molar: 1. pulpectomy technique. *Dent Update* 16:26-28, 1989.
7. Rabinowitch BZ: Pulp management in primary teeth. *Oral Surg Oral Med Oral Pathol* 6:542-50, 671-76, 1953.
8. Castagnola L, Orlay, HG: Treatment of gangrene of the pulp by the Walkhoff method. *Br Dent J* 93:93-102, 1952.
9. Woods RL, Kildea PM, Gabriel SA, Freilich LS: A histologic comparison of Hydron and zinc oxide-eugenol as endodontic filling materials in the primary teeth of dogs. *Oral Surg Oral Med Oral Pathol* 58:82-93, 1984
10. O'Riordan MW, Coll J: Pulpectomy procedure for deciduous teeth with severe pulpal necrosis. *J Am Dent Assoc* 99:480-82, 1979.
11. Coll JA, Josell L, Casper JS: Evaluation of a one-appointment formocresol pulpectomy technique for primary molars. *Pediatr Dent* 7:123-29, 1985.
12. Barr ES, Flaitz CM, Hicks MJ: A retrospective radiographic evaluation of primary molars pulpectomies. *Pediatr Dent* 13:4-9, 1991.
13. Rifkin A: The root canal treatment of abscessed primary teeth — a three to four year follow-up. *ASDC J Dent Child* 49:428-31, 1982.
14. Gould JM: Root canal therapy for infected primary molar teeth — preliminary report. *ASDC J Dent Child* 39:269-73, 1972.
15. Reyes AD, Reina ES: Root canal treatment in necrotic primary molars. *J Pedod* 14:36-39, 1989.
16. Erausquin J, Muruzabal M: Root canal fillings with zinc oxide-eugenol cement in the rat molar. *Oral Surg Oral Med Oral Pathol* 24:547-58, 1967.
17. Spedding RH: Incomplete resorption of resorbable zinc oxide root canal filling in primary teeth: report of two cases. *ASDC J Dent Child* 52:214-16, 1985.
18. Jerrell RG, Ronk SL: Developmental arrest of a succedaneous tooth following pulpectomy in a primary tooth. *J Pedod* 6:337-42, 1982.
19. Walkhoff O: Mein system der med Behandlung schwerer Erkrankungen der Zahnpulpen und des Periodontium. Cited in: Garcia-Godoy F: Evaluation of an iodoform paste in root canal therapy for infected primary teeth. *ASDC J Dent Child* 54:30-34, 1987.
20. Barker BCW, Lockett BC: Endodontic experiments with resorbable paste. *Aust Dent J* 16:364-72, 1971.
21. American Academy of Pediatric Dentistry: Guidelines presented at the annual session, San Antonio, Texas, 1991.
22. Yacobi R, Kenny DJ, Judd PL, Johnston DH: Evolving primary pulp therapy techniques. *J Am Dent Assoc* 122:83-85, 1991.
23. Fuks AB, Eidelman E: Pulp therapy in the primary dentition. *Curr Opin in Dent* 1:556-63, 1991.
24. Tagger E, Sarnat H: Root canal therapy of infected primary teeth. *Acta Odontol Pediatr* 5:63-66, 1984.
25. Kopel HM: Pediatric endodontics. In *Endodontics*, 3rd Ed. JI Ingle and JF Taintor EDS. Philadelphia: Lea and Febiger, 1985, pp 782-809.
26. Hibbard ED, Ireland RL: Morphology of the root canals of the primary molar teeth. *ASDC J Dent Child* 24:250-57, 1957.