

Single-rooted molars in the primary and permanent dentition in two siblings: case report

CASE REPORT

Gideon Holan, DMD Aubrey Chosack, BDS (Rand), MSD

Introduction

Primary and permanent molars are usually multirooted. Maxillary molars usually have three roots and mandibular are double-rooted (DuBrul 1980). A single root was attributed to fusion of roots or deep taurodontism. These roots previously were termed "pyramidal," "cuneiform," "tubular," "cylindrical," "prismatic," and "conical" (Ackerman et al. 1973). Investigators agree that this variation in root form results from failure of invagination of Hertwig's epithelial root sheath (Ackerman et al. 1973).

Fused roots were found in 15 to 22% of second permanent molars and in 19 to 38% of third permanent molars in a study of modern European man. However, only 0.2 to 0.3% of the first permanent molars presented this phenomenon (Ackerman et al. 1973). Taurodont, pyramidal, and fused roots may be variations of a single heritable trait, with the single pyramid-shaped root the most severe expression of this trait (Bixler 1976).

Ackerman et al. (1973) reported a kindred with root formation anomalies and described a 10-year-old boy with pyramidal roots in all primary molars.

The present report describes a case of single-rooted primary and permanent molars and multiple hypodontia in a sister and brother whose unaffected parents are cousins.

Case Report

Case 1

A 9-year-old girl from an Arab town in Israel was referred because of an abscess in the maxillary incisor area. Her medical history included a normal birth following a full-term, normal pregnancy, postnatal development with eruption of the first teeth at age 9 months, and fracture of the left arm at 2 years of age. The child had an elongated face, slightly hairy forehead and temples, and bluish sclera. No hypohydrosis was detected.

Clinical examination revealed signs of a chronic abscess in the maxillary right permanent central incisor, which also had a wide palatal exposure — possibly of iatrogenic origin — of the pulp chamber. Both central incisors had an unusual form. A periapical radiograph of the premaxilla (Fig 1) showed central incisors with incomplete root formation and deep dens invaginatus, but no permanent lateral incisors. All four permanent

canines and the mandibular first permanent molars were present, as were all of the primary molars, except for the mandibular left first molar. The four mandibular primary incisors and the maxillary right primary lateral incisor also were identified clinically. A panoramic radiograph (Fig 2) revealed that the erupted teeth were all that had

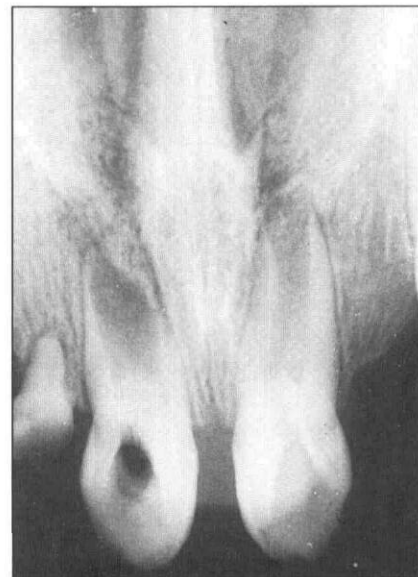

Fig 1. Periapical radiograph of the premaxilla region of Case 1. Notice the deep dens invaginatus in both incisors and the missing permanent lateral incisors.

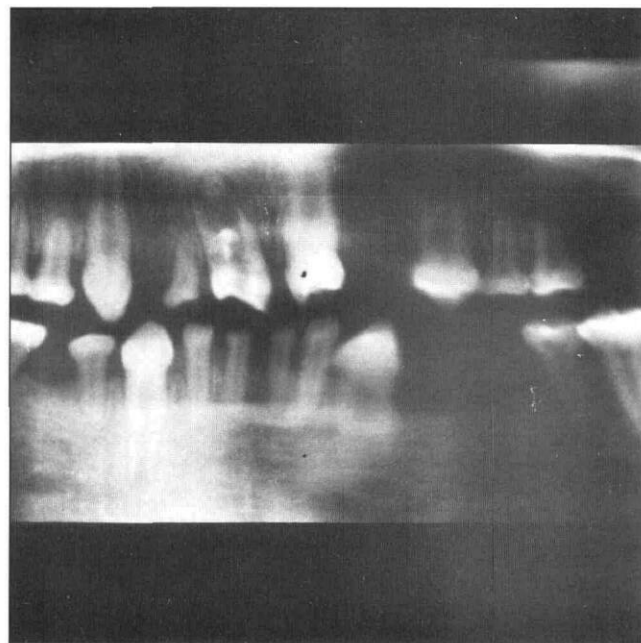


Fig 2. Panoramic radiograph of Case 1. Notice the single-rooted primary and permanent molars and the multiple missing teeth.

developed. All molars, both primary and permanent, were single rooted.

A panoramic radiograph exposed three years previously showed that all the primary incisors were present, but that all four primary canines and the lower left first primary molars were missing at age 6 years.

Case 2

The brother, who was 8 years old, had an uneventful medical history except for a fracture of the left foot at 2 years of age. He was the product of normal birth following a full-term, normal pregnancy, and had developed normally. His primary incisors had erupted at a later age than those of his sister. Wide feet with syndactyly of toes 2 and 3 on both sides were noted. He, too, had a bluish sclera but normal perspiration.

His clinical examination revealed similar dental anomalies, including single-rooted primary and permanent molars, and multiple missing teeth (Figs 3 and 4). He had all his primary teeth except for the four canines. His permanent dentition comprised the maxillary central incisors, canines, and first molars, and mandibular left canine and first molars. The permanent central incisors had dens invaginatus.

Clinical and radiographic examination of the parents revealed normal dentitions without any of their children's dental malformations. The mother had two other unsuccessful pregnancies that ended with spontaneous abortion.

The family history revealed consanguinity. The father and mother were first cousins once removed. The parents were not aware of any similar dental anomalies in their siblings, nephews, or nieces. Unfortunately, investigation of the occurrence of such anomalies in other members of the family was impossible. The family was referred for genetic consultation. The genetic investigation did not detect any of the known syndromes in which hypodontia is a major sign.

Discussion

This case report describes a sister and brother with similar dental anomalies of single-rooted primary and permanent molars, multiple missing teeth, and dens invaginatus of the permanent maxillary central incisors. Both children were caries-free, so the absent primary teeth were most probably congenitally missing. The parents did not remember previous extractions.

The condition of single-rooted molars is extremely rare, especially in the primary dentition. No reports were found in the literature since Ackerman et al. (1973) described the first case of single-rooted primary molars in a 10-year-old child.

Robbins and Keene (1964) described a family with multiple morphologic dental anomalies including conical, unbifurcated posterior roots and dens invaginatus

in the incisors. They suggested that single pyramid-shaped roots in molars were inherited as an autosomal dominant condition.

The major dental anomalies in the present case report were similar to those described by Robbins and Keene (1964), but the pattern of transmission in the family described here suggests an autosomal recessive condition. Both parents of the affected children and possibly other members of the family are heterozygote carriers of the condition. The fact that the parents are close relatives (first cousins once removed) increased the possibility that their children will be homozygotic and have syndromes.

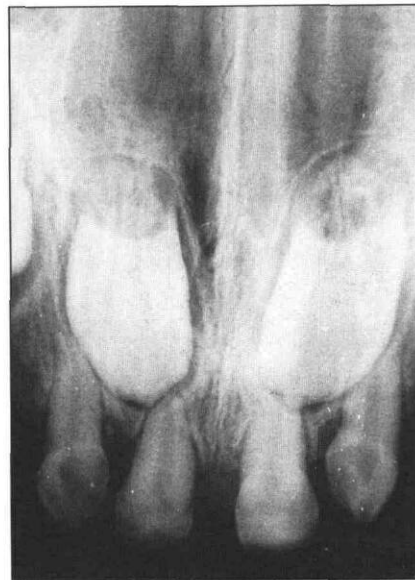

Fig 3. Periapical radiograph of the premaxilla of Case 2. Notice the missing permanent lateral incisors and the dens invaginatus in both teeth.

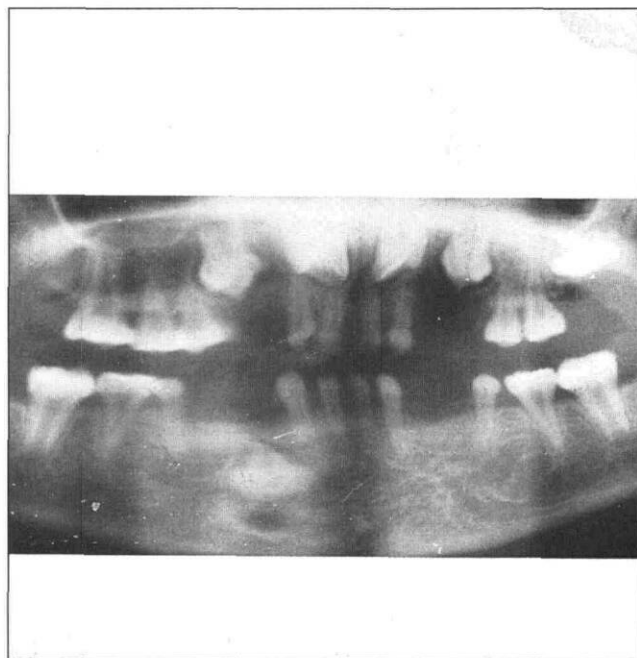


Fig 4. Panoramic radiograph of Case 2. Notice the single-rooted primary and permanent molars and the multiple missing teeth.

Dr. Holan is clinical lecturer and Dr. Chosack is professor, Department of Pediatric Dentistry at The Hebrew University, Hadassah Faculty of Dental Medicine, Jerusalem, Israel. Reprint requests should be sent to Dr. Gideon Holan, Department of Pediatric Dentistry, Hadassah School of Dental Medicine, Post Office Box 1172, Jerusalem, Israel 91010.

Ackerman JL, Ackerman AL, Ackerman AB: Taurodont, pyramidal and fused molar roots associated with other anomalies in a kindred. *Am J Phys Anthropol* 38:681-94, 1973.

Bixler D: Heritable disorders affecting cementum and the periodontal structure, in *Oral Facial Genetics*. Stewart RE, Prescott GH, eds. St Louis: CV Mosby Co, 1976, pp 262-87.

DuBrul EL: *Sicher's Oral Anatomy*. St Louis: CV Mosby Co, 1980, pp 256-66.

Robbins IM, Keene HJ: Multiple morphologic dental anomalies. *Oral Surg* 17:683-90, 1964.

Child care poses less injury risk than home care: telephone survey

A national telephone survey has found children appear to get hurt and poisoned less in child care than at home, according to a study in the July 1991 issue of the American Medical Association's *American Journal of the Diseases of Children*.

Although out-of-home child care may carry an increased risk of infectious disease relative to home care, it does not appear to carry an increased risk of injury and, in fact, may confer a lower risk, according to the study by Walter J. Gunn, PhD, from the Center for Infectious Diseases, Centers for Disease Control, Atlanta, and colleagues.

The researchers conducted a national telephone survey in 1987 because of previous studies which indicated that out-of-home child care may expose children to an excessive risk of injury. Detailed data were collected from 1,775 households that included 2,250 children younger than 5 years old.

Adults who participated in the survey were asked the following questions: "During the past year, have any of your children had an accident or injury that required a visit to a doctor or hospital?" and "During the past year, has there been any incident where you had to contact a doctor or poison control center about a possible poisoning of one of your children?"

Of the 171 reported poisonings in the survey, none occurred during out-of-home child care. The rate of injury during out-of-home child care was 1.69 per 100,000 child-hours, compared with 2.66 per 100,000 child-hours for home care.

The researchers also learned more about when children are most susceptible to injury. Overall injury rates were slightly higher for children enrolled in out-of-home child care than for those who were not. This occurred because children enrolled in out-of-home child care had a higher injury rate during home care than did the children who were not enrolled in out-of-home child care.

Differences in supervision, behavior, and environment may explain why children with any out-of-home care have higher injury rates during home care. After work, parents of children exposed to out-of-home care may have to spend time preparing meals or otherwise managing the home instead of supervising the child. Parents of children in full-time home care may be able to accomplish such tasks while the child naps.

"On release from the structured, controlled, out-of-home care environment, children may exhibit more reckless behavior; the child in full-time home care may exhibit more constant behavior," the researchers suggested.

The researchers also concluded that home care environments of children in out-of-home care may not be as well "child-proofed" as those of children in full-time home care, thus leading to more chances for injury.