

Hemangiopericytoma of the tongue in an 11-year-old girl: case report and literature review

Oscar Hasson, DMD Gina Kirsch, DMD Joshua Lustmann, DMD

Abstract

Hemangiopericytoma is an uncommon vascular tumor of unknown etiology. The tongue is the most common site for this tumor in the oral cavity. Literature review disclosed 20 cases of hemangiopericytoma of the tongue, four of which were in the pediatric population. The treatment of choice is wide surgical excision. This tumor has a high rate of recurrence and often a malignant transformation. The literature is reviewed and an additional case is reported. (Pediatr Dent 16:49–52, 1994)

Introduction

Hemangiopericytoma, first described by Stout and Murray in 1942,¹ is an uncommon vascular neoplasm that occurs rarely in children. This neoplasm is characterized by an abnormal proliferation of pericytes around thin-walled vascular channels and has a predilection for the musculoskeletal system.^{2–5} Clinically, the tumor may occur at any age, with the highest incidence between the third and the sixth decades,^{2–8} and without any sex predilection. According to the literature, this tumor may behave benignly, being well defined, slow growing, painless and firm, and having a normal overlying mucosa.^{2,3,9} The recurrence rate is reported to be more than 50%^{2,7,8} and metastasis ranges from 12 to more than 50%.^{5–8}

The incidence of head and neck hemangiopericytoma in all age groups ranges from 9.4 to 28%.^{2,3,10} In children the head and neck hemangiopericytoma is as frequent as 35%,¹¹ while the highest frequency (46%) is found in infants.¹² Infantile hemangiopericytoma may have a different clinical presentation, mainly multilobulated lesions located in the subcutis—usually with benign behavior.¹²

Approximately 50 cases of hemangiopericytoma in the oral cavity have been described in the literature, 20 of which were located on the tongue (Table).^{7,9–11,13–22} Three of these cases were in children and one was a neonate. Of these cases, only one—a 59-year-old male—was reported to have distant metastasis to the lung.²⁰ We present an additional case of hemangiopericytoma of the tongue in an 11-year-old girl. Its clinical and histological presentation and treatment aspects are described, together with a review of the relevant literature.

Case report

An 11-year-old girl was referred to the Department of Oral & Maxillofacial Surgery, Hadassah School of Dental Medicine, Jerusalem, complaining of a mass on her tongue of six months' duration. On examination a well-defined, firm mass, 0.5 cm in diameter, was seen

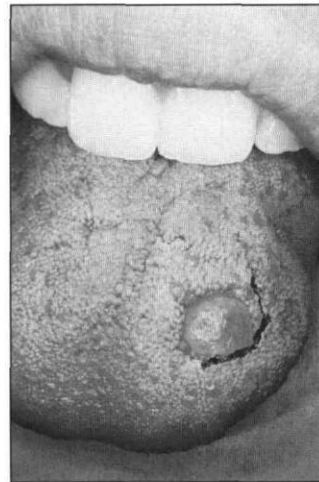


Fig 1. Clinical appearance of the hemangiopericytoma of the tongue. Note the CO₂ laser incision on the left aspect of the lesion.

on the middle third of the tongue's dorsum (Fig 1). The lesion was painless, displaying a normal overlying mucosa. No history of trauma to the tongue was reported. Submandibular lymph nodes were not palpable. The differential diagnosis included a fibroma and granular cell myoblastoma. Under local anesthesia, an excisional biopsy using a CO₂ laser was performed, and then the specimen was evaluated histologically. The gross specimen was a round, firm, purplish brown mass, 7 mm in diameter.

Hematoxylin- and eosin-stained sections showed nodules of tumor tissue separated by collagenous connective tissue septae (Fig 2). There were numerous endothelial-lined vascular channels of varying sizes and shapes, some containing erythrocytes and polymorphonuclear cells (Fig 3). The capillaries were surrounded by a proliferation of round and spindle-shaped cells with round or oval nuclei and various amounts of eosinophilic cytoplasm (Fig 4). No mitoses were observed and no capsule was evident. Silver reticulin staining of the sections blackened the capillary sheaths of the vascular channels, which formed a meshwork around the individual tumor cells (Fig 5). The extravascular position of the tumor cells demonstrated by this stain favored the diagnosis of hemangiopericytoma. As the surgical margins of the specimen were not tumor free, a second excision, using a CO₂ laser with wide safety margins was performed two weeks after the incomplete primary excision. The second specimen was tumor free. Two years after sur-

gery the patient was healthy with no signs of recurrence.

Discussion

The etiology of hemangiopericytoma is still unknown. There is wide variation between histopathological features and clinical behavior. Often, the tumor seems to be encapsulated clinically, although tumor cell infiltration of the capsule wall is detected histologically.

In the differential diagnosis one should take into consideration the glomus tumor, hemangioendothelioma, vascular fibrosarcoma, and leiomyosarcoma.³⁻⁵ The glomus tumor is composed of pericytes showing a defined organoid pattern and—contrary to the hemangiopericytoma—it is a painful tumor that is always benign and encapsulated with no infiltration of the capsule. Silver reticulin stain is used to differentiate hemangiopericytoma from hemangioendothelioma by exposing the neoplastic cells situated within the vascular sheath in the latter case. Van Gieson's stain (trinitrophenol and acid fuchsin) can be used to distinguish the tumor from fibrosarcoma. The cytoplasm of the pericyte stains

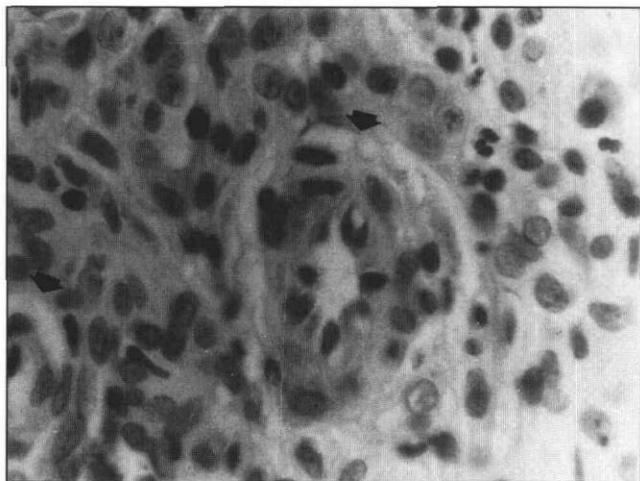


Fig 4. High-power view of plump spindle-shaped tumor cells surrounding blood vessels (arrows) (H&E, 200x).

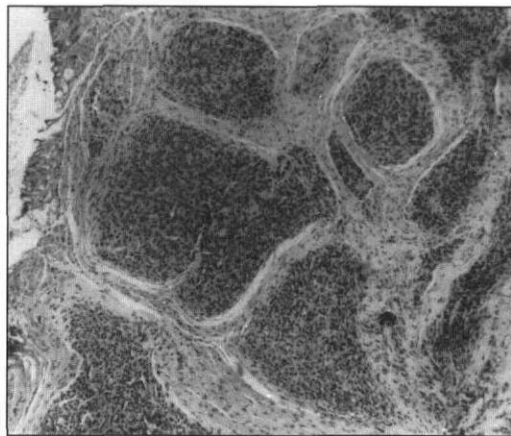


Fig 2. Low-power view of the specimen. Nodules of tumor mass separated by collagenous fibers (H&E, 20x).

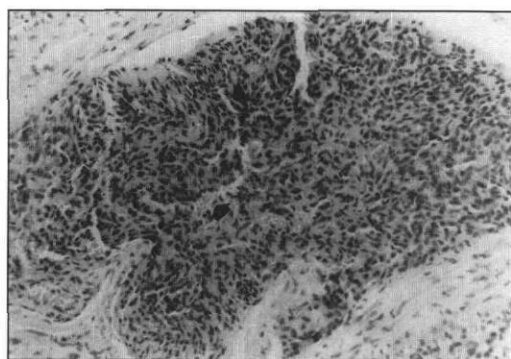


Fig 3. Magnification of one area of the tumor. Slit like endothelial channels (arrows) surrounded by spindle cells and fibrillar stroma (H&E, 35x).

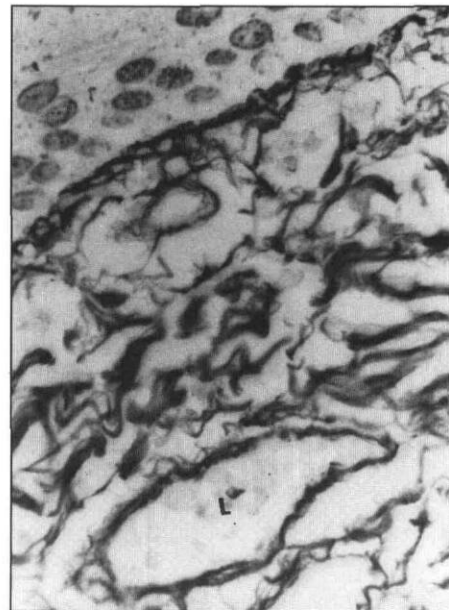


Fig 5. Silver impregnation shows the lumen of the vessel (L). Peripherally the tumor cells are surrounded by reticulin fibers (200x).

light tan and the cells do not form collagen fibers. The differentiation from leiomyosarcoma may be achieved by using the trichrome stain, which eliminates smooth muscle by staining the myofibrils. Final diagnosis of the hemangiopericytoma is made histologically with silver reticulin stain, which displays abundant sheets of neoplastic pericytes lying outside the vascular reticulin sheath. There is usually a moderate proliferation of capillaries surrounded by round or elongated pericytes supported by reticulin fibers. From the histological picture it is impossible to ascertain whether a case is potentially malignant because in this particular tumor, presence or absence of mitoses and anaplastic changes are not proof of malignancy.^{5, 8, 11}

The literature reveals that the tongue is the most common site for the intraoral hemangiopericytoma. In contrast to the high incidence of hemangiopericytoma affecting all organs between the third and sixth decades, and its equal sex distribution, tongue hemangiopericytoma shows an almost identical distribution in all age groups with females affected twice as much as males, and children comprising 23.8% of the cases. In all instances the tumor was presented as a mass or as a painless mass, ranging from 0.5 to more than 5 cm in diameter. The overlying mucosa retained its normal color despite the fact that the tumor is characterized by a proliferation of blood vessels. This phenomenon might be due to the obliteration of the blood vessels caused by the proliferating pericytes. The time span from first notice of the tumor to when the patient

Table. Reported cases of hemangiopericytomas in the tongue

<i>Author</i>	<i>Age</i>	<i>Sex</i>	<i>Clinical Features</i>	<i>Size (cm)</i>	<i>Tumor Presence Before Diagnosis</i>	<i>Treatment</i>	<i>Recurrence</i>
Stout ⁷ (1949)	13	M	Mass	1 x 1	4 months	Excision	Yes, 14 months
Kauffman & Stout ¹¹ (1960)	6	M	Mass	0.3 x 1	—	Excision	No, 6 months
	13	M	Mass	1 x 1	3 months	Excision	Yes, 14 months
Cernea et al. ¹³ (1970)	39	F	Painless mass	—	5 months	Excision	No, 1 year
	56	M	Ulcerated mass	1 x 2	—	Excision	Yes, 4 months
Walike & Bailey ¹⁰ (1971)	64	F	Nonulcerated mass	1 x 1	—	Excision Radiotherapy	Yes, Died 1 mo. after 2nd excision and radiotherapy
Orlian ¹⁴ (1973)	34	F	Painless mass	5.5 x 5.5	3 years	Excision	No, 4 years
Citowicki et al. ¹⁵ (1976)	27	F	Mass	—	—	Excision	Two recurrences No recurrences after 3rd excision
Hary & Safta ¹⁶ (1977)			3 cases			Excision	—
Hisaeda et al. ¹⁷ (1977)	45	F	Painless mass	4 x 4	6 years	Excision	No, 1 year
Brockbank ⁹ (1979)	51	F	Painless mass	1 x 1	2 months	Excision	—
De Rosa et al. ¹⁸ (1983)	24	F	Mass	—	—	Excision	No, 2 years
Kwon et al. ¹⁹ (1984)	29	M	Nonulcerated mass	3 x 2.5	4 years	Excision	No, 1 year
Bertrand et al. ²⁰ (1984)	39	F	Nonulcerated mass	2 x 2	6 months	Excision	No, 12 years
	25	F	Mass	—	—	Excision	No, 5 years
	59	M	Ulcerated mass	3 x 3	—	Excision Radio & chemotherapy	4 Recurrences Died after 3rd year from the tumor
Alpers et al. ²¹ (1984)	•	F	Mass	4 x 4	—	Excision Chemotherapy	Yes, 2 months No recurrence after 2nd excision and chemotherapy
Suceava & Gheorghiu ²² (1989)	31	F	Mass	4.5 x 4.5	—	Excision Radiotherapy	Yes No recurrence after 2nd excision and radiotherapy
Present study 1992	11	F	Painless mass	0.5 x 0.5	6 months	Excision	No, 2 years

• Congenital.

sought medical advice ranged from a few months to six years. In all instances, surgical excision was the treatment of choice.

Though an innocent-looking tumor, it has a high recurrence rate; Stout⁷ found it to be 28%, Hajdu⁸ 29%, and Backwinkel² 52.2%. Malignant change also is common with a range quoted in the literature of 9–60%.^{3,6-8,23} The incidence of metastases may range from 12 to 57%,^{3,5,8} the lungs being the most common site. In our review of tongue hemangiopericytoma, 47% recurrence was reported (eight of 17 cases). In the five cases occurring in children, three cases^{7,11,21} exhibited recurrence. In only one case²⁰ was a distant metastasis to the lung reported.

Treatment following recurrence was mentioned in five cases and consisted of a wide surgical excision, followed either by radiotherapy or chemotherapy. Two patients died from the tumor. Radiotherapy or chemotherapy might be advocated in inoperable cases. Long-term followup to check for any distant metastases, which spread along hematological or lymphatic pathways cannot be overemphasized since there are no specific histological or clinical criteria to assess prognosis.

The potential of the CO₂ laser to seal blood and lymphatic vessels in the line of the surgical incision might play an important role in minimizing spread of tumor cells during surgical intervention, thus minimizing metastases.²⁴ The artifactual distortion of the tissue following the use of the CO₂ laser is restricted to a thin layer of damaged cells in the line of the incision. Such minimal and restricted tissue damage does not compromise the microscopic diagnosis.²⁵

Dr. Hasson is resident, oral and maxillofacial surgery; Dr. Kirsch is resident, oral pathology; and Dr. Lustmann is senior lecturer, oral and maxillofacial surgery, Hebrew University, Hadassah School of Dental Medicine, Jerusalem, Israel.

1. Stout AP, Murray MR: Hemangiopericytoma—a vascular tumour featuring Zimmermann's pericytes. *Ann Surg* 116:26–33, 1942.
2. Backwinkel KD, Diddams JA: Hemangiopericytoma—report of a case and comprehensive review of the literature. *Cancer* 25:896–901, 1970.
3. Enzinger FM, Smith BH: Hemangiopericytoma—an analysis of 106 cases. *Hum Pathol* 7:61–82, 1976.
4. Enzinger FM, Weiss SW: *Soft Tissue Tumors*. 2nd ed. St. Louis: CV Mosby Co., 1988, pp 597, 605–9.
5. Kissane JM, ED: *Anderson's Pathology*. 9th ed. St. Louis: CV Mosby Co. 1990, pp 1888–89.
6. Macmaster MJ, Soule EH, Ivins JC: Hemangiopericytoma—a Clinicopathologic study and long-term followup of 60 patients. *Cancer* 36:2232–44, 1975.
7. Stout AP: Hemangiopericytoma—a study of twenty-five new cases. *Cancer* 2:1027–54, 1949.
8. Hajdu SI: *Pathology of Soft Tissue Tumors*. 1st ed. Philadelphia: Lea & Febiger. 1979, pp 385, 388–92.
9. Brockbank J. Hemangiopericytoma of the oral cavity—report of case and review of the literature. *J Oral Surg* 37:659–64, 1979.
10. Walike JW, Bailey BJ. Head and neck hemangiopericytoma. *Arch Otolaryngol* 93:345–53, 1971.
11. Kauffman SL, Stout AP. Hemangiopericytoma in children. *Cancer* 13:695–710, 1960.
12. Baker DL, Oda D, Myall RWT: Intraoral infantile hemangiopericytoma: literature review and addition of a case. *Oral Surg Oral Med Oral Pathol* 73:596–602, 1992.
13. Cernea P, Brocheriou C, Laudenbach P, Guilbert F, Rouchon C: Deux hemangiopericytomes de la langue. Un hemangiopericytome du front. *Rev Stomatol Chir Maxillofac* 71:435–40, 1970. [French]
14. Orlian AI: Benign hemangiopericytoma of the tongue. *J Oral Surg* 31:936–38, 1973.
15. Citowicki W, Kulczynski B, Bierla I, Sobieszczyk A: Lingual hemangiopericytoma. *Otolaryngol Pol* 30:527–30, 1976. [Polish]
16. Hary M, Safta M: Hemangiopericytoma of the tongue. *Rev Chir Stomatol* 24:127–32, 1977. [Rumanian]
17. Hisaeda K, Wada T, Shirasuna K, et al.: A case of hemangiopericytoma of the tongue. *Jpn J Oral Surg* 23:778–82, 1977. [Japanese]
18. De Rosa G, Donofrio V, Barra E, Percopo G: Tongue metastasis of hemangiopericytoma. *Pathologica* 75:127–32, 1983. [Italian]
19. Kwon HJ, Browne GA, Posalaky IP, Waite DE: Hemangiopericytoma of the tongue—report of case. *J Am Dent Assoc* 109:583–85, 1984.
20. Bertrand JCH, Guilbert F, Vaillant JM, Szpirglas H, Chomette G, Auriol M, Mercier C: Les hemangiopericytomes de la sphere oro-faciale. *Ann Oto-Laryngol (Paris)* 101:607–13, 1984.
21. Alpers CE, Rosenau W, Finkbeiner WE, de Lorimier AA, Kronish D: Congenital (infantile) hemangiopericytoma of the tongue and sublingual region. *Am J Clin Pathol* 81:377–82, 1984.
22. Suceava I, Gheorghiu D: Vascular neoplasm in the ORL organs (anatomic-clinical observations). *Rev Chir Otorinolaringol* 34:149–52, 1989. [Rumanian]
23. Angervall L, Kindblom LG, Nielsen JM, Stener B, Svendsen P: Hemangiopericytoma—a clinicopathologic, angiographic and microangiographic study. *Cancer* 42:2412–27, 1978.
24. Frame JW: Removal of oral soft tissue pathology with the CO₂ laser. *J Oral Maxillofac Surg* 43:850–55, 1985.
25. Lanzafame RJ, Rogers DW, Naim JO, et al.: Reduction of local tumor recurrence by excision with the CO₂ laser. *Lasers Surg Med* 6:439–41, 1986.