

# Delayed tooth eruption in congenital hypertrichosis lanuginosa

Deborah L. Franklin, PhD, MDent Sci, BDS, FDSRCS (Eng), MRCD (C) Graham J. Roberts, MDS, PhD, FDSRCS (Eng), BDS, MPhil

**H**ypertrichosis in childhood is found in a variety of conditions and may be localized or generalized.<sup>1</sup> Localized hypertrichosis may be related to trauma, nevi, or spina bifida occulta. Generalized hypertrichosis can occur with a variety of metabolic, chromosomal, and congenital disorders; these include Gorlin syndrome, Cornelia de Lange syndrome, Leprechaunism, the porphyrias and mucopolysaccharidoses, trisomy 18, gingival hyperplasia with hypertrichosis, and the congenital hypertrichoses. Pre- or postnatal drug exposure with drugs such as glucocorticoids, cyclosporin, and maternal alcohol abuse in pregnancy may also result in hypertrichosis. In the congenital hypertrichoses, excessive hair growth is the primary disorder. The terminology of these disorders has been confused in the past but they have been described as congenital hypertrichosis universalis, transient congenital hypertrichosis universalis, and congenital hypertrichosis lanuginosa.<sup>1</sup>

The present case is one of congenital hypertrichosis lanuginosa in which the body is covered with dense lanugo (fetal) hair at birth, which persists and is constantly renewed throughout life. Congenital hypertrichosis lanuginosa is very rare; a review of the literature in 1969 found reports of only 32 cases.<sup>2</sup> The inheritance is believed to be autosomal dominant with varying expressivity<sup>2-7</sup> and there are several families in which the disorder has been described in more than one generation,<sup>3,5,6</sup> with a four-generation pedigree in one Burmese family.<sup>5</sup> Others have reported excessive hairiness in previous generations,<sup>7</sup> suggesting the idea of varying expressivity. The disorder is primarily an aesthetic one; the lanugo hair is constantly renewed throughout life, but in some cases does appear to diminish with age.<sup>7</sup> The growth of the hair is dense along the back, particularly at the base of the spine, and can block the external nose and external auditory canals, causing apparent deafness. The only parts of the body free from hair are the palms of the hands and soles of the feet. In the past, individuals with extremes of hypertrichosis of all types have been widely exhibited in side-shows and described in terms such as “dog-faced boy”, “the nondescript”, and “human werewolf”.<sup>5,8,9</sup>

Dental anomalies such as neonatal teeth, hypodontia, the presence of supernumerary teeth, and “defects” in the enamel have been reported in association with hypertrichosis lanuginosa.<sup>3,5,7</sup> The present case illustrates delayed eruption of primary and permanent teeth resulting in unusual root morphology of primary molar teeth, and also enamel hypoplasia.

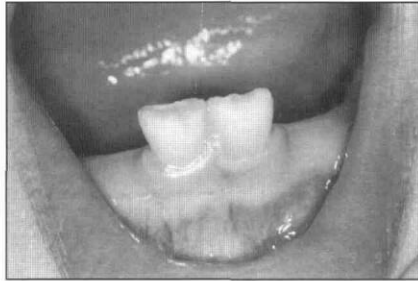
### Case report

A male child was born of unrelated parents following a normal pregnancy and delivery. He was the first born and has an unaffected younger brother. The mother had taken no medication or vitamin/mineral supplements during the pregnancy. The child was covered in dense blonde lanugo hair at birth which was particularly dense around the base of the spine and external auditory canals. The palms of the hands and soles of the feet were free from hair growth. The scalp, eyebrow, and eyelash hair were slightly coarser and darker than that on the rest of the body. At birth, the right cornea was noted to be cloudy as a result of glaucoma; this was treated with a trabeculotomy.<sup>10</sup> During the first year of life much of the hair fell out, but that on the face and ears persisted; this is shaved regularly (Fig 1). There is no known maternal or paternal family history of congenital hypertrichosis lanuginosa. However the parents and younger brother are “quite hairy”, and the mother reports that she has relatives who have a large amount of head hair. Low intelligence and growth retardation have been reported previously in congenital hypertrichosis lanuginosa.<sup>3</sup> The child in our case appears to have normal mental and physical development.

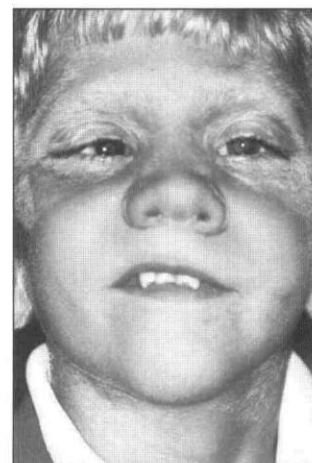

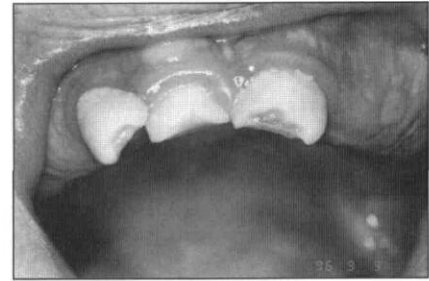Fig 1. Full face illustrating congenital hypertrichosis lanuginosa (the face is shaved regularly).

At the age of 2, no



◀ Fig 2a. Mandibular teeth showing pitting and discoloration of the incisal edges.



▶ Fig 2b. Maxillary teeth showing pitting and discoloration of the incisal edges.

teeth had erupted; the gum pads were normal in appearance but the maxillary pad was noted to be relatively large. By the age of 3-and-a-half the mandibular primary central incisors (71, 81) had erupted (Fig. 2a) and by 5 years the maxillary primary central incisors (51, 61) were present. The child is now 6 years old and the upper right primary lateral incisor (52) has also erupted (Fig 2b). The teeth are chalky white with pitting and brown discoloration of the incisal edges, particularly in the maxilla (Fig 2b); this suggests the possibility of an enamel defect. No treatment has yet been carried out and none is planned in the near future. Although the child appears to have developed normally, both physically and mentally, he is quite shy and reluctant to cope with dental examinations.

The radiographs of the present case confirm the presence of all primary teeth; the permanent incisors, canines, and first molars (Fig 3). The unerupted primary molars are still completely covered in bone. The first permanent molars, particularly on the right side, appear closer to eruption than any primary molars. The roots of the mandibular primary molars are very close to the lower border of the mandible and the mesial and distal roots have become divergent and splayed (Fig 3). The maxillary primary molar roots are unclear on the radiograph. There is evidence that the maxillary second permanent molars are showing signs of mineralization. Between the mandibular primary molars there are triangular areas of altered radiodensity, some of which extend from the alveolar crest to the lower border of the mandible.

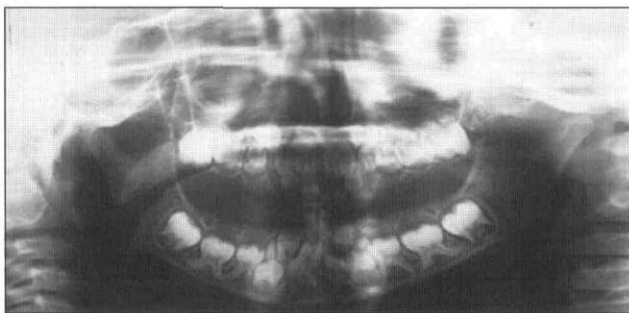


Fig 3. Panoramic radiograph showing unerupted teeth and splaying of deciduous molar roots. Patient cooperation has not yet been sufficient for intraoral radiographs and photographs.

## Discussion

A variety of dental findings have been described in relation to congenital hypertrichosis lanuginosa. These include delayed eruption of permanent teeth, hypodontia, neonatal teeth, microdontia, and the presence of supernumerary teeth.<sup>3, 5, 7</sup> As there have been several reports of hypodontia associated with congenital hypertrichosis lanuginosa, it has been suggested that there may be a hypodontia/congenital hypertrichosis lanuginosa syndrome.<sup>5</sup> It is possible that teeth were present in some of the reported cases but failed to erupt and could have been seen radiographically. One case of congenital hypertrichosis lanuginosa has been described in which there were no apparent dental anomalies.<sup>8</sup>

The present case exhibits delayed eruption of both deciduous and permanent teeth. At the age of 6-and-a-half years only five deciduous teeth have erupted, and no permanent teeth. This is the stage of dental development expected in a child younger than 1 year of age. In the present case, most of the permanent and deciduous teeth are actually present. The teeth, particularly the deciduous molars, have failed to undergo eruptive movement within the alveolar bone. During the intraosseous stage of tooth eruption, bone resorption occurs over the crown of the tooth with bone formation beneath the roots forming an eruption pathway. The dental follicle produces growth factors and enzymes, which initiate much of this tissue turnover.<sup>11</sup> It is possible that the triangular areas of altered radiodensity extending from the alveolar crest to the lower border of the mandible seen in the radiograph of this case represent extensions of the dental follicle. This may be an attempt to form an eruption pathway, which the teeth have failed to follow. This has resulted in splaying of the tooth roots.

There is at present no evidence of the developing premolars and lower second permanent molars. Calcification of the crowns of the premolars is usually completed between the ages of 5 and 7 years and the second permanent molar crowns are often not calcified until the age of 8; it is therefore possible that these teeth may yet develop. Delayed eruption of the permanent teeth has previously been described in a case of congenital hypertrichosis lanuginosa,<sup>2</sup> and delayed tooth eruption occurs in children with other disorders

such as Down syndrome, cleidocranial dysplasia, hypopituitarism, hypothyroidism, and hereditary gingival hyperplasia associated with hypertrichosis. In cleidocranial dysplasia, the deciduous teeth usually erupt normally. In the permanent dentition, the delayed eruption is often related to the numerous supernumerary teeth which may be present. There is no radiographic evidence of developing supernumerary teeth in the present case that may be preventing the eruption of some teeth, but cooperation has not yet been good enough for intraoral radiographs to be taken.

The enamel of the erupted teeth of the present case appears to be hypoplastic. Enamel hypoplasia can occur for a variety of reasons,<sup>12</sup> including disorders affecting the skin like epidermolysis bullosa.<sup>13</sup> Teeth with enamel hypoplasia and other enamel defects such as amelogenesis imperfecta may often be slow to erupt, and may exhibit other eruptive anomalies such as follicular cysts and impactions.<sup>14, 15</sup>

Several cases of hypertrichosis of the terminal hair associated with gingival hyperplasia have been reported,<sup>4, 9, 16, 17</sup> and it has been suggested the two are part of the same disorder. Congenital hypertrichosis lanuginosa does not appear to be associated with gingival hyperplasia. The relatively large maxillary gum pad noted in the present case prior to eruption of the maxillary central incisors is probably insignificant and excess gingiva has been described in association with delayed eruption.<sup>18</sup> As teeth have erupted it has become evident that gingival hyperplasia is not really present. In several of the reports of hypertrichosis of the terminal hair associated with gingival hyperplasia, the gingiva has been excised and the teeth exposed.<sup>16, 17</sup> This type of procedure has also been carried out in other cases of delayed tooth eruption such as cleidocranial dysplasia.<sup>19</sup> At present this is not planned for our patient, and a "watch and wait" strategy is being carried out until such time as the child becomes concerned about his dentition.

The present case was reported soon after the birth of the child, as it is the first in which glaucoma has been reported in conjunction with congenital hypertrichosis lanuginosa.<sup>10</sup> The present report is the first in which the dental findings have been described. Glaucoma has been associated with various skeletal and dental malformations and it may be that there is a relationship between neural crest development and all these disorders.<sup>10</sup> This may have resulted in the delayed tooth eruption described in the present case and the various other dental anomalies described by others.

Dr. Franklin is senior registrar, Paediatric Dentistry, Eastman Dental Hospital and Great Ormond Street Hospital for Children and Dr. Roberts is joint professor of Paediatric Dentistry, Eastman Dental Institute and Great Ormond Street Hospital for Children, London.

## References

1. Baumeister FA, Schwarz HP, Stengel-Rutkowski S: Childhood hypertrichosis: diagnosis and management. *Arch Dis Child* 72:457-59, 1995.
2. Felgenhauer WR: Hypertrichosis lanuginosa universalis. *J Genet Hum* 17:1-44, 1969.
3. Freire-Maia N, Felizali J, de Figueiredo AC, Opitz JM, Parreira M, Maia NA: Hypertrichosis lanuginosa in a mother and son. *Clin Genet* 10:303-306, 1976.
4. Lee IJ, Im SB, Kim DK: Hypertrichosis universalis congenita: a separate entity, or the same disease as gingival fibromatosis? *Pediatr Dermatol* 10:263-66, 1993.
5. Bondeson J, Miles AE: The hairy family of Burma: a four generation pedigree of congenital hypertrichosis lanuginosa. *J R Soc Med* 89:403-408, 1996.
6. Ravin JG, Hodge GP: Hypertrichosis portrayed in art. *JAMA* 207:533-35, 1969.
7. Partridge JW: Congenital hypertrichosis lanuginosa: neonatal shaving. *Arch Dis Child* 62:623-25, 1987.
8. Beighton P: Congenital hypertrichosis lanuginosa. *Arch Dermatol* 101:669-72, 1970.
9. Bondeson J, Miles AEW: Julia Pastrana, the nondescript: an example of congenital generalized hypertrichosis terminalis with gingival hyperplasia. *Am J Med Genet* 47:198-212, 1993.
10. Judge MR, Khaw PT, Rice NS, Christopher A, Holmstrom G, Harper JI: Congenital hypertrichosis lanuginosa and congenital glaucoma. *Br J Dermatol* 124:495-97, 1991.
11. Marks SC Jr: The basic and applied biology of tooth eruption. *Connect Tissue Res* 32:149-57, 1995.
12. Seow WK: Enamel hypoplasia in the primary dentition: a review. *ASDC J Dent Child* 58:441-52, 1991.
13. Scully C: Oral manifestations of disease. *Dent Update* 7:53-60, 1980.
14. Winter GB, Brook AH: Enamel hypoplasia and anomalies of the enamel. *Dent Clin North Am* 19:3-24, 1975.
15. Seow WK: Dental development in amelogenesis imperfecta: a controlled study. *Pediatr Dent* 17:26-30, 1995.
16. Horning GM, Fisher JG, Barker BF, Killoy WJ, Lowe JW: Gingival fibromatosis with hypertrichosis. A case report. *J Periodontol* 56:344-47, 1985.
17. Winter GB, Simpkins MJ: Hypertrichosis with hereditary gingival hyperplasia. *Arch Dis Child* 49:394-99, 1974.
18. Evian CI, Cutler SA, Rosenberg ES, Shah RK: Altered passive eruption: the undiagnosed entity. *J Am Dent Assoc* 124:107-110, 1993.
19. Jensen BL, Kreiborg S: Dental treatment strategies in cleidocranial dysplasia. *Br Dent J* 172:243-47, 1992.