



# Mucosal calcified nodule of the gingiva in an infant

Catherine M. Flaitz, DDS, MS    Michael Milano, DMD

*Dr. Flaitz is professor of oral and maxillofacial pathology and pediatric dentistry, Department of Diagnostic Sciences; Dr. Milano is clinical associate professor, Department of Pediatric Dentistry, and director, Pediatric Dentistry Residency Program, University of Texas at Houston Health Science Center, Houston, Tex. Correspond with Dr. Flaitz at cflaitz@admin4.hsc.uth.tmc.edu*

## Abstract

The mucosal calcified nodule is a rare oral lesion that has a predilection for the young child. This case report describes an infant with a persistent and tender gingival swelling associated with an unerupted, maxillary central incisor. Besides a differential diagnosis for this entity, the causes of abnormal calcium deposits within the skin of children are discussed. (*Pediatr Dent.* 2002;24:337-339)

**KEYWORDS:** ORAL PATHOLOGY, MUCOSAL NODULE, CALCINOSIS CUTIS

The mucosal calcified nodule (MCN) is a recently recognized entity of the oral cavity that represents the idiopathic form of calcinosis cutis.<sup>1-3</sup> By definition, calcinosis cutis is a term used to describe a group of disorders in which there is an abnormal deposit of calcium salts within the tissue.<sup>4</sup> Depending on the primary etiology of the condition, calcinosis cutis is categorized into 4 groups: dystrophic, metastatic, iatrogenic and idiopathic. Besides idiopathic, the potential causes for this aberrant collection of calcified material in the skin or mucosa of children are diverse. Important examples include systemic metabolic disease, autoimmune connective tissue disorders, certain syndromes, local tissue injury, calcification of preexisting tumors and as a consequence of a procedure such as repeated heel sticks.<sup>4</sup> The purpose of this case report is to describe the clinical, radiographic and microscopic features of a mucosal calcified nodule involving the gingiva of a toddler.

## Case history

An 11-month-old Hispanic boy was referred by an emergency room physician for the management of a gingival abscess that had been increasing in size for one month. This healthy and normally developing infant was in the 75<sup>th</sup> percentile for height and weight. The gingival swelling was described as being painful and was nonresponsive to amoxicillin. According to his parents, the lesion was beginning to interfere with eating and drinking. Furthermore, the child was constantly rubbing or hitting the gums with his toys, due to teething problems. Clinical examination revealed a 2X1.5-cm gingival enlargement of the anterior left maxillary alveolar mucosa, which was spongy to palpation

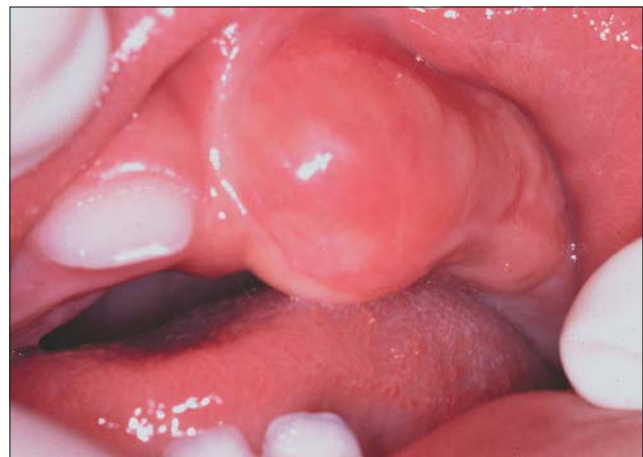

Fig 1. Gingival swelling associated with an unerupted maxillary central incisor

(Fig 1). The mucosal surface was smooth and intact with a pinkish-yellow coloration. No other oral or cutaneous nodules were identified.

An anterior occlusal radiograph revealed a fully developed central incisor that was covered by soft tissue. Adjacent to the crown of the incisor was a fine granular and opaque material that created a halo-like effect that was less dense than the odontogenic tissues (Fig 2). Based on the clinical and radiographic findings, the differential diagnosis included an infected eruption cyst with dystrophic calcification, calcifying odontogenic cyst, developing odontoma and adenomatoid odontogenic tumor.

An excisional biopsy was performed at the emergency appointment because of the perceived discomfort associated

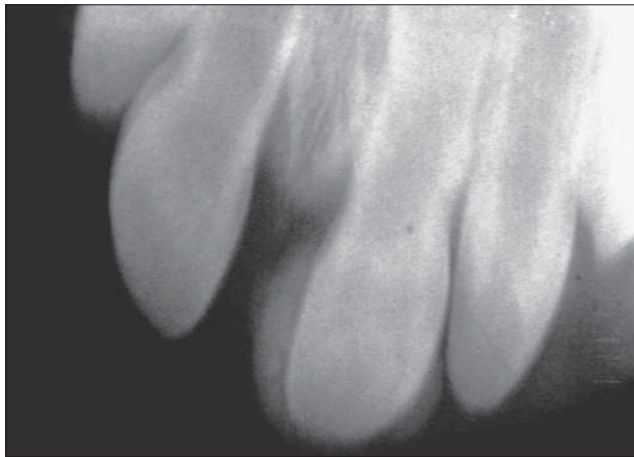


Fig 2. Occlusal radiograph, exhibiting fine, granular opacities around the crown of the central incisor

with this gingival lesion. During the removal of the soft tissue, a chalky white material was discharged. The primary central incisor was exposed, demonstrating a normal-appearing crown, and the surrounding tissues were curetted to remove the gritty substance. All tissue was submitted for histopathologic examination and the surgical site was allowed to heal by secondary intention.

Microscopic examination revealed a surgical ellipse of alveolar mucosa with pools of basophilic calcified material in the underlying connective tissue (Fig 3). Adjacent to the calcified product, a foreign body reaction was observed with macrophages and multinucleated giant cells in the stroma. There was no evidence of an epithelial lining associated with this lesion and only isolated rests of odontogenic epithelium were noted in the connective tissue. The diagnosis of mucosal calcified nodule was rendered based on the clinical and histopathologic findings.

The surgical site healed uneventfully after 2 weeks and the aggressive teething behaviors subsided. Based on the diagnosis, a referral for serum calcium, inorganic phosphate and alkaline phosphatase studies was requested and no abnormalities were found.

## Discussion

The MCN is a recently recognized form of calcinosis cutis of unknown pathogenesis. Including the present case, only 6 examples of a MCN are identified in the literature, all of which are diagnosed in the first 2 decades of life with a male predilection (2:1).<sup>1-3,5</sup> The age range varies from 5 months to 19 years old with only one case diagnosed after the age of 6.<sup>5</sup> There is an equal distribution of these nodules on the anterior maxillary gingiva, dorsal tongue and palatal mucosa. Clinically, this oral lesion presents as a firm to hard nodule with a smooth, pink to pinkish-yellow surface, ranging in size from 1 to 2 cm. Typically, the MCN has a slow growth rate and is asymptomatic.

However, both cases that involved the gingiva resulted in either displacement or delayed eruption of the teeth. Excisional biopsy is the recommended treatment and a

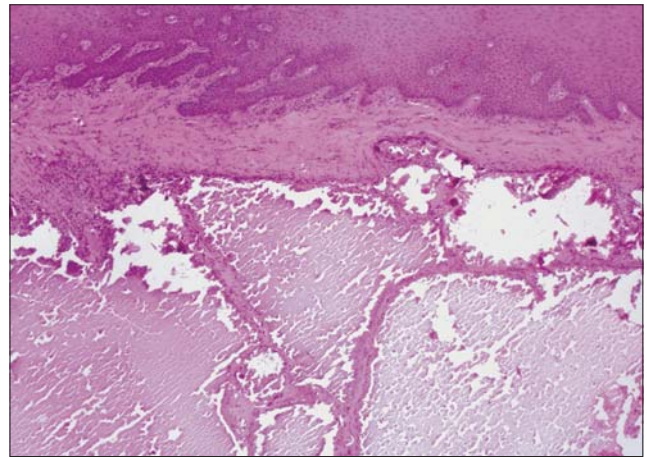


Fig 3. Gingival lesion shows pools of calcifying matrix in a fibrous connective tissue surrounded by a foreign body reaction (Hematoxylin-eosin stain; original magnification X40)

history of recurrence has not been reported. Furthermore, it is speculated that spontaneous resolution may occur in some lesions if the calcified material is expelled through an ulcerated surface mucosa.<sup>1</sup>

When comparing the MCN to the oral counterpart of the cutaneous lesion—the subepidermal calcified nodule (SCN)—many similarities exist. The cause of this uncommon skin lesion is unknown but several hypotheses exist, including calcification of a hamartoma, nevus or viral wart; calcification in fat necrosis, milium or adnexal structures; degranulation of mast cells with secondary calcification; and traumatic calcification secondary to repetitive irritation or dermal injury.<sup>6,7</sup> Similar to the oral counterpart, this cutaneous lesion occurs most frequently in children with a 2:1 male predilection. Occasional examples of congenital lesions are found. The head and neck region, especially the face and ears, is the most commonly affected site.<sup>4,6</sup> Most skin lesions present as a solitary, yellow to red, firm nodule with a smooth, papillary or ulcerated surface. These persistent nodules measure less than 1 cm in size and respond well to surgical excision. Connective tissue disease or calcium and phosphorus abnormalities are not observed with this entity.

## Differential diagnosis

Odontogenic lesions are the primary consideration when there is delayed eruption of a tooth with an overlying gingival swelling. The eruption cyst presents as a soft, fluctuant enlargement around the crown of an unerupted primary or permanent tooth. Typically, it is translucent to bluish purple in color due to the thinness of the mucosa and bleeding into the tissues, although there are some examples that are red or amber in color. Occasionally, these cystic lesions become secondarily infected due to microtrauma and invasion of normal oral flora into the follicular space. Most eruption cysts rupture due to trauma and spontaneously resolve without surgical intervention. Except for an enlarged follicular space with extension into the soft tissues, no other radiographic findings are noted.

The developing odontoma, calcifying odontogenic cyst and adenomatoid odontogenic tumor are lesions that are also found in children. In general, all of these intrabony entities are nontender and characterized by minimal to moderate expansion, delayed eruption of teeth and a predilection for the anterior region of the maxilla and mandible. The radiographic features include a well-defined, unilocular radiolucency around the crown of a tooth with varying amounts of calcifications. Both the odontoma and calcifying odontogenic cyst demonstrate irregular calcifications or tooth-like structures, while the adenomatoid odontogenic tumor is associated with fine opaque flecks.

#### Pediatric significance

It is uncertain how common a MCN is because it does not have clinically distinct features, except for the presence of a chalky white, gritty material, which resembles a purulent exudate. If a mucosal injury or preexisting oral lesion predisposes a child to this type of lesion, as suspected in skin lesions,<sup>6</sup> the MCN should be observed more frequently. It is possible that this entity is more common, but due to constant trauma of the oral mucosa, most lesions resolve spontaneously following the expulsion of the calcified granules.<sup>1</sup>

Of importance, the group of disorders described as calcinosis cutis represents a wide range of localized and systemic conditions that may require additional laboratory studies for diagnosis.<sup>4</sup> This is particularly true if a multifocal pattern is observed, since connective tissue diseases, such as juvenile dermatomyositis,<sup>8</sup> or metabolic diseases<sup>9</sup>—including hyperparathyroidism, hypercalcemia or hyperphosphatemia—produce similar cutaneous and oral lesions. In addition, certain genetic conditions such as Down syndrome, Ehlers-Danlos syndrome, Werner syndrome and Rothmund-Thompson syndrome are at increased risk for these calcified nodules.<sup>4</sup>

This case report is unique because it is the first time that radiographic findings associated with this entity have been

described. The fine, fuzzy pattern of calcification surrounding the crown of a tooth is an unusual radiographic finding that may be interpreted as slight movement during the taking of the film. It is this unusual radiographic finding that prompted the excision of the lesion, along with the submission of the tissue for histopathologic evaluation.

#### References

1. El-Mofty SK, Santa Cruz D. Mucosal calcified nodule. The oral counterpart of the subepidermal calcified nodule. *Oral Surg Oral Med Oral Pathol.* 1992;73:472-475.
2. Afzal MN, Dancea S, de Nanassy J. Mucosal calcified nodule of the hard palate in an infant: case report and review of the literature. *Pediatr Pathol Lab Med.* 1997;17:611-615.
3. Demsar WJ, Williams SB. Palatal mucosal calcified nodule: case report and review of the literature. Essay Program #27. Proceedings from the American Academy of Oral & Maxillofacial Pathology Annual Meeting, New Orleans, LA. April 2002.
4. Nunley JR, Jones LME. Calcinosis cutis. *eMedicine Journal.* 2001;2(11):1-16. [www.emedicine.com/derm/topic66.htm](http://www.emedicine.com/derm/topic66.htm). Accessed March 23, 2002.
5. Abdelkader M, Johnston A, Wilson K. Idiopathic calcinosis of the tongue. *J Laryngol Otol.* 2000;114:548.
6. Evans MJ, Blessing K, Gray ES. Subepidermal calcified nodule in children: a clinicopathologic study of 21 cases. *Pediatr Dermatol.* 1995;12:307-310.
7. Nico MMS, Bergonse FN. Subepidermal calcified nodule: report of two cases and review of the literature. *Pediatr Dermatol.* 2001;18:227-229.
8. Sanger RG, Kirby JW. The oral and facial manifestations of dermatomyositis with calcinosis. *Oral Surg Oral Med Oral Pathol.* 1973;35:476-488.
9. Marinho ROM, Anderson GP, Warren AY. Tumoral calcinosis in the premaxillary region. *Oral Surg Oral Med Oral Pathol Oral Radiol Endod.* 1999;87:725-729.