

# Indirect pulp treatment: in vivo outcomes of an adhesive resin system vs calcium hydroxide for protection of the dentin-pulp complex

Caline A. Falster, DDS Fernando B. Araujo, DDS, MS, PhD Lloyd H. Straffon, DDS, MS Jacques E. Nör, DDS, MS, PhD  
Dr. Falster is a postgraduate student, and Dr. Araujo is associate professor, Department of Pediatric Dentistry, School of Dentistry, Universidade Federal do Rio Grande do Sul, Brazil; Dr. Straffon is professor, Department of Orthodontics and Pediatric Dentistry, and Dr. Nör is assistant professor, Department of Cariology, Restorative Sciences and Endodontics, School of Dentistry, University of Michigan, Ann Arbor, Mich.  
Correspond with Dr. Nör at [jenor@umich.edu](mailto:jenor@umich.edu)

## Abstract

**Purpose:** The purpose of this prospective and randomized in vivo study was to compare the clinical and radiographic outcomes of an adhesive resin system vs a calcium hydroxide liner for protection of the dentin-pulp complex of primary molars treated with indirect pulp treatment.

**Methods:** Forty-eight primary molars with deep occlusal caries, but without preoperative signs and symptoms of irreversible pulpitis, received indirect pulp treatment and were restored with a composite resin (Z100). The teeth were randomly divided into 2 groups according to the material used for protection of the dentin-pulp complex: (1) adhesive resin system (Scotchbond MultiPurpose); and (2) calcium hydroxide liner (Dycal). These teeth were evaluated clinically and radiographically for 2 years.

**Results:** After 2 years, 83% (19/23) of the teeth treated with calcium hydroxide and 96% (24/25) of teeth treated with only the adhesive resin system presented a successful outcome, as determined by clinical and radiographic examination. Interradicular and/or periapical lesions were the most predominant signs of treatment failure, since 3 out of 23 teeth treated with calcium hydroxide and 1 out of 25 teeth treated with only adhesive resin presented this outcome. One tooth treated with the calcium hydroxide liner was diagnosed with internal root resorption at the 18-month examination. Of the 5 teeth diagnosed from radiographs as a failure of the indirect pulp treatment, none presented clinical signs/symptoms of pulpitis or necrosis such as the presence of fistula, enhanced tooth mobility, or pain.

**Conclusions:** This study demonstrates that protection of the dentin-pulp complex of primary molars with an adhesive resin system results in similar clinical and radiographic 2-year outcomes as compared to calcium hydroxide when indirect pulp treatment is performed in Class I composite restorations. (*Pediatr Dent* 24:241-248, 2002)

**KEYWORDS:** INDIRECT PULP TREATMENT, PRIMARY TEETH, ADHESIVE RESIN, CALCIUM HYDROXIDE

Received August 7, 2001 Revision Accepted February 26, 2002

Indirect pulp treatment is defined as the procedure in which the non-remineralisable carious tissue is removed and a thin layer of caries is left at the deepest sites of the cavity preparation where complete caries removal would result in pulp exposure.<sup>1,2</sup> Importantly, the complete removal of all carious tissues from the lateral walls of the cavity preparation is an absolute requirement for the improvement of the restorative material/tooth structure interfacial seal and for allowing adequate control of microleakage.<sup>3,4</sup> Under this circumstance, residual bacteria will be isolated from nutrient

sources, stop proliferating, and die.<sup>1,5-10</sup> Most patients that receive indirect pulp treatment experience a decrease or complete absence of postoperative pain,<sup>11-13</sup> and several clinical trials have demonstrated a high prevalence of successful outcomes.<sup>10,11,14,15</sup>

The indication for indirect pulp treatment is limited to teeth that have no signs of irreversible pulp pathologies based on a thorough clinical and radiographic examination and a direct evaluation of the cavity preparation.<sup>3,16-18</sup> Fistulas, swelling of the periodontal tissues, or enhanced mobility that

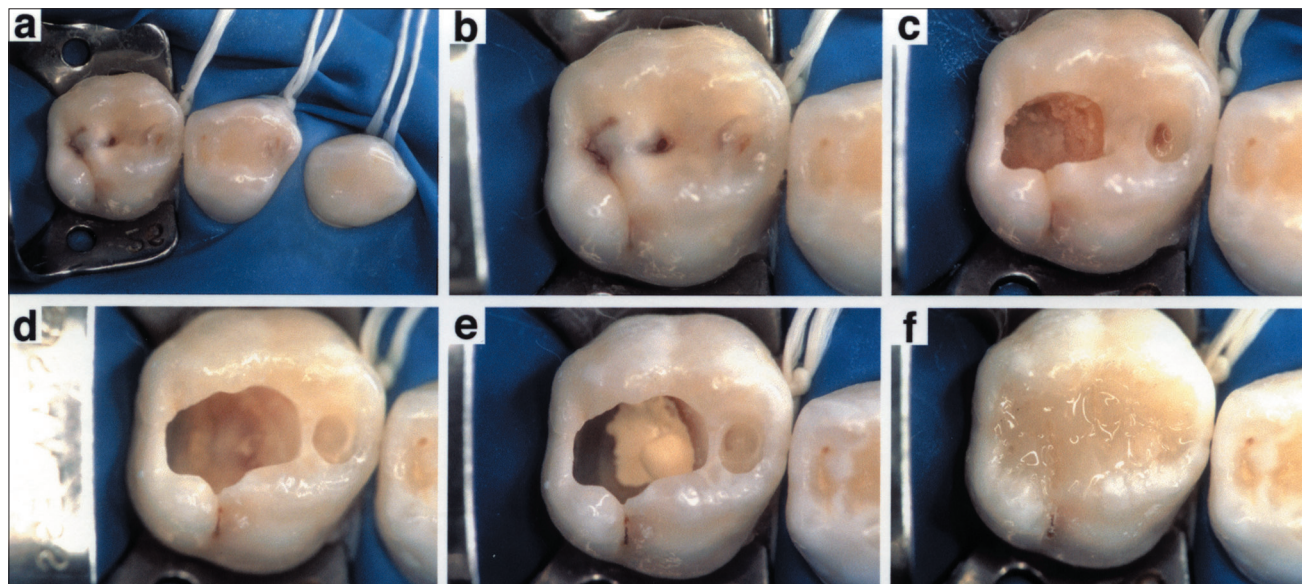


Fig 1. Clinical photographs depicting the technique used for indirect pulp treatment and restoration with composite resin. Rubber dam isolation of maxillary right quadrant (a); close-up view of tooth A (second primary molar, upper right quadrant) (b); initial opening of the cavity preparation depicting extensive caries lesion (c); final cavity preparation for indirect pulp treatment (caries was not completely removed at sites nearest to the pulp) (d); placement of a layer of the calcium hydroxide liner Dycal (e); final restoration with the composite resin Z100 followed by the application of Fortify (f).

cannot be explained by the exfoliation process contraindicate the indirect pulp treatment.<sup>3,16-18</sup> Radiographically, the diagnosis of interradicular or periapical radiolucencies or internal/external root resorption that is not related to the normal exfoliation process also contraindicate the indirect pulp treatment. The clinical evaluation of the carious tissue during the caries removal step is important, since the status of the dentin that is not removed may impact the outcome of the indirect pulp treatment.<sup>17,19</sup>

The indirect pulp treatment and the definitive restoration of the tooth can be performed in one appointment.<sup>7,14</sup> This recommendation is based on data from previous studies that evaluated teeth that received indirect pulp treatment and have been reopened. These studies demonstrated that the dentin left is mostly remineralized and hardened, and no signs of caries progression were found in the absence of microleakage.<sup>1,20-23</sup> Importantly, the reopening of the restoration for complete caries removal in a second appointment might result in an unnecessary risk for pulp exposure.<sup>3,20,21</sup>

The conventional technique for indirect pulp treatment involves the application of a bacteriostatic/bactericidal liner, such as calcium hydroxide, over the carious dentin to induce remineralization and protect the pulp.<sup>1,2</sup> The application of an acidic conditioner to both enamel and dentin does not lead to

irreversible pulp pathologies if the remaining dentin thickness is at least 0.5 mm and no pulp exposure is present.<sup>24,25</sup> Furthermore, it has been previously shown that the acidic pH of conditioners results in a significant decrease in bacterial contamination of the remaining tooth structure.<sup>26</sup>

However, the outcome of indirect pulp treatment using the total-etch technique with 10% phosphoric acid, followed by the application of an adhesive resin system over the carious dentin and restoration with a composite resin in primary molars, remains to be determined. The purpose of this randomized and prospective in vivo study was to compare the clinical and radiographic outcome of primary molars treated with the indirect pulp treatment when either a calcium hydroxide liner or only an adhesive resin system was used for protection of the dentin-pulp complex.

**Table 1. Outcomes of Indirect Pulp Treatment in Primary Molars According to Material Used for Pulp Protection and the Diagnosis Treatment Failure**

	Calcium hydroxide (n=23)			Adhesive resin system (n=25)		
	Clinical	Radiographic		Clinical	Radiographic	
		Periapical lesion*	Pathologic root resorption		Periapical lesion**	Pathologic root resorption
3 months	0/23(0)	0/23(0)	0/23(0)	0/25(0)	0/25(0)	0/25(0)
6 months	0/23(0)	0/23(0)	0/23(0)	0/25(0)	0/25(0)	0/25(0)
12 months	0/23(0)	1/23(4)	0/23(0)	0/25(0)	0/25(0)	0/25(0)
18 months	0/23(0)	2/23(9)	1/23(4)	0/25(0)	1/25(4)	0/25(0)
24 months	0/23(0)	3/23(13)	1/23(4)	0/25(0)	1/25(4)	0/25(0)
Total	0/23(0)	3/23(13)	1/23(4)	0/25(0)	1/25(4)	0/25(0)

\*Data is presented as the cumulative number and percentage (in parenthesis) of treatment failure as a function of time

\*\*Interradicular and periapical lesions were pooled in one group

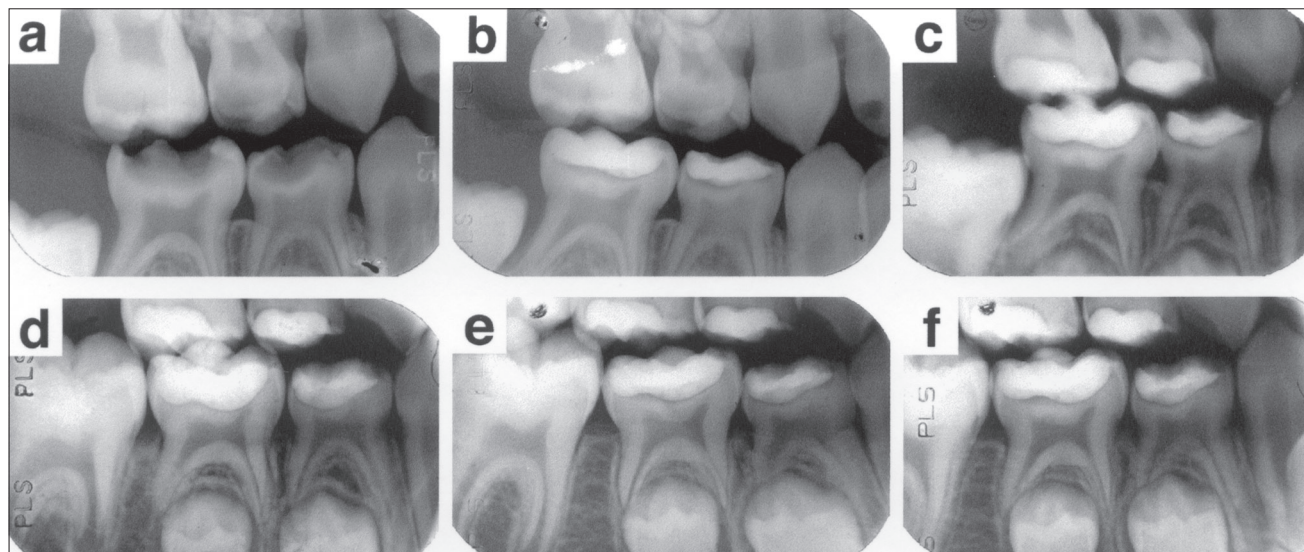


Fig 2. Radiographic evaluation of a mandibular first and second primary molar that received indirect pulp treatment with adhesive resin only and were considered successful outcomes after 2 years. Preoperative radiograph (a), immediate postoperative (b), and 6 months (c), 12 months (d), 18 months (e) and 24 months (f) after indirect pulp treatment.

### Methods

Primary molars from 3- to 5-year-old children were treated with the indirect pulp treatment and evaluated for 24 months. These children presented with a high caries activity at the beginning of their treatment. Therefore, they were included in a preventive/therapeutic program that was based on the orientation for oral health, extraction of unrestorable teeth, restoration of cavitated carious lesions and pulp treatments as necessary, and professional application of topical fluoride at regular intervals, as determined by the caries risk assessment.

The inclusion criteria for this study were: (1) active carious lesion in deep dentin limited to the occlusal surface of primary molars; (2) absence of cavitated lesions at the buccal or lingual surfaces and at the interproximal surfaces, as

determined by clinical and radiographic examination; (3) absence of clinical diagnosis of pulp exposure, fistula, swelling of periodontal tissues, and abnormal tooth mobility; (4) absence of clinical symptoms of irreversible pulpitis, such as spontaneous pain or sensitivity to pressure; (5) the extension of the carious lesion should be such that complete caries removal would risk pulp exposure, as determined by clinical and radiographic assessment; (6) absence of radiolucencies at the interradicular or periapical regions, or thickening of the periodontal spaces, that would indicate the presence of irreversible pulp pathologies or necrosis; (7) absence of internal or external root resorption; (8) only children that were 3-5 years old at the time of first appointment, male or female, and in good general health were included; (9) patients were only included if the parents/legal guardians had read

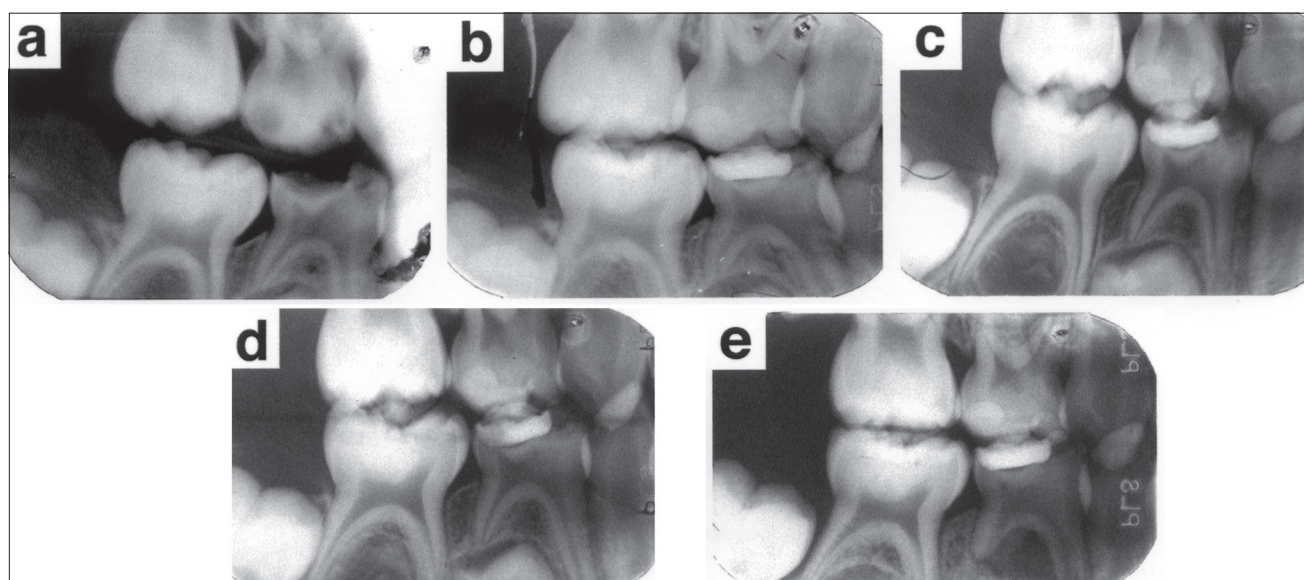


Fig 3. Radiographic evaluation of a mandibular first primary molar that received indirect pulp treatment with adhesive resin only and was considered a failure after 18 months. Preoperative radiograph (a), immediate postoperative (b), and 6 months (c), 12 months (d) and 18 months (e) after indirect pulp treatment. The interradicular lesion accompanied by external and internal root resorption observed in panel (e) was indicative of treatment failure.

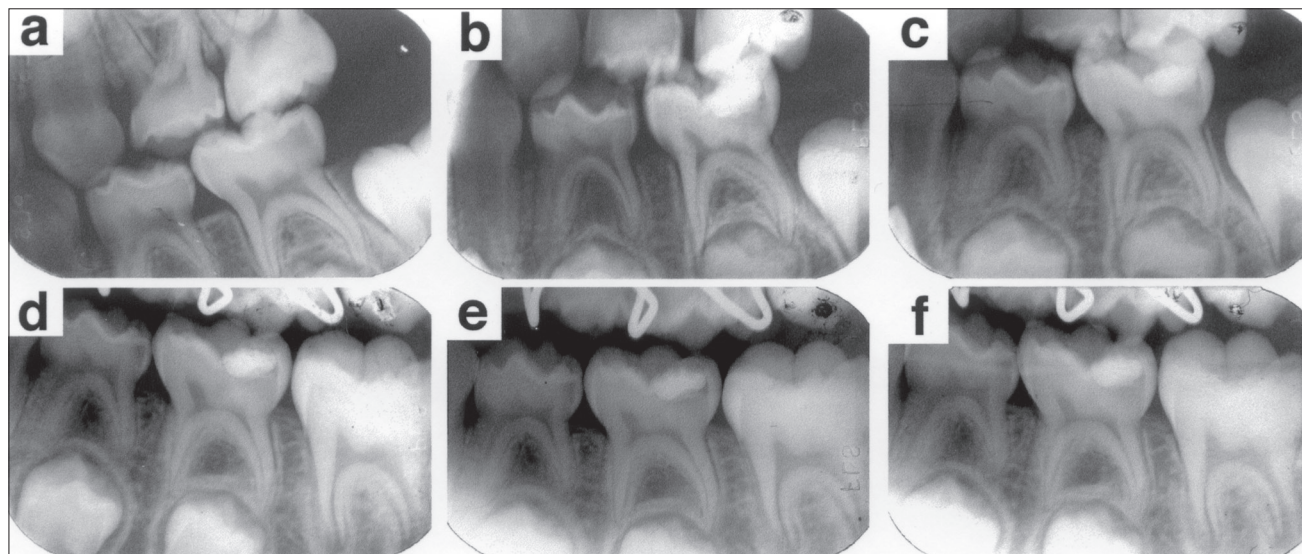


Fig 4. Radiographic evaluation of a mandibular second primary molar that received indirect pulp treatment with calcium hydroxide and was considered a successful outcome after 2 years. Preoperative radiograph (a), immediate postoperative (b) and 6 months (c), 12 months (d), 18 months (e) and 24 months (f) after indirect pulp treatment.

and signed an informed consent form for this study. The design of this study and the consent forms were reviewed and approved by the ethics committee.

The methods used for this investigation were as follows: All patients received prophylaxis prior to the clinical examination. Standardized periapical and posterior bitewings were taken and evaluated to complete the assessment for inclusion in the study. In a follow-up appointment, the patients were anesthetized, and rubber dam isolation was performed by quadrants. Class I cavity preparations and pulp protection were performed as follows (Fig 1). Undermined enamel was removed with carbide bur #245 at high-speed with copious air/water spray. Caries was removed completely from the cavosurface margins and all lateral walls of the cavity preparation with carbide burs #2 to #8 at low speed. Caries removal at the site of "risk for pulp exposure" was performed with a #6 or #8 carbide bur at low speed, and the cavity was thoroughly rinsed with phosphate-buffered saline (pH 7.4). Teeth were excluded from the study if an accidental pulp exposure has occurred or if the caries was completely removed at the end of cavity preparation.

Teeth were randomly assigned for the experimental (25 first and second primary molars) or control groups (23 first and second primary molars) as soon as the parents signed the consent form (ie, before the beginning of treatment). In the experimental group, the total-etch technique was performed by applying 10% phosphoric acid gel (Bisco, Itasca, IL) for 15 seconds to the cavity. The acid was removed by rinsing with water for 15 seconds and the cavity was gently dried with air and cotton pellets.

The adhesive resin system Scotchbond MultiPurpose (3M, Minneapolis, MN) was applied to the entire cavity as instructed by the manufacturer. All teeth were restored with the composite resin Z100 (3M) using the incremental technique, and each increment was polymerized for 40 seconds. After the polymerization of the last increment, the entire

restoration received an additional 60 seconds of light-curing, and standard techniques for finishing and polishing composite resins were employed. Reetching of the finished composite surface and reseal of the margins with Fortify (Bisco) was performed in all teeth to minimize microleakage. The rubber dam was then removed and the occlusion checked. In the control group, a 1-1.5 mm thick layer of the calcium hydroxide liner (Dycal, Dentsply, Milford, DE) was applied to the carious dentin. The cavity preparation was etched with 10% phosphoric acid (Bisco). In the event of partial loss of the calcium hydroxide liner during etching and rinsing procedures, the lost area was replaced with a new layer of Dycal (Dentsply). The remaining procedures for bonding with Scotchbond MultiPurpose (3M) and restoration with the composite resin Z100 (3M) were performed with the same technique as described for the experimental group. Immediately after completion of the restoration, a postoperative periapical radiograph was taken for each tooth. One operator (CAF) performed all the indirect pulp treatments, restorations, and radiographs included in this study.

The teeth included in the study were examined at 15 days, 1, 3, 6, 9, 12, 18 and 24 months after restoration, but follow-up periapical radiographs were only taken at the 6, 12, 18 and 24 month recalls. These teeth were not reopened for evaluation of the status of the remaining carious dentin. The criteria used for determination of clinical and radiographic successful outcome of the indirect pulp treatment were: (1) absence of spontaneous pain and/or sensitivity to pressure; (2) absence of fistula, edema, and/or abnormal mobility; (3) absence of radiolucencies at the interradiolar and/or periapical regions, as determined by periapical radiographs; (4) absence of internal or external root resorption that was not compatible with the expected resorption due to the exfoliation process. Any tooth that presented clinical or radiographic signs or symptoms of irreversible pulp pathologies or necrosis was either pulpectomized or extracted and

recorded as treatment failure. Two calibrated operators (CAF, and FBA) performed the clinical and radiographic follow-up examinations, and a consensus was reached between them to determine if the tooth in question presented a successful or unsuccessful outcome of the indirect pulp treatment.

### Statistical analysis

The data obtained was analyzed by Fisher exact test to examine the effect of the pulp protection method used (calcium hydroxide or adhesive resin system) in each time period evaluated (6, 12, 18 or 24 months) on the outcome of primary molars treated by indirect pulp treatment. The statistical significance of the data was determined at  $P \leq 0.05$ . The software used for these analyses was SigmaStat 2.0 (SPSS Science, Chicago, IL).

### Results

In general, the clinical and radiographic outcome of the indirect pulp treatment in primary molars restored with composite resins was considered satisfactory. Ninety-six percent of the teeth treated with only the total-etch technique followed by the application of adhesive resin (experimental group) and 83% of the teeth that received a calcium hydroxide liner before application of the adhesive resin (control group) were considered successful after 24 months (Table 1, Figs 2 and 4). While these results showed a favorable tendency for the indirect pulp-capping treatment without the use of a calcium hydroxide liner, the difference between the two conditions was not significant ( $P=0.180$ ). Only one tooth was considered a failure in the first 12 months of this study, whereas the majority of the failures happened at 18-24 months after treatment (Table 1). When both groups were pooled and evaluated together, the overall

success rate of indirect pulp capping was approximately 90% (43/48 teeth) after 2 years.

The technique used for cavity preparation and restoration with composite resin is depicted in Fig 1. In this clinical case, a tooth from the control group is shown in which the pulp protection was performed with calcium hydroxide liner followed by the total-etch technique, application of the adhesive resin system and restoration with composite resin. In the experimental group, all clinical steps were the same, except that a layer of calcium hydroxide was not applied before etching and bonding of the composite restoration. The composite resin Z100 was used to restore all teeth after indirect pulp treatment.

None of the teeth included in this study was considered a failure based on the clinical examination. There was no report of postoperative pain that was indicative of irreversible pulp pathology, and none of the patients presented with a fistula, swelling of periodontal tissues, or enhanced tooth mobility (Table 1). The radiographic examination revealed the presence of interradicular and/or periapical lesions, which indicated that most failures of indirect pulp treatment were due to pulp necrosis (Figs 3 and 5). However, the incidence ( $P=0.338$ ) of interradicular and/or periapical radiolucencies in the adhesive resin group (1/25) was similar to the calcium hydroxide group (3/23; Table 1). Only one tooth was diagnosed with internal root resorption, and it belonged to the group treated with calcium hydroxide (Table 1).

To evaluate the incidence of failures of indirect pulp capping according to the tooth, the number of failures in first vs second primary molars were compared. The single treatment failure in the adhesive resin group was in a first primary molar. In the calcium hydroxide control group, all failures occurred in second primary molars.

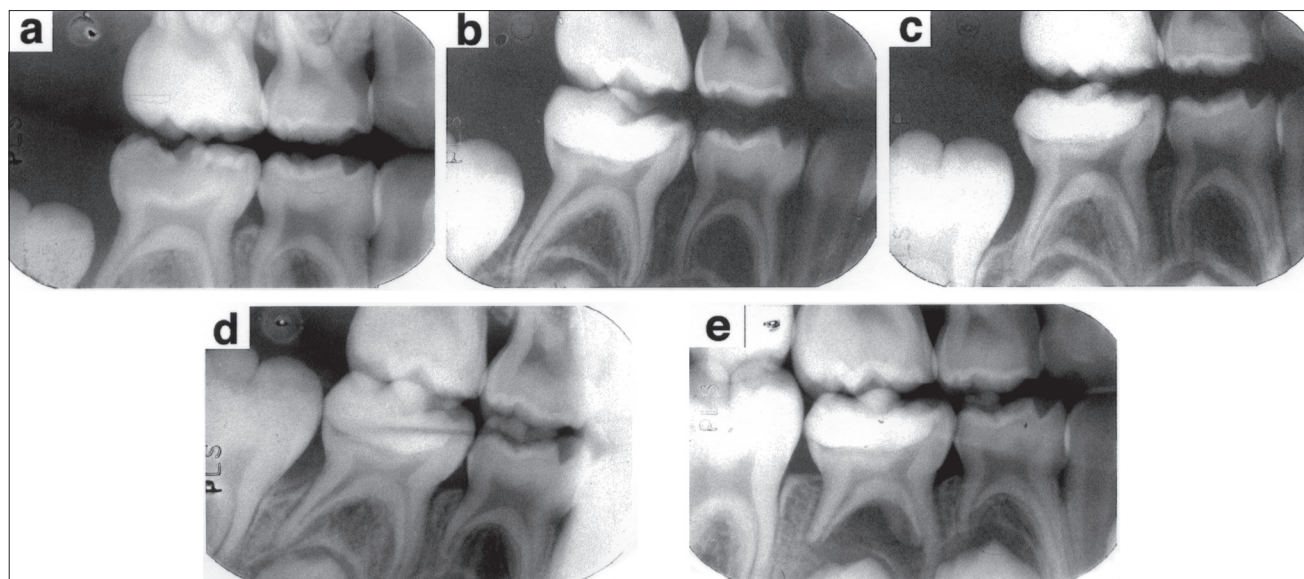


Fig 5. Radiographic evaluation of a mandibular second primary molar that received indirect pulp treatment with calcium hydroxide and was considered a failure after 18 months. Preoperative radiograph (a), immediate postoperative (b) and 6 months (c), 12 months (d) and 18 months (e) after indirect pulp treatment. The interradicular lesion accompanied by external root resorption observed in panel (e) was indicative of treatment failure.

## Discussion

Despite favorable clinical and radiographic outcomes in most clinical trials reported in the literature, the indirect pulp treatment is still not widely used by pediatric dentists.<sup>27</sup> The prospective and randomized clinical trial reported here corroborates the results of previous manuscripts and shows a high percentage of clinical and radiographic success of the indirect pulp-capping treatment after a 2-year follow-up. Importantly, it demonstrates that the 2-year clinical outcome was independent on the application of calcium hydroxide prior to restoration with a composite resin. These findings suggest that, once the grossly decayed dentin is removed and good interfacial seal is provided, the healing and self-repair processes of the dentin-pulp complex are independent from the application of an inducer of mineralization such as calcium hydroxide.

The main objective of the indirect pulp treatment is to maintain the vitality of teeth with reversible pulp injury.<sup>18</sup> The rationale for this treatment modality is based on the observation that postmitotic odontoblasts can be induced to up-regulate their synthetic and secretory activities in response to reduced infectious challenge.<sup>18</sup> This results in deposition of a tertiary dentin matrix—that has the effect of increasing the distance between the caries and the pulp cells—and the deposition of peritubular dentin (sclerotic dentin) that results in decreased dentin permeability.<sup>18</sup> These responses are believed to be mediated by the activation of endogenous signaling molecules, such as TGF- $\beta$ s,<sup>28</sup> that can be found at the dentinal matrix and are solubilized either by cavity conditioning agents or calcium hydroxide.<sup>29</sup>

The traditional technique for indirect pulp treatment utilizes two strategies for the elimination of bacteria from carious dentin substrates left after partial caries removal: (1) the application of a bacteriostatic/bactericidal agent such as calcium hydroxide; and (2) the restoration of the cavity with a material that provides a good marginal seal and limits the nutrient influx necessary to maintain bacterial metabolism and proliferation. The acid etching used for bonding procedures was shown to eliminate most bacterial contamination from tooth structure.<sup>26</sup> Therefore, the total-etch technique may allow for a similar bacteriostatic/bactericidal effect as compared to the effect of calcium hydroxide. Here we observed that the clinical and radiographic outcomes of either total-etch and placement of an adhesive resin or application of calcium hydroxide is similar after 2 years. Future studies are warranted to evaluate the effect of both techniques on the bacterial counts in affected dentin maintained after indirect pulp treatment.

Previous work has demonstrated that well-sealed margins are necessary for the prevention of pulp pathologies.<sup>4,30,31</sup> The ability of composite resins to provide a good marginal seal and prevent microleakage is dependent upon adequate bonding to tooth structure.<sup>4,30,31</sup> Despite the recent finding of a “modified hybrid layer” at the resin/carious primary dentin interface,<sup>32</sup> the bonding of composite resins to carious dentin was shown to be weaker than to sound dentin for most adhesive resin systems tested.<sup>32-34</sup> Therefore, the success of

the indirect pulp treatment is dependent upon complete elimination of caries from the cavosurface margins and from all the lateral walls of the cavity preparation. The only area of carious dentin that should be maintained at the end of the cavity preparation is the one adjacent to the pulp chamber, and all the remaining walls have to be thoroughly cleaned.

The dilemma that clinicians face when performing an indirect pulp treatment is assessing how much caries to leave at the pulpal or axial floor. The carious tissue that should remain at the end of the cavity preparation is the tissue that is necessary to avoid the exposure of the pulp. This requires knowledge of tooth anatomy, clinical experience and a good understanding of the process of caries progression. The use of large, round carbide burs (#6 or #8) allows for better control of the “partial caries removal step” at the site of potential pulp exposure, as compared to the use of spoon excavators. With spoon excavators, the removal of deeper layers of affected dentin and accidental exposure of the pulp is more frequent than with large round burs at low speed. The reward for the use of the indirect pulp treatment is that its overall success rates across several studies reported in the literature is significantly higher than the success rates of direct pulp capping or pulpotomy, the alternative pulp treatments for primary molars with deep dentinal caries.<sup>3,17,35</sup>

Careful diagnosis of the preoperative pulp status is essential for the success of any conservative pulp treatment.<sup>37</sup> Children present an additional challenge for the diagnosis of pulp health, since it is more difficult to obtain reliable information about the intensity and frequency of pain from them. On the other hand, it is generally accepted that the healing capacity of young dental pulps is enhanced, which favors conservative pulp treatment strategies in these teeth. Nevertheless, the low percentage of treatment failure after 2 years suggests that careful clinical and radiographic examination was sufficient to allow for proper selection of teeth for indirect pulp treatment. These findings were recently corroborated by a retrospective study that evaluated the success rates of indirect pulp treatment in the Pediatric Dentistry Clinic of the University of Michigan School of Dentistry.<sup>38</sup> In that study, 9 out of 187 primary molars (5%) treated with indirect pulp treatment by undergraduate or graduate students failed after a follow-up period of up to 43 months.

Indirect pulp treatment has been controversial over the years. The randomized and prospective clinical trial presented here demonstrates a high clinical and radiographic success rate for this procedure. This study suggests that the application of calcium hydroxide over the affected dentin is not a determinant of the successful outcome of the indirect pulp treatment. Thorough diagnoses of pulp status, associated with careful restorative technique involving complete caries removal from the lateral walls of the cavity and proper bonding procedures, are directly correlated with the low percentage of failures reported here for the indirect pulp treatment.

## Conclusions

1. The 2-year outcome of primary molars subjected to indirect pulp treatment and restored with a composite resin was similar when the protection of the dentin-pulp complex was performed with a layer of calcium hydroxide or only with an adhesive resin system.
2. The most frequent cause for failure of the indirect pulp treatment in this study was the development of interradicular and/or periapical lesions that indicated the presence of irreversible pulp inflammation or necrosis.
3. In this prospective and randomized clinical trial, the overall success rate of indirect pulp treatment was approximately 90% after 2 years.

## Acknowledgments

The authors are thankful to Drs. Tatiana Botero and Maria Gabriela Mantellini for their reviews and insightful suggestions for this manuscript. This work was supported, in part, by the Brazilian Dental Association, section of Rio Grande do Sul (ABO-RS).

## References

1. McDonald RE, Avery DR. treatment of deep caries, vital pulp exposure, and pulpless teeth. In: RE McDonald, DR Avery, eds. *Dentistry for the Child and Adolescent*. 6<sup>th</sup> ed. Philadelphia: CV Mosby Co; 1994:428-454.
2. American Academy of Pediatric Dentistry. Reference Manual guidelines for pulp treatment for primary and young permanent teeth. *Pediatr Dent*. 2001;22:67-70.
3. Straffon LH, Loos P. The indirect pulp cap: a review and commentary. *J Israel Dent Assoc*. 2000;17:7-14.
4. Bergenholtz G. Evidence for bacterial causation of adverse pulpal responses in resin-based dental restorations. *Crit Rev Oral Biol Med*. 2000;11:467-480.
5. Loesche W. The symptomatic treatment of dental decay. In: WJ Loesche, ed. *Dental Caries: A Treatable Infection*. 1<sup>st</sup> ed. Grand Haven: Automated Diagnostic Documentation Inc.; 1993:295-298.
6. Plasschaert AJ. The treatment of vital pulps 2: Treatment to maintain pulp vitality. *Int Endod J*. 1983;16:115-120.
7. Fairbourn DR, Charbeneau GT, Loesche WJ. Effect of improved Dycal and IRM on bacteria in deep carious lesions. *JADA*. 1980;100:547-552.
8. King JB JR, Crawford JJ, Lindahl RL. Indirect pulp capping: a bacteriologic study of deep carious dentine in human teeth. *Oral Surg Oral Med Oral Pathol*. 1965;20:663-669.
9. Leung RL, Loesche WJ, Charbeneau GT. Effect of Dycal on bacteria in deep carious lesions. *JADA*. 1980;100:193-197.
10. Fitzgerald M, Heys RJ. A clinical and histological evaluation of conservative pulpal treatment in human teeth. *Oper Dent*. 1991;16:101-112.
11. Hutchins DW, Parker WA. Indirect pulp capping: clinical evaluation using polymethyl methacrylate reinforced zinc oxide-eugenol cement. *J Dent Child*. 1972;39:55-56.
12. Eidelman E, Finn SB, Koulourides T. Remineralization of carious dentin treated with calcium hydroxide. *J Dent Child*. 1965;32:218-225.
13. Law DB, Lewis TM. The effect of calcium hydroxide on deep carious lesions. *Oral Surg Oral Med Oral Pathol*. 1961;14:1130-1137.
14. Nirschl RF, Avery DR. Evaluation of a new pulp capping agent in indirect pulp treatment. *J Dent Child*. 1983;50:25-30.
15. Straffon LH, Corpron RL, Bruner FW, Daprai F. Twenty-four-month clinical trial of visible-light-activated cavity liner in young permanent teeth. *ASDC J Dent Child*. 1991;58:124-128.
16. Aponte AJ, Hartsook JT, Crowley MC. Indirect pulp capping success verified. *J Dent Child*. 1966;33:164-166.
17. Farooq NS, Coll JA, Kuwabara A, Shelton P. Success rates of formocresol pulpotomy and indirect pulp treatment in the treatment of deep dental caries in primary teeth. *Pediatr Dent*. 2000;22:278-286.
18. Tziafas D, Smith AJ, Lesot H. Designing new treatment strategies in vital pulp therapy. *J Dent*. 2000;28:77-92.
19. Nordbo H, Brown G, Tjan AH. Chemical treatment of cavity walls following manual excavation of carious dentin. *Am J Dent*. 1996;9:67-71.
20. Bjorndal L, Thylstrup A. A practice-based study on stepwise excavation of deep carious lesions in permanent teeth: a 1-year follow-up study. *Community Dent Oral Epidemiol*. 1998;26:122-128.
21. Bjorndal L, Larsen T, Thylstrup A. A clinical and microbiological study on deep carious lesions during stepwise excavation using long treatment intervals. *Caries Res*. 1997;31:411-417.
22. Mertz-Fairhurst EJ, Adair SM, Sams DR, et al. Cariostatic and ultraconservative sealed restorations: nine-year results among children and adults. *ASDC J Dent Child*. 1995;62:97-107.
23. Oliveira EF. Clinical, microbiological, and radiographic evaluation of deep carious lesions after partial caries removal. [Estudo clínico, microbiológico e radiográfico de lesões profundas de cárie após a remoção incompleta de dentina cariada]. Masters of Science Dissertation, Universidade Federal do Rio Grande do Sul, Porto Alegre, Brazil, 1999.
24. Perdigão J, Lopes M. Dentin bonding—questions for the new millennium. *J Adhes Dent*. 1999;1:191-209.
25. Costa CA, Hebling J, Hanks CT. Current status of pulp capping with dentin adhesive systems: a review. *Dent Mater*. 2000;16:188-197.
26. Settembrini L, Boylan R, Strassler H, Scherer W. A comparison of antimicrobial activity of etchants used for a total-etch technique. *Oper Dent*. 1997;22:84-88.

27. Primosch RE, Glomb TA, Jerrell RG. Primary tooth pulp treatment as taught in predoctoral pediatric dental programs in the United States. *Pediatr Dent.* 1997;19:118-122.
28. Finkelman RD, Mohan S, Jennings JC, Taylor AK, Jepsen S, Baylink DJ. Quantitation of growth factors IGF-1, SGF/IGF-2, and TGF- $\beta$  in human dentin. *J Bone Mineral Res.* 1991;5:717-523.
29. Smith AJ, Smith G. Solubilization of TGF- $\beta$ 1 by dentine conditioning agents. *J Dent Res.* 1998;77:1034 (Abstr.3224).
30. Bergenholtz G, Cox CF, Loesche WJ, Syed SA. Bacterial leakage around dental restorations: its effect on the dental pulp. *J Oral Pathol.* 1982;11:439-450.
31. Inokoshi S, Iwaku M, Fusayama T. Pulpal response to a new adhesive restorative resin. *J Dent Res.* 1982;61:1014-1019.
32. Ribeiro CC, Baratieri LN, Perdigao J, Baratieri NM, Ritter AV. A clinical, radiographic, and scanning electron microscopic evaluation of adhesive restorations on carious dentin in primary teeth. *Quintessence Int.* 1999;30:591-599.
33. Nakajima M, Sano H, Burrow MF, et al. Tensile bond strength and SEM evaluation of caries-affected dentin using dentin adhesives. *J Dent Res.* 1995;74:1679-1688.
34. Xie J, Flaitz CM, Hicks MJ, Powers JM. Bond strength of composite to sound and artificial carious dentin. *Am J Dent.* 1996;9:31-33.
35. Perdigao J, Swift EJ JR, Denehy GE, Wefel JS, Donly KJ. In vitro bond strengths and SEM evaluation of dentin bonding systems to different dentin substrates. *J Dent Res.* 1994;73:44-55.
36. Ranly DM, Garcia-Godoy F. Current and potential pulp therapies for primary and young permanent teeth. *J Dent.* 2000;28:153-161.
37. Stanley HR. Pulp capping: conserving the dental pulp—can it be done? Is it worth it? *Oral Surg Oral Med Oral Pathol.* 1989;68:628-639.
38. Al-Zayer MA. A clinical success of indirect pulp treatment of primary posterior teeth (a retrospective study). Masters of Science Dissertation, University of Michigan, Ann Arbor, Michigan, 2000.

#### ABSTRACT OF THE SCIENTIFIC LITERATURE



#### IT'S ONLY TEETHING...A REPORT OF THE MYTHS AND MODERN APPROACHES TO TEETHING

As early as the 4<sup>th</sup> century BC Hippocrates observed, "Teething children suffer from itching of the gums, fevers, convulsions and diarrhoea, especially when they cut their eye teeth and when they are very corpulent and costive." A variety of teething remedies to alleviate symptoms were used over time that varied from pig's brain to chicken fat. Lancing of the gums was popular in the 19<sup>th</sup> century since an erupting tooth could cause "functional derangements" to the child via "reflex stimulation" to cranial and spinal nerves. Behavioral changes associated with teething are irritability, night crying and a poor appetite along with drooling, circumoral rash and inflammation of the gums. Treatment is usually symptomatic.

**Comments:** The historical content of this article makes it a real gem. The author presents quite interesting historical teachings and old wives' tales about teething dating back to Hippocrates in the 4<sup>th</sup> century BC. Furthermore, the biological process of teething, timing of tooth eruption, behavioral and physiological changes associated with teething and treatment are covered. As pediatric dentists we are frequently asked questions about this important topic not only in the office, but also in a variety of social settings. This essay provides essential information for enlightened discussion with patients and friends, and makes for informative reading in the waiting room. **JDR**

*Address correspondence to Dr. M.P. Ashley, Department of Restorative Dentistry, Charles Clifford Dental Hospital, Wellesley Road, Sheffield S10 2SZ UK.*

**Ashley, ME. It's only teething...A report of the myths and modern approaches to teething. *Brit Dent J* 191:4-8, 2001.**

8 references