



## A comparison of the pulpal response to freeze-dried bone, calcium hydroxide, and zinc oxide-eugenol in primary teeth in two cynomolgus monkeys

Shahrbanoo Fadavi, DDS, MS    Allen W. Anderson, DDS, MS

### Abstract

*This study assessed the pulp healing response to human freeze-dried bone (FDB) in two cynomolgus monkeys using 36 noncarious primary teeth pulpotomized and randomly assigned to three medicaments. FDB was applied on the pulp stumps and covered with sterile tin foil as experimental group. The two other groups received either calcium hydroxide [Ca(OH)<sub>2</sub>], or IRM (reinforced ZOE). All teeth were restored with amalgam. One animal was sacrificed at 6 weeks and the other 6 months after treatment. Teeth were extracted and placed in 10% formalin. Histological evaluation indicated that 100% of teeth treated with FDB had vital pulps compared with 75% of the Ca(OH)<sub>2</sub> group after 6 weeks. Dentin bridges were present in 87.5% of FDB versus 75% of Ca(OH)<sub>2</sub> group. Inflammatory cells were absent or mild in 100% of FDB-treated versus 75% of the Ca(OH)<sub>2</sub> group. After 6 months, 83.3% of FDB-treated teeth had vital pulps compared with the Ca(OH)<sub>2</sub> group, which showed 100% pulpal necrosis. In FDB-treated pulps, 100% of teeth showed dentin bridges versus 50% of teeth treated with Ca(OH)<sub>2</sub>. Inflammatory cells were absent or mildly present in 83.3% of FDB-treated teeth while 100% of Ca(OH)<sub>2</sub> showed moderate to severe inflammation. IRM-treated teeth all showed pulpal necrosis after 6 months. We concluded that FDB was superior to calcium hydroxide in treating primary pulp dentition in cynomolgus monkeys. (Pediatr Dent 18:52–56, 1996)*

The use of formocresol as a pulpotomy agent has been questioned for many years. Recently concerns have been raised about the toxicity and potential carcinogenicity of formocresol in humans.<sup>1–6</sup> Different alternatives have been sought to maintain partial pulpal vitality. These are electrosurgery,<sup>7,8</sup> laser,<sup>9</sup> and preparations containing corticosteroids,<sup>10–14</sup> collagens,<sup>15–17</sup> glutaraldehyde,<sup>18–20</sup> and freeze-dried bone (FDB).<sup>21</sup>

Our investigation evaluated the tissue response to FDB as a pulp treatment modality in comparison to the traditional method using calcium hydroxide (CH). Al-

though it is presently recommended in the permanent dentition, CH is not recommended for pulpotomies in the primary dentition<sup>22</sup> due to studies describing failures related to the frequent development of chronic pulpal inflammation and internal resorption.

Clinically, FDB has been used in a variety of orthopedic and oral surgical procedures.<sup>23</sup> Its compatibility with the host bone and its effectiveness as a successful graft material have been shown in animal experiments.<sup>24</sup> Moreover, this material induces new bone and stimulates osteogenesis along with cementogenesis.<sup>25</sup> Since pulp and dentin are mesodermal tissues — as are bone and cementum — it seems reasonable to suggest that FDB also may serve as an inducer of a calcific barrier over an amputation (wound) site (as does CH). Additionally, it has been observed that dentin chips in contact with pulp tissue (debris from the opening into the pulp chamber) may serve as a nidus for calcific barrier formation.<sup>26</sup> Furthermore, observations by McLean and Urist<sup>27</sup> show that the proteins of the matrix of bone and dentin contain the precursor of the inducing substance. It is the interaction of mesodermal cells and mesodermal derivatives during the process of bone resorption that induces differentiation of preosteoblasts, osteoblasts, and new bone formation. Thus FDB may be useful as an alternative to formocresol in primary teeth pulpotomy.

In our previous study, FDB proved to be biologically compatible with pulpal tissue. Evidence of reparative dentin formation in the teeth treated with freeze-dried bone suggested an effort by a healthy, vital pulp to wall off or heal the area of insult.<sup>21</sup> Since 12 weeks was a relatively short postoperative evaluation, further studies with larger sample size and longer follow-up seemed to be needed to examine the effect of FDB in a suitable animal model.

It was hypothesized that FDB would promote healing of pulpal tissue and follow a healing pattern and process similar to calcium hydroxide without the disadvantages of internal resorption. The specific objec-

tive of this study was to compare the pulpal response in an animal model to FDB in comparison to CH for a period of 6 months.

## Methods and materials

### Animals

Two male cynomolgus monkeys approximately 20 months old with a full complement of primary and first permanent molar teeth were used for the experiments. Cynomolgus monkeys are important to this study because of the life cycle of the primary teeth and the root development stage in the permanent teeth. Dog teeth are exfoliated too rapidly; and rat teeth do not resorb. The pattern and nature of the pulpal healing in monkey and human teeth have been reported to be identical.<sup>28</sup>

### Pulpotomy technique

The animals were weighed and anesthetized by standard inhalation techniques using thiamylal sodium 2.5%, ketamine (dosage for primates) halothane 0.8%, and nitrous oxide 37%. All operative procedures were performed using a rubber dam and sterile burs. Amputation of coronal pulps was accomplished with sharp spoon excavators to avoid creating dentin debris that could cloud data interpretation. A high-speed handpiece with a continuous water spray was used for all operative procedures. Preoperative periapical radiographs were exposed immediately before treatment to record both the root resorption stage of the primary teeth and the degree of root development of the permanent teeth. After removing the coronal portion of the pulp, a sterile No. 2 cotton pellet saturated with sterile water was placed into the pulp chamber. After 1 min, this cotton pellet was removed and replaced with a second sterile, water-saturated cotton pellet. After an additional 5 min, the cotton pellet was removed and the hemorrhage evaluated.

Pulpotomies were performed on molars, canines, and on only the maxillary incisors. The mandibular incisors in both animals were left untreated for histological analysis of pulpal status during the experimental period. A total of 32 noncarious teeth were randomly assigned to three medicaments. Fourteen teeth were treated with FDB, 10 received  $\text{Ca}(\text{OH})_2$  and eight received IRM only as medicament.

### Medicaments

FDB (Department of Surgery, University of Miami, Miami, FL) was mixed with sterile saline to form a paste according to the manufacturer's instructions.

Calcium hydroxide U.S.P. (Amend Drug & Chemical Co, Irvington, NJ) was selected as the control medicament for this investigation. The second set of control teeth were only pulpotomized and pulp stumps were covered with a tin foil barrier and IRM.

After achieving hemostasis, a paste of FDB or calcium hydroxide was placed with light pressure as a layer of approximately 1-mm thickness over the amputated

pulps. The amount of bone or calcium hydroxide placed in each tooth was directly related to the size of the tooth (permanent versus primary, multi-rooted versus single rooted). However, in each situation, it was sufficient to cover the amputated site.

After applying the pulpal medicaments, the access cavities were sealed with IRM (reinforced zinc oxide-eugenol, Caulk Co, Milford, DE) and amalgam restoration. Special care was taken to eliminate any possibility of premature contacts leading to a traumatic insult. Postoperatively, animals were monitored by Biological Resources Laboratory (BRL) staff for recovery and received their normal diet for the duration of the experiment.

### Clinical and radiographic monitoring

The pulpotomized teeth were monitored clinically for any mobility or soft tissue changes at 6 weeks in the first monkey; and at 6 weeks, 3 months, and 6 months after treatment in the second animal. Radiographic observations also were made at the same intervals in both monkeys to determine any changes in the periodontium of the teeth.

### Histological analysis

One monkey was sacrificed at 6 weeks and another 6 months after treatment. Four teeth that clinically demonstrated loss of occlusal restoration or showed any evidence of fistulus tract were eliminated from the study [one tooth with FDB, two with  $\text{Ca}(\text{OH})_2$ , and one with IRM]. A total of 28 teeth remained for histological analysis. Teeth were extracted and — after restorations were removed immediately using a diamond bur — were placed in a 10% formalin solution. After fixation for 1 week, teeth were radiographed and placed in 8N formic acid in sodium formate for demineralization. After radiographic determination of complete decalcification, they were sectioned longitudinally in a buccolingual direction and embedded in paraffin blocks. Serial sections, approximately 8  $\mu\text{m}$  thick, were prepared to include the pulp, the apex, and the surrounding tissue for histological examination. The sections were stained with hematoxylin and eosin and examined under a light microscope at low and high power by both authors who were standardized using established techniques. Diagnosis consistency between examiners was checked by inter- and intraexaminer tests. Ten histological specimens were examined by the investigators on three separate occasions. Paired *t*-test revealed no significant inter- and intraexaminer differences  $P > 0.1$ . The assessment of the slides was blinded since the specimens were not marked with the name of the medicaments.

### Assessment of inflammation

The reaction of pulpal cells to each medicament was studied according to the parameters as described by Fuks et al.<sup>16</sup> Table 1 shows the assessment criteria.

**TABLE 1. CRITERIA ASSESSMENT OF PULPAL INFLAMMATION**

<i>Pulpal Vitality</i>	<i>Inflammation</i>	<i>Odontoblastic Layer</i>	<i>Dentin Bridge</i>	<i>Pulp Calcification</i>
No necrosis	Absent/mild	Regular	Present	Present
Partial necrosis	Moderate	Irregular	Absent	Absent
Total necrosis	Severe	Absent		

**TABLE 2. CLINICAL AND RADIOGRAPHIC FINDINGS**

<i>Evaluation Criteria</i>	<i>6 Weeks (Total = 31*)</i>			<i>6 Months (Total = 13†)</i>		
	<i>FDB = 14</i>	<i>CH = 9</i>	<i>IRM = 8</i>	<i>FDB = 6</i>	<i>CH = 4</i>	<i>IRM = 3</i>
Fistulus tract	None	None	None	1 (16.6%)	1 (25%)	2 (66.6%)
Mobility	None	None	None	1 (16.6%)	1 (25%)	2 (66.6%)
PDL widening	None	None	None	1 (16.6%)	2 (50%)	2 (66.6%)
Furcation radiolucency	None	None	None	1 (16.6%)	2 (50%)	2 (66.6%)

\* After 6 weeks one tooth treated with Ca(OH)<sub>2</sub> lost filling and was eliminated from evaluation (clinical and radiologic findings in both monkeys).

† After 6 months one tooth with FDB, one with Ca(OH)<sub>2</sub> and one with IRM lost filling and were eliminated from evaluation (clinical and radiologic findings for the only monkey that continued with the study).

## Results

### Clinical and radiographic findings

Clinically and radiographically, there were no pathological signs associated with any of the treated teeth at 6 weeks. A clinical and radiographic examination 6 months after treatment indicated that 16.6% (1 of 6) of teeth treated with freeze-dried bone, 25% (1 of 4) treated with calcium hydroxide, and 66.6% (2 of 3) with IRM and tin-foil only developed fistula and mobility. Radiographically, 16.6% (1 of 6) of teeth treated with FDB, 50% (2 of 4) with calcium hydroxide, and 66.6% (2 of 3) with IRM and tin foil only showed PDL widening and furcation radiolucency (Table 2).

### Histological findings

All of the teeth treated with FDB had vital pulps after 6 weeks compared with 75% of teeth treated with calcium hydroxide. In the FDB-treated pulps, dentin bridges were present in 87.5% of teeth versus 75% in the calcium hydroxide

group. Inflammatory cells were absent or mild in 100% of FDB-treated pulps versus 75% of control teeth treated with calcium hydroxide. All those teeth treated with IRM in the first monkey showed necrosis, severe inflammation, irregular odontoblastic cells, and no sign of dentin bridge formation after 6 weeks (Table 3, Figs. 1–3).

Six-month results indicated the presence of vital pulps in 83.3% of FDB; while in the calcium hydroxide group, 100% of treated teeth showed partial necrosis. Dentin bridge was evident in 100% of FDB versus 50% in those treated with calcium hydroxide. Inflammatory cells were absent or mildly present in 83.3% of FDB-treated teeth; while 50% of calcium hydroxide group showed moderate to severe inflammation. IRM-treated teeth all showed necrosis after 6 months (Table 3, Figs. 4 and 5).

The nontreated mandibular incisor showed normal pulp histologically after 6 months (Fig. 6).

## Discussion

In this study, the hypotheses that FDB would promote healing of pulpal tissue and that it follows a similar healing pattern and process as calcium hydroxide without the disadvantages of internal resorption have been supported.

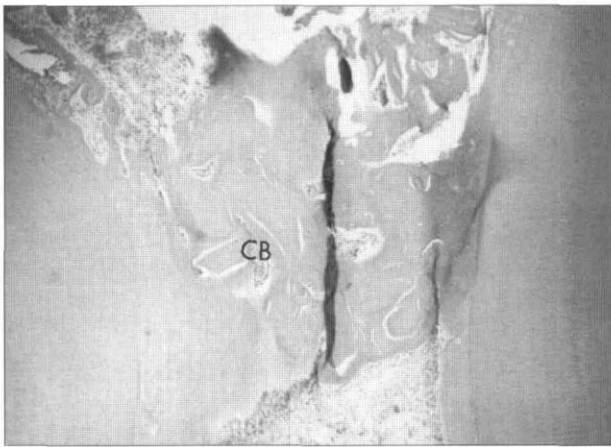
Development of a calcific barrier traditionally has been identified as an indicator of a successful pulp treatment in addition to other criteria such as lack of inflam-

**TABLE 3. HISTOLOGICAL FINDINGS**

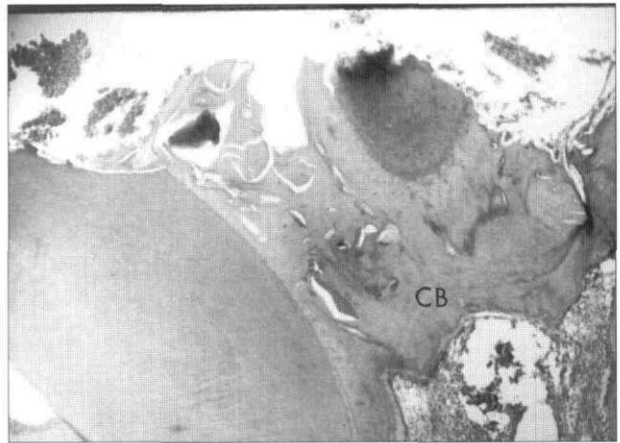
<i>Evaluation criteria</i>		<i>6 Weeks (Total = 15*)</i>			<i>6 Months (Total = 13†)</i>		
		<i>FDB = 7</i>	<i>CH = 4</i>	<i>IRM = 4</i>	<i>FDB = 6</i>	<i>CH = 4</i>	<i>IRM = 3</i>
Vitality	No necrosis	7 (100%)	3 (75%)	0 (0%)	5 (83.3%)	0 (0%)	0 (0%)
	Partial necr.	0 (0%)	1 (25%)	0 (0%)	1 (16.7%)	4 (100%)	1 (33%)
	Total necr.	0 (0%)	0 (0%)	4 (100%)	0 (0%)	0 (0%)	2 (67%)
Inflammation	Abs./mild	7 (100%)	3 (75%)	0 (0%)	5 (83.3%)	0 (0%)	0 (0%)
	Moderate	0 (0%)	1 (25%)	0 (0%)	1 (16.7%)	2 (50%)	0 (0%)
	Severe	0 (0%)	0 (0%)	4 (100%)	0 (0%)	2 (50%)	3 (100%)
Odontoblastic layer change	Regular	7 (100%)	3 (75%)	0 (0%)	2 (33.3%)	0 (0%)	0 (0%)
	Irregular	0 (0%)	1 (25%)	0 (0%)	4 (66.6%)	1 (25%)	0 (0%)
	Absent	0 (0%)	0 (0%)	4 (100%)	0 (0%)	3 (75%)	3 (100%)
Dentin bridge	Present	6 (87.5%)	3 (75%)	0 (0%)	6 (100%)	2 (50%)	0 (0%)

\* After 6 weeks one tooth treated with Ca(OH)<sub>2</sub> lost filling and was eliminated from evaluation (histologic findings of the monkey that was sacrificed at 6 weeks).

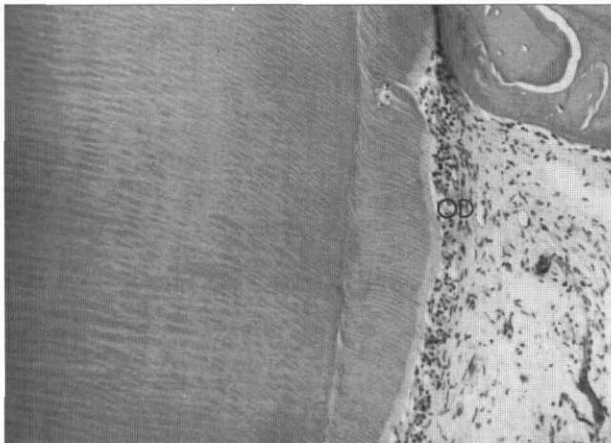
† After 6 months one tooth with FDB, one with Ca(OH)<sub>2</sub> and one with IRM lost filling and were eliminated from evaluation (histological findings of the monkey that was sacrificed at 6 months).



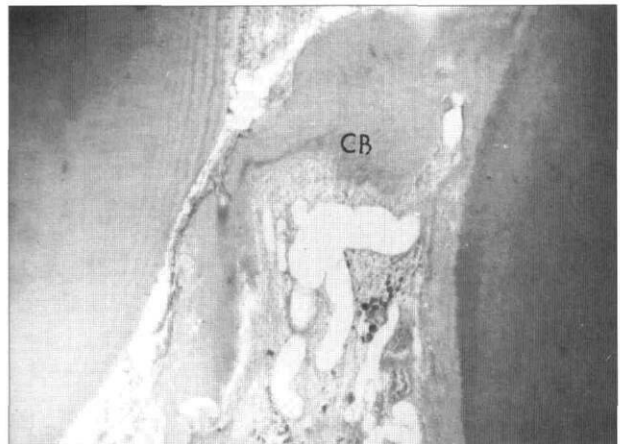
**Fig 1.** Photomicrograph of coronal portion (amputation site) of a maxillary second primary molar 6 weeks after treatment with freeze-dried bone. Observe the calcific barrier (CB) formation at the amputation site (orig mag 5x).



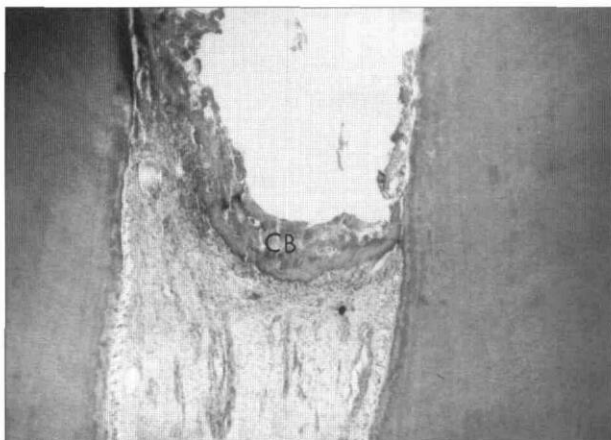
**Fig 4.** Photomicrograph of coronal portion (amputation site) of a maxillary second primary molar 6 months after treatment with freeze-dried bone (orig mag 5x). Note the presence of calcific barrier formation at the amputation site (CB).



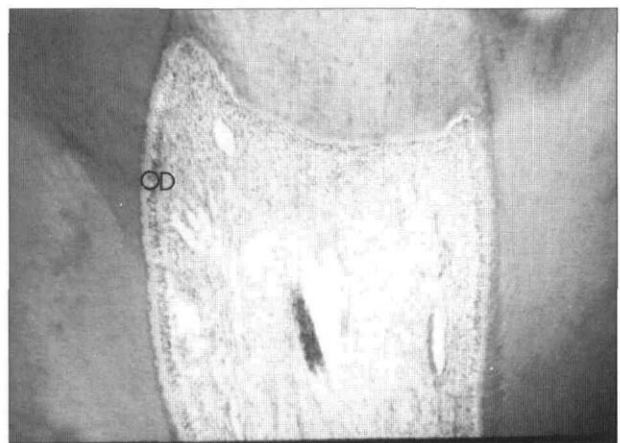
**Fig 2.** A higher magnification of the same tooth showing the presence of normal-appearing odontoblastic cells (OD) (orig mag 40x).



**Fig 5.** Photomicrograph of coronal portion (amputation site) of a maxillary primary canine 6 months after treatment with calcium hydroxide (orig mag 5x). Note the presence of calcific barrier formation at the amputation site (CB).



**Fig 3.** Photomicrograph of coronal portion (amputation site) of a maxillary primary canine 6 weeks after treatment with calcium hydroxide (orig mag 5x). Note the presence of calcific barrier formation at the amputation site (CB).



**Fig 6.** Photomicrograph of a pulp of a nontreated control (mandibular central incisor) after 6 months (orig mag 5x). Note the normal odontoblastic cells (OD).

mation. In this study, teeth treated with FDB showed dentin bridges in 100% of the cases; whereas only 50% of teeth treated with calcium hydroxide had evidence of calcific barrier after 6 months. The evidence of reparative dentin formation in teeth treated with FDB suggested an effort by a healthy, vital pulp to wall off or heal the area of insult.

The formation of calcific barrier along with the state of inflammation prove the superiority of FDB over calcium hydroxide. In this study, teeth treated with FDB showed evidence of moderate inflammatory cells in only 16.6% of the cases; while teeth treated with calcium hydroxide showed moderate or severe inflammation in 100% of treated teeth. The lack of periapical, furcal, or necrotic involvement in teeth treated with FDB suggests that FDB may be a viable pulp amputation dressing without the dissemination and toxic ramifications of formocresol.

FDB offers a promising alternative for the biological approach to pulp therapy. Although its use in pulp therapy may be new, FDB has been employed extensively as an off-the-shelf grafting material in periodontal osseous defects. Clinical and histological studies have shown the effectiveness of FDB technique in regenerating bone and cementum in osseous defects.<sup>24</sup>

It is logical to believe that FDB is a more biologically acceptable material to the pulp tissue than is formocresol (the most widely accepted fixative agent for the pulpotomy procedure in primary teeth in the United States).

## Conclusion

Based on the findings of this study, we conclude that FDB is superior to calcium hydroxide in treating primary pulp dentition in cynomolgus monkeys. Freeze-dried bone should be considered for further studies on vital pulpotomies in human teeth.

Dr. Fadavi is associate professor of pediatric dentistry and Dr. Anderson is dean and professor of pediatric dentistry, College of Dentistry, University of Illinois at Chicago.

1. Avram DC, Pulver F: Pulpotomy medicaments for vital primary teeth: surveys to determine use and attributes in pediatric dental procedure and in dental schools throughout the world. *ASDC J Dent Child* 56:426-34, 1989.
2. Judd PL, Kenny DJ: Formocresol concerns, a review. *Can Dent Assoc J* 53:401-4, 1987.
3. Myers DR, Shoaf HK, Dirksen TR, Pashley DH, Whitford GM, Reynolds KE: Distribution of 14c-formaldehyde after pulpotomy with formocresol. *J Am Dent Assoc* 96:805-13, 1978.
4. Sun HW, Feigal RJ, Messer HH: Cytotoxicity of glutaraldehyde and formaldehyde in relation to time of exposure and concentration. *Pediatr Dent* 12:303-7, 1990.
5. Auerbach C, Moutschen-Dahmen M, Moutschen M: Genetic and cytogenetical effects of formaldehyde and related compounds. *Mutat Res* 39:317-61, 1977.

6. Block RM, Lewis RD, Sheats JB, Burke SG: Antibody formation to dog pulp tissue altered by formocresol within the root canal. *Oral Surg* 45:282-92, 1978.
7. Shaw DW, Sheller B, Barras BD, Morton TH: Electrosurgical pulpotomy — a 6 month study in primates. *J Endod* 13:500-5, 1987.
8. Ruemping DR, Morton TH Jr, Anderson MW: Electrosurgical pulpotomy in primates — a comparison with formocresol pulpotomy. *Pediatr Dent* 5:14-18, 1983.
9. Shoji S, Nakamura M, Horiuchi H: Histopathological changes in dental pulps irradiated by CO<sub>2</sub> laser: a preliminary report on laser pulpotomy. *J Endodont* 11:379-84, 1985.
10. Cowan A: Treatment of exposed vital pulps with a corticosteroid antibiotic agent. *Br Dent J* 120:521-32, 1966.
11. Sykaras SN: The effect of corticosteroid antibiotic compound on the dental pulp: a clinical and histopathological study. *J Br Endod Soc* 6:8-12, 1972.
12. Paterson RC: Corticosteroids and the exposed pulp. *Br Dent J* 140:174-77, 1976.
13. Seow WK, Thong YH: Evaluation of the novel anti-inflammatory agent tetrandrine as a pulpotomy medicament in canine model. *Pediatr Dent* 15:260-66, 1993.
14. Wright KJ, Barbosa SV, Araki K, Spangberg L: In vitro antimicrobial and cytotoxic effects of KRI 1 paste and zinc oxide-eugenol used in primary tooth pulpsectomies. *Pediatr Dent* 16:102-6, 1994.
15. Bimstein E, Shoshan S: Enhanced healing of tooth-pulp wounds in the dog by enriched collagen solution as a capping agent. *Arch Oral Biol* 26:97-101, 1981.
16. Fuks AB, Michaeli Y, Sofer-Saks B, Shoshan S: Enriched collagen solution as a pulp dressing in pulpotomized teeth in monkeys. *Pediatr Dent* 6:243-47, 1984.
17. Fuks AB, Jones PC, Michaeli Y, Bimstein E: Pulp response to collagen and glutaraldehyde in pulpotomized primary teeth of baboons. *Pediatr Dent* 13:142-50, 1991.
18. Tagger E, Tagger M: Pulpal and periapical reactions to glutaraldehyde and paraformaldehyde pulpotomy dressing in monkeys. *J Endod* 10:364-71, 1984.
19. Garcia-Godoy F: A 42-month clinical evaluation of glutaraldehyde pulpotomies in primary teeth. *J Pedod* 10:148-55, 1986.
20. Fuks AB, Bimstein E, Michaeli Y: Glutaraldehyde as a pulp dressing after pulpotomy in primary teeth of baboon monkeys. *Pediatr Dent* 8:32-36, 1986.
21. Fadavi S, Anderson AW, Punwani IC: Freeze-dried bone in pulpotomy procedures in monkey. *J Pedod* 13:108-22, 1989.
22. Troutman KC, et al: Pulp therapy. In: *Pediatric Dentistry*, Stewart RE, Barber TK, Troutman KC, Wei SHY, Eds. St Louis: CV Mosby Co, 1981, pp 908-38.
23. Sepe WW, Bowers GM, Lawrence JJ, Friedlaender GE, Koch RW: Clinical evaluation of freeze-dried bone allografts in periodontal osseous defects. Part II. *J Periodontal* 49:9-14, 1978.
24. Froum SJ, Thaler R, Scoop IW, Stahl S: Osseous autografts. II. Histological responses to osseous coagulum bone blend grafts. *J Periodontal* 46:656-61, 1975.
25. Mellonig JT, Bowers GM, Bright RW, Lawrence JJ: Clinical evaluation of freeze-dried bone allograftism in periodontal osseous defects. *J Periodontal* 47:125-31, 1976.
26. Spedding RM, Mitchell DF, McDonald RE: Formocresol and calcium hydroxide therapy. *J Dent Res* 44:1023-34, Sept-Oct, 1965.
27. McLean FC, Urist MR: Bone. Chicago: University of Chicago Press, 1968.